



Case report

A human tail arising from the anal mucocutaneous junction: A case report

Hussein Ibrahim^{a,*}, Ahmed Maher^a, Hesham Fayek Fouad^b, Tarek Abdelazeem Sabra^a^a Pediatric Surgery Unit, Assiut University Children Hospital, Assiut, Egypt^b General Surgery Department, Assiut University Hospital, Assiut, Egypt

ARTICLE INFO

Keywords:

Human tail

Anal mucocutaneous junction, case report

ABSTRACT

Introduction: Human tails are rare congenital malformations that describe protrusions commonly located around the midline of the lumbosacral region covered by skin, representing an embryonic remnant. Human tails are broadly classified into true and pseudo-tails. The real ones represent the persistence of a remnant of the embryonic tail formed between the fourth and eighth week of gestation.

Presentation: A male infant aged 42 days presented to our institution with a tail-like structure that originated from the anal mucocutaneous junction. The parents did not bring the baby at birth because of the social stigma and ignorance. On examination, there was a tail-like structure that is about 22 cm in length and 1.5 cm in diameter originated from the mucocutaneous junction at the anus at the left side. There was no bony element on palpation. The lower vertebral column examination showed no abnormalities, and this was confirmed with an x-ray. The patient was operated on with simple excision of the tail and primary closure of the wound at the base. He was discharged on the same day well and good. The tail was taken for microscopic histopathology.

Discussion: There are few reported cases describing human tails. However, none of them was originating from the anal mucocutaneous junction.

Conclusion: We report the first case of a human tail arising from the anal mucocutaneous junction worldwide. Due to its very superficial origin, it was not associated with any other anomalies.

1. Introduction

Human tails are rare congenital malformations that describe protrusions located around the midline of the lumbosacral region covered by skin, representing an embryonic remnant [1–3]. Human tails are broadly classified into true and pseudo-tails [2,4]. The real ones represent the persistence of a remnant of the embryonic tail formed between the fourth and eighth week of gestation, being composed of adipose and connective tissue, blood vessels, muscle and nerve fibers. Pseudo-tails are protuberances mainly containing adipose or cartilaginous tissue and bone elements [1,5]. The purpose of this article is to present a case of a real human tail that is unique in its position, arising from the anal mucocutaneous junction in a 42 days old infant.

2. Case report

A male infant aged 42 days presented to our institution with a tail-like structure that originated from the anal mucocutaneous junction (Fig. 1A and B). The parents did not bring the baby at birth because of

the social stigma, ignorance, and shame. On history taking there was neither specific prenatal exposure, prenatal diagnosis nor similar family history. On examination, there was a tail-like structure 22 cm in length and 1.5 cm in diameter originated from the mucocutaneous junction at the anus at the left side (Fig. 1A and B). There was no bony element on palpation. The lower vertebral column examination showed no abnormalities, and this was confirmed with an x-ray. The patient was operated on with simple excision of the tail and primary closure of the wound at the base (Fig. 2A and B). He was discharged on the same day well and good. The tail was taken for microscopic histopathology. The infant did not come for follow up. This case was reported in line with the SCARE 2020 criteria [6] (Fig. 3).

3. Discussion

Human tails are rare entities that represent the remnant of an embryonic vestige [3,7]. They have been reported by the end of the nineteenth century, being small sized and present around the midline and lumbosacral area [7,8]. In this article, we reported the first case of a

* Corresponding author.

E-mail address: husinfarah@aun.edu.eg (H. Ibrahim).<https://doi.org/10.1016/j.ijscr.2021.106228>

Received 10 June 2021; Received in revised form 18 July 2021; Accepted 20 July 2021

Available online 22 July 2021

2210-2612/© 2021 Published by Elsevier Ltd on behalf of IJS Publishing Group Ltd. This is an open access article under the CC BY-NC-ND license

<http://creativecommons.org/licenses/by-nc-nd/4.0/>.

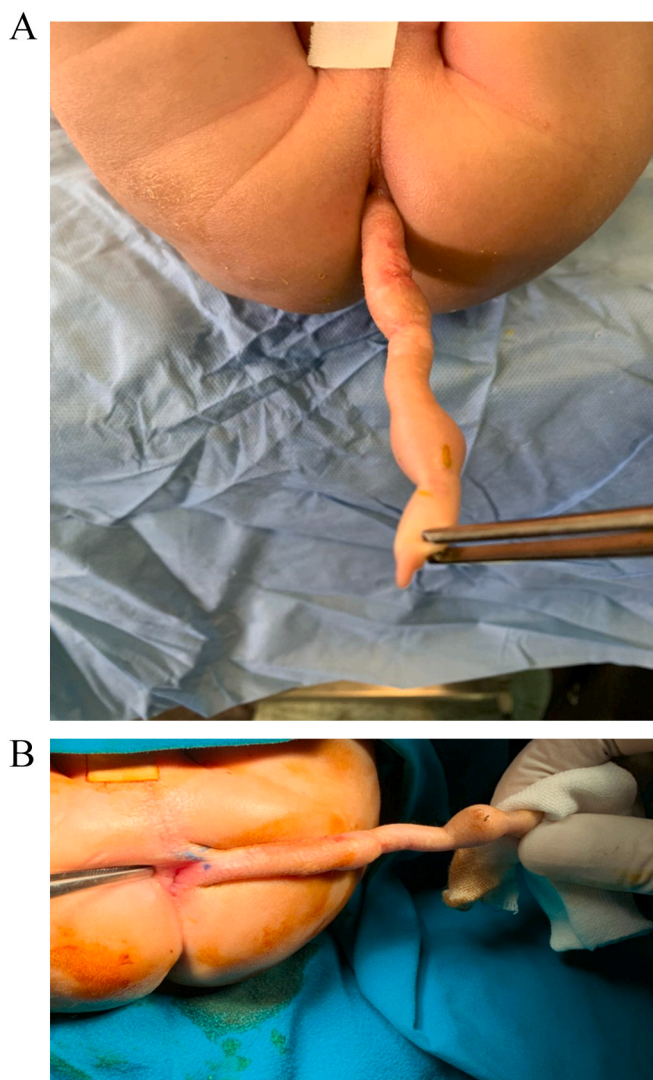


Fig. 1. A and B showing a tail-like structure about 22 cm in length and 1.5 cm in diameter originating from left side of the anal muco-cutaneous junction.

human tail originating from the mucocutaneous junction at the left side of the anus. Owing to this very superficial and distal position away from the vertebrae and the spinal cord, physical examination was conclusive and there was no need for sophisticated neurological examination nor

Magnetic resonance imaging (MRI).

Human tails are frequently associated with Occult Spinal Dysraphism (OSD) (60%), lipomas (30%), anchored spinal cord (26%) or other congenital malformations [3,7]. Spina bifida is considered as the most frequent anomaly reported with the human tail [1,7,10,11,12]. In our case, the tail was very superficial and low in its position. It was not related to the vertebrae nor the spinal cord. There were no associated anomalies.

There is much confusion regarding the definition of human tail and its classification. Harrison [13] described anything that is appended to sacral or coccygeal region as a tail. Virchow [14] in 1880 probably first categorized human tail into: (a) Cauda perfecta – tails containing vertebrae, (b) Cauda imperfect – tails without any vertebrae, and (c) various protrusions that resembled tail (pseudotails). Dao and Netsky's [15] system of classification has been popularly used to classify these appendages. They published an article entitled "Human tails and pseudotails" in 1984. They defined a true human tail as a boneless, midline protrusion which contains adipose and connective tissue, striated muscle, blood vessels, and nerves covered by normal skin with hair follicles and sweat glands but no bone, cartilage, notochord, or spinal cord components. As regarding "pseudotail" term, it describes protruding lesions in the lumbosacral region and resembles true tails such as coccygeal vertebrae, lipomas, teratomas, chondromegaly, glioma, and parasitic fetus. Our case can be classified as "True tail" according to "Dao and Netsky's" system of classification. A new classification was recently postulated by Tojima S. et al. [11], dividing human tails into four groups depending on the presence of bone elements and location. Type I are lesions that contain bone elements, subdivided into AI, in cases of coccyx protrusions, and type IB, for tails with non-coccygeal bone elements. Type II are tails without bone elements, divided into IIA, when located above the intergluteal cleft, and IIB when located in the perianal region on the left or right [11]. According to this classification, the reported case can be grouped as a human type IIB tail.

The pathophysiology is not fully understood, but Lu et al. (1998), reported that the premature focal disjunction of the neural tube plays a vital role in the disturbance of the development and regression of the human tail during embryonic life [7]. Failure of fusion of the neural tube exposes the paraxial mesoderm to the posterior side of the neural ectoderm, ending in the formation of lipogenic components, which would support the fact that mature adipose tissue is the main element present in histopathology and the high incidence of lipomas (27.12%) in the reported cases [7]. In our case, the microscopic histopathology picture revealed hamartoma with presence of tissue fragments covered by keratinized stratified squamous epithelium with skin appendages (sweat glands, sebaceous glands). Subepithelial tissue composed of adipose tissue, muscle bundles and blood vessels. No cartilage or bone tissue could be detected. All structures are mature. No immature

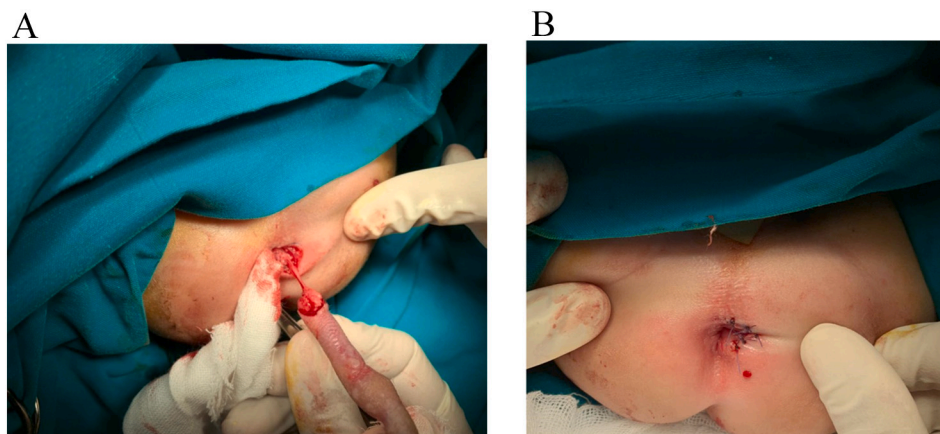


Fig. 2. A and B showing simple excision of the tail and primary closure of the wound at the base.

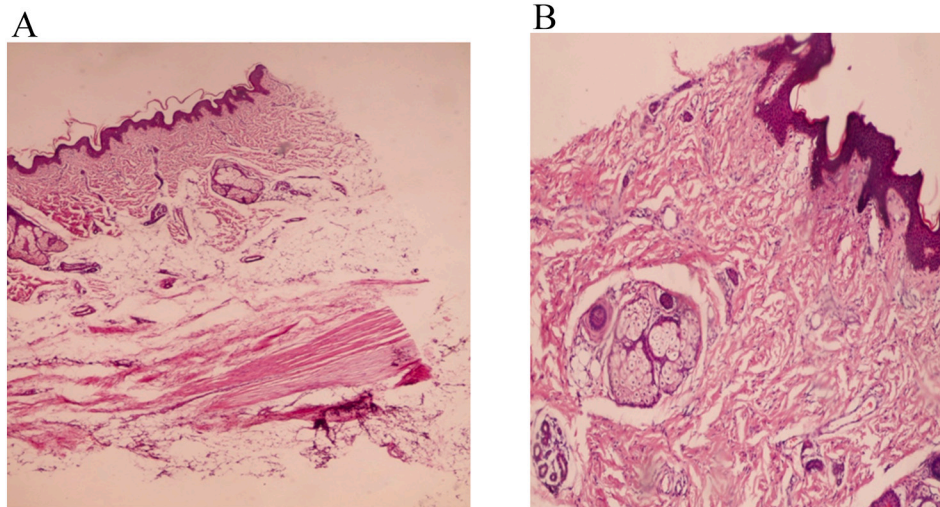


Fig. 3. A and B showing histopathological findings of the human tail.

elements, atypia or features of neoplasia could be detected.

Treatment for human tails should be done with surgical resection of this appendix, based on clinical and radiological examinations, [2,11,16,17]. Our patient was operated on with simple excision of the tail and primary closure of the wound at the base. He was discharged on the same day well and good.

4. Conclusion

Human tail is not a common problem in humans and it was never reported to arise from the anal mucocutaneous junction. we reported a unique case that was superficial needing only simple excision and the tail was sent for histopathological study.

Sources of funding

No sources of funding.

Ethical approval

The case report is exempt from ethical approval in my institution.

Consent

Written informed consent was obtained from the patient's parents for publication of this case report and accompanying images. A copy of the written consent is available for review by the Editor-in-Chief of this journal on request.

Author contribution

Hussein Ibrahim: main author of the paper and wrote the manuscript.

Ahmed Maher: literature review.

Hesham Fayek Fouad: revised the manuscript.

Tarek Abdelazeem Sabra: supervising and editing.

Registration of research studies

Not applicable

Guarantor

Hussein Ibrahim Ahmed Ibrahim.

Provenance and peer review

Not commissioned, externally peer-reviewed.

Declaration of competing interest

No conflict of interest.

References

- [1] D.K. Singh, B. Kumar, V.D. Sinha, Bagaria HR the human tail: rare lesion with occult spinal dysraphism - a case report, *J. Pediatr. Surg.* 43 (9) (2008) e41–e43.
- [2] B. Mukhopadhyay, R.M. Shukla, M. Mukhopadhyay, K.C. Mandal, P. Haldar, Benare a spectrum of human tails: a report of six cases, *J. Indian Assoc. Pediatr. Surg.* 17 (1) (2012) 23–25.
- [3] K. Oliveira, A.L. Leite, A.P. Sousa, Silva AV cola humana: lesión rara con disrafismo Espinal oculo, *Cir. Pediatr.* 27 (2004) 146–148.
- [4] G. Canaz, N. Akkoyun, E. Emel, O.M. Cevik, S. Baydin, Gokcedag a a rare case of "human tail" associated with lipomyelomeningocele and tethered cord, *J. Pediatr. Neurosci.* 13 (2) (2018) 241–244.
- [5] A.H. Dao, Netsky MG human tails and pseudotails, *Hum. Pathol.* 15 (5) (1984) 449–453.
- [6] for the SCARE Group, R.A. Agha, T. Franchi, C. Sohrabi, G. Mathew, The SCARE 2020 guideline: updating consensus Surgical CASE REport (SCARE) guidelines, *Int. J. Surg.* 84 (2020) 223–226.
- [7] F.L. Lu, P.J. Wang, R.J. Teng, Yau KIT the human tail, *Pediatr. Neurol.* 19 (1998) 230–233.
- [8] D. Kumar, Kapoor a human tail: nature's aberration, *J. Child Neurol.* 27 (7) (2012) 924–926.
- [9] N.A. Muthukumar, Bony human tail causing tethered cord syndrome: case report, *Childs Nerv. Syst.* 30 (4) (2014) 703–707.
- [10] S. Tojima, S. Yamada, Classification of the "human tail": correlation between position, associated anomalies, and causes, *Clin. Anat.* 22 (6) (2020) 1–14.
- [11] M.K. Pillai, Nair ST a true human tail in a neonate: case report and literature review, *Sultan Qaboos Univ. Med. J.* 17 (1) (2017) e109–e111.
- [12] R.G. Harrison, On the occurrence of tails in man, with a description of the case reported by Dr Watson, *Johns Hopkins Hosp. Bull.* 12 (1901) 96–101.
- [13] R. Virchow, Über schwanzbildung beim menschen, *Virchows Arch. Pathol. Anat. Physiol.* 79 (1880) 176–182.
- [14] A.H. Dao, M.G. Netsky, Human tails and pseudotails, *Hum. Pathol.* 15 (1984) 449–453.
- [15] P.J. Giri, Chavan VS human tail: a benign condition hidden out of social stigma and shame in young adult - a case report and review, *Asian J. Neurosurg.* 14 (1) (2019) 1–4.
- [16] V. Nair, J.S. Nigam, A.H. Deshpande, J.N. Bharti, Patil NP curious tale of human tail, *Pediatr. Dev. Pathol.* 21 (3) (2018) 341–342.