



Since January 2020 Elsevier has created a COVID-19 resource centre with free information in English and Mandarin on the novel coronavirus COVID-19. The COVID-19 resource centre is hosted on Elsevier Connect, the company's public news and information website.

Elsevier hereby grants permission to make all its COVID-19-related research that is available on the COVID-19 resource centre - including this research content - immediately available in PubMed Central and other publicly funded repositories, such as the WHO COVID database with rights for unrestricted research re-use and analyses in any form or by any means with acknowledgement of the original source. These permissions are granted for free by Elsevier for as long as the COVID-19 resource centre remains active.

Contents lists available at [ScienceDirect](https://www.sciencedirect.com)

Journal of Cardiothoracic and Vascular Anesthesia

journal homepage: www.jcvaonline.com

Case Report

Anesthetic Considerations in a Patient With LVAD and COVID-19 Undergoing Video-Assisted Thoracic Surgery

Rutuja R. Sikachi, MD¹, Diana Anca, MD*Department of Anesthesiology, Zucker School of Medicine at Hofstra/Northwell, New Hyde Park, NY*

Increased survival with left ventricular assist devices (LVAD) has led to a large number of patients with LVADs presenting for noncardiac surgeries (NCS). With studies showing that a trained noncardiac anesthesiologist can safely manage these patients when they present for NCS, it is vital that all anesthesiologists understand the LVAD physiology and its implications in various surgeries. This is even more relevant during the current pandemic in which these complex cardiopulmonary interactions may be even more challenging in patients with coronavirus disease 2019 (COVID-19). The authors describe a case of a patient with COVID-19 with an LVAD who needed thoracoscopic decortication for recurrent complex pleural effusion and briefly discuss unique challenges presented and their management.

© 2021 Published by Elsevier Inc.

Key Words: left ventricular assist device; noncardiac surgery; video-assisted thoracic surgery; COVID-19; cardiothoracic anesthesia

INCREASED SURVIVAL with left ventricular assist devices (LVAD) has led to a large number of patients with LVADs presenting for noncardiac surgeries (NCS).^{1,2} These NCS may be needed for managing complications arising from LVAD or otherwise. With studies showing that a trained noncardiac anesthesiologist can safely manage these patients when they present for NCS, it is vital that all anesthesiologists understand the LVAD physiology and its implications in various surgeries.³⁻⁵ This is even more relevant during the current pandemic in which these complex cardiopulmonary interactions may be even more challenging in patients with coronavirus disease 2019 (COVID-19). Patients with an LVAD may present for minor procedures, such as endoscopies or major surgeries including general, vascular, or thoracic surgeries.⁶ They may undergo monitored anesthesia care or general anesthesia with various monitoring modalities ranging from noninvasive to invasive depending on the clinical situation and stability of the patient.⁷ The authors describe a case of a patient with COVID-19 with an LVAD who needed thoracoscopic decortication for

recurrent complex pleural effusion. They briefly discuss unique challenges presented and their management in this report.

Case Report

A 51-year-old woman with a HeartMate 3 (Abbott, Chicago, IL) and who was hemodialysis-dependent was hospitalized for a COVID-19 infection (height: 158 cm; weight: 59 kg; BMI: 23.6 kg/m²). She was transitioned from ECMO to LVAD as destination therapy six months prior for stage D congestive heart failure from lymphocytic myocarditis. During her previous year-long hospital stay, she had undergone multiple procedures. This included an indwelling tracheostomy that recently was decannulated. During the stay, her chronic left-sided pleural effusion was found on CT scans to be increased and loculated, not amenable to drainage with a simple indwelling pleural catheter. Hence, she was scheduled to undergo left-sided video-assisted thoracic surgery for decortication (Fig 1).

During preoperative evaluation, the LVAD was found to be adequately functional, with a speed of 5,600 revolutions per minute, flow of 3.5 L/min, power of 4.1 watts, and pulsatility index of 1.9, with a mean arterial pressure of 90 mmHg.

¹Address correspondence to Rutuja Sikachi, MD, Department of Anesthesiology, Zucker School of Medicine at Hofstra/Northwell, 270-5 76th Avenue, New Hyde Park, NY 11040.

E-mail address: rsikachi@northwell.edu (R.R. Sikachi).

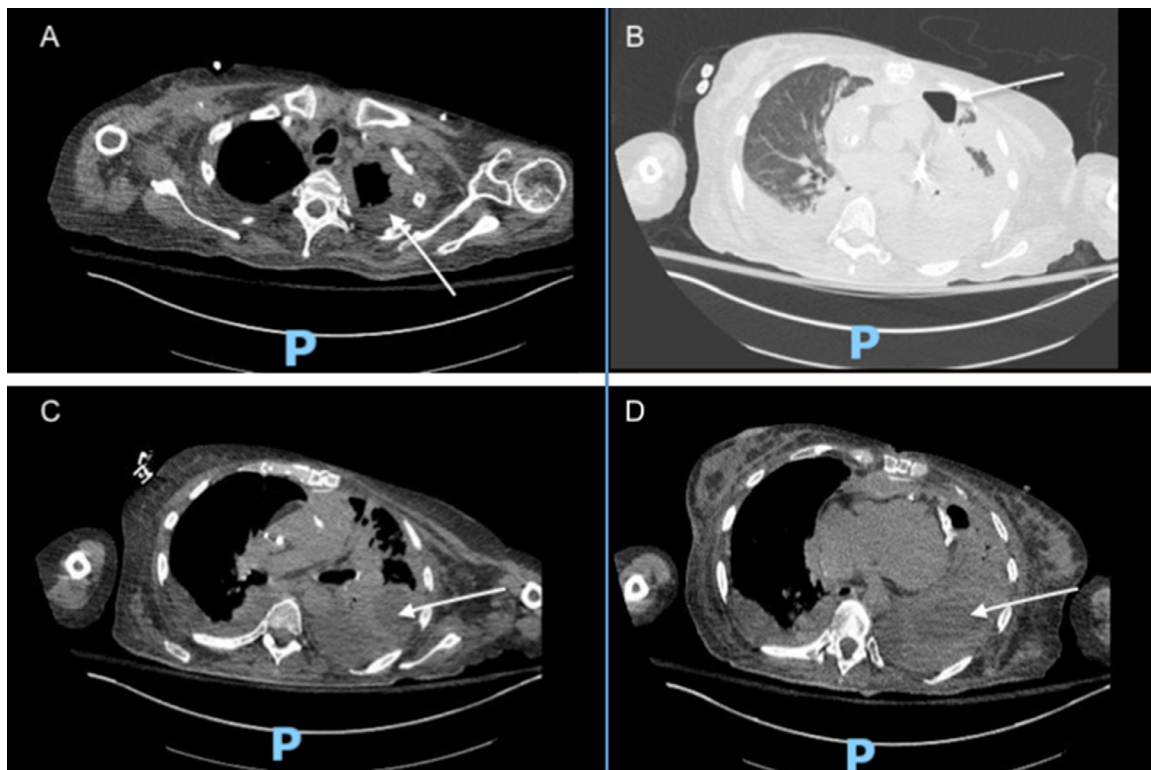


Fig 1. Computed tomography of the chest with axial cuts demonstrating a complex left pleural effusion with a component of hydropneumothorax. (A) Arrow demonstrating thickened left pleura. (B) Arrow demonstrating loculated pocket of air anteriorly with fluid posteriorly (hydropneumothorax). (C) Arrow demonstrating complex left pleural space with atelectatic lung, loculated pleural effusion, and thickened pleura. (D) Arrow demonstrating loculated pleural effusion.

Preoperative oxygenation was stable on room air. Transthoracic echocardiogram showed severe global left and right ventricular systolic dysfunction but no pericardial effusion, septal defects, or cardiac thrombi. From physical examination and previous anesthesia records, she was found to have limited mouth opening, Mallampati grade 3 airway. Mask ventilation easily was achieved, but intubations were performed with a video laryngoscope (GlideScope, Verathon, Bothell, WA) with moderate difficulty in the past. The respiratory examination showed decreased air entry on the left side with no wheezing or stridor. Her anticoagulation with warfarin was bridged with heparin infusion for the surgery and was stopped on the morning of the surgery. Preoperative coagulation profile was found to be normal. A preoperative fiberoptic evaluation was not performed due to absence of any radiologic signs of stenosis on the CT scan and based on the authors' discussions with the thoracic surgery team.

In the operating room, a routine five-lead ECG was applied to the chest and a pulse oximeter and NIBP cuff were applied to the right arm. A defibrillator was available on standby. A preinduction arterial line was inserted in the left brachial artery under ultrasound guidance. A peripherally inserted central venous catheter already was present and was used for intravenous medications. General anesthesia was induced after low-flow preoxygenation with intravenous etomidate 16 mg, 50 μ g of fentanyl, and succinylcholine 100 mg. The airway was secured, once the patient became completely apneic, with an 8.0-mm standard cuffed endotracheal tube under video laryngoscopy visualization. Adequate PPE was used during the

entire procedure. An endobronchial blocker (Uniblocker, Fuji, 9 Fr) was inserted and secured in the left mainstem bronchus under fiberoptic bronchoscopic (FOB) guidance. The patient was positioned in the right lateral position to facilitate surgery, and the position of the endobronchial blocker was confirmed with FOB once again. The patient was ventilated only after confirming a closed system throughout these maneuvers given the positive COVID-19 status. Anesthesia was maintained with intravenous fentanyl, sevoflurane/oxygen, and cisatracurium. The LVAD parameters did not change after initiating one-lung ventilation. The arterial blood gas analysis once one-lung ventilation was established demonstrated a pH of 7.27 with P_{CO_2} of 55 and P_{O_2} of 339. Ventilation was adjusted to maintain normocarbica and was monitored throughout the procedure using end-tidal CO_2 and frequent ABGs. The pH and P_{CO_2} showed improvement once ventilation was adjusted and adequate oxygenation was maintained. MAP was maintained at about 80-to-90 mmHg throughout, close to the patient's baseline, with balanced anesthesia using sevoflurane, fentanyl, and cisatracurium. Administration of a vasopressor was not necessary. A transesophageal echocardiogram (TEE) was on standby in case further invasive monitoring was required during the procedure. All the involved personnel in the room wore appropriate personal protective equipment during the surgery. The TEE cart was covered with a plastic cover. Only required personnel, instruments, and medications were kept in the room, with one circulating nurse right outside the room to help with additional supplies if required.

At the end of the surgery, an intercostal block was performed with liposomal suspension of 1.3% bupivacaine, as postoperative opioid patient-controlled analgesia was rendered inappropriate for this patient. The bronchial blocker was removed and two-lung ventilation was established. The patient was extubated after reversal with neostigmine and glycopyrrolate and meeting all the extubation criteria. She was transferred to the intensive care unit (ICU) awake and alert with supplemental oxygen and was restarted on intravenous heparin infusion. The surgical pathology from the procedure demonstrated an acute fibrinous pleuritis that was managed with antibiotics.

Discussion

Patients with LVADs often have reduced right ventricular function, and it is imperative to avoid factors that worsen pulmonary vascular resistance during the anesthetic management. Anesthetic management of these patients becomes even more challenging during thoracoscopic procedures given the cross-interactions between the LVAD physiology and one-lung ventilation physiology. In addition, patients with COVID-19 often present with pulmonary findings that can affect the pulmonary vascular resistance secondary to hypoxemia and make the management of these patients even more challenging. Another additional anesthetic consideration in the management of such a patient with COVID-19 undergoing one-lung ventilation is to avoid exposure of healthcare personnel given its potential as an aerosol-generating procedure.

In this patient, one-lung ventilation was achieved with a bronchial blocker. The bronchial blocker can offer fewer hemodynamic disturbances as compared with a double-lumen tube.⁸ Known difficult airway, history of tracheal stoma or constriction, and limited mouth opening are relative contraindications for use of a double-lumen tube and this patient had all of them.^{9,10} The Uniblocker was selected based on the ease of use and the preference of the attending anesthesiologist. Also, during the COVID-19 pandemic, a survey conducted by the European Association of Cardiothoracic Anesthesia showed that a bronchial blocker was the preferred technique for lung isolation in patients who were COVID-19-positive, were already intubated, and had difficult airways.¹¹ It also is easy to maintain a closed circuit with a bronchial blocker, and it can help minimize aerosolization and exposure of perioperative personnel to the virus.¹² Other described techniques to facilitate one-lung ventilation in a patient with suspected or confirmed COVID-10 infection include a laparoscopy smoke evacuation system with an attached filter connected to the tracheal lumen of the double-lumen tube to prevent aerosolization of the particles and exposure of healthcare workers.¹³

While dealing with LVAD patients, the main focus is on supporting the right ventricular function to maintain hemodynamic stability.⁷ LVAD function is preload-dependent and afterload-sensitive.⁷ Physiologically, preload depends on venous return, right ventricular function, and pulmonary vascular resistance, all of which can be adversely affected during

thoracoscopic procedures. Venous return decreases with lateral positioning as well as positive-pressure ventilation. With left lateral positioning there also is a risk of kinking of the LVAD drive-line. Pump flow should be closely monitored during positioning, and preload and afterload should be adjusted as needed. The right ventricle is often poorly functional in patients with an LVAD due to global cardiomyopathy, as in the authors' patient. This is further worsened due to an increase in pulmonary vascular resistance during one-lung ventilation and hypercarbia. Ventilation should be adjusted so as to avoid hypoxia, hypercarbia, and acidosis to avoid right heart strain. This may necessitate switching to two-lung ventilation.

Similar to preload, afterload also needs close monitoring and management. Afterload is increased with inadequate depth of anesthesia and sympathetic stimulation from laryngoscopy. This can reduce the pump flow and promote pump thrombosis. On the other hand, vasodilation from anesthesia can reduce the afterload, causing excessive offloading from the left ventricle. This creates anatomic distortion of the right ventricle, leading to a suck-down phenomenon. Invasive monitoring with a pulmonary artery catheter or TEE is very helpful in guiding afterload management with fluids, blood products, and vasoactive drugs, as needed, and should be used if an LVAD patient is unstable. If required, vasopressin can be a good vasopressor choice for such procedures, as it has minimal effect on pulmonary vasculature.¹⁴ Although it is important to understand the complex cardiopulmonary interactions in these patients, there were no hemodynamic disturbances noted in this patient and the use of a vasopressor was not necessary. Postoperatively, these patients should be cared for in the ICU setting by personnel knowledgeable about LVADs. For pain management, regional and nonopioid analgesia techniques should be preferred, as opioids can lead to hypoventilation causing hypoxia, hypercarbia, and acidosis, which have caused fatalities.¹⁵ In addition, it is important to optimally manage the anticoagulation status during surgical interventions in patients with an LVAD. Although anticoagulation carries the risk of bleeding during the procedure, being off anticoagulation for prolonged periods can lead to pump thrombosis. A well-coordinated multidisciplinary approach is essential to minimize the time off anticoagulation. For surgeries with a high risk of bleeding, warfarin can be held and bridged with heparin infusion, which can be stopped on the morning of the planned procedure. After the procedure, warfarin may be resumed when the risk of bleeding is acceptable. The patient can be bridged with heparin while waiting for the international normalized ratio to reach the target.^{7,16} The patient was bridged with heparin, which was stopped on the morning of the procedure, and restarted once the patient postoperatively was stable. The anesthetic challenges, as well as approach to a patient with an LVAD undergoing one-lung ventilation, is described in [Table 1](#).

Thus, in summary, the authors describe the challenges of dealing with patients with LVAD undergoing noncardiac surgeries, especially during the COVID-19 pandemic.

Table 1
Summary of Anesthetic Challenges and Approach in Patient With LVAD Undergoing One-Lung Ventilation

Multidisciplinary planning: Close communication between LVAD management team, surgery, and cardiac anesthesia; discussion should involve preoperative optimization, postoperative recovery, and care; intra- and postoperative need for invasive monitoring, transfusion goals, adequacy of vascular access, and central vascular access planning as patients may be difficult to cannulate.

Anticoagulation: Considerable institutional variability; for nonemergent procedures warfarin and anti-platelets may be continued if the risk of bleeding is low; if need to be stopped, bridging with heparin or heparin alternative should be considered; emergent cases may require reversal of anticoagulation with fresh frozen plasma, prothrombin complex concentrate, or vitamin K. Decisions pertaining to anticoagulation should be taken in a multidisciplinary fashion and tailored to each case.

Monitoring: Monitoring the LVAD monitor (speed, power, flow, pulsatility index [PI]), might require the LVAD team/nurse in the room; pulse oximetry and NIBP may not be helpful, depending on the degree of pulsatility; cerebral oximetry could be an adjuvant to pulse oximetry and gauge of CO; ABG could be used to assess oxygenation; several studies show that NIBP sufficiently reliable for short procedures, such as endoscopies; RV failure most directly diagnosed via TEE, but can be inferred from high CVP, hypotension, and increased pressor requirements; use of TEE, invasive monitoring such as arterial line for moderate- to high-risk procedures, fluid, and cardiac output management with a PA catheter should be considered for patients with LVAD.

Hemodynamic management: Maintain preload with judicious use of fluid and blood products; discuss with LVAD team for lowest acceptable hematocrit and transfuse accordingly; manage afterload so as to maintain MAP and LVAD flow rate close to baseline.

Ventilation: Avoid hypoxia, hypercarbia, and acidosis, which can worsen right heart function; if positive pressure ventilation, avoid high PEEP, high tidal volume, watch for high airway pressures, choose technique to achieve 1-lung ventilation based on clinical presentation, anticipate if patient may remain intubated at the end of procedure. If required, vasopressin can be a good vasopressor choice as it has minimal effect on pulmonary vasculature.

Positioning: Watch for kinks in LVAD driveline while positioning; take care to avoid any accidental dislodgment or disconnection of any LVAD component during positioning and repositioning.

Abbreviations: ASA, American Society of Anesthesiologists; ECG, electrocardiogram; LVAD, left ventricular assist device; MAP, mean arterial pressure; NIBP, noninvasive blood pressure; PA, pulmonary artery; PEEP, positive end-expiratory pressure; TEE, transesophageal echocardiography.

Conflict of Interest

None.

References

- 1 Chung M. Perioperative management of the patient with a left ventricular assist device for noncardiac surgery. *Anesth Analg* 2018;126:1839–50.
- 2 Rose EA, Gelijns AC, Moskowitz AJ, et al. Long-term use of a left ventricular assist device for end-stage heart failure. *N Engl J Med* 2001;345:1435–43.
- 3 Brown TA, Kerpelman J, Wolf BJ, et al. Comparison of clinical outcomes between general anesthesiologists and cardiac anesthesiologists in the management of left ventricular assist device patients in noncardiac surgeries and procedures. *J Cardiothorac Vasc Anesth* 2018;32:2104–8.
- 4 Degnan M, Brodt J, Rodriguez-Blanco Y. Perioperative management of patients with left ventricular assist devices undergoing noncardiac surgery. *Ann Card Anaesth* 2016;19:676–86.
- 5 Tickoo M, Bardia A. Anesthesia at the edge of life: Mechanical circulatory support. *Anesthesiol Clin* 2020;38:19–33.
- 6 Taghavi S, Jayarajan SN, Ambur V, et al. Noncardiac surgical procedures after left ventricular assist device implantation. *ASAIO J* 2016;62:370–4.
- 7 Hwang KY, Hwang NC. Facilitating noncardiac surgery for the patient with left ventricular assist device: A guide for the anesthesiologist. *Ann Card Anaesth* 2018;21:351–62.
- 8 Lu Y, Dai W, Zong Z, et al. Bronchial blocker versus left double-lumen endotracheal tube for one-lung ventilation in right video-assisted thoracoscopic surgery. *J Cardiothorac Vasc Anesth* 2018;32:297–301.
- 9 Bora V, Kritzmire S. Double lumen endobronchial tubes. <https://www.statpearls.com/nursepractitioner/ce/activity/20690/?specialty=Nurse-%20Anesthetist>. Accessed October 12, 2020.
- 10 Campos JH. Lung isolation techniques for patients with difficult airway. *Curr Opin Anaesthesiol* 2010;23:12–7.
- 11 Senturk M, El Tahan MR, Szegedi LL, et al. Thoracic anesthesia of patients with suspected or confirmed 2019 novel coronavirus infection: Preliminary recommendations for airway management by the European Association of Cardiothoracic Anaesthesiology Thoracic Subspecialty Committee. *J Cardiothorac Vasc Anesth* 2020;34:2315–27.
- 12 Tryphonopoulos P, McFaul C, Gagne S, et al. COVID-19 and one-lung ventilation. *Anesth Analg* 2020;131:e90–1.
- 13 Iwata S, Yokokawa S, Sato M, et al. Anesthetic management of a patient with a continuous-flow left ventricular assist device for video-assisted thoracoscopic surgery: A case report. *BMC Anesthesiol* 2020;20:18.
- 14 Dandel M, Krabatsch T, Falk V. Left ventricular vs. biventricular mechanical support: Decision making and strategies for avoidance of right heart failure after left ventricular assist device implantation. *Int J Cardiol* 2015;198:241–50.
- 15 Slininger KA, Haddadin AS, Mangi AA. Perioperative management of patients with left ventricular assist devices undergoing noncardiac surgery. *J Cardiothorac Vasc Anesth* 2013;27:752–9.
- 16 Feldman D, Pamboukian SV, Teuteberg JJ, et al. The 2013 International Society for Heart and Lung Transplantation guidelines for mechanical circulatory support: Executive summary. *J Heart Lung Transplant* 2013;32:157–87.