

Intraductal papillary mucinous neoplasm to pancreas ductal adenocarcinoma sequence and pancreas cancer screening

James J. Farrell

Department of Digestive Diseases, Yale Center for Pancreatic Diseases, Yale School of Medicine, New Haven, Connecticut, USA

INTRODUCTION

Worldwide, there are about 330,000 cases of pancreatic cancer annually, and by 2030, it is estimated to be the second most common cause of cancer-related death in the United States.^[1] The American Cancer Society has reported the 5-year survival proportion for pancreatic ductal adenocarcinoma (PDAC) to be only 8%.^[1] The only potentially curative option for PDAC is surgical resection, which on average improves 5-year survival to 27%.^[2] Most of the pancreatic lesions present in late stages after cancer has spread including regional spread (29%) and distant metastasis (52%).^[1] A study of the clonal relationship between primary tumor and metastasis estimates the evolution of fully transformed precursor lesions into infiltrating carcinoma over 11.7 years and metastasis over an additional 6.8 years, perhaps offering a substantial potential window of opportunity to detect early PDAC lesions including precursor lesions.^[3]

This article will focus on what is known about the precursor lesions of pancreatic malignancy as well as the intraductal papillary mucinous neoplasm (IPMN) and pancreatic intraepithelial neoplasms (PanIN) sequence to pancreatic cancer. In addition, it will briefly

discuss how this knowledge impacts current pancreas cancer screening strategies especially for high-risk individuals (HRIs).

PRECURSOR LESIONS OF PANCREATIC MALIGNANCY

The current working model of pancreatic malignancy pathogenesis includes several precursor lesions with at least two distinct pathways to cancer [Figure 1].^[4,5] The screening and surveillance strategies among HRIs are targeted to identify the precursor lesions and PDAC at early and potentially resectable stages.^[6]

Pancreatic intraepithelial neoplasms

PanINs are microscopic flat or papillary lesions, comprising cuboidal or columnar cells that originate from pancreatic ducts, and are felt to be the major precursor of PDAC.^[7] Low-grade lesions have a different immunohistochemical and genetic profile in comparison with high-grade or late lesions. Although low-grade PanIN lesions are very common in the general population, the evidence supporting the importance of PanIN lesions as precursors to PDAC come from both molecular analysis and the high rate

This is an open access journal, and articles are distributed under the terms of the Creative Commons Attribution-NonCommercial-ShareAlike 4.0 License, which allows others to remix, tweak, and build upon the work non-commercially, as long as appropriate credit is given and the new creations are licensed under the identical terms.

How to cite this article: Farrell JJ. Intraductal papillary mucinous neoplasm to pancreas ductal adenocarcinoma sequence and pancreas cancer screening. *Endosc Ultrasound* 2018;7:314-8.

Access this article online	
Quick Response Code: 	Website: www.eusjournal.com
	DOI: 10.4103/eus.eus_49_18

Address for correspondence

Dr. James J. Farrell, Department of Digestive Diseases, Yale Center for Pancreatic Diseases, Yale School of Medicine, LMP 1080, 15 York Street, New Haven, Connecticut 06510-3221, USA. E-mail: james.j.farrell@yale.edu

Received: 2018-06-28; **Accepted:** 2018-07-27; **Published online:** 2018-10-15

of high-grade PanIN lesions seen with patients with established PDAC. Although they are potential targets of screening and intervention, progress in this area is limited by the accurate detection of PanINs.

Intraductal papillary mucinous neoplasms

IPMNs are mucin-producing epithelial neoplasms that originate from the main pancreatic duct (main duct [MD] IPMN), its contributing branches (branch duct [BD] IPMN) or possibly mixed origins (mixed duct IPMN). Microscopically, IPMN cells have papillary projections and lack of ovarian-like stroma. Between 21% and 40% of BD-IPMN cases are multifocal. Based on the predominance cell type, IPMNs have also been classified into gastric type, intestinal type, and pancreaticobiliary type, which may have prognostic significance. For example, typically gastric type IPMN is more commonly seen with BD-IPMN and can develop into a tubular type of invasive cancer similar in histology to conventional PDAC. Alternatively, the intestinal type IPMN is more commonly seen in MD-IPMN and resulting in a colloid variety of invasive IPMN.

Although histologically it may be difficult to differentiate them, IPMN-related cancer is considered a distinct process from regular PDAC based on the molecular analysis (*e.g.*, presence of GNAS mutation). For example, overall, IPMN cancer has a better prognosis than PDAC, which is especially true for both oncocytic and colloid variants of IPMN cancer (compared with tubular variants of IPMN cancer).^[8] Although this difference appears to be lost, when IPMN cancer spreads to involves lymph nodes (compared with PDAC with lymph node involvement). The issue of malignant risk with IPMN is further compounded by its association with concomitant PDAC remote from the IPMN. This has been reported to occur in up to 8% of patients with IPMN and needs to be considered in pancreatic cancer screening protocols.

MD-IPMNs have higher predisposition for malignant transformation, compared with BD-IPMNs, as demonstrated in a longitudinal study; wherein, the 5-year actuarial risk of progression to high-grade dysplasia among MD-IPMNs was of 63% in contrast to 15% in the BD-IPMNs.^[9] Hence, if accurately preoperatively diagnosed, MD-IPMN is considered a surgical disease requiring resection due to the high risk of invasive malignancy. For patients with

presumed BD-IPMN, where the risk of malignancy is significantly lower, a variety of guidelines have evolved to help decide which patients should have surgery and which patients' cancer be safely surveyed. According to the most recent revised Fukuoka guidelines and the European consensus guidelines, high-risk or absolute features favoring surgical management includes cysts accompanying obstructive jaundice, those with enhancing mural nodules >5 mm or in the main pancreatic duct and >10 mm in dimension^[10] whereas worrisome or relative features favoring further investigation with EUS include cysts >3 cm, enhancing mural nodules <5 mm, thickened/enhancing cyst walls, main duct size 5–9 mm, abrupt change in caliber of pancreatic duct with distal pancreatic atrophy, lymphadenopathy, increased serum level of CA19–9, and cyst growth rate >5 mm/2 years or >10 mm during the follow-up.^[11,12]

Mucinous cystic neoplasms

MCNs are uncommon mucin-producing cystic neoplasms characteristically defined by ovarian-like stroma.^[13] These lesions are more likely to be found among middle-aged women (>90%). MCNs are solitary lesions, mostly occurring in the body and tail of the pancreas. They lack communications with pancreatic ducts, are morphologically distinct from other precursor lesions and do not recur postresection. For patients with presumed MCNs up to 4 cm without masses or nodules, surveillance imaging has been recommended. However, they are often managed by surgical resection, given the young age of onset, the body/tail location, and the almost 100% of 5-year survival postresection (in the absence of cancer).^[14]

PRECURSOR LESION (INTRADUCTAL PAPILLARY MUCINOUS NEOPLASM, PANCREATIC INTRAEPITHELIAL NEOPLASM) TO INVASIVE PANCREATIC CANCER MODEL

The current model suggests that most pancreatic malignancy arises from two “distinct” pathways, both with a common initiating KRAS mutation [Figure 1].^[5] The PanIN progression pathway development of high-grade lesions and subsequently invasive cancer is associated with a p16, followed by a p53/SMAD4 mutation. The IPMN progression pathway is somewhat similar except for an additional GNAS mutation early on, as well as an RNF43 mutation during

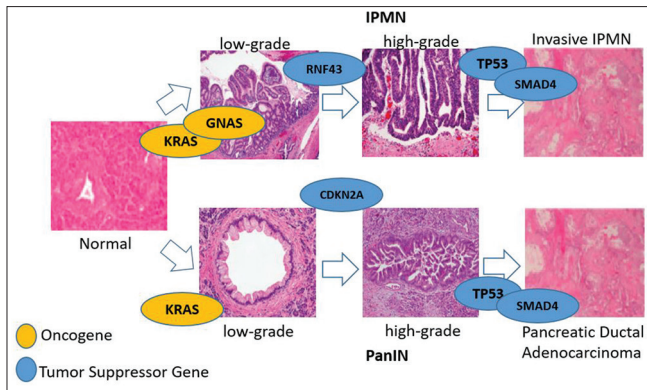


Figure 1. Pathways to pancreatic malignancy. Pancreatic malignancy may arise from either the progression of intraductal papillary mucinous neoplasm (top) or pancreatic intraepithelial neoplasm (bottom). Intraductal papillary mucinous neoplasm, intraductal papillary mucinous neoplasm, pancreatic intraepithelial neoplasm, and pancreatic intraepithelial neoplasia. (Adapted from Patra *et al.*, *Clinical and Translational Gastroenterology* (2017); 8 (4): E86, with permission)

progression of low-grade IPMN to high-grade IPMN. Although a variety of data suggests two very distinct pathogenesis pathways (*e.g.*, differing cell of origin, distinct epigenetic events, and distinct cofactor in mouse models of pancreatic cancer), there is also evidence supporting common overlap between both pathways such as RNF43 mutations occur in the PanIN pathway pushing toward an IPMN phenotype. In addition, the tubular form of IPMN cancer is very similar to PDAC both clinically and histologically. The overall risk of an IPMN developing cancer is very low at about 6% (more likely related to the very large number of IPMNs prevalent in the population). Recent data support the ideas of IPMNs being related to their co-occurring invasive PDAC cancers especially for colloid cancers.^[15]

Additional information about factors driving progression through this model continues to evolve including the roles of epigenetics (*e.g.*, methylation) and microRNAs. Although clonal lineage data analysis suggests that it may take up to 11 years for invasive pancreatic malignancy to develop from the initial KRAS mutation, data from pancreatic cyst surveillance literature suggest that most cysts remain stable overtime with only a minority progression to more advanced pathologies.

IMPLICATIONS OF CURRENT MODEL FOR PANCREATIC CANCER SCREENING

Screening population

Our knowledge of the precursor to pancreas cancer sequence has implications for not only who we screen but also how we screen. Despite its aggressive nature

and high degree of lethality, screening for PDAC is not standard practice among the general population because of its low incidence (individual lifetime risk about 1.5%) and absence of reliable, noninvasive screening tools.^[16] Population screening tests of such low lifetime risk disease requires both very high sensitivity and specificity to avoid large numbers of false positives for each true positive found by the test.^[17] Hence, current screening strategies have largely focused on groups of individuals thought to be at increased risk of pancreatic cancer compared with the general population.

Although 90% of pancreatic cancers are sporadic; however, in some individuals, it can be attributed to familial aggregation or high-risk genetic syndromes. Such familial or genetic predisposition confers an elevated lifetime risk, generally at least five-fold relative risk of PDAC, and these individuals are classified as HRI (high risk individuals). A number of genetic syndromes have been associated with increased risk of PDAC, including hereditary pancreatitis, Peutz–Jeghers syndrome (STK11/LKB1), familial atypical multiple mole melanoma (p16 mutations), hereditary breast-ovarian cancer syndrome (germline mutations in BRCA1, BRCA2, PALB2 and ATM,) and Lynch syndrome (hereditary nonpolyposis colorectal cancer). Familial pancreatic cancer which is defined as families with two or more first-degree relatives (FDR) with PDAC, and where the family does not fulfill criteria for other known genetic syndromes, carries a very high risk of pancreatic malignancy (*e.g.*, risk ratio of 32-fold for an individual with 3 FDRs [lifetime risk, 40%]).^[18,19]

When to start screening?

Screening for pancreatic malignancy typically begins at the age of 50 or at least 10 years younger than the youngest member of the family kindred.^[20] However, most programs have initiated screening at the age of 40 years, or 10 years before the youngest age of onset for *PRSS1* mutation carriers with hereditary pancreatitis,^[21] and at age 30 years among patients with PJ syndrome, given the younger ages of onset in these high-risk subsets.

How to screen?

Whereas most solid pancreatic mass, such as early PDAC, may be detected with either computed tomography (CT), magnetic resonance imaging (MRI), or EUS, data support the use of either MRI or EUS for the diagnosis of small pancreatic cysts, which could be either IPMNs or when very small, focal

PanIN lesions.^[22,23] There are no specific fluid-based or imaging (*e.g.*, CT, MRI, or EUS)-based strategies to either identify PanINs or differentiate low-grade from high-grade PanINs or invasive PDAC. PanINs may be associated with focal lobular centric atrophy of the pancreatic parenchyma, which may sometime be appreciated at EUS imaging as “chronic pancreatitis like changes,” a pancreatic ductal stricture on ERCP, or even possibly small subcentimeter pancreatic cysts seen on imaging of patients at increased risk of pancreatic malignancy.^[23,24]

Biomarkers for screening

To date, the only clinically established biomarker for PDAC is carbohydrate (or cancer) antigen 19–9 (CA 19–9), which is not only expressed by some PDACs but also by inflamed pancreas tissue.^[25] Hence, on its own, it is inadequate to detect precursor lesions or early malignancy among normal individuals or in the general population. Early data suggest a possible role for blood-based circulating DNA and tumor cells in the diagnosis of pancreatic cancer and precursor lesions in high-risk pancreatic cancer screenings. A study combining cell-free DNA mutations and circulating proteins for the detection of early pancreatic cancer has shown a sensitivity of 69%–98% and specificity of >99% in PDAC diagnosis.^[26] Circulating tumor cells have also been identified in the blood of patients with pancreatic IPMN.^[27] Again, there are currently no blood-based markers for accurately identifying PanIN lesions and differentiating early PanIN from late PanIN lesions.

The role of pancreatic cyst fluid biomarkers in determining precursor cystic lesions of the pancreas is well established. Initial studies of cyst fluid carcinoembryonic antigen levels to differentiate between mucinous and nonmucinous cystic lesions have now been complemented by cyst fluid DNA mutations (*e.g.*, KRAS and GNAS), loss of heterozygosity at CDKN2A, RNF43, SMAD4, TP53, and VHL and evolving epigenetic-based biomarkers which have the potential to further discriminate between mucinous and nonmucinous lesions as well as high-grade and invasive mucinous lesions from low-grade lesions.^[28] The accuracy of these studies for identifying PDAC precursor lesions is uncertain in high-risk screening populations.

Analyzing pancreatic juice collected from the duodenum is another approach for screening otherwise asymptomatic patients considered to be at

high risk of developing pancreatic cancer, albeit with the limitation of inadequate disease localization for a positive study. Higher pancreatic juice TP53 mutation frequencies has been found in advanced lesions, including PanIN-3s and IPMNs with high-grade dysplasia, with one study identifying both TP53 and SMAD4 mutations in pancreatic juice between 4 and 61 months before the development of visible pancreatic malignancy.^[29,30]

Surveillance intervals and outcomes

Based on our current knowledge of the precursor and cancer sequence, the success of a pancreas cancer screening program is based on identification and surgical resection of early resectable invasive PDAC, and advanced precursor lesions such as PanIN3 and advanced IPMNs. For patients who are undergoing surveillance, interval evaluation has been suggested at 1 year based on our knowledge of precursor lesions, surveillance patterns in sporadic cystic lesions, and anecdotal cases of cancers missed on surveillance.^[24] The patient risk factors, screening modalities, and outcome measures of various screening studies have been reported, with data suggesting possible higher rates of curative resection (60% *vs.* 25%, $P = 0.011$) and prolonged survival (14.5 months *vs.* 4 months, $P < 0.001$) in screening cohorts.^[31,32]

CONCLUSION

An understanding of the precursor lesions associated with pancreatic malignancy as well as the sequence from precursor lesion to invasive cancer provides a basis for a rational approach to pancreas cancer screening especially in HRIs. The future challenges include noninvasive and invasive identification of PanIN lesions as well as expanding screening populations to include new-onset diabetes and even the general population.

Conflicts of interest

There are no conflicts of interest.

REFERENCES

1. Siegel RL, Miller KD, Jemal A. Cancer statistics, 2018. *CA Cancer J Clin* 2018;68:7-30.
2. Katz MH, Wang H, Fleming JB, *et al.* Long-term survival after multidisciplinary management of resected pancreatic adenocarcinoma. *Ann Surg Oncol* 2009;16:836-47.
3. Yachida S, Jones S, Bozic I, *et al.* Distant metastasis occurs late during the genetic evolution of pancreatic cancer. *Nature* 2010;467:1114-7.
4. Brat DJ, Lillemo KD, Yeo CJ, *et al.* Progression of pancreatic intraductal neoplasias to infiltrating adenocarcinoma of the pancreas. *Am J Surg*

- Pathol* 1998;22:163-9.
5. Patra KC, Bardeesy N, Mizukami Y. Diversity of precursor lesions for pancreatic cancer: The genetics and biology of intraductal papillary mucinous neoplasm. *Clin Transl Gastroenterol* 2017;8:e86.
 6. Berman JJ, Albores-Saavedra J, Bostwick D, et al. Precancer: A conceptual working definition – Results of a consensus conference. *Cancer Detect Prev* 2006;30:387-94.
 7. Hruban RH, Takaori K, Klimstra DS, et al. An illustrated consensus on the classification of pancreatic intraepithelial neoplasia and intraductal papillary mucinous neoplasms. *Am J Surg Pathol* 2004;28:977-87.
 8. Wasif N, Bentrem DJ, Farrell JJ, et al. Invasive intraductal papillary mucinous neoplasm vs. sporadic pancreatic adenocarcinoma: A stage-matched comparison of outcomes. *Cancer* 2010;116:3369-77.
 9. Lévy P, Jouannaud V, O'Toole D, et al. Natural history of intraductal papillary mucinous tumors of the pancreas: Actuarial risk of malignancy. *Clin Gastroenterol Hepatol* 2006;4:460-8.
 10. Kim TH, Song TJ, Hwang JH, et al. Predictors of malignancy in pure branch duct type intraductal papillary mucinous neoplasm of the pancreas: A nationwide multicenter study. *Pancreatol* 2015;15:405-10.
 11. Kang MJ, Jang JY, Kim SJ, et al. Cyst growth rate predicts malignancy in patients with branch duct intraductal papillary mucinous neoplasms. *Clin Gastroenterol Hepatol* 2011;9:87-93.
 12. Kwong WT, Lawson RD, Hunt G, et al. Rapid growth rates of suspected pancreatic cyst branch duct intraductal papillary mucinous neoplasms predict malignancy. *Dig Dis Sci* 2015;60:2800-6.
 13. Valsangkar NP, Morales-Oyarvide V, Thayer SP, et al. 851 resected cystic tumors of the pancreas: A 33-year experience at the massachusetts general hospital. *Surgery* 2012;152:S4-12.
 14. Yamao K, Yanagisawa A, Takahashi K, et al. Clinicopathological features and prognosis of mucinous cystic neoplasm with ovarian-type stroma: A multi-institutional study of the Japan pancreas society. *Pancreas* 2011;40:67-71.
 15. Felsenstein M, Noë M, Masica DL, et al. IPMNs with co-occurring invasive cancers: Neighbours but not always relatives. *Gut* 2018;67:1652-62.
 16. National Cancer Institute. Probability of Cancer - Surveillance Research Program. Available from: <https://surveillance.cancer.gov/devcan/canques.html>. [Last accessed on 2018 May 31].
 17. Wentzensen N, Wacholder S. From differences in means between cases and controls to risk stratification: A business plan for biomarker development. *Cancer Discov* 2013;3:148-57.
 18. Grover S, Syngal S. Hereditary pancreatic cancer. *Gastroenterology* 2010;139:1076-80, 1080.e1-2.
 19. Brand RE, Lerch MM, Rubinstein WS, et al. Advances in counselling and surveillance of patients at risk for pancreatic cancer. *Gut* 2007;56:1460-9.
 20. Canto MI, Harinck F, Hruban RH, et al. International cancer of the pancreas screening (CAPS) consortium summit on the management of patients with increased risk for familial pancreatic cancer. *Gut* 2013;62:339-47.
 21. Ulrich CD; Consensus Committees of the European Registry of Hereditary Pancreatic Diseases, Midwest Multi-Center Pancreatic Study Group, International Association of Pancreatology. Pancreatic cancer in hereditary pancreatitis: Consensus guidelines for prevention, screening and treatment. *Pancreatol* 2001;1:416-22.
 22. Harinck F, Konings IC, Kluijft I, et al. A multicentre comparative prospective blinded analysis of EUS and MRI for screening of pancreatic cancer in high-risk individuals. *Gut* 2016;65:1505-13.
 23. Canto MI, Almario JA, Schulick RD, et al. Risk of neoplastic progression in individuals at high risk for pancreatic cancer undergoing long-term surveillance. *Gastroenterology* 2018. pii: S0016-5085(18)34568-2.
 24. Canto MI, Hruban RH, Fishman EK, et al. Frequent detection of pancreatic lesions in asymptomatic high-risk individuals. *Gastroenterology* 2012;142:796-804.
 25. Goggins M. Molecular markers of early pancreatic cancer. *J Clin Oncol* 2005;23:4524-31.
 26. Cohen JD, Li L, Wang Y, et al. Detection and localization of surgically resectable cancers with a multi-analyte blood test. *Science* 2018;359:926-30.
 27. Rhim AD, Thege FI, Santana SM, et al. Detection of circulating pancreas epithelial cells in patients with pancreatic cystic lesions. *Gastroenterology* 2014;146:647-51.
 28. Springer S, Wang Y, Dal Molin M, et al. A combination of molecular markers and clinical features improve the classification of pancreatic cysts. *Gastroenterology* 2015;149:1501-10.
 29. Eshleman JR, Norris AL, Sadakari Y, et al. KRAS and guanine nucleotide-binding protein mutations in pancreatic juice collected from the duodenum of patients at high risk for neoplasia undergoing EUS. *Clin Gastroenterol Hepatol* 2015;13:963-9.e4.
 30. Yu J, Sadakari Y, Shindo K, et al. Digital next-generation sequencing identifies low-abundance mutations in pancreatic juice samples collected from the duodenum of patients with pancreatic cancer and intraductal papillary mucinous neoplasms. *Gut* 2017;66:1677-87.
 31. Corral JE, Mareth KF, Riegert-Johnson DL, et al. Diagnostic yield from screening asymptomatic individuals at high risk for pancreatic cancer: A meta-analysis of cohort studies. *Clin Gastroenterol Hepatol* 2018. pii: S1542-3565(18)30498-1.
 32. Lu C, Xu CF, Wan XY, et al. Screening for pancreatic cancer in familial high-risk individuals: A systematic review. *World J Gastroenterol* 2015;21:8678-86.