

Cytomegalovirus pneumonia in a background of central nervous system tuberculosis

Sugeesha Wickramasinghe¹ | Menaka Tillekeratne¹ | Sasanka Wijayawardhana¹ |
Aflah Sadikeen¹ | Dilshan Priyankara² | Manoj Edirisooriya² | Amitha Fernando¹

¹Department of Respiratory Medicine, Central Chest Clinic, Borella, Sri Lanka

²Department of Critical Care, National Hospital of Sri Lanka, Borella, Sri Lanka

Correspondence

Sugeesha Wickramasinghe, 19/26, Siri Nikethanarama Road, Mahara, Kadawatha, Sri Lanka.
Email: sugeesha@gmail.com

Associate Editor: Michael Maze

Abstract

A 32-year-old patient, who was on treatment for tuberculous meningitis complicated with venous sinus thrombosis, was referred to the medical unit as he developed new onset fever, cough and shortness of breath. He was in respiratory distress and needed intubation. Investigations revealed elevated liver enzymes, leukopenia, spherocytosis and lower lobe predominant consolidations and diffuse nodules in the high-resolution computed tomography. He was suspected to have cytomegalovirus (CMV) pneumonia with the above results, and further investigations revealed an extremely elevated CMV viral load. He was treated with ganciclovir followed by valganciclovir for a total of 42 days resulting in a complete recovery. Liver functions resolved with anti-viral treatment, and he was started on full anti-tuberculosis (TB) treatment. Further investigations did not reveal evidence of immunosuppression. Association of CMV and TB is explained genetically, although clinical association is rarely described. The presence of either infection should lead to higher degree of suspicion of the respective other condition in relevant clinical setting.

KEYWORDS

cytomegalovirus, immunocompetent, pneumonia, spherocytes, TB meningitis

INTRODUCTION

Cytomegalovirus (CMV), belonging to the Herpesviridae family, is transmitted mostly by contact with infectious saliva, urine and genital or by trans-placental route. Its prevalence ranges between 50% and 85%, with epidemiological differences among different age and socio-economic grounds. Even though there are numerous case reports describing CMV infection in immunocompromised patients, the clinical course of complicated CMV pneumonia in immunocompetent patients is rarely described.

CASE REPORT

A 32-year-old patient was admitted to the medical unit as he developed new onset fever, cough and shortness of breath for 1 day. There was no history of haemoptysis, weight loss, arthralgia or chest pain. He did not have a past history of chronic lung conditions, recurrent infection and he was not on any immunosuppressive treatment. He denied a history of diarrhoea or risk-taking behaviour. He was recently investigated for a new onset headache 3 weeks back and was diagnosed to have tuberculosis (TB) meningitis based on positive cerebrospinal fluid TB polymerase chain reaction (PCR) and TB culture, complicated with venous sinus thrombosis. He was then started on anti-TB treatment (ATT) and warfarin. After starting ATT, he had elevated liver enzymes and routine ATT was withheld, and he was started on streptomycin, ethambutol and levofloxacin.

This case was presented at the Annual Congress of European Respiratory Society 2020—Lungs on fire in Respiratory infections.

This is an open access article under the terms of the [Creative Commons Attribution-NonCommercial-NoDerivs](https://creativecommons.org/licenses/by-nc-nd/4.0/) License, which permits use and distribution in any medium, provided the original work is properly cited, the use is non-commercial and no modifications or adaptations are made.

© 2022 The Authors. *Respirology Case Reports* published by John Wiley & Sons Australia, Ltd on behalf of The Asian Pacific Society of Respiriology.

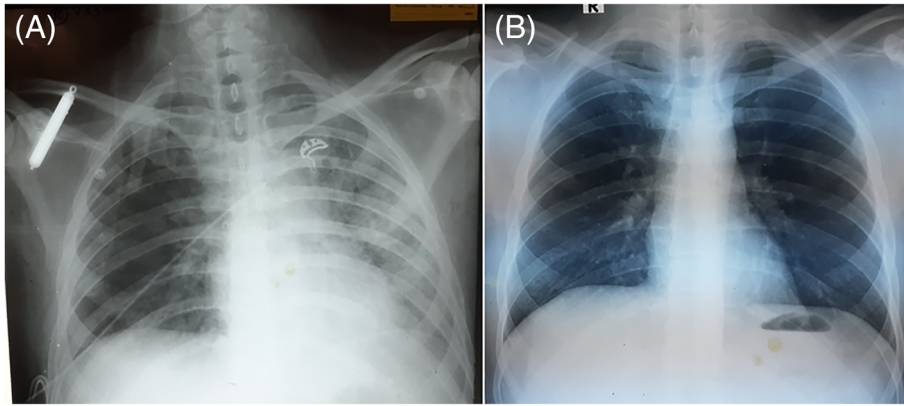


FIGURE 1 (A) Chest X-ray (CXR) done on admission showing left-sided consolidation. (B) CXR done 2 weeks later showing significant improvement.

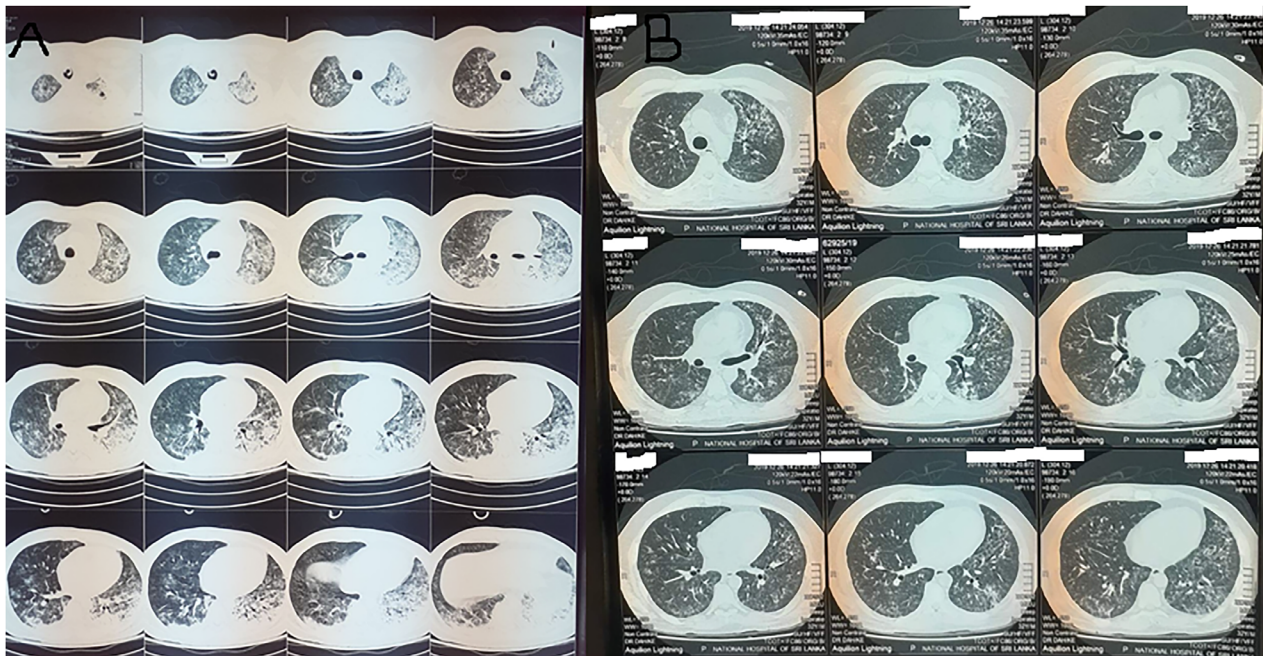


FIGURE 2 (A) High-resolution computed tomography (HRCT) showing bilateral lower lobe predominant ground-glass changes with centrilobular nodules involving the left lung more than the right. (B) HRCT chest done 2 weeks later showing partial resolution.

On examination, he was febrile, conscious (Glasgow coma scale-15) and tachycardic, without lymphadenopathy. Respiratory examination revealed a respiratory rate of 34/min with reduced chest expansion on the left hemithorax with bilateral coarse crepitation. There was no neck stiffness or focal neurology. Soon after review, he was transferred to intensive care and electively intubated as he was in respiratory distress.

Initial chest X-ray (Figure 1) showed left-sided consolidation. High-resolution computed tomography of the chest (Figure 2) revealed lower lobe predominant (L >> R) consolidation and nodules. His blood count showed leucopenia with lymphopenia (Table 1) and elevated liver enzymes (alanine aminotransferase, 214; aspartate aminotransferase, 204; total bilirubin, normal). He was suspected to have CMV pneumonia provided the CT appearance, elevated

liver enzymes and concurrent TB infection. His CMV viral load in serum was 900554.7 IU/ml. He had positive CMV IgM and negative IgG, suggesting acute infection. Once stabilized, he was subjected to bronchoscopy and a BAL was obtained and sent for acid-fast bacilli (AFB), Gene X-pert, fungal culture, pyogenic culture, AFB culture, *Pneumocystis jirovecii* PCR and galactomannan, which were negative. Further investigation with HIV (three repeated tests with 2 weeks intervals), Legionella antigen, hepatitis screening, Mycoplasma antibodies and influenza A/B PCR screening were negative. After confirmation of CMV, he was treated with IV ganciclovir 5 mg/kg bd for 10 days followed by oral valganciclovir for further 32 days. Initially, acute infection was covered with IV ceftriaxone and clarithromycin for 4 days, and this was stopped when CMV serology was available. The patient was not subjected to a lung biopsy as he was

TABLE 1 Haematological and biochemical results.

Investigation	Day 1	Day 4	Day 14
White cell count (/mm ³)	2900	2780	4030
Neutrophils (/mm ³)	2400	2390	2370
Lymphocytes (/mm ³)	500	290	1170
Haemoglobin (g/dl)	11.8	9.6	9.3
MCV (fl)	100	100	99.4
Platelets (/mm ³)	132,000	111,000	167,000
CRP (mg/dl)	203	185	43
ESR (mm/h)	112		
AST (U/L)	115	89	60
ALT (U/L)	123	84	90
Total bilirubin (mg/dl)	0.7	0.7	0.5
Albumin (g/dl)	2.7	2.7	3.4
Serum creatinine (mg/dl)	0.65		
Na (mmol/L)	135	138	140
K (mmol/L)	3.9	3.6	4.1
Ferritin (ng/dl)	1816		
Globulin (g/dl)	4.1	3.8	4.2
Blood picture	Normochromic normocytic cells with macrocytic cells. Spherocytes and polychromatic cells. Leucopenia noted with neutrophil predominance with toxic changes		

Abbreviations: ALT, alanine aminotransferase; AST, aspartate aminotransferase; CRP, C-reactive protein; ESR, erythrocyte sedimentation rate; MCV, mean corpuscular volume.

not stable. His liver functions became normal with anti-viral treatment; he was gradually started on ATT with desensitization, and there was no further liver impairment after resolution of CMV pneumonia. He made a significant recovery after treatment and was extubated on the sixth day following intubation and discharged to the ward on the 18th day. Further evaluation with CD4 count was within normal range, and he was able to produce a gamma interferon response.

DISCUSSION

CMV retinitis, conjunctivitis, oesophagitis and hepatitis are commonly described entities, although CMV pneumonitis is a rarely described entity in immunocompetent adults.¹ CMV pulmonary involvement has a spectrum of clinical presentation from dry cough to severe interstitial pneumonia, as described in our case.² Patients who have unexplained atypical lymphocytosis with elevated serum transaminases, the possibility of CMV pneumonia should be considered, including immunocompetent patients.³ In addition, low-grade haemolysis can be seen in rare circumstances. Our patient was detected to have mildly elevated liver enzymes, and this was initially attributed to ATT, which was bridged with alternative treatment. However, there was no improvement in liver enzymes noted after withdrawal of conventional ATT. In addition, he was

detected to have leucopenia, and further evaluation with a blood picture revealed spherocytosis in the blood, which is associated with CMV infection. This was the initial clue for suspicion of CMV pneumonia in our patient.

CT findings in CMV pneumonia include mixed alveolar, interstitial infiltrative opacification, bilateral diffuse symmetrically distributed nodules, lower lobe predominant confluent consolidations, tree-in-bud appearances and bronchovascular bundle thickening.³ Our patient had lower lobe predominant consolidation and bilateral diffuse nodules, which were supportive of the diagnosis. CT findings, hepatitis and leucopenia (with lymphopenia) with spherocytosis in the blood picture were highly suggestive of CMV infection, and the viral load of $>9 \times 10^9$ IU/ml was confirmatory of the diagnosis and the level significantly improved with treatment.^{4,5}

There is ample evidence in the literature to diagnose CMV infection based on viral load, although viral cultures and viral invasion in histology are more conclusive.⁶⁻¹² However, this is not feasible in most circumstances as viral cultures are difficult to perform, and patients are not stable enough to be subjected to a biopsy as in our case. Strong association between TB and CMV infection has been described (4,5). Immune activation after CMV infection is associated with increased risk of TB disease in infants.¹³⁻¹⁵

Primary drugs used for the treatment involve ganciclovir and valganciclovir, and they should be continued for a total of 42 days for a better outcome. However, these drugs are toxic and associated with severe complications, such as bone marrow suppression, renal impairment, infertility and teratogenicity, which need careful monitoring and were challenging in our case as our patient was young and unmarried with a life-threatening pneumonia.¹⁶

AUTHOR CONTRIBUTION

Sugeesha Wickramasinghe, Menaka Tillekeratne and Sasanka Wijayawardhana were involved in writing up the case. Aflah Sadikeen and Amitha Fernando were involved in advising on the intellectual content of the article. Manoj Edirisooriya and Dilshan Priyankara were involved in intensive care management and review of the work and final improvement of the article.

ACKNOWLEDGMENT

We would like to thank Dr. Bimsara Senanayake (Consultant Neurologist), who has managed this patient's neurological condition.

CONFLICT OF INTEREST

None declared.

DATA AVAILABILITY STATEMENT

No data are available as this is a case report.

ETHICS STATEMENT

The authors declare that appropriate written informed consent was obtained for the publication of this manuscript and accompanying images.

ORCID

Sugeesha Wickramasinghe  <https://orcid.org/0000-0001-6372-3263>

REFERENCES

1. Staras SA, Dollard SC, Radford KW, Flanders WD, Pass RF, Cannon MJ. Seroprevalence of cytomegalovirus infection in the United States, 1988-1994. *Clin Infect Dis*. 2006;43:1143-51.
2. Ross SA, Novak Z, Pati S, Boppana SB. Diagnosis of cytomegalovirus infections. *Infect Disord Drug Targets*. 2011;11:466-74.
3. Gonçalves C, Cipriano A, Santos FV, Abreu M, Méndez J, Sarmiento e Castro R. Cytomegalovirus acute infection with pulmonary involvement in an immunocompetent patient. *IDCases*. 2018;14:e00445.
4. Whittaker E, López-Varela E, Broderick C, Seddon JA. Examining the complex relationship between tuberculosis and other infectious diseases in children. *Front Pediatr*. 2019;7:1-23.
5. Muller J, Matsumiya M, Snowden MA, Landry B, Satti I, Harris SA, et al. Cytomegalovirus infection is a risk factor for tuberculosis disease in infants. *JCI Insight*. 2019;4(23):e130090.
6. Razonable RR, Hayden RR. Clinical utility of viral load in management of cytomegalovirus infection after solid organ transplantation. *Clin Microbiol Rev*. 2013;26:703-27.
7. Eguchi H, Horita N, Ushio R, Kato I, Nakajima Y, Ota E, et al. Diagnostic test accuracy of antigenaemia assay for PCR-proven cytomegalovirus infection-systematic review and meta-analysis. *Clin Microbiol Infect*. 2017;23:907-15.
8. Kotton CN, Kumar D, Caliendo AM, Hupriker S, Chou S, Danziger-Isakov L, et al. The third international consensus guidelines on the management of cytomegalovirus in solid-organ transplantation. *Transplantation*. 2018;102:900.
9. Aitken C, Barrett-Muir W, Millar C, Templeton K, Thomas J, Sheridan F, et al. Use of molecular assays in diagnosis and monitoring of cytomegalovirus disease following renal transplantation. *J Clin Microbiol*. 1999;37:2804-7.
10. Humar A, Gregson D, Caliendo AM, McGeer A, Malkan G, Krajden M, et al. Clinical utility of quantitative cytomegalovirus viral load determination for predicting cytomegalovirus disease in liver transplant recipients. *Transplantation*. 1999;68:1305-11.
11. Sia IG, Wilson JA, Espy MJ, Paya CV, Smith TF. Evaluation of the COBAS AMPLICOR CMV MONITOR test for detection of viral DNA in specimens taken from patients after liver transplantation. *J Clin Microbiol*. 2000;38:600-6.
12. Sia IG, Wilson JA, Groettum CM, Espy MJ, Smith TF, Paya CV. Cytomegalovirus (CMV) DNA load predicts relapsing CMV infection after solid organ transplantation. *J Infect Dis*. 2000;181:717-20.
13. Fodil-Cornu N, Vidal SM. Type I interferon response to cytomegalovirus infection: the kick-start. *Cell Host Microbe*. 2008;3:59-61.
14. O'garra A, Redford PS, McNab FW, Bloom CI, Wilkinson RJ, Berry MPR. The immune response in tuberculosis. *Annu Rev Immunol*. 2013;31:475-527.
15. Cobelens F, Nagelkerke N, Fletcher H. The convergent epidemiology of tuberculosis and human cytomegalovirus infection. *F1000Res*. 2018;7:280.
16. Available from: <https://bnf.nice.org.uk/drugs/ganciclovir>

How to cite this article: Wickramasinghe S, Tillekeratne M, Wijayawardhana S, Sadikkeen A, Priyankara D, Edirisooriya M, et al. Cytomegalovirus pneumonia in a background of central nervous system tuberculosis. *Respirology Case Reports*. 2022; 10:e01002. <https://doi.org/10.1002/rcr2.1002>