

Fatal myopericarditis complicated with coronary vein perforation under the triple antithrombotic therapy: a case report

Akihiro Takasaki ^{1,2}, Ryuji Okamoto ^{1*}, Hiroko Sugimoto³, and Kaoru Dohi ¹

¹Department of Cardiology and Nephrology, Mie University Graduate School of Medicine, 2-174 Edobashi, Tsu, Mie 514-8507, Japan; ²Department of Cardiology, Matsusaka Central Hospital, Kobo 102, Kawai-machi, Matsusaka, Mie 515-8566, Japan; and ³Department of Pathology, Matsusaka Central Hospital, Kobo 102, Kawai-machi, Matsusaka, Mie 515-8566, Japan

Received 8 November 2020; first decision 25 November 2020; accepted 26 February 2021

Background

Acute pericarditis generally follows a mild clinical course and is rarely fatal. Coronary vein involvement is rarely reported.

Case summary

We report an autopsy case of cardiac tamponade from idiopathic myopericarditis due to coronary venous perforation under the triple antithrombotic therapy. A 69-year-old man was admitted to our hospital with abnormal findings on electrocardiography, bloody pericardial effusion, and mild elevation of troponin I. Oral anti-inflammatories were started and the patient followed a benign course. However, on hospital Day 5, he suddenly suffered cardiogenic shock with pulseless electric activity due to cardiac tamponade under the combination use of the dual antiplatelet drugs and an anticoagulant drug. He died despite intense medical treatment. Autopsy revealed cardiac tamponade caused by perforation in the coronary venous wall. To the best of our knowledge, this is the first description of fatal myopericarditis as a complication of coronary venous perforation.

Discussion

The aetiology and mechanism remain unknown; however, we should take care for this rare complication in patients with acute myopericarditis and bloody effusion under the triple antithrombotic therapy.

Keywords

Case report • Pericardial disease • Coronary vein • Triple antithrombotic therapy

Learning points

- Coronary vein perforation is a rare complication of myopericarditis whilst on antithrombotic therapy, presenting as a haemorrhagic pericardial effusion.

Introduction

Acute pericarditis generally follows a mild clinical course and is rarely fatal.¹ Herein, a severe case of acute myopericarditis is reported presenting with blood pericardial effusion leading to uncontrollable

cardiac dysfunction and death. Autopsy revealed perforation of the coronary vein due to acute inflammation. Although the underlying mechanisms remain unclear, this appears to represent the first description of fatal myopericarditis complicated by coronary vein perforation.

* Corresponding author. Tel: +81-59-231-5015, Fax: +81-59-231-5201, Email: ryuji@clin.medic.mie-u.ac.jp

Handling Editor: Diego Araiza-Garayordobil

Peer-reviewers: Edoardo Conte and Edin Begic

Compliance Editor: Daniel Tardo

Supplementary Material Editor: Ross Thomson

© The Author(s) 2021. Published by Oxford University Press on behalf of the European Society of Cardiology.

This is an Open Access article distributed under the terms of the Creative Commons Attribution Non-Commercial License (<http://creativecommons.org/licenses/by-nc/4.0/>), which permits non-commercial re-use, distribution, and reproduction in any medium, provided the original work is properly cited. For commercial re-use, please contact journals.permissions@oup.com

Timeline

	<p>Past history of percutaneous coronary intervention for angina pectoris, surgical resection of rectal cancer, and lung metastatic cancer</p> <p>Medications included low-dose aspirin, cilostazol, valsartan, and cilnidipine</p>
Two weeks before admission	Anterior chest discomfort+
One week before admission	Asymptomatic, normal electrocardiography (ECG)
On admission	<p>Asymptomatic, pericardial friction rub +, ST-elevation in almost all leads in ECG</p> <p>C-reactive protein and troponin I were increased, at 2.97 mg/dL and 1995 pg/mL</p> <p>Mild pericardial effusion with attenuation indicating blood constituent</p> <p>Treatment including aspirin (750 mg every 8 h) and colchicine (0.5 mg/day)</p>
Three days after admission	<p>Paroxysmal atrial fibrillation+</p> <p>Treatment including rivaroxaban (15 mg/day): triple antithrombotic therapy+</p>
Five days after admission	<p>C-reactive protein and troponin I were reduced, at 0.44 mg/dL and 1718 pg/mL</p> <p>The unchanged volume of pericardial effusion</p> <p>He abruptly complained of severe chest discomfort and cardiogenic shock developed due to cardiac tamponade</p> <p>Urgent first and last pericardiocentesis was performed and confirmed haemorrhagic effusion</p> <p>He died after bloody drainage and cardiac dysfunction were continued</p>
Autopsy	<p>The oozing site led to the coronary sinus, perforation of the coronary vein</p> <p>Chronic changes including mild fibrosis in pericardial and myocardial tissues around the perforated site</p>

Case presentation

A 69-year-old man presented to our outpatient department complaining of anterior chest discomfort, which had intermittently continued for a week. Because the symptom was improving and blood testing and electrocardiography (ECG) showed no abnormalities, he returned home, and visited a doctor again 1 week later. He had a history of successful percutaneous coronary stenting for angina pectoris (10 years ago), surgical resection of rectal cancer (6 years ago), and lung metastatic cancer (5 years ago). Medications included low-dose aspirin (100 mg/day), cilostazol (200 mg/day), valsartan (80 mg/day), and cilnidipine (10 mg/day). He visited our outpatient department without any symptoms during the preceding week. However, auscultation revealed pericardial friction rub and ECG showed ST-elevation in I, II, III, aVF, and V2 to V6 leads (Figure 1A). Laboratory evaluation

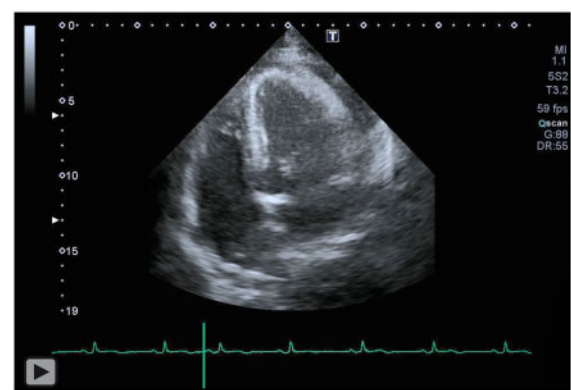
revealed elevated C-reactive protein (CRP) level of 2.97 mg/dL (normal, ≤ 0.30 mg/dL) and troponin I level of 1995 pg/mL (normal, ≤ 26.2 pg/mL). Creatine phosphokinase (CPK) was within normal limits. On admission, the patient showed no symptoms with a blood pressure of 133/84 mmHg, temperature of 35.0°C, heart rate of 68 b.p.m., respiratory rate of 15 breaths/min, and oxygen saturation of 98% in room air.

Transthoracic echocardiography showed circumferential mild pericardial effusion without any findings of cardiac tamponade including swinging heart and diastolic collapse of right atria and ventricle (Video 1). Coronary angiography revealed no significant stenosis. Computed tomography (CT) also revealed mild pericardial effusion with attenuation of ~ 60 Hounsfield units (HU), indicating blood constituent (Figure 1B). Acute pericarditis and pericardial effusion with minor injury in cardiac muscle were diagnosed. Treatment including aspirin (750 mg every 8 h) and colchicine (0.5 mg/day) was started according to pericardial disease management guidelines.² On hospital Day 3, paroxysmal atrial fibrillation (AF) lasting 20 min was recognized, although the patient was asymptomatic. A regular dose (15 mg/day) of rivaroxaban was added to his medications.

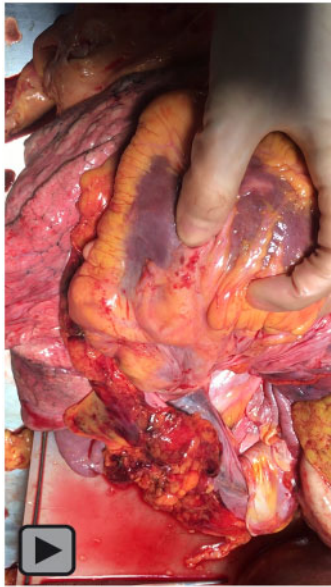
On hospital Day 5, laboratory evaluation revealed that CRP and troponin I were reduced, at 0.44 mg/dL and 1718 pg/mL, respectively. However, the volume of pericardial effusion was unchanged on echocardiography. The patient abruptly complained of severe chest discomfort and cardiogenic shock developed, accompanied by systolic blood pressure of 50–59 mmHg and a heart rate of 155 b.p.m. of AF. He suffered cardiogenic shock with pulseless electric activity due to cardiac tamponade despite synchronized cardioversion. Urgent pericardiocentesis was performed and confirmed haemorrhagic effusion. Percutaneous cardiopulmonary support was introduced immediately, and intra-aortic balloon pumping was also started, because return of spontaneous circulation was not obtained.

Bloody drainage and cardiac dysfunction were continued. Despite extensive medical treatment including blood transfusion, heart rate, and blood pressure gradually decreased without any ventricular arrhythmia and the patient finally died 12 h after onset of cardiogenic shock.

Autopsy revealed a drainage tube placed in the posterior side of the pericardial cavity and ~ 690 mL of blood retained there. Culture



Video 1 Echocardiography showed mild pericardial effusion with no findings of cardiac tamponade.



Video 2 Blood oozing was identified on manual compression.

and polymerase chain reaction yielded negative results for bacterial infection. The heart weighed 520 g and exhibited many petechiae on the fatty tissue of the inferoposterior wall. In addition, blood oozing was identified on manual compression (*Figure 1C*, *Video 2*). Because the oozing site led to the coronary sinus, perforation of the coronary vein was identified. Microscopically, the perforated site was confirmed in the coronary venous wall as expected (*Figures 1D–G*). Lymphocytic infiltration (*Figure 1H*), macrophages containing haemosiderin (*Figure 1I*) and mild fibrosis were detected in pericardial and myocardial tissues only around the perforated site. The coronary vein was considered to have been perforated a few days earlier based on the presence of fibrosis.

Discussion

The two major indicators of poor prognosis in acute pericarditis are reportedly the existence of cardiac tamponade and the failure of anti-inflammatory drugs.³ Indeed, the present case was accompanied by cardiac tamponade and failure of aspirin and colchicine treatment. It is important for us to be more careful when encountering such patients with acute pericarditis.

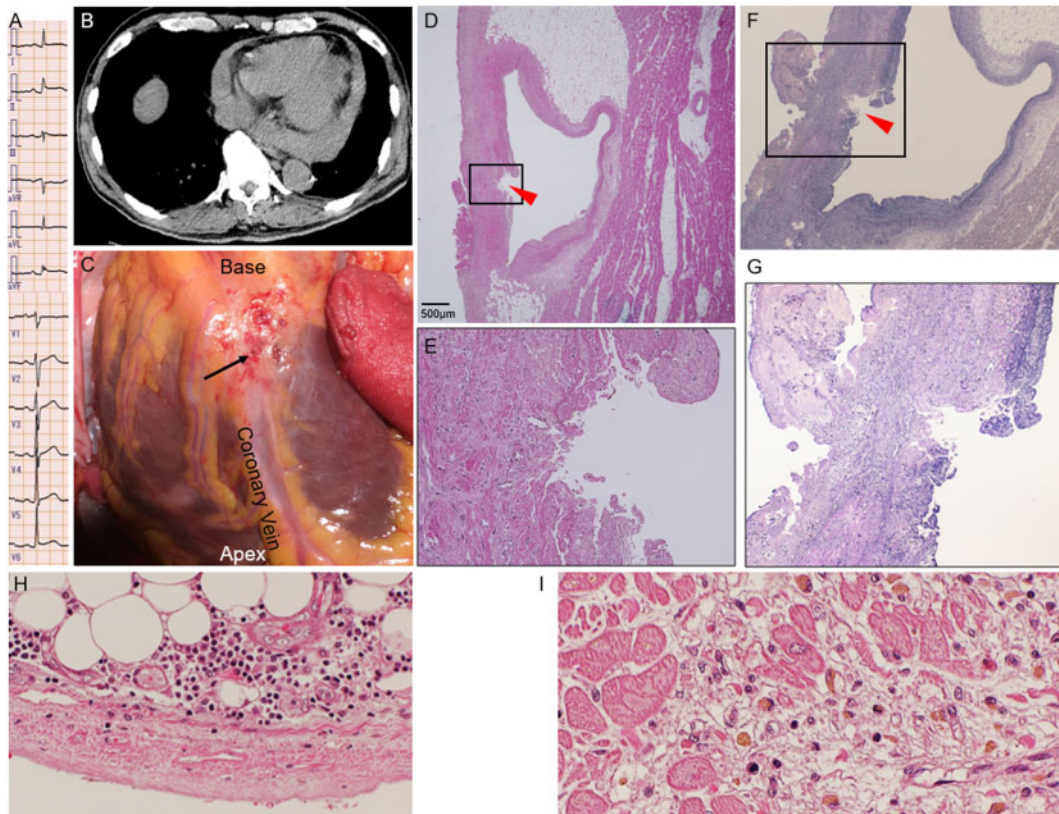


Figure 1 (A) ST-T changes on electrocardiography on admission (Day 1). (B) Chest computed tomography demonstrates mild pericardial effusion (Day 1). (C) Perforation of the coronary vein is apparent in the inferior wall in the autopsied heart (arrow). Please note fragile tissue of the cardiac surface with many petechiae. (D–G) Site of perforation in the coronary vein in the pathological examination (arrowhead). (E, G) Magnification of the boxed area. (H) Infiltration of lymphocytes and (I) macrophages containing haemosiderin around the perforated site.

Computed tomography on admission revealed mild pericardial effusion with 60 HU. Hounsfield units >30 in pericardial effusion has been reported to have a sensitivity of 100% and specificity of 70% for visceral or vascular rupture.⁴ Haemorrhagic pericardial effusion is caused by several diseases including cardiac rupture due to myocardial infarction or trauma, impending aortic rupture, iatrogenic injury of coronary artery and veins, which were excluded by the clinical history and the histological examination.

In the present case, the cause of death was identified as cardiac tamponade and dysfunction due to coronary venous perforation complicating myopericarditis.

Pericarditis and myocarditis share common aetiologies and overlap in daily clinical practice. According to European Society of Cardiology Task Force consensus, our patient met the criteria for pericarditis plus mild elevation of markers of myocardial damage without focal or diffuse impairment of left ventricular function on echocardiography, and we diagnosed 'myopericarditis'.² Damage to the myocardium was limited to within the surface area, with no elevation of CPK recognized during the clinical course and autopsy ruled out active myocarditis. Negative results from culture excluded the possibility of purulent pericarditis.

The use of rivaroxaban in addition to aspirin and cilostazol might have exacerbated damage to the coronary vein wall due to myopericarditis. However, no other common bleeding events such as gastrointestinal and/or subcutaneous bleeding were observed. It remains unclear whether we should or should not start anticoagulant drugs when paroxysmal AF is observed in patients with pericarditis and pericardial effusion with high HU in CT images.

Viral infections are among the most common causes of myopericarditis. Other mechanisms causing myopericarditis include connective tissue diseases, radiation-induced, drug-induced, or vaccine-associated diseases.² Any preceding viral illness was not reported by the patient and blood tests showed no evidence of connective tissue diseases.

The patient had undergone low anterior resection due to rectal cancer 6 years earlier, thoracoscopic resection of metastases in the left lung inferior lobe followed by chemotherapy including bevacizumab (a vascular endothelial growth factor inhibitor) and radiofrequency ablation therapy 3 years earlier. Therefore, it is impossible to rule out the possibility completely that chemotherapy and radiofrequency ablation therapy had induced chronic inflammation in the pericardium or surface of the myocardium. Although coronary veins can be involved by pericardial metastatic cancer,⁵ the tumour cells were not identified histologically and cytologically. The thickening of the pericardium, which is an important sign of chronic radiation-induced pericarditis,⁶ was not recognized on chest CT image 3 months before the admission and not in autopsy specimen. Therefore, it is unlikely that coronary vein perforation was associated with chronic inflammatory response due to metastasis or radiation.

Coronary venous perforation is an extremely rare entity and only several cases have been reported as a complication of catheterization and percutaneous coronary intervention.⁷ Perforation of the coronary vein was estimated to be induced by both inflammation of myopericarditis and the combined use of rivaroxaban, aspirin, and cilostazol.

In conclusion, our case presented with fatal myopericarditis (pericarditis plus minor cardiac muscle injury) complicated by coronary

vein perforation. The aetiology and mechanisms underlying extensive focal damage to superficial tissue around the coronary vein remain unclear. It is important to take this rare complication into consideration when we see patients with pericarditis and uncontrollable cardiac tamponade and dysfunction due to bloody effusion under the triple antithrombotic therapy.

Lead author biography



Akihiro Takasaki is a cardiologist at Mie University Hospital, Mie, Japan. He is currently undertaking a PhD with the Mie University, exploring familial hypercholesterolaemia using the Acute Coronary Registry data in Mie prefecture.

Supplementary material

[Supplementary material](#) is available at *European Heart Journal - Case Reports* online.

Slide sets: A fully edited slide set detailing this case and suitable for local presentation is available online as [Supplementary data](#).

Consent: The authors confirm that written consent for submission and publication of this case report including images and associated text has been obtained from the patient's next of kin in line with COPE guidance.

Conflict of interest: None declared.

Funding: None declared.

References

- Imazio M, Brucato A, Barbieri A, Ferroni F, Maestroni S, Ligabue G et al. Good prognosis for pericarditis with and without myocardial involvement: results from a multicenter, prospective cohort study. *Circulation* 2013;**128**:42–49.
- Adler Y, Charron P, Imazio M, Badano L, Baron-Esquivias G, Bogaert J, ESC Scientific Document Group et al. 2015 ESC Guidelines for the diagnosis and management of pericardial diseases: the task force for the diagnosis and management of pericardial diseases of the European Society of Cardiology (ESC). Endorsed by: the European Association for Cardio-Thoracic Surgery (EACTS). *Eur Heart J* 2015; **36**:2921–2964.
- Imazio M, Cecchi E, Demicheli B, Ierna S, Demarie D, Ghisio A et al. Indicators of poor prognosis of acute pericarditis. *Circulation* 2007;**115**:2739–2744.
- Rifkin RD, Mernoff DB. Noninvasive evaluation of pericardial effusion composition by computed tomography. *Am Heart J* 2005;**149**:1120–1127.
- Thurber DL, Edwards JE, Achor RW. Secondary malignant tumors of the pericardium. *Circulation* 1962;**26**:228–241.
- Cuomo JR, Sharma GK, Conger PD, Weintraub NL. Novel concepts in radiation-induced cardiovascular disease. *World J Cardiol* 2016;**8**:504–519.
- Nomura T, Kikai M, Hori Y, Yoshioka K, Kubota H, Miyawaki D et al. Bizarre sequela with cardiac venous perforation after percutaneous coronary intervention. *JACC Cardiovasc Interv* 2017;**10**:e95–e96.