

A simple technique to repair distal and mid-shaft hypospadias using a de-epithelialized Byars' flap

Jiaqiang Li^{1*}, Shoulin Li^{1*}, Zhilin Yang¹,
Zhicong Ke¹, Tiejun Zhang¹ and
Jianchun Yin¹ 

Abstract

Objective: To describe standard and modified de-epithelialized Byars' flap techniques in tubularized incised plate urethroplasty and evaluate postoperative outcomes.

Methods: We retrospectively evaluated data for 404 primary hypospadias repair patients who underwent standard (Group A) or modified (Group B) urethroplasty between January 2016 and 2021. Group B's data were analyzed to evaluate whether our modified technique was effective for all hypospadias types.

Results: There was no difference in the ratio of different hypospadias types between Groups A (n = 145) and B (n = 259). Median follow-up duration was 35 months. Fistula occurred in 19 patients in Group A and 12 in Group B (statistically significant difference). The total complication rate was statistically significantly different between the groups. In Group B, 3/142 patients with distal hypospadias developed urethrocutaneous fistula vs 4/95 with mid-shaft hypospadias and 5/22 with proximal hypospadias. No difference was noted between the distal and mid-shaft groups. Significant differences were observed when comparing distal and mid-shaft groups with the proximal group; total complication rates were similar. Glans dehiscence and meatal stenosis rates were similar between Groups A and B, and among the hypospadias phenotypes.

Conclusion: Our modified procedure is simple to perform and yields excellent results in distal and mid-shaft hypospadias repair.

*These authors contributed equally to this work.

Corresponding author:

Jianchun Yin, Shenzhen Children's Hospital, Yitian Road
7019, Shenzhen, Guangdong 518038, China.

E-mail: szjcyin158@163.com

¹Department of Pediatric Urology, Shenzhen Children's Hospital, Shenzhen, Guangdong Province, China



Keywords

Hypospadias, primary tubularized incised plate urethroplasty, de-epithelialized Byars' flap, fistula, pediatrics, complication, surgery

Date received: 11 February 2022; accepted: 5 July 2022

Introduction

There are more than 200 procedures used to repair hypospadias. Despite developments in surgical techniques, no single technique is completely successful in correcting all types of hypospadias.¹ Tubularized incised plate (TIP) urethroplasty was introduced by Snodgrass et al. in 1994, and is increasingly used to repair hypospadias with mild penile ventral curvature.²⁻³ The TIP procedure is easy to learn and has a high success rate. However, postoperative complications, such as urethrocutaneous fistula and glans dehiscence may occur. Urethrocutaneous fistula is the most common complication, and using a cover flap over the urethroplasty site is the most effective way to avoid fistula development.⁴⁻⁷ Specifically, Snodgrass et al.⁵ described using a transverse island of dorsal subcutaneous tissue to cover the repair site to prevent postoperative complications. Many other techniques have been described for harvesting vascularized dartos flaps or vascularized tunica vaginalis flaps to cover the neourethral suture line.^{6,7} The shortcomings of these methods are as follows: (1) complicated manipulation for preparing a vascularized flap, especially for novice surgeons; and (2) skin complications following dorsal dartos flap dissection, such as ischemia at the ends of the flap, can result in skin necrosis, and the testis may be affected after harvesting a tunica vaginalis flap.⁷

Here, we report our experience de-epithelializing the end of the Byars' flap and using the flap as a barrier layer in

TIP urethroplasty. This study investigated whether this technique could reduce the incidence of complications after TIP urethroplasty compared with the standard TIP procedure. We also evaluated whether this modified technique is effective in the repair of all types of hypospadias.

Materials and methods

A retrospective review was performed of the records of 404 patients who underwent primary hypospadias repair between January 2016 and January 2021. The inclusion criteria were patients who underwent primary TIP urethroplasty. We excluded patients who required urethral plate transection to correct a ventral curvature even though primary TIP urethroplasty was originally planned. We followed the relevant Equator guidelines when writing this manuscript.⁸ We did not strictly perform random grouping, but rather, roughly alternate grouping. All surgeries in this study were performed by a single surgeon (the corresponding author). The study was approved by the Shenzhen Children's Hospital ethics committee (approval number: 2021033). The parents of all of the patients in this study provided written informed consent.

All patients were divided into two groups. Group A comprised patients who underwent the standard TIP procedure in which a dorsal dartos flap is used to cover the neourethra. The patients in Group B underwent TIP urethroplasty with a de-epithelialized Byars' flap used to cover the

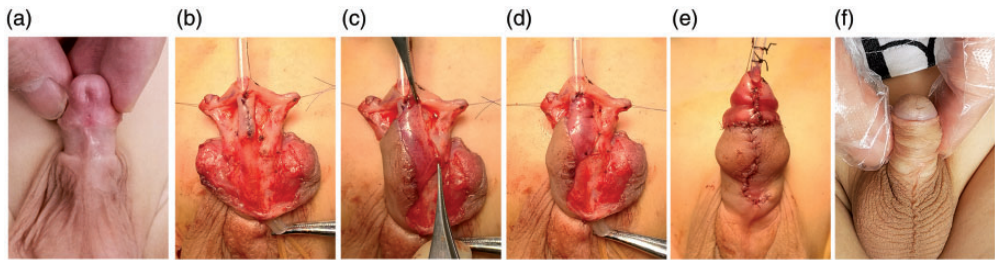


Figure 1. Photographs of the modified TIP surgical procedure (a) Preoperative appearance. (b) Closure of the incised plate. (c) Skin de-epithelialized from the inner aspect. (d) Coverage of the neourethra with the de-epithelialized Byars' flap. (e) Postoperative outcome. (f) Postoperative appearance 18 months after surgery. TIP, tubularized incised plate.

neourethra. The efficacy and safety of the procedures was evaluated by recording the number and types of complications in each group.

Surgical techniques

Standard TIP procedure: The primary steps in this procedure were in accordance with the description by Snodgrass et al.⁵ Briefly, a circumscribed skin incision is made approximately 5 mm from the proximal end of the penis to the coronary sulcus. The shaft skin is then degloved to the penoscrotal junction. A U-shaped incision is made along the visible junction of the glans wings to the urethral plate. Artificial erection is routinely performed. If ventral curvature of less than 30° is encountered, this is corrected by dorsal plication using 5-0 Prolene sutures (Ethicon Inc., Somerville, NJ, USA).

A tourniquet is applied around the base of the penis for hemostasis. The urethral plate is then separated from the glans wings by parallel longitudinal incisions. A relaxing incision is made on the midline from within the meatus to the end of the plate. The urethral plate is tubularized with two layers of 6-0 polydioxanone sutures. A barrier layer is prepared by developing a dartos pedicle from the dorsal shaft skin.

The barrier layer is buttonholed and transposed ventrally to cover the neourethra.

Modified TIP procedure: We modified the standard procedure for preparing a barrier layer, in our technique. Photographs of the surgical procedure and illustrations of the surgical operation are shown in Figures 1a–e and 2a–f, respectively. Before completing the neourethra, the prepuce is gently stretched and incised vertically into two halves (as originally described by Byars).⁹ The two flaps are then brought ventrally around the side of the penile shaft to reconstruct the ventral shaft skin. The end of one side of the Byars' flap is de-epithelialized to harvest a dartos flap (Figures 1c and 2d) while securing a sufficient preputial flap to cover the ventral shaft wound. The flap (either left or right) that provides greater opportunity for securing vascularization is selected to cover the ventral shaft wound. After the urethral plate is tubularized, the de-epithelialized flap is placed over the suture line of the entire neourethra, especially the glans wings (Figures 1d and 2e). Glansplasty is performed with 6-0 polydioxanone sutures, and ventral skin closure is then completed.

Postoperative care

For all patients in this study, the dressing was removed 4 days after surgery.

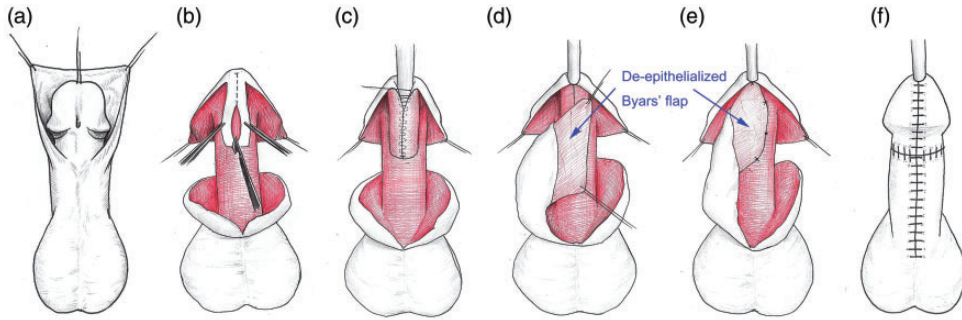


Figure 2. Illustrations showing the TIP surgical operation (a) Preoperative appearance. (b) Urethral plate separated from the glans wings and midline incision in the urethral plate. (c) The urethral plate is tubularized over a suitably-sized stent. (d) One side of the Byars' flap is de-epithelialized to harvest a dartos flap. (e) Coverage of the neourethra with the de-epithelialized Byars' flap. (f) Postoperative appearance. TIP, tubularized incised plate.

The silicone urethral stent, either 6- or 8F, was left in place for 8 to 9 days postoperatively. All patients received cephalosporin for 3 days.

Statistical analysis

Chi-square or Fisher's exact tests were used to analyze the surgical outcomes of patients in groups A and B. Further analysis was performed for patients in Group B to determine whether the modified TIP procedure was suitable for all types of hypospadias.

Results

Of the 404 patients in our study who underwent TIP urethroplasty, 223 distal, 146 mid-shaft, and 35 proximal TIP repairs were performed across the two groups. Patient age at the time of operation ranged from 1 year and 1 month to 12 years and 7 months (median age, 3.2 years). The duration of postoperative follow-up ranged from 11 months to 4 years and 6 months. A total of 145 patients underwent standard primary TIP urethroplasty and were classified as Group A (81 distal, 51 mid-shaft, and 13

proximal hypospadias), and 259 underwent modified TIP urethroplasty with a de-epithelialized Byars' flap and were classified as Group B (142 distal, 95 mid-shaft, and 22 proximal hypospadias). There was no statistical difference in the proportions of the types of hypospadias between the two groups.

The surgical complications are summarized in Table 1. Although there was no statistically significant difference in glans dehiscence and meatal stenosis rates between Groups A and B, the proportion of patients who developed glans dehiscence was higher in Group A than that in Group B. Urethrocutaneous fistula occurred in 19 (13.1%) patients in Group A and 12 (4.6%) in Group B, with a statistically significant difference ($P=0.002$). Overall, 77 (19.1%) complications occurred in the 404 patients: 43 (29.7%) were observed in Group A and 34 (13.1%) in Group B, and this was a statistically significant difference ($P<0.001$). No urethral strictures or recurrent penile ventral curvatures occurred in either group.

The results of the analysis of the three types of hypospadias in Group B are

Table 1. Comparison between the groups undergoing standard primary TIP (Group A) or de-epithelialized Byars' flap TIP (Group B).

Variable	Group A, N = 145	Group B, N = 259	P-value
Median age (years)	2.9 (1.1–11.3)	2.7 (1.2–12.6)	
Urethrocutaneous fistula; n (%)	19 (13.1%)	12 (4.6%)	0.002
Glans dehiscence; n (%)	15 (10.7%)	14 (5.4%)	0.065
Meatal stenosis; n (%)	9 (6.2%)	8 (3.1%)	0.13
Total complication rate; n (%)	43 (29.7%)	34 (13.1%)	< 0.001

Statistically significant P-values are in bold.

Table 2. Comparison between the three types of hypospadias with a de-epithelialized Byars' flap to cover the neourethra in TIP urethroplasty.

Variable	Hypospadias type and number of patients			P-value
	Distal, N = 142	Mid-shaft, N = 95	Proximal, N = 22	
Patient median (range) age; years	2.6 (1.2–12.6)	2.8 (1.3–11.9)	2.8 (1.2–5.6)	
Urethrocutaneous fistula; n (%)	3 (2.1%)	4 (4.2%)	5 (22.7%)	0.001* ; 0.34 [#] , 0.001^{&} ; 0.003[§]
Glans dehiscence; n (%)	5 (3.5%)	6 (5.2%)	3 (13.6%)	0.13 [*]
Meatal stenosis; n(%)	3 (2.1%)	3 (3.1%)	2 (9.1%)	0.21 [*]
Total complication rate; n (%)	11 (7.7%)	13 (13.7%)	10 (45.4%)	0.001* ; 0.14 [#] , 0.001^{&} ; 0.0007[§]

Statistically significant P-values are in bold.

*Comparing the three groups: [#]Distal vs Mid-shaft; [&]Distal vs Proximal; [§]Mid-shaft vs Proximal. TIP, tubularized incised plate.

presented in Table 2. There was no significant difference in glans dehiscence and meatal stenosis rates between the hypospadias types. However, 3/142 (2.1%) patients developed urethrocutaneous fistula in the distal group compared with 4/95 (4.2%) in the mid-shaft group and 5/22 (22.7%) in the proximal group ($P=0.001$). No statistically significant difference was noted when the distal group was compared with the mid-shaft group. However, a significant difference was observed when the distal group was compared with the proximal group ($P=0.001$) and when the mid-shaft group was compared with the proximal group ($P=0.003$). Overall, complications occurred in 11/142 (7.7%) patients in the distal group compared with 13/95 (13.7%)

patients in the mid-shaft group and 10/22 (45.4%) patients in the proximal group ($P=0.001$). No statistically significant difference was noted when the distal group was compared with the mid-shaft group. However, a significant difference was observed when the distal group was compared with the proximal group ($P=0.001$) and when the mid-shaft group was compared with the proximal group ($P=0.0007$).

Discussion

Despite the excellent outcomes of TIP repair and its popularity since 1994,² surgical complications still occur, and urethrocutaneous fistula is especially common.⁴ Studies indicate that well-vascularized

coverage of the primary urethroplasty effectively decreases the incidence of fistula.^{4-6,10-15} There are four ways in which a waterproof layer of tissue is commonly created: (1) using a dorsal dartos flap that is buttonholed and transposed ventrally to cover the entire neourethra;⁵ (2) using ventral vascular dartos tissue;⁶ harvesting tissue from the tunica vaginalis;^{11,15} or (4) using a de-epithelialized split preputial flap.¹²⁻¹⁴ The procedure described by Snodgrass uses a vascularized dorsal dartos flap to provide additional coverage of the neourethra.⁵ However, this method requires extensive experience, and there is a possibility that the preputial skin will become hypovascular, which may cause skin complications. Additionally, ventral skin necrosis following the harvest of a dorsal dartos flap has been reported.^{7,11}

Soygur et al. reported that ventral-based flaps were easier to harvest and transpose to cover the neourethra; complications of fistula and meatal stenosis occurred in 8.3% and 10% of cases, respectively.⁶ However, in our experience, in most cases, there is insufficient ventral-based vascular dartos tissue to harvest to cover the suture line.

The tunica vaginalis flap has been reported to be a better alternative to the dorsal dartos flap in non-distal TIP repairs.^{7,16} Babu and Hariharasudhan reported that the tunica vaginalis flap was associated with a lower fistula rate and was superior to the inner preputial dartos flap as a waterproofing layer for primary TIP repair in mid-shaft hypospadias.⁷ Snodgrass and Bush also reported replacing the dorsal dartos flap with a tunica vaginalis flap in all proximal TIP repairs as part of the evolution of their technique.¹⁶ However, complicated manipulation is required for the preparation of a tunica vaginalis flap, and this flap may cause penile torsion or curvature and iatrogenic cryptorchidism. As a result, consensus has not yet been

established to support the routine use of this flap in all non-distal TIP repairs.

In 1988, Belman described de-epithelialized preputial skin flap coverage in hypospadias repair.¹³ This technique not only decreases the incidence of fistulas but also avoids glans disruption compared with other techniques.¹³ Additionally, compared with other techniques for harvesting a waterproof layer, in our experience, the advantages of de-epithelialized flap techniques are that they are easy to perform, there is no need to separate the dartos tissue from the skin that covers the penile wound, and the risk of compromising the vascularity of the penile skin is low.

Other reports have described using de-epithelialized skin flap techniques that are similar to ours.^{11,12,17,18} Tam et al. reported that using a de-epithelialized split preputial flap for the cover layer resulted in fewer fistulas (10.5%) compared with dorsal dartos flaps (28.8%) in the repair of mid-shaft and proximal hypospadias ($P=0.03$).¹¹ Moreover, el-Kassaby et al. reported that a modification of TIP urethroplasty with a de-epithelialized preputial flap for the cover layer provided excellent functional and cosmetic results in the repair of 738 (96.6%) distal hypospadias.¹² Additionally, Abouzeid reported that fistulas occurred in 3.6% of patients who underwent modified TIP urethroplasty and 10.5% of patients who underwent the standard procedure.¹⁷ These previous procedures de-epithelialized half or almost half of the preputial flap, and the other half of the flap was used to reconstruct the ventral penile skin. When half of the preputial flap is de-epithelialized, there may be insufficient skin to cover the penile wound as well as the median skin suture line. This compromises the cosmetic outcome and could cause penile torsion. Our technique is slightly different: we de-epithelialize only the end of half of the Byars' flap (Figure 1c), and leave enough skin to cover the ventral wound. In our

experience, only a small amount of tissue (3–4 mm) is required to create the barrier layer across the suture line (Figure 1d). This preputial flap is easier to harvest than the traditional dorsal dartos flap and in most instances, the flap can also cover the median skin suture line and produces good cosmetic results (Figure 1e). Moreover, this technique could reduce the incidence of penile torsion. In this study, the patients in the standard TIP urethroplasty group (Group A) had higher fistula and total complication rates than the rates for those who underwent TIP urethroplasty with a de-epithelialized Byars' flap (Group B). Our outcomes are similar to those of previous studies (el-Kassaby et al.¹² and Abouzeid¹⁷). Our findings suggest that this modification is an easy and valuable method for hypospadias repair.

TIP urethroplasty can be used for all types of hypospadias repair where the urethral plate can be preserved.³ The procedure can be used in most distal and mid-shaft hypospadias because these hypospadias types have mild penile ventral curvatures. However, most cases of proximal hypospadias have severe chordee, and staged surgery is preferred. In our study group, only a small number of proximal hypospadias cases with mild ventral curvature were suitable for primary TIP urethroplasty. Therefore, only 22 proximal primary TIP urethroplasty procedures were performed. Despite the small number of these surgeries, we found that the distal and mid-shaft groups had similarly low fistula and total complication rates compared with the proximal group. No statistically significant difference was observed when the distal group was compared with the mid-shaft group. Our findings suggest that our modification is an ideal method for distal and mid-shaft hypospadias repair.

The results of our analyses revealed the limitation of our modified technique for proximal hypospadias repair. With the

relatively small number of proximal hypospadias in the entire study sample, it was impossible to investigate the effectiveness of a de-epithelialized Byars' flap in preventing fistulas in proximal hypospadias compared with dorsal dartos flaps. In patients with insufficient de-epithelialized tissue to adequately cover the whole neourethra in proximal hypospadias, the contralateral Byars' flap was crossed over the midline to cover the proximal region of the neourethra. Fistulas occurred in 22.7% (5/22) of the patients treated this way. Fortunately, the diameter of the fistulas in these five patients was less than 1 mm, and reoperation was performed to correct this complication. Because the tunica vaginalis flap can be used to cover the suture line, and this approach has shown good results in proximal TIP repairs,^{7,11} we suggest that this flap be used when there is insufficient de-epithelialized Byars' flap to cover the whole neourethra. However, the complications associated with this method should be considered carefully.

The TIP procedure is associated with low postoperative meatal stenosis and urethral stricture rates; the overall reported incidence is only 3%.^{3,19} In our experience, a deep plate incision, plate tubularization that is not too distal and that preserves the appropriate width of the opening, and tension-free closure of the glans wings can help reduce the risk of meatal stenosis.

The main limitation of this study is the non-prospective randomized controlled design. Even though all surgeries were performed by the same surgeon, it is possible that other variables may have affected surgical outcomes; for example, bias in patient selection for performing standard primary or modified TIP urethroplasty, and the surgeon's experience. However, there was no significant change in the incidence of fistula over time. In Group B, patients with proximal hypospadias had higher fistula and total complication rates compared with

distal and mid-shaft hypospadias. These higher rates may have resulted from the small number of patients with proximal hypospadias in the study, and the limitation of this modification when used in proximal TIP urethroplasty. Given these limitations, a prospective randomized controlled trial is being planned to obtain more objective and reliable results to enable our modified technique to be recognized and widely disseminated.

Conclusions

Compared with standard TIP, a de-epithelialized Byars' flap is easier to harvest and more effective in avoiding fistula formation, especially in distal and mid-shaft primary hypospadias repair.

Declaration of conflicting interest

The Authors declare that there is no conflict of interest.

Funding

The author(s) disclosed receipt of the following financial support for the research, authorship, and/or publication of this article: This work was supported by the Sanming Project of Medicine in Shenzhen [grant number SZSM201612013]; the Shenzhen Medical Key Discipline of Pediatric Surgery (2020 to 2024) [grant number SZXK035]; the Shenzhen Health System Research Project [grant number SZXJ2018045]; the Shenzhen Health System Research Project [grant number SZFZ2018055]; and the Medical Research Fund of Guangdong Province [grant number A2022525].

Authors' contributions

All authors conceived and designed the study. All authors read and approved the final manuscript.

ORCID iD

Jianchun Yin  <https://orcid.org/0000-0002-9776-6656>

References

1. Wilkinson DJ, Farrelly P and Kenny SE. Outcomes in distal hypospadias: a systematic review of the Mathieu and tubularized incised plate repairs. *J Pediatr Urol* 2012; 8: 307e312.
2. Snodgrass W, Bush N and Cost N. Tubularized, incised plate urethroplasty for distal hypospadias. *J Urol* 1994; 151: 464–465.
3. Snodgrass WT. Tubularized incised plate (TIP) hypospadias repair. *Urol Clin North Am* 2002; 29: 285–290.
4. Tessier B, Sfar, S, Garnier S, et al. A cover flap reduces the rate of fistula after urethroplasty whatever the severity of hypospadias. *World J Urol* 2020; 39: 2691–2695.
5. Snodgrass WT. Snodgrass technique for hypospadias repair. *BJU Int* 2005; 95: 683–693.
6. Soygur T, Arıkan N, Zumrutbas AE, et al. Snodgrass hypospadias repair with ventral based dartos flap in combination with mucosal collars. *Eur Urol* 2005; 47: 879–884; discussion 884.
7. Babu R and Hariharasudhan S. Tunica vaginalis flap is superior to inner preputial dartos flap as a waterproofing layer for primary TIP repair in midshaft hypospadias. *J Pediatr Urol* 2013; 9: 804–807.
8. Von Elm E, Altman DG, Egger M, et al. The Strengthening the Reporting of Observational Studies in Epidemiology (STROBE) statement: guidelines for reporting observational studies. *Lancet* 2007; 370: 1453–1457.
9. Byars LT. Functional restoration of hypospadias deformities; with a report of 60 completed cases. *Surg Gynecol Obstet* 1951; 92: 149–154.
10. Appignani A, Prestipino M, Bertozzi M, et al. Double-cross flap protection: new technique for coverage of neourethra in hypospadias repair. *J Urol* 2009; 182: 1521–1527.
11. Tam YH, Pang KK, Wong YS, et al. Improved outcomes after technical modifications in tubularized incised plate urethroplasty for mid-shaft and proximal hypospadias. *Pediatr Surg Int* 2016; 32: 1087–1092.

12. el-Kassaby AW, Al-Kandari AM, Elzayat T, et al. Modified tubularized incised plate urethroplasty for hypospadias repair: a long-term results of 764 patients. *Urology* 2008; 71: 611–615.
13. Belman AB. De-epithelialized skin flap coverage in hypospadias repair. *J Urol* 1988; 140: 1273–1276.
14. Belman AB. The de-epithelialized flap and its influence on hypospadias repair. *J Urol* 1994; 152: 2332–2334.
15. Basavaraju M and Balaji DK. Choosing an ideal vascular cover for Snodgrass repair. *Urol Ann* 2017; 9: 348–352.
16. Snodgrass W and Bush N. Tubularized incised plate proximal hypospadias repair: continued evolution and extended applications. *J Pediatr Urol* 2011; 7: 2–9.
17. Abouzeid AA. Modified Byars' flaps for securing skin closure in proximal and mid-penile hypospadias. *Ther Adv Urol* 2011; 3: 251–256.
18. Ross JH and Kay R. Use of a de-epithelialized local skin flap in hypospadias repairs accomplished by tubularization of the incised urethral plate. *Urology* 1997; 50: 110–112.
19. Snodgrass W and Bush N. TIP hypospadias repair: a pediatric urology indicator operation. *J Pediatr Urol* 2016; 12: 11–18.