

Developing Consistency in Rhinoplasty

Erez Dayan, MD
Rod J. Rohrich, MD

Summary: This invited Special Topic article outlines the authors' evolution and technique to optimize consistent results in rhinoplasty. (*Plast Reconstr Surg Glob Open* 2020;8:e2679; doi: [10.1097/GOX.0000000000002679](https://doi.org/10.1097/GOX.0000000000002679); Published online 22 April 2020.)

INTRODUCTION

Rhinoplasty is among the most technically and conceptually challenging procedures for plastic surgeons to achieve consistent reproducible results. Over the past 25 years, nasal analysis and strategies for correction of functional and aesthetic nasal deformities have evolved considerably.¹ According to the American Society of Plastic Surgeons, rhinoplasty was among the top 5 most popular cosmetic surgical procedures in 2017, with 218,924 procedures performed. The purpose of this special topic article is to describe preoperative considerations, nasal analysis, and technical maneuvers to allow the plastic surgeon to develop consistent results in the earlier part of one's career.

PREOPERATIVE EVALUATION AND NASAL ANALYSIS

Preoperative evaluation of the rhinoplasty patient includes an evaluation of the patient's psychological state and desired 3 top goals, as well as a critical evaluation of functional and aesthetic components of the nose. This systematic evaluation process is a critical first step to determine if the patient is a good rhinoplasty candidate and if their functional and aesthetic goals are achievable. The clinician should be attuned to patients with unrealistic expectations and avoid operating on them, as patients seeking rhinoplasty have been shown to have a higher association with body dysmorphic disorder.²

Comprehensive and systematic preoperative nasofacial analysis is requisite to define surgical goals and achieve satisfactory results. However, aesthetic ideals should be approached cautiously as there is significant variability among different ethnicities.³ Several methods for nasofacial analysis have been described.^{1,4,5} The senior author (R.J.R.) approaches the nasofacial exam in a systematic fashion, from 3 different views. We follow a systematic

analysis of the frontal/lateral/basal components of the nose, respectively (Table 1).

OPERATIVE TECHNIQUE

The open rhinoplasty approach is favored for optimal binocular visualization and precise diagnosis and correction of nasal deformities.^{1,5,6} All rhinoplasty surgery is performed under general anesthesia to ensure patient comfort and airway safety. Before preparation and draping, a 27-gauge needle is used to infiltrate 1% lidocaine containing 1:100,000 epinephrine into the columella, along the infracartilaginous incision, the dorsum, and soft tissues medial and lateral to the nasal bones. The nose is packed bilaterally with oxymetazoline soaked pledgets. A moist 3-inch gauze throat pack is placed by the surgeon. This sequence allows ample timing for the vasoconstrictive effect of the local anesthesia to take effect.^{1,5,6}

INCISION AND OPEN APPROACH TO RHINOPLASTY

A stair-step transcolumellar incision is designed in the narrowest part of the columella, and carried into the vestibule 2–3 mm laterally. In secondary or tertiary cases, the location of the transcolumellar incision is placed in the preferred location regardless of location/orientation of previous incisions.⁷ Dissection of the columella proceeds from inferior to superior. A wide double hook is placed to evert the alar rim over the fourth finger. This maneuver allows for reliable identification of the caudal margin of the lateral crus upon which an infracartilaginous incision is made in a lateral to medial direction toward the nostril apex. This incision sequence leaves a vestibular tissue bridge under the soft triangle which is incised last (Fig. 1). This ensures adequate vestibular tissue (~3 mm)

From the Dallas Plastic Surgery Institute, Dallas, Tex.

Received for publication November 1, 2018; accepted January 13, 2020.

Copyright © 2020 The Authors. Published by Wolters Kluwer Health, Inc. on behalf of The American Society of Plastic Surgeons. All rights reserved. This is an open-access article distributed under the terms of the [Creative Commons Attribution-Non Commercial-No Derivatives License 4.0 \(CCBY-NC-ND\)](https://creativecommons.org/licenses/by-nc-nd/4.0/), where it is permissible to download and share the work provided it is properly cited. The work cannot be changed in any way or used commercially without permission from the journal.

DOI: [10.1097/GOX.0000000000002679](https://doi.org/10.1097/GOX.0000000000002679)

Related Digital Media are available in the full-text version of the article on www.PRSGlobalOpen.com.

Disclosures: R.J.R. receives instrument royalties from Eriem Surgical Inc. and book royalties from Thieme Medical Publishing. He is a Clinical and Research Expert for Allergan Inc. and MTF Biologics, and the Owner of Medical Seminars of Texas, LLC. E.D. is a founder and developer of WikiPlasticSurgery.com a web-based resource for plastic surgery education. He serves as a consultant for InMode. No funding was received for this article.

Table 1. Systematic Nasofacial Analysis (Frontal, Lateral, Basal Views), Nasal Analysis

Frontal		
1. Facial proportions	a. Horizontal 1/3s	• Hairline-glabella-nasal base-menton
2. Skin type/quality	a. Fitzpatrick b. Thin/thick, sebaceous	• Thinnest skin at rhinion (osseocartilaginous jx, keystone area), thickest at supratip
3. Symmetry and nasal deviation	a. Midline vs deviated nose-dorsal deviation	• C-, reverse C-, S-shaped deviation
4. Dorsal aesthetic lines	a. Symmetric vs asymmetric b. Well- vs ill-defined c. Narrow vs wide	• M: wide, straight DALs • F: narrow, concave at bridge
5. Bony vault	a. Narrow vs wide b. Asymmetric nasal bones c. Short vs long nasal bones	• Width of bony base = 80% alar base or intercanthal dist • Open roof deformity -> wide, flat bony vault
6. Midvault	a. Narrow vs wide b. Collapse, inverted-V	• Midvault collapse allows outline of nasal bones to be seen (inverted-V) • Saddlenose: loss of dorsal septal support
7. Nasal tip	a. Ill- vs well-defined tip-defining points b. Bulbous vs boxy c. Pinched e. Infratip lobule	• Broad, less refined tip in M • Bulbous tip (round, ill-defined) • Boxy (square, wide) d/t 1.inc'd angle of divergence>30° (btwn middle crus); 2. wide domal arc >4mm • Infratip lobule excess d/t 1.inc'd width or length of middle crus; or 2. prominent caudal septum • Seagull in gentle flight
8. Alar rims	a. Gull-shaped b. Notching, retraction	• Nasal base width = intercanthal dist • Upper lip crease
9. Alar base	a. Wide vs narrow	
10. Upper lip	a. Long vs short b. Dynamic depressor septi	
Lateral		
1. Nasofrontal angle	a. Acute vs obtuse NF angle b. High vs low radix	• NF angle 130° (M) - 134° (F) • Radix = btwn lash line and supratarsal fold • Nasion = 15mm anterior to medial canthus
2. Nasal length	a. Long vs short (low radix -> short nose)	• Nasal length = radix to nasal tip; ideal is 2/3 midfacial height, or equal to chin vertical
3. Dorsum	a. Smooth b. Convexity, hump c. Scooped out	
4. Supratip	a. Supratip break b. Supratip fullness, pollybeak	
5. Tip projection	a. Over or under-projected	• Tip projection = 0.67x ideal nasal length, or 50%–60% of nasal tip lies anterior to lip *nasolabial angle = 90°–95° (M), or 95°–105° (F). Axis from most anterior to posterior points of nostril *columellar-labial angle: inc'd fullness usually d/t prominent caudal septum
6. Tip rotation	a. Over or under-rotated	• Ideal columellar show = 2–3 mm • Excess columellar show d/t 1.retracted ala, or 2. hanging columella • Distance from long axis of nostril to alar rim or columella: 1–2 mm
7. Alar-columellar relationship	a. Alar retraction hanging columella c. Hanging ala retracted columella	• Chin should be at level of anterior-most point of lip in M, and 3 mm posterior to this in F
8. Periapical hypoplasia	a. Maxillary or soft tissue deficiency	
9. Lip-chin relationship	a. Over vs underprojected chin (deficient chin)	• Columella:lobule = 2:1
Basal		
1. Nasal projection (tip-defining points)	a. Over or under-projected	• Nostril:tip = 2:1
2. Nostril (Alar rim)	a. Well- vs ill-defined a. Symmetry b. Long/narrow vs short/wide a. Alar notching or collapse	• ideal basilar view: alar rims fall within equilateral triangle • “Concave” ala: weak alar rims -> pinched ala, alar notching • “Convex” ala: rounded ala, d/t convex LLC or thick alae • Septal tilt
3. Columella	b. Concave vs convex ala a. Caudal septal deviation b. Flaring of medial crura -> wide columella	• Alar base = intercanthal distance • Alar flaring should be within 3 mm outside alar base
4. Alar base	a. Width	
5. Alar flaring		

d/t, due to; inc'd, increased.

for closure, prevents alar cartilage transection, and avoids distortion of the soft triangle and nostril rim.^{1,5,6}

Once the infracartilaginous incisions are completed bilaterally and the lower lateral cartilages (LLC) are partially exposed, a wide double hook is placed at the nostril apices and retracted caudally. The nasal soft tissues are elevated off the cartilaginous framework with fine dissecting scissors. When the caudal portion of the nasal bones is reached at the keystone area, a Joseph periosteal elevator is used to achieve a limited subperiosteal

dissection over the areas of planned bony work. The periosteal dissection proceeds in 3 directions—central, right, and left—to allow for placement of the Aufrecht retractor.

TURBINATE REDUCTION

In the vast majority of cases requiring inferior turbinate reduction, we prefer the closed microfracture technique as described by Rohrich et al.⁸ The oxymetazoline

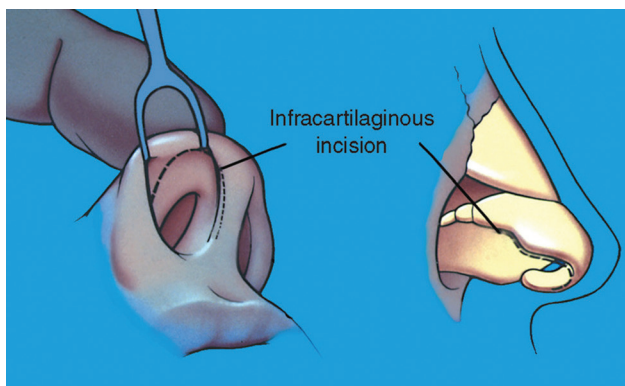


Fig. 1. Infracartilaginous open rhinoplasty incision sequence.

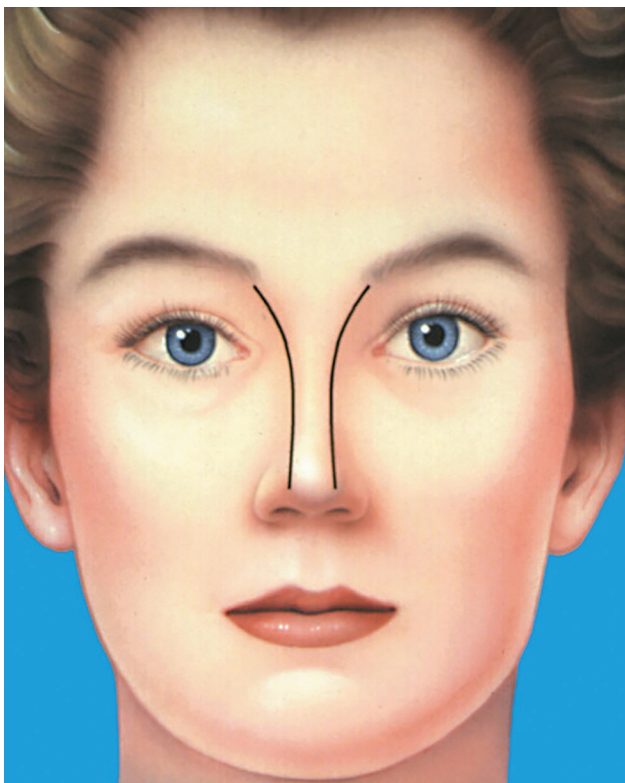


Fig. 2. Symmetric dorsal aesthetic lines on frontal view.

soaked pledgets are removed from the vestibules bilaterally and a long heavy Vienna nasal speculum is used to microfracture the inferior turbinates through a closed approach from posterior to anterior while pushing the speculum laterally onto the inferior turbinate. This technique maintains a mucosal sac over the comminuted inferior turbinate, avoiding a greenstick-type fracture that could migrate back into an obstructive position.

THE COMPONENT DORSUM

Modification of the nasal dorsum, and in particular dorsal hump reduction, is one of the most common goals among rhinoplasty patients.^{9–11} In these cases, the patient

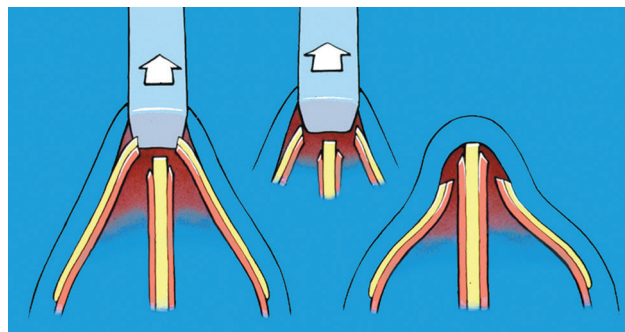


Fig. 3. Composite dorsal hump reduction (note: loss of ULC).

may emphasize the desire for a smooth dorsum on profile view. However, the rhinoplasty surgeon should always aim to achieve aesthetic ideals in all views, including symmetric dorsal aesthetic lines on frontal view (Fig. 2). This is the key to successful consistent results in rhinoplasty.

Historically, dorsal reduction was achieved by reducing the osseocartilaginous structures in a composite fashion (Fig. 3).¹² However, this approach led to little control and increased risk for functional and aesthetic complications such as inverted V deformity, internal valve collapse, and irregular dorsal aesthetic lines.^{1,5,6,9} The 5-step component dorsal hump reduction (CDHR), described in 2004 by Rohrich et al, serves to reduce the dorsum in a precise and graduated fashion while maintaining the upper lateral cartilages (ULCs).^{6,10,11,13–15} CDHR begins with (1) separation of the ULCs from the septum. This is done by dividing the suspensory ligament between the medial crura and identification of the anterior septal angle. A scalpel is then used to score the perichondrium ~3mm posterior to the anterior septal angle. A submucoperichondrial tunnel deep to the ULC is developed with a Cottle elevator. Next, the ULCs are separated from the septum at a 30-degree angle with a 15 blade to preserve maximal horizontal length of the ULC, (2) the septum proper is then incrementally reduced, (3) the bony dorsum is reduced with a down-biting rasp using short excursions centrally, to the right and left of the nasal pyramid, (4) lastly smoothness of the dorsum is verified by palpation, and (5) final modifications are made (spreader grafts, suturing techniques, osteotomies). This step-wise approach allows for reassessment at every interval to ensure consistent results.¹⁴ (See Video 1 [online], which displays a CDHR.)

Septum

Septoplasty may be required in cases of nasal obstruction and/or deviation (septal tilt, anterior posterior deviation, craniocaudal deviation, or septal spurs).^{1,5,6,9} Alternatively, septoplasty may be performed in cases without septal deformity, as a preferred donor site for cartilage grafts. In either circumstance, the septum is approached by performing a wide submucoperichondrial/mucoperiosteal dissection with a Cottle elevator in a posterior to inferior to anterior sequence (Fig. 4). This dissection releases potentially deforming extrinsic forces of the mucoperichondrium on the septal cartilage and allows for access to any intrinsic septal deformities requiring correction.^{1,5,6,9}

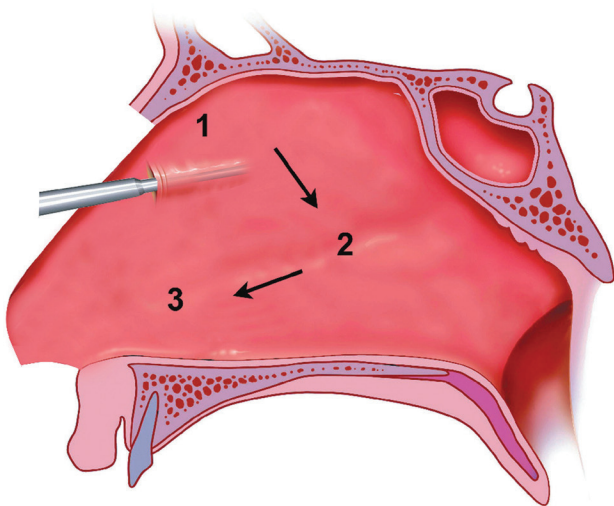


Fig. 4. Submucoperichondrial dissection of the septum.

Particularly in cases of caudal septal deviation, the mucoperichondrium should be elevated completely off the caudal end of the septum down to the anterior nasal spine (ANS). The septum is reassessed after release of the mucoperichondrium. If intrinsic deviation is present, an L-strut is designed of at least 15mm dorsally and 10mm caudally to ensure stability. Importantly, the septal incision is directed in a posterior-oblique direction at the cephalic portion of the cartilaginous septum to protect the articulation with the perpendicular plate of the ethmoid.^{1,5,6,9} Similarly, the transition point between the dorsal and caudal L-strut is curved to reduce the risk of L-strut fracture. Deviations of

the vomer or bone spurs are removed with a Rongeur or Takahashi forceps; as this can impair nasal airflow particularly in anterior inferior portion of the airway.

The remaining septal L-strut is reassessed for deviation. Persistent caudal septal deviation is not uncommon and usually caused by vertical excess of the anterior septum.¹⁶ In these cases, the caudal portion of the L-strut is released from the ANS/maxillary crest and the vertical excess is excised. The caudal septum is then re-secured to the contralateral aspect of the ANS with a 5-0 polydioxanone suture (PDS) suture.¹⁶ While these techniques may correct septal deviations in majority of cases, occasionally more aggressive maneuvers previously described such as scoring or partial-thickness wedge excisions along with batten support grafts may be required to create a straight and stable L-strut.^{17,18} It is important for the rhinoplasty surgeon to consider that a number of these septal maneuvers (ie, open approach, ANS manipulation, shortening caudal septum) may impact tip projection and rotation. A columellar strut may be utilized to support and unify the tip complex.¹⁶ Alternatively, a septal extension graft may be required if changes in tip projection or rotation are desired (Fig. 5).

RECONSTITUTION OF THE DORSUM

After CDHR, the ULCs tend to recoil and an asymmetric retroposed position.^{13,14,19} Several techniques may be used for restoration of the position and contour of the ULCs.¹¹ Most commonly, ULCs and dorsal septum can be reconstituted using ULC tension spanning sutures or autospreader flaps (Fig. 6). The ULC tension spanning suture functions to stabilize the ULC to the septum while establishing symmetric

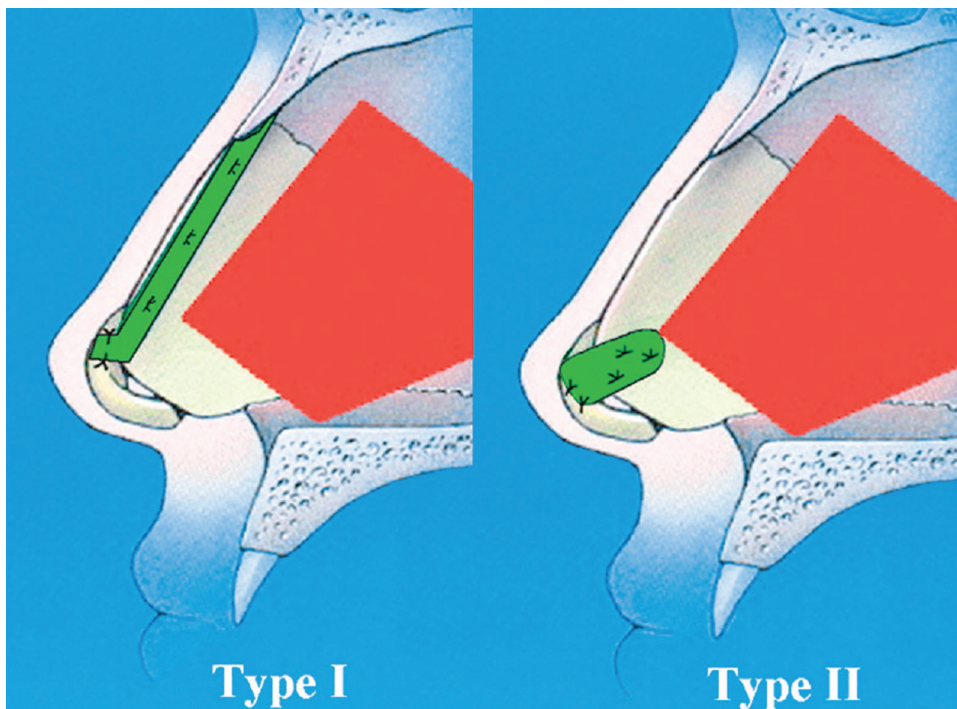


Fig. 5. Septal extension grafts.

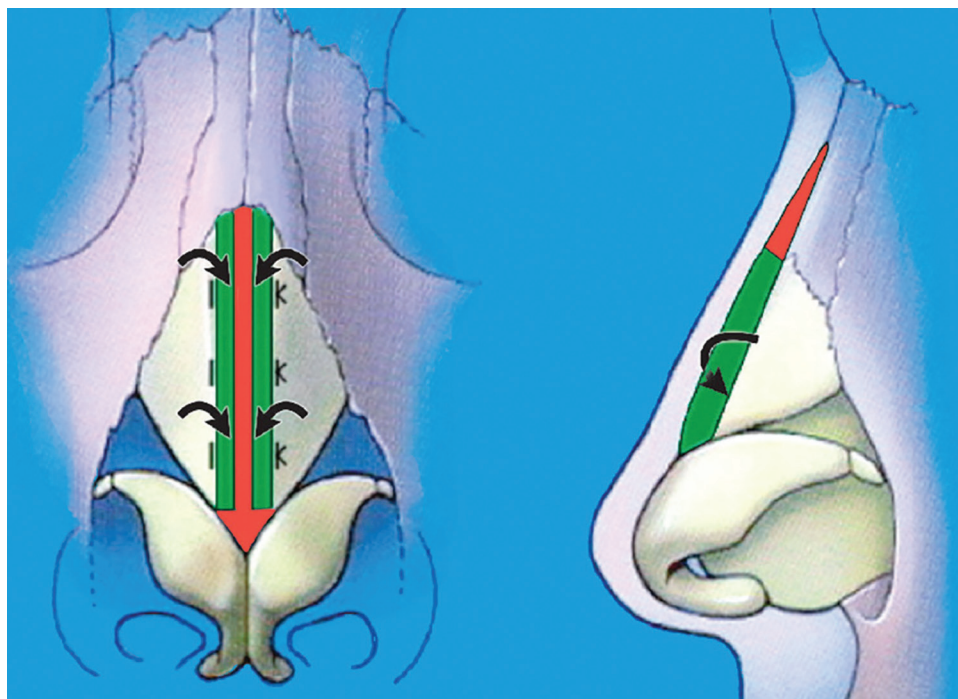


Fig. 6. ULC autospreader flaps.

dorsal aesthetic lines. Furthermore, preserving the ULCs by CDHR and subsequently reconstituting them on slight tension allows for a horizontal spreader function that avoids undesirable ULC medial shift. A 5-0 PDS is placed from the edge of both ULCs to the distal septum, advancing both ULCs ~3mm distally along the septum.²⁰ This stabilizes the ULCs to the septum on slight tension, providing a more anatomic contour. Additional sutures can be placed cephalically along the ULCs and septum as needed for support or improved contour. Occasionally, the caudal portion of the ULCs requires trimming, depending on if patient requires tip rotation or nasal shortening. Confirmation of dorsal aesthetic line reconstruction is assessed by direct visualization and palpation.^{1,5,6,11,15,19,20} Autospreader flaps can be performed when there is excess horizontal dimension to the ULCs. The anterior edge of the ULCs is folded inward and a 5-0 PDS suture is secured in a horizontal mattress fashion.^{1,19,20} (See Video 2 [online], which displays a ULC autospreader flap.)

The need for spreader grafts has become far less common since the introduction of CDHR, as the ULC horizontal dimension is preserved, allowing for better patency of the internal nasal valve and dorsal contour with ULC tension spanning sutures or autospreader flaps.^{1,5,6} However, spreader grafts may be required in secondary cases or if the patient has a deviated nose, narrow midvault, or collapsed internal valve.^{1,5,6}

BONY BASE

Nasal osteotomies are primarily used to narrow a widened bony vault, close an open roof deformity, or straighten deviated nasal bones.^{1,5,21-23} The senior author (R.J.R.) prefers a low-to-low percutaneous perforated lateral discontinuous osteotomy (Fig. 7).²¹ This approach minimizes

intranasal trauma and morbidity associated with internal osteotomies while allowing for a more controlled fracture.^{1,5} A sharp 2-mm osteotome is introduced percutaneously at the level of the inferior orbital rim and nasofacial junction parallel to the horizontal surface of the maxilla. The osteotome is swept down the lateral nasal sidewall in the subperiosteal plane to avoid injury to the angular artery. The osteotomy is oriented at an angle such that only 1 corner of the edge is in the direct contact with the bone. This allows for increased precision and minimizes trauma to surrounding tissue. A mallet is used to strike the osteotome until the surgeon notices a change in both the feel and sound at the desired osteotomy site. Multiple discontinuous osteotomies are spaced 2-mm apart in a low-to-low fashion. It is important to remain within the initial percutaneous osteotomy site to avoid injury to the angular artery.

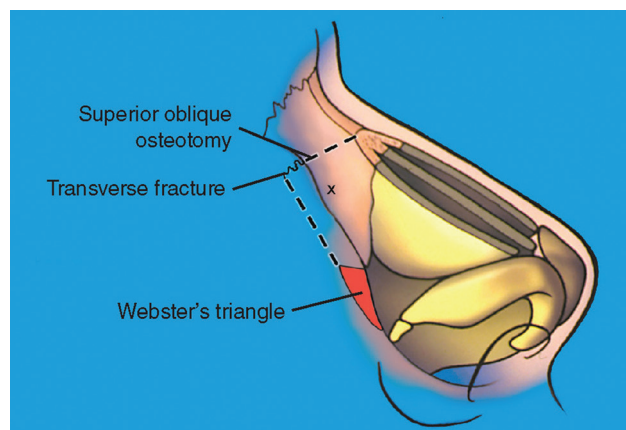


Fig. 7. Low to low nasal bone osteotomy.

If withdrawal of the osteotome is necessary it should be replaced in the original percutaneous access site with the same previously described downward sweeping motion to avoid vascular injury.²¹ After the bilateral osteotomies are completed, the nasal bones are greenstick fractured with gentle pressure between the thumb and forefinger until the bony pyramid is positioned in the desired location.

Osteotomies can be performed at any point during the procedure. Once the osteotomized segments have been positioned, the dorsum should be reassessed to confirm that no dorsal irregularities have been created, particularly in the keystone region as the ULCs can be pushed posteriorly to cause an inverted V deformity or become more prominent on the dorsum due to compression from the osteotomized bone segments.²¹ Depending on preoperative asymmetries in the bony pyramid, a butter knife can be used to differentially align each side to more symmetric position.

TIP MANEUVERS

The nasal tip shape, projection, and rotation is primarily determined by the LLCs and associated fibrous attachments.^{24–27} However, adjacent structures such as the ULCs, nasal septum, nasal base, and piriform aperture can also significantly influence the nasal tip.^{1,5,6} The soft tissue envelope is particularly important when trying to modify the nasal tip.⁹ For example, patients with thick sebaceous skin may require a more aggressive approach to tip work to achieve a desired correction. A variety of techniques have been described to refine the nasal tip, including cartilage resection, suturing, and visible or invisible cartilage grafts.^{24–30} Over the past 20 years, there has been a significant shift in tip shaping techniques.^{5,25,26} Rigid visible grafts are typically not utilized in primary rhinoplasty patient unless necessary and have been replaced by tip suturing techniques and modifications of existing nasal cartilage.^{1,5,6} The rhinoplasty surgeon must consider all components of the tip complex to assure that the appropriate shaping maneuvers are employed to provide the patient with ideal tip position while maintaining adequate support.

Conceptually, the tip complex can be viewed as a nasal tripod; with modifications to any of the limbs leading to changes in rotation and/or projection.^{27,31} Frequently, a graduated series of techniques is required to correct tip deformities, improve shape, and minimize loss of support.²⁸ To obtain consistent results in nasal tip shaping, the rhinoplasty surgeon should be comfortable with indications and execution of cephalic trim, use of a columellar strut graft, septal extension grafts, nasal tip suturing techniques, and nasal tip grafting.^{24,25,27,28,30,32,33} These techniques are most precisely and easily approached through the open rhinoplasty approach. However, the open approach itself leads to mild loss of tip projection because of the disruption of soft-tissue support structures, which must be taken into consideration and supported with suturing techniques or grafting.⁶

Cephalic Trim

The purpose of cephalic trim is to refine the nasal tip and decrease supratip fullness by reducing the vertical height of the LLCs.^{30,34–36} Typically, only convex areas leading to

domal fullness are resected. The LLC is separated from the ULC at the scroll area. The cephalic portion of the LLC is trimmed leaving at least 8–10mm medially and 5–7mm laterally.³⁶ (See Video 3 [online], which displays a cephalic trim.) Care must be taken to not overly resect and weaken the LLC as this can lead to alar deformities (pinched tip, alar retraction, nasal tip asymmetry/collapse) or external nasal valve collapse.^{5,27,31} There are multiple variations of cephalic trim depending on the deformity to be corrected as described by Rohrich et al.^{27,36} The cephalic trim should not be used as a standard maneuver in primary and secondary rhinoplasties as it has been in the past.³⁶ This technique should be employed judiciously and in a graduated manner after careful preoperative and intraoperative assessment. Dome suture techniques or trimming of the anterior septal angle as it approaches the domes are alternative powerful techniques to refine the nasal tip and reduce peridomal fullness without weakening LLCs.²¹

Tip Suturing

Key tip suturing techniques to improve position and shape include medial crural, transdomal, and interdomal sutures.^{5,26,28,33} The three endpoints of tip suturing are: (1) caudal portion of the tip should be higher than the cephalic portion, (2) lateral crura should be straight, and (3) the lower lateral complex should be everted upward. (See Video 4 [online], which displays key endpoints of tip shaping.)

Medial crural sutures can be used to address a number of deformities, such as correct medial crural asymmetries, reduce flaring, control width of the columella, increase tip projection, and to secure a columellar strut graft.^{5,26,28,33} Often, these sutures are the first of the tip suturing techniques performed, as the medial crural-columellar strut complex acts as a point of stability in the nasal tripod.^{1,5,26} Typically this is performed with a 5-0 PDS using a 3 suture technique: (1) internal medial footplate suture, (2) lower intercrural, and (3) high intercrural. This suture increases tip strength and projection by recruiting medial crura anteriorly toward the anterior septal angle.^{1,5,26}

The transdomal suture is a powerful technique used to alter tip shape as well as contour of the lateral crura.^{1,9,26,27} A 5-0 PDS horizontal mattress suture is placed from medial to lateral across the dome. Differential placement of these sutures can be used to correct asymmetries in the domes.^{1,5,26} One should be cautious of over-tensioning these sutures as this can lead to excess concavity adjacent to the domes and excessive tip projection. Also, attention should be paid to the cranio-caudal placement of the suture, as this can have a significant impact on rotation of the LLC.^{1,5,26}

The interdomal suture is another important suturing technique that is commonly used to decrease the angle of domal divergence, narrow the tip-defining points, increase tip projection, and refine the infratip lobule.^{25–28,31} A 5-0 PDS suture is placed from lateral to medial through 1 dome and then again from medial to lateral through the opposite dome as a loop suture.^{1,5,26} A figure-of-eight suture can also be used if needed to properly align the domes. Similar to the transdomal suture, the interdomal suture should be tightened incrementally to achieve the desired interdomal distance without over-tightening. Also,

cephalo-caudal placement of this suture technique will have a significant impact on the orientation of the domes and lateral crura.^{1,5,26}

Cartilage Grafts

The use of cartilage grafts has changed over time in primary and secondary rhinoplasty.^{1,5} Traditionally, placement of visible grafts such as the onlay tip or dorsal grafts were commonplace. However, long-term complications, such as displacement, absorption, warping, and increased visibility, over time caused these grafts to become less desirable. At the same time, increased popularity of the open rhinoplasty approach and advancement of tip suturing techniques led to a shift toward these suturing methods over grafting for nasal tip refinement.^{1,5} A number of visible and invisible grafting techniques are still commonly used in select patients to support and shape the tip complex, including columellar strut grafts, septal extension grafts, and tip grafts.^{1,5,6,9,26,27,36} In general, grafting should be approached from the base to tip lobule to ensure stability.

The columellar strut graft is placed in a pocket created between the medial crura and can either be floating or stabilized on the ANS.^{29,37,38} This graft can be used to unify the tip complex, maintain tip projection, treat medial crural deformities, or treat columellar deformities.^{29,37,38} Septal extension grafts may allow for greater versatility in tip rotation as well as projection.³⁴ (See Video 5 [online], which displays a septal extension graft.) There are numerous types of septal extension grafts that serve different functions beyond the scope of this article, including paired spreader grafts, paired batten grafts extending across the caudal and dorsal septum, and direct extension grafts.^{1,5,31,34}

Tip grafts may be required to achieve a refined nasal tip in patients with thick skin. The main variations in tip grafting include infralobular (Sheen),³⁹ onlay (Peck),⁴⁰ cap (Rohrich),³¹ butterfly (Rohrich),^{30,41} or combined (Gunter).³³ Tip grafts can be designed in various shapes, but must have all sharp edges beveled to avoid visibility long term.

ALAR RIMS

Increasingly, the importance of the alar rims and their contribution to the alar-columellar relationship, nasal tip support, and patency of the external nasal valve is being understood.^{33,42,43} The rhinoplasty surgeon should identify and anticipate the potential for deformities of the alar rims such as notching or retraction, soft triangle deformities, malposition of the lateral crura, or external valve collapse.^{1,5,6} A number of techniques serve to strengthen and modify the lateral crura and alar rims including the lateral crural horizontal mattress sutures,^{44,45} lateral crural strut grafts,⁴⁶ batten grafts, lower lateral crural turnover flaps,⁴⁷ and alar contour grafts.^{48,49} Senior author (R.J.R.) uses alar contour grafts in nearly every rhinoplasty to support the alar rims and prevent retraction.⁴⁸ (See Video 6 [online], which displays alar contour graft.)

CLOSURE

The transcolumellar incision is meticulously reapproximated with 6-0 nylon interrupted sutures. A double

hook is used to slightly evert the alar rim to place interrupted chromic sutures in the lateral aspect of the intracartilaginous incision.^{5,6} Medially, 2–3 interrupted sutures are placed. Importantly, the soft tissue triangle and nostril apex are not closed with suture to avoid distortion of these delicate structures. Several small pieces ($4 \times 4 \text{ mm}^2$) of surgicel coated in mupirocin ointment are packed in the nostril apices to eliminate dead space.^{5,6} (See Video 7 [online], which displays nasal closure.)

ALAR BASE

While assessment of alar flare is part of the standard preoperative nasal analysis, the final decision to perform alar flare reduction occurs only after wound closure.^{1,5} The reason for this is because alar flare heavily depends on tip projection, rotation, and by the length/strength of the lateral crura and alar rims. Classification of 3 alar flare types and excision patterns for each have been described by Rohrich et al.⁴³ Importantly, an elliptical design is drawn within the alar groove to minimize scar visibility. The medial extent of the excision should not violate the vestibule as it is undesirable to reduce the nostril aperture for isolated nasal flaring.⁴³ However, if a patient has alar flaring in addition to wide alar base, the alar resection is designed to include the nasal sill.⁵⁰ Closure is obtained with 1 layer of 6-0 nylon externally and 5-0 chromic gut for the vestibular portion.

CONCLUSIONS

Rhinoplasty continues to be among the most challenging procedures for plastic surgeons to develop consistency in. However, with careful preoperative nasofacial analysis and functional assessment, the rhinoplasty surgeon can approach each nasal component systematically. The graduated approaches outlined in this article allow the rhinoplasty surgeon to achieve desired modifications and corrections to the nose while maintaining adequate nasal support and minimizing complications.

Rod J. Rohrich, MD

Dallas Plastic Surgery Institute

9101 N. Central Expressway

Dallas, TX 75231

E-mail: rod.rohrich@dpsi.org

REFERENCES

1. Rohrich RJ, Ahmad J. Rhinoplasty. *Plast Reconstr Surg*. 2011;128:49e–73e.
2. Herruer JM, Prins JB, van Heerbeek N, et al. Negative predictors for satisfaction in patients seeking facial cosmetic surgery: a systematic review. *Plast Reconstr Surg*. 2015;135:1596–1605.
3. Rohrich RJ, Bolden K. Ethnic rhinoplasty. *Clin Plast Surg*. 2010;37:353–370.
4. Guyuron B. Precision rhinoplasty. Part I: the role of life-size photographs and soft-tissue cephalometric analysis. *Plast Reconstr Surg*. 1988;81:489–499.
5. Rohrich RJ, Ahmad J. A practical approach to rhinoplasty. *Plast Reconstr Surg*. 2016;137:725e–746e.
6. Rohrich RJ, Afroz PN. Rhinoplasty refinements: the role of the open approach. *Plast Reconstr Surg*. 2017;140:716–719.

7. Unger JG, Roostaean J, Cheng DH, et al. The open approach in secondary rhinoplasty: choosing an incision regardless of prior placement. *Plast Reconstr Surg.* 2013;132:780–786.
8. Rohrich RJ, McKee D, Malafa M. Closed microfracture technique for surgical correction of inferior turbinate hypertrophy in rhinoplasty: safety and technical considerations. *Plast Reconstr Surg.* 2015;136:607e–611e.
9. Tanna N, Nguyen KT, Ghavami A, et al. Evidence-based medicine: current practices in rhinoplasty. *Plast Reconstr Surg.* 2018;141:137e–151e.
10. Lee MR, Unger JG, Rohrich RJ. Management of the nasal dorsum in rhinoplasty: a systematic review of the literature regarding technique, outcomes, and complications. *Plast Reconstr Surg.* 2011;128:538e–550e.
11. Roostaean J, Unger JG, Lee MR, et al. Reconstitution of the nasal dorsum following component dorsal reduction in primary rhinoplasty. *Plast Reconstr Surg.* 2014;133:509–518.
12. Halewyck S, Michel O, Daele J, et al. A review of nasal dorsal hump reduction techniques, with a particular emphasis on a comparison of component and composite removal. *B-ENT.* 2010;6(Suppl 15):41–48.
13. Afroz PN, Rohrich RJ. The keystone: consistency in restoring the aesthetic dorsum in rhinoplasty. *Plast Reconstr Surg.* 2018;141:355–363.
14. Rohrich RJ, Muzaffar AR, Janis JE. Component dorsal hump reduction: the importance of maintaining dorsal aesthetic lines in rhinoplasty. *Plast Reconstr Surg.* 2004;114:1298–1308; discussion 1309–1212.
15. Mojallal A, Ouyang D, Saint-Cyr M, et al. Dorsal aesthetic lines in rhinoplasty: a quantitative outcome-based assessment of the component dorsal reduction technique. *Plast Reconstr Surg.* 2011;128:280–288.
16. Constantine FC, Ahmad J, Geissler P, et al. Simplifying the management of caudal septal deviation in rhinoplasty. *Plast Reconstr Surg.* 2014;134:379e–388e.
17. Rohrich RJ, Gunter JP, Deuber MA, et al. The deviated nose: optimizing results using a simplified classification and algorithmic approach. *Plast Reconstr Surg.* 2002;110:1509–1523; discussion 1524–1505.
18. Gunter JP, Rohrich RJ. Management of the deviated nose. The importance of septal reconstruction. *Clin Plast Surg.* 1988;15:43–55.
19. Rohrich RJ, Pulikkotil BJ, Stark RY, et al. The importance of the upper lateral cartilage in rhinoplasty. *Plast Reconstr Surg.* 2016;137:476–483.
20. Geissler PJ, Roostaean J, Lee MR, et al. Role of upper lateral cartilage tension spanning suture in restoring the dorsal aesthetic lines in rhinoplasty. *Plast Reconstr Surg.* 2014;133:7e–11e.
21. Rohrich RJ, Krueger JK, Adams WP Jr, et al. Achieving consistency in the lateral nasal osteotomy during rhinoplasty: an external perforated technique. *Plast Reconstr Surg.* 2001;108:2122–2130; discussion 2131.
22. Rohrich RJ, Minoli JJ, Adams WP, et al. The lateral nasal osteotomy in rhinoplasty: an anatomic endoscopic comparison of the external versus the internal approach. *Plast Reconstr Surg.* 1997;99:1309–1312; discussion 1313.
23. Rohrich RJ, Janis JE, Adams WP, et al. An update on the lateral nasal osteotomy in rhinoplasty: an anatomic endoscopic comparison of the external versus the internal approach. *Plast Reconstr Surg.* 2003;111:2461–2462; discussion 2463.
24. Lee MR, Geissler P, Cochran S, et al. Decreasing nasal tip projection in rhinoplasty. *Plast Reconstr Surg.* 2014;134:41e–49e.
25. Rohrich RJ, Griffin JR. Correction of intrinsic nasal tip asymmetries in primary rhinoplasty. *Plast Reconstr Surg.* 2003;112:1699–1712; discussion 1713–1695.
26. Sieber DA, Rohrich RJ. Finesse in nasal tip refinement. *Plast Reconstr Surg.* 2017;140:277e–286e.
27. Ghavami A, Janis JE, Acikel C, et al. Tip shaping in primary rhinoplasty: an algorithmic approach. *Plast Reconstr Surg.* 2008;122:1229–1241.
28. Rohrich RJ, Adams WP Jr. The boxy nasal tip: classification and management based on alar cartilage suturing techniques. *Plast Reconstr Surg.* 2001;107:1849–1863; discussion 1864.
29. Rohrich RJ, Kurkjian TJ, Hoxworth RE, et al. The effect of the columellar strut graft on nasal tip position in primary rhinoplasty. *Plast Reconstr Surg.* 2012;130:926–932.
30. Rohrich RJ, Deuber MA. Nasal tip refinement in primary rhinoplasty: the cephalic trim cap graft. *Aesthet Surg J.* 2002;22:39–45.
31. Toriumi DM. New concepts in nasal tip contouring. *Arch Facial Plast Surg.* 2006;8:156–185.
32. Adams WP Jr, Rohrich RJ, Hollier LH, et al. Anatomic basis and clinical implications for nasal tip support in open versus closed rhinoplasty. *Plast Reconstr Surg.* 1999;103:255–261; discussion 262–254.
33. Gunter JP, Rohrich RJ. Correction of the pinched nasal tip with alar spreader grafts. *Plast Reconstr Surg.* 1992;90:821–829.
34. Ha RY, Byrd HS. Septal extension grafts revisited: 6-year experience in controlling nasal tip projection and shape. *Plast Reconstr Surg.* 2003;112:1929–1935.
35. Guyuron B, DeLuca L, Lash R. Supratip deformity: a closer look. *Plast Reconstr Surg.* 2000;105:1140–1151; discussion 1152–1143.
36. Nagarkar P, Stark RY, Pezeshk RA, et al. Role of the cephalic trim in modern rhinoplasty. *Plast Reconstr Surg.* 2016;137:89–96.
37. Rohrich RJ, Liu JH. The dorsal columellar strut: innovative use of dorsal hump removal for a columellar strut. *Aesthet Surg J.* 2010;30:30–35.
38. Rohrich RJ, Hoxworth RE, Kurkjian TJ. The role of the columellar strut in rhinoplasty: indications and rationale. *Plast Reconstr Surg.* 2012;129:118e–125e.
39. Sheen JH. Achieving more nasal tip projection by the use of a small autogenous vomer or septal cartilage graft. A preliminary report. *Plast Reconstr Surg.* 1975;56:35–40.
40. Peck GC. The onlay graft for nasal tip projection. *Plast Reconstr Surg.* 1983;71:27–39.
41. Rohrich RJ, Afroz PN. The infratip lobule butterfly graft: balancing the transition from the tip lobule to the alar lobule. *Plast Reconstr Surg.* 2018;141:651–654.
42. Unger JG, Roostaean J, Small KH, et al. Alar contour grafts in rhinoplasty: a safe and reproducible way to refine alar contour aesthetics. *Plast Reconstr Surg.* 2016;137:52–61.
43. Rohrich RJ, Malafa MM, Ahmad J, et al. Managing alar flare in rhinoplasty. *Plast Reconstr Surg.* 2017;140:910–919.
44. Gruber RP, Nahai F, Bogdan MA, et al. Changing the convexity and concavity of nasal cartilages and cartilage grafts with horizontal mattress sutures: part I. Experimental results. *Plast Reconstr Surg.* 2005;115:589–594.
45. Gruber RP, Nahai F, Bogdan MA, et al. Changing the convexity and concavity of nasal cartilages and cartilage grafts with horizontal mattress sutures: part II. Clinical results. *Plast Reconstr Surg.* 2005;115:595–606; discussion 607.
46. Gunter JP, Friedman RM. Lateral crural strut graft: technique and clinical applications in rhinoplasty. *Plast Reconstr Surg.* 1997;99:943–952; discussion 953–945.
47. Janis JE, Trussler A, Ghavami A, et al. Lower lateral crural turnover flap in open rhinoplasty. *Plast Reconstr Surg.* 2009;123:1830–1841.
48. Rohrich RJ, Raniere J Jr, Ha RY. The alar contour graft: correction and prevention of alar rim deformities in rhinoplasty. *Plast Reconstr Surg.* 2002;109:2495–2505; discussion 2506.
49. Cochran CS, Sieber DA. Extended alar contour grafts: an evolution of the lateral crural strut graft technique in rhinoplasty. *Plast Reconstr Surg.* 2017;140:559e–567e.
50. Ponsky D, Guyuron B. Alar base disharmonies. *Clin Plast Surg.* 2010;37:245–251.