

Surgical management in hepatocellular carcinoma with portal vein tumour thrombosis: is this the end of the road or a chance to expand the criteria for resectability?

Nikolaos Benatatos¹, Iliana Papadopoulou¹, Stelios F. Assimakopoulos², Francesk Mulita¹, Evangelos Iliopoulos¹, Stylianos Germanos¹, Michail Vailas¹, Christina Kalogeropoulou³, Panagiotis Kitrou⁴, Ioannis Maroulis¹

¹Department of Surgery, University Hospital of Patras, Patras, Greece

²Department of Internal Medicine and Infectious Diseases, University Hospital of Patras, Patras, Greece

³Department of Radiology, University Hospital of Patras, Patras, Greece

⁴Department of Interventional Radiology, University Hospital of Patras, Patras, Greece

Gastroenterology Rev 2022; 17 (4): 257–265
DOI: <https://doi.org/10.5114/pg.2022.118138>

Key words: portal vein, hepatocellular carcinoma, surgical management, tumour thrombus.

Address for correspondence: Dr. Francesk Mulita, Department of Surgery, University Hospital of Patras, Patras, Greece,
e-mail: oknarfmulita@hotmail.com

Abstract

Portal vein thrombosis is a common complication associated with malignancies such as hepatocellular carcinoma, with a dismal and negative impact on prognosis. A thorough literature search in Pubmed and Google Scholar, under the terms 'hepatocellular carcinoma AND portal vein thrombosis', regarding the surgical management of portal vein thrombosis was conducted by the authors, and the associated results are presented in this narrative review. Precise classification of portal vein thrombosis and identification of subgroups of patients that will benefit from surgery is of paramount importance. Evolution of novel surgical techniques in liver resection and associated low morbidity and mortality rates in specialized hepatobiliary centres worldwide have been linked with promising results from the adoption of surgical management in these patients, when compared to systemic chemotherapy or arterial chemoembolization management that has traditionally been followed in such cases.

Introduction

Hepatocellular carcinoma (HCC) is among the five leading causes of cancer-related death worldwide, with mortality rates reaching 6% and with a reported 5-year survival of 18% [1, 2]. Despite the fact that previous SEER registries reported expected HCC rates to continuously increase in the forthcoming decades, the latest data demonstrates that HCC rates declined significantly between 2011 and 2016 [2]. However, taking in consideration that risk factors for HCC are widely known and strict screening protocols are usually implemented to identify early-stage HCC, 70% to 80% of patients are still diagnosed at an advanced stage [3]. Hepatocellular carcinoma is characterized by its propensity to invade the vasculature within the liver, especially portal vein tributaries or even the main trunk of portal vein. Portal

vein tumour thrombosis (PVTT) is the most common form of macrovascular invasion of HCC with a prevalence rate ranging from 10% to over 60% [4–8] and median survival of 2.7–4.0 months, when the tumour remains untreated [8, 9]. On the other hand, a fact that needs to be emphasized is that many cases of portal vein thrombosis in HCC patients are not the result of tumour thrombus. More specifically, cirrhotic patients usually present with non-neoplastic portal vein thrombosis with an incidence that ranges between 0.6% and 11%, and therefore prompt differentiation from PVTT is of great importance [5].

The prognosis of patients with HCC is multifactorial and depends on both tumour and liver factors [10]. Tumour diameter, multifocality, PVTT, and α -fetoprotein (AFP) blood levels are the most important factors re-

lated to prognosis. Among these, PVTT reflects tumour aggressiveness and limits standard treatment options such as liver resection or transplantation. In addition, consequences on residual liver function cannot be overlooked [7, 11]. According to the treatment guidelines of the American Association for the Study of Liver Disease/Barcelona Clinic for Liver Cancer (AASLD/BCLC) Staging System, PVTT is considered an advanced stage of the disease with dismal prognosis, and the proposed treatment options are limited nowadays to chemotherapy, with a median survival time of 10.7 months [6, 12]. Multiple treatment options exist in treating small HCCs in well compensated cirrhosis, classified as extremely early and early stage HCCs. Among these, surgery is seemingly feasible and effective, with more favourable outcomes when compared to non-surgical approaches, achieving 77.2% to 91.5% overall survival [13, 14]. However, to date, the surgical strategy for HCC with PVTT remains controversial. As a result of recent advances in surgical techniques and perioperative management, aggressive surgical resection for HCC with vascular invasion has been proposed, to improve the survival benefit in this group of patients [12, 15–18]. In real-life experience, the adherence to international guidelines for HCC treatment is far from being universally applied, with many surgeons worldwide following personalized approaches on a case-by-case basis. It seems that there is scarce evidence of survival benefit provided by a therapeutic approach of HCC beyond the guidelines if an individualized approach is implemented. Because the nature of advanced HCC remains heterogeneous, there is a need to expand the treatment options of individualized therapeutic strategies applied in selected group of patients [12, 15].

Material and methods

A thorough literature search in PubMed and Google Scholar, under the terms ‘hepatocellular carcinoma AND portal vein thrombosis’ until 31 December 2020, regarding the surgical management of portal vein thrombosis was conducted by the authors, and the associated results are presented in this narrative review.

Discussion

Current stage classification of HCC and controversies of clinical guidelines

Different staging systems exist regarding disease stage classification associated with prognosis and survival in patients with HCC. Each stage has been linked with specific treatment guidelines, and different treatments are offered to different subgroups of patients [19, 20]. Liver transplantation (LT), surgical resection,

and ablation techniques are considered the most effective treatment modalities, which benefit patients with an early-stage tumour (BCLC 0/A). Patients with greater tumour burden confined to the liver (stage BCLC B-C), who are not indicated for radical treatments, could still benefit from local treatments as arterial chemo-radioembolization (TACE-TARE) or oral treatment with the multi-kinase inhibitor (sorafenib) [20]. However, therapeutic algorithms for HCC recommended by international study groups depend on several parameters, such as the scarcity of liver donors for LT, identification or not of early tumours, and the performance status of the patients. These factors play a pivotal role in the risk benefit ratio when non-transplant curative treatments are implemented [20]. Most staging systems classify HCC with PVTT as an advanced-stage disease. Non-surgical treatments, including molecularly targeted therapy, TACE, TARE, or best supportive care, are the main therapeutic methods used in many centres, especially in the West [6]. Moreover, the European Association for the Study of the Liver (EASL) and the American Association for the Study of the Liver (AASLD) guidelines classify HCC with PVTT based on Barcelona Clinical Liver Cancer criteria (BCLC) as stage C, and recommend systemic therapy with sorafenib [14, 21–23]. According to this algorithm, liver resection is not the optimal treatment option for patients with advanced-stage disease. Instead, surgical management is limited to patients with early-stage tumours [24].

On the other hand, there are scientific studies showing that liver resection for HCC with PVTT could provide significant survival benefit and may be advantageous in terms of avoiding liver failure secondary to tumour thrombus [12, 25–27]. Under this view, most medical centres in Asian countries, which have the highest HCC prevalence worldwide, follow approaches expanding EASL/AASLD guidelines. East-Asian countries, through a multidisciplinary approach, have expanded the indications for surgery with satisfactory outcomes in selected patients with BCLC stage C against sorafenib monotherapy [22, 28, 29]. According to different study groups, the benefits of liver resection have been accepted for selected patients with HCC harbouring PVTT and are implemented in their treatment guidelines [30–32]. Moreover, the recent management guidelines from the AASLD recognize that the definition of operability and resectability is quite heterogeneous and could differ significantly in clinical practice. A growing body of evidence shows a potential advantage of resection beyond early BCLC stages, so the role of strict treatment guidelines needs to be reconsidered among pioneers worldwide. In high-volume centres, different treatments are assigned to different groups of patients, creating

a great overlap between recommended therapies and prognostic stages in daily clinical practice [14, 24, 33].

Mechanisms of PVTT formation

The mechanism of PVTT formation is not entirely understood and until recently has not been elucidated. Many factors are implicated in this process, with haemodynamic and biological factors playing an important role. Among researchers, the mechanical force seems to be of greater importance when compared to biological cancer cell factors to determine the metastatic route. Apart from the traditional belief that cancer cells directly infiltrate the venous wall and grow into the portal vein, researchers have identified PVTT distant from liver tumours, demonstrating that the mechanism is much more complex [34]. It has been advocated that a tumour microenvironment in cirrhotic patients plays a major role, and not only genetic or biological factors influence the pattern of vascular invasion. The complex mechanism of PVTT is associated with hepatic artery-portal fistula (HAPVF) and a portal vein counter current (PVCC) and this hypothesis has been demonstrated in PVTT patients before [35].

PVCC mechanisms of formation can be briefly summarized as follows: HCC nodules might block central veins and feeding arteries to the cancer nodules, which communicate with small portal branches. The high pressure creates a system with regional portal hypertension and increased pressure in sinusoids, which in turn causes HAPVF and PVCC. Tumour vessels transform into drainage channels, and cancer cells migrate intra-hepatically through these reversal blood flows. These cells are prone to implantation in the obstructed portal vein branches [36]. On the other hand, the biology of the tumour cell exhibits functions that are not entirely understood. This is probably the reason why HCC patients rarely present with splenic or hepatic vein thrombosis. Studies have shown that portal vein blood inhibits the apoptosis and promotes the migration and invasion of CSQT-2 cells. In addition, portal vein blood could up-regulate the expression of matrix metalloproteinase-2

(MMP-2), which is considered to be strongly associated with tumour metastasis [37]. Moreover, lower concentrations of IL-12 in portal vein serum could be linked with a negative effect on the apoptosis of PVTT-originated cells. The aforementioned molecular alterations suggest that the microenvironment of the portal venous system could enhance the infiltrative capacity of HCC cells. Additionally, the transformation of macrophages activated by the tumour environment and the release of several growth factors that could promote tumour metastasis need to be further studied [34, 35].

Classification of PVTT

In the presence of PVTT a careful selection is paramount, when curative aggressive invasive treatment is advocated. To be able to identify subgroups of patients who could benefit from surgery, a universal classification of PVTT is required. Various classification systems have been used by several centers especially in the East, where major complicated operations for advanced stage HCC are more often performed. In this regard the Liver Cancer Study Group of Japan (LCSGJ) developed a macroscopic classification of HCC with PVTT: Vp0, no PVTT; Vp1, a PVTT distal to, but not in, the second-order branches of the portal vein; Vp2, PVTT in the second-order branches; Vp3, the presence of a PVTT in the first-order branches; and Vp4, the presence of a PVTT in the main portal vein or a contralateral portal vein branch or both [31]. For the first 2 stages surgical resection was deemed a feasible approach, while selected Vp3 or Vp4 patients could receive surgical resection with a 5-year survival of 18.3% [31, 38] (Table I). Further attempts to correlate overall survival and the stage of PVTT after liver resection have been proposed. Shi *et al.* have classified PVTT, known as Cheng's classification, including stages from type I to type IV according to PVTT extension (Table II) [39]. The 1-, 2-, and 3-year OS rates were 54.8%, 33.9%, and 26.7% for type I patients, respectively. For type II the OS was 36.4%, 24.9%, and 16.9% respectively; 25.9%, 12.9%, and 3.7% for type 3 patients, respectively; and 11.1%, 0%, and 0%, respec-

Table I. Classification status of PVTT in HCC according to current available systems

Author [ref.]	Microscopic PVTT	Segmental branch	2 nd order PV branch	Left or right PV	Main PV	SMV
Shi [39]	IO		I	II	III	IV
Kudo [31]		Vp1	Vp2	Vp3	Vp4	
Xu [40]			B		A (or both L/R PV)	
Chen [41]			A	A (< 1 cm of resection line)	B (or > 1 cm of resection line)	
Fukumoto [22]		Floating	Floating/expansive		Expansive	

Table II. Cheng's classification of PVTT

Types	Subtypes
Type IO: PVTT found under microscopy	
Type I: PVTT in segmental branches or above	Type Ia: segmental or above Type Ib: segmental branches extending to sectoral branch
Type II: PVTT involving right/left portal vein	Type IIa: PVTT right/left portal vein Type IIb: PVTT involving both left and right portal veins
Type III: PVTT involving the main portal vein trunk	Type IIIa: main portal vein trunk for no more than 2 cm below the confluence Type IIIb: main portal vein trunk for more than 2 cm below the confluence
Type IV: Tumour thrombi involving SMV	

tively, for type 4 patients ($p < 0.0001$) [39]. Furthermore, Xu *et al.* have simplified the classification of PVTT into 2 groups: group A, with involvement of the main portal vein trunk or both the left and right portal veins, and Group B, with involvement only of the left or right portal vein [40]. The results regarding OS were 31.5% for group A after resection, while for group B they were 62.3%, 16.1%, and 5.2% in 1, 3, and 5 years. Similarly, Chen *et al.* divided PVTT patients into group A, with tumour thrombus located in the hepatic resection area or protruding into the first branch of the main portal vein beyond the resection line for < 1 cm, and group B, with PVTT extended into the main portal vein [41]. PVTT recurrence within 6 months after surgery in group B was significantly higher than that in group A: 76.9% vs. 11.3%, respectively. In addition, Fukumoto *et al.* divided macroscopically PVTT into “expansive” and “floating” type depending on how proximally or distally to the main portal trunk it has occurred and if the relative vessel maintains its original vascular calibre [22]. For example, in an expansive growth, the diameter of the portal vein becomes much larger than the calibre of the original one. This has implications in the surgical technique of liver resection and thrombectomy [22]. Most of the classifications offer the advantages of a relatively precise topographic staging in combination with ascending degree of severity. The surgical approach relies upon the type of PVTT, and so does the prognosis, which is determined from the extent of the thrombosis [42].

Surgical efficacy vs. non-surgical treatments

Several modalities have been attempted to increase survival in HCC patients with PVTT [43]. In a Japanese nationwide survey, survival rates at 1, 3, and 5 years after initial diagnosis for the surgical group of patients was significantly higher compared to the non-surgical treatment group, with survival rates being 70.9%, 43.5%, and 32.9% vs. 62.9%, 31.6%, and 20.1%, re-

spectively. Even if the surgical treatment has reached a survival benefit independently from other prognostic factors such as tumour size or aetiology, which was not significant in the advance stage of PVTT. Thus, liver resection was recommended when PVTT was limited to the first-order branch of the portal vein [12, 28, 31, 38]. In another large cohort study from China, the median survival time for type I and II patients were 15.9 and 12.5 months, respectively, with better results than non-surgical treatments [44]. Several other studies presented comparable results while suggesting that type IV patients are not qualified for surgery [18, 42, 45, 46]. Furthermore, attempts to compare TACE to surgical treatment showed better prognosis in the surgical group for type I/II, but not for type III/IV [44, 47–49]. A combination of preoperative TACE with surgery seems promising but failed to achieve a survival benefit for advance stage PVTT [15, 50–52]. Several existing meta-analyses including BCLC B patients have reported 5-year survival rates for surgery vs. TACE at 45% vs. 23%, respectively, and OS higher in liver resection than in TACE. Moreover, there has been no reliable study comparing resection or TACE with systemic target therapy for BCLC stage-C HCC patients. Therefore, surgery should be considered a therapeutic option tailored to a carefully selected group of BCLC stage-B HCC patients with well-preserved liver function [24, 53–55]. Another meta-analysis showed that HCC patients with branch type PVTT and surgery had better result in terms of prognosis, but showed no benefit over TACE or sorafenib in patients with main PVTT [56–59], whereas other published studies showed that TACE is associated with similar outcomes when treating patients with type III PVTT ($p = 0.541$) [60]. In Western countries, conversely, the first-line treatment option for HCC-PVTT is sorafenib, with median survival 10.7 months (6.5 months in Eastern countries) [46]. Even if the efficacy of sorafenib is not well established in PVTT patients, an OS of 8.1 months was demonstrated [61],

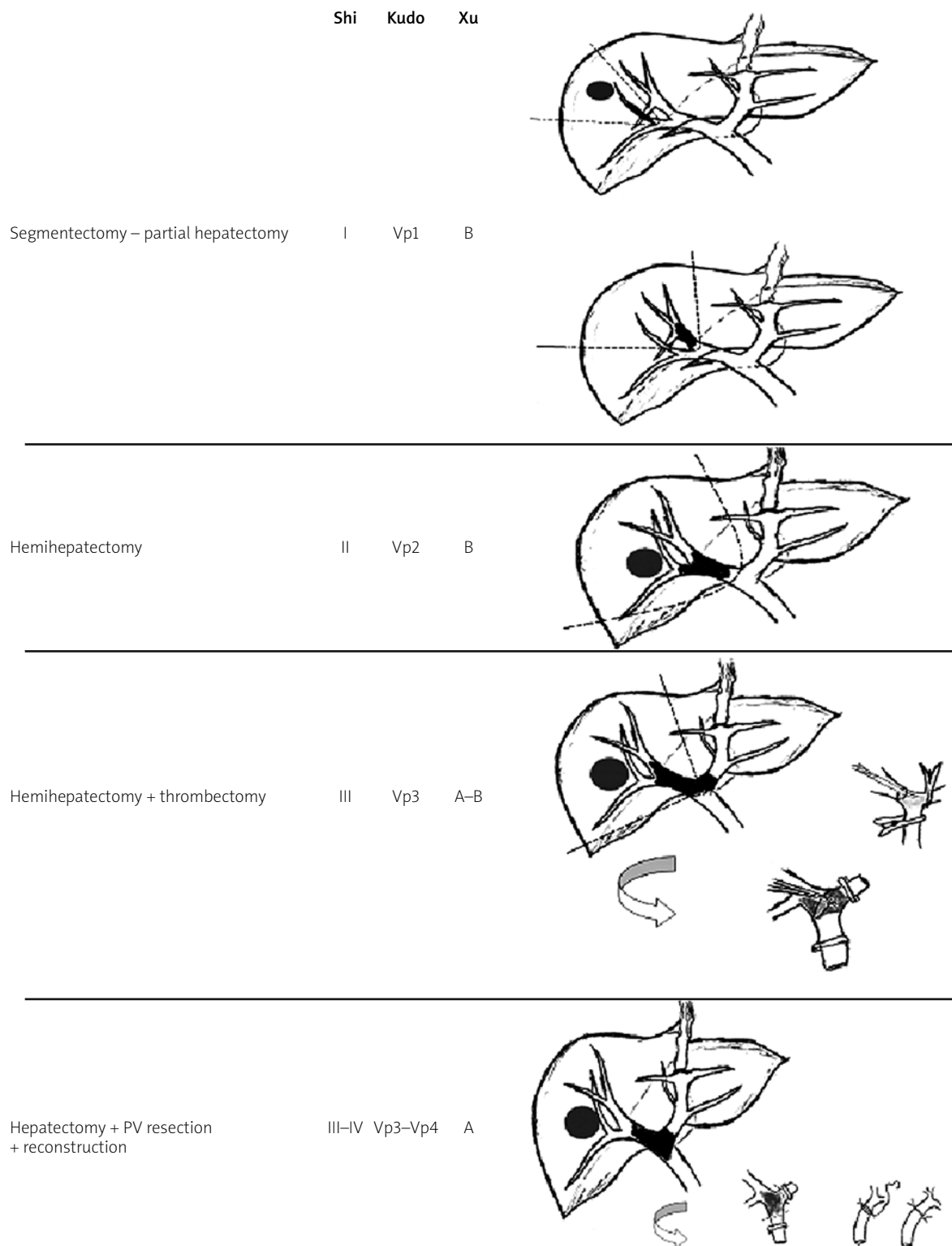


Figure 1. Patterns of tumour thrombus and proposed surgical techniques relative to PVTT classification (author's work)

while in an Asia-Pacific trial [62, 63], sorafenib was associated with modest prolongation of survival (5.6 vs. 4.1 months).

In addition, the effect of radiotherapy compared to surgery in a subgroup analysis showed that the 2-year OS in type I PVTT receiving 3D conformal radiotherapy (CRT) and surgery are 39% and 53%, respectively, ($p < 0.001$) indicating that surgery is superior to radiotherapy in terms of efficacy, while in type II PVTT the effect of both modalities was similar [64]. While modern radiotherapy, particularly in combination with other treatment options, may be feasible for HCC patients with PVTT, additional evidence is needed to confirm a survival benefit [63].

Surgical methods and techniques

Even though non-surgical treatment is recommended in HCC with PVTT patients, liver resection could be proposed in carefully selected cases based on the available scientific data. Decreased portal pressure after removal of the tumour thrombus might improve liver function and quality of life and potentially prolong survival [39, 57]. Taking into account data that report median survival for type I-IV PVTT of 6.2 to 64 months in patients who underwent resection and around 3 months for conservative treatments in type I-II, it seems reasonable that resection pathways might be the most promising option to follow [13, 65]. However, surgery due to technical challenges along with the underlying cirrhosis has been limited historically to patients with PVTT distally to the first-order branch [63, 66–68].

Child status, extrahepatic spread, classification of PVTT, and total removal of thrombus are parameters that need to be carefully considered before offering aggressive surgical treatment [36, 44]. There is still some controversy regarding the theoretical advantage of anatomical resection to non-anatomical because anatomical resection can remove satellite lesions along the portal peripheral branches, but the significance has not been established in current practice. As a result, several surgical techniques have been introduced. Depending on the level of thrombus to the liver resection line, en bloc resection could be achieved. For example, for Cheng's type I PVTT a segmentectomy could be performed, while a formal hemihepatectomy is indicated for a type II. On the other hand, if PVTT extends the resection line (type III/IV), hepatectomy and thrombectomy plus portal vein reconstruction is a suitable technique [44, 46].

Major liver resections, however, according to PVTT extension, could impair liver function, and for this reason en bloc resections are occasionally abandoned. In the so-called peeling off (PO) technique, the thrombus

is removed from the internal wall of the portal veins along with sparing parenchyma tumour resection. In this manner portal vein reconstruction is not necessary, and the liver function could be maintained because lesser resections are applied. This approach is supported by the hypothesis that the risk of cancer spread could not be higher because the blood flow is already exposed to tumour cells and because tumour thrombus rarely infiltrates the portal vein wall [17]. Inoue *et al.* [17] presented satisfactory results with 3- and 5-year OS rates for the PO group of 46% and 39%, respectively, which is comparable with those of the en bloc group (41% and 41%). Excellent results have been presented regarding this type of thrombectomy, with 5-year survival rates in Vp3 and Vp4 of up to 21.2% and with no difference in terms of long-term outcomes [69]. Conversely, Zhang *et al.* [70] showed a significantly increased recurrence rate of vascular invasion when compared with the en bloc group (23.9% vs. 9.7%, respectively, $p = 0.005$).

In addition, the back flow technique introduced by Fukumoto *et al.* [22], treating patients with contralateral first portal branch PVTT with crushing and suctioning using the back-flow pressure of the portal system, has been linked with 1-, 3-, and 5-year OS rates of 53.6, 15.3, and 7.7%, respectively. Ban *et al.* [69] improved the outcomes in type Vp3/Vp4 patients with the 'thrombectomy first' technique, presenting 1-, 3-, and 5-year survival rates of 69.6%, 37.4%, and 22.4%, respectively. Even if in the aforementioned studies the results regarding the recurrence at liver remnant, residual vein tumour, and disseminated peritoneal disease are promising, further studies are needed to confirm and justify these outcomes [16, 17, 27, 70, 71]. Based on the location and extent of PVTT, commonly used surgical methods are summarized in (Figure 1). As stated, surgery could be feasible and effective in advance stages of HCC and should be considered on a case-by-case basis. Clinicians should be aware of the disadvantages of various strategies and the relatively aggressive approach must be tailored to each patient [72–79].

Conclusions

Patients harbouring HCC with PVTT present more often with complications related to the degree of cirrhosis, and they have a worse prognosis. The accuracy of the classification of PVTT is paramount when aggressive surgical treatment has been anticipated. Careful appreciation of predictors that are associated with dismal prognosis is necessary before planning major resection. Combination treatment strategies as a feasible treatment modality should be performed after careful selection. Furthermore, the implementation of down-

staging techniques could increase the pool of patients who could benefit from surgery afterwards. Despite the fact that PVTT is a major prognostic factor, efforts to improve prognosis in such patients rendering the necessity to implement liver resection in future treatment guidelines must be seriously considered. Well-designed studies should focus on this issue, comparing surgery to other treatment strategies with the aim of improving outcomes, increasing the pool of patients to be treated, and reducing tumour recurrence. In the future, a combination of biomarkers, sophisticated imaging, and individualized treatment according to the extent of PVTT could add more than just an improvement in quality of life in these patients.

Conflict of interest

The authors declare no conflict of interest.

References

1. Siegel RL, Miller KD, Jemal A. Cancer statistics, 2020. *CA Cancer J Clin* 2020; 70: 7-30.
2. Petrick JL, Florio AA, Loomba R, McGlynn KA. Have incidence rates of liver cancer peaked in the United States? *Cancer* 2020; 126: 3151-5.
3. Cheng S, Chen M, Cai J; National Research Cooperative Group for Diagnosis and Treatment of Hepatocellular Carcinoma with Tumor Thrombus. Chinese expert consensus on multidisciplinary diagnosis and treatment of hepatocellular carcinoma with portal vein tumor thrombus: 2016 edition. *Oncotarget* 2017; 8: 8867-76.
4. Poon RT, Fan ST, Lo CM, et al. Intrahepatic recurrence after curative resection of hepatocellular carcinoma: long-term results of treatment and prognostic factors. *Ann Surg* 1999; 229: 216-22.
5. Chan SL, Chong CC, Chan AW, et al. Management of hepatocellular carcinoma with portal vein tumor thrombosis: review and update at 2016. *World J Gastroenterol* 2016; 22: 7289-300.
6. Llovet JM, Bustamante J, Castells A, et al. Natural history of untreated nonsurgical hepatocellular carcinoma: rationale for the design and evaluation of therapeutic trials. *Hepatology* 1999; 29: 62-7.
7. Quirk M, Kim YH, Saab S, Lee EW. Management of hepatocellular carcinoma with portal vein thrombosis. *World J Gastroenterol* 2015; 21: 3462-71.
8. Pirisi M, Avellini C, Fabris C, et al. Portal vein thrombosis in hepatocellular carcinoma: age and sex distribution in an autopsy study. *J Cancer Res Clin Oncol* 1998; 124: 397-400.
9. Huo L, Wei W, Yan Z, et al. Short-term and long-term outcomes of liver resection for HCC patients with portal vein tumor thrombus. *Cell Biosci* 2019; 9: 23.
10. Carr BI, Pancoska P, Branch RA. Tumor and liver determinants of prognosis in unresectable hepatocellular carcinoma: a large case cohort study. *Hepatol Int* 2009; 4: 396-405.
11. Akkiz H, Carr BI, Kuran S, et al. Macroscopic portal vein thrombosis in HCC patients. *Can J Gastroenterol Hepatol* 2018; 2018: 3120185.
12. Kokudo T, Hasegawa K, Matsuyama Y, et al.; Liver Cancer Study Group of Japan. Survival benefit of liver resection for hepatocellular carcinoma associated with portal vein invasion. *J Hepatol* 2016; 65: 938-43.
13. Ho MC, Hasegawa K, Chen XP, et al. Surgery for intermediate and advanced hepatocellular carcinoma: a Consensus Report from the 5th Asia-Pacific Primary Liver Cancer Expert Meeting (APPLE 2014). *Liver Cancer* 2016; 5: 245-56.
14. Heimbach JK, Kulik LM, Finn RS, et al. AASLD guidelines for the treatment of hepatocellular carcinoma. *Hepatology* 2018; 67: 358-80.
15. Yamamoto Y, Ikoma H, Morimura R, et al. Post-hepatectomy survival in advanced hepatocellular carcinoma with portal vein tumor thrombosis. *World J Gastroenterol* 2015; 21: 246-53.
16. Shaohua L, Qiaoxuan W, Peng S, et al. Surgical strategy for hepatocellular carcinoma patients with portal/hepatic vein tumor thrombosis. *PLoS One* 2015; 10: e0130021.
17. Inoue Y, Hasegawa K, Ishizawa T, et al. Is there any difference in survival according to the portal tumor thrombectomy method in patients with hepatocellular carcinoma? *Surgery* 2009; 145: 9-19.
18. Minagawa M, Makuuchi M. Treatment of hepatocellular carcinoma accompanied by portal vein tumor thrombus. *World J Gastroenterol* 2006; 12: 7561-7.
19. Forner A, Llovet JM, Bruix J. Hepatocellular carcinoma. *Lancet* 2012; 379: 1245-55.
20. Sangiovanni A, Triolo M, Iavarone M, et al. Multimodality treatment of hepatocellular carcinoma: how field practice complies with international recommendations. *Liver Int* 2018; 38: 1624-34.
21. Bruix J, Sherman M; American Association for the Study of Liver Diseases. Management of hepatocellular carcinoma: an update. *Hepatology* 2011; 53: 1020-2.
22. Fukumoto T, Kido M, Takebe A, et al. New macroscopic classification and back-flow thrombectomy for advanced hepatocellular carcinoma with portal vein tumor thrombus invading the contralateral second portal branch. *Surg Today* 2017; 47: 1094-103.
23. Vitale A, Burra P, Frigo AC, et al. Italian Liver Cancer (ITA.LI.CA) group. Survival benefit of liver resection for patients with hepatocellular carcinoma across different Barcelona Clinic Liver Cancer stages: a multicentre study. *J Hepatol* 2015; 62: 617-24.
24. Hyun MH, Lee YS, Kim JH, et al. Hepatic resection compared to chemoembolization in intermediate- to advanced-stage hepatocellular carcinoma: a meta-analysis of high-quality studies. *Hepatology* 2018; 68: 977-93.
25. Chen JS, Wang Q, Chen XL, et al. Clinicopathologic characteristics and surgical outcomes of hepatocellular carcinoma with portal vein tumor thrombosis. *J Surg Res* 2012; 175: 243-50.
26. Lin DX, Zhang QY, Li X, et al. An aggressive approach leads to improved survival in hepatocellular carcinoma patients with portal vein tumor thrombus. *J Cancer Res Clin Oncol* 2011; 137: 139-49.
27. Higaki T, Yamazaki S, Moriguchi M, et al. Indication for surgical resection in patients with hepatocellular carcinoma with major vascular invasion. *Biosci Trends* 2017; 11: 581-7.
28. Cheng S, Yang J, Shen F, et al. Multidisciplinary management of hepatocellular carcinoma with portal vein tumor thrombus – Eastern Hepatobiliary Surgical Hospital consensus statement. *Oncotarget* 2016; 7: 40816-29.

29. Woo HY, Heo J. New perspectives on the management of hepatocellular carcinoma with portal vein thrombosis. *Clin Mol Hepatol* 2015; 21: 115-21.
30. Omata M, Lesmana LA, Tateishi R, et al. Asian Pacific Association for the Study of the Liver consensus recommendations on hepatocellular carcinoma. *Hepatol Int* 2010; 4: 439-74.
31. Kudo M, Matsui O, Izumi N, et al.; Liver Cancer Study Group of Japan. JSH Consensus-Based Clinical Practice Guidelines for the Management of Hepatocellular Carcinoma: 2014 Update by the Liver Cancer Study Group of Japan. *Liver Cancer* 2014; 3: 458-68.
32. Korean Liver Cancer Study Group (KLCSG); National Cancer Center, Korea (NCC). 2014 KLCSG-NCC Korea Practice Guideline for the Management of Hepatocellular Carcinoma. *Gut Liver* 2015; 9: 267-317.
33. Bolondi L, Burroughs A, Dufour JF, et al. Heterogeneity of patients with intermediate (BCLC B) Hepatocellular Carcinoma: proposal for a subclassification to facilitate treatment decisions. *Semin Liver Dis* 2012; 32: 348-59.
34. Sun JX, Shi J, Li N, et al. Portal vein tumor thrombus is a bottleneck in the treatment of hepatocellular carcinoma. *Cancer Biol Med* 2016; 13: 452-8.
35. Liu Q, Zhang A, Xu W, Dong J. A new view of the roles of blood flow dynamics and Kupffer cell in intra-hepatic metastasis of hepatocellular carcinoma. *Med Hypotheses* 2011; 77: 87-90.
36. Wang JC, Xia AL, Xu Y, Lu XJ. Comprehensive treatments for hepatocellular carcinoma with portal vein tumor thrombosis. *J Cell Physiol* 2019; 234: 1062-70.
37. Tang Y, Yu H, Zhang L, et al. Experimental study on enhancement of the metastatic potential of portal vein tumor thrombus-originated hepatocellular carcinoma cells using portal vein serum. *Chin J Cancer Res* 2014; 26: 588-95.
38. Kudo M, Kitano M, Sakurai T, Nishida N. General rules for the clinical and pathological study of primary liver cancer, nationwide follow-up survey and clinical practice guidelines: the outstanding achievements of the Liver Cancer Study Group of Japan. *Dig Dis* 2015; 33: 765-70.
39. Shi J, Lai EC, Li N, et al. A new classification for hepatocellular carcinoma with portal vein tumor thrombus. *J Hepatobiliary Pancreat Sci* 2011; 18: 74-80.
40. Xu JF, Liu XY, Wang S, Wen HX. Surgical treatment for hepatocellular carcinoma with portal vein tumor thrombus: a novel classification. *World J Surg Oncol* 2015; 13: 86.
41. Chen XP, Qiu FZ, Wu ZD, et al. Effects of location and extension of portal vein tumor thrombus on long-term outcomes of surgical treatment for hepatocellular carcinoma. *Ann Surg Oncol* 2006; 13: 940-6.
42. Chan SL, Chong CC, Chan AW, et al. Management of hepatocellular carcinoma with portal vein tumor thrombosis: review and update at 2016. *World J Gastroenterol* 2016; 22: 7289-300.
43. Takizawa D, Kakizaki S, Sohara N, et al. Hepatocellular carcinoma with portal vein tumor thrombosis: clinical characteristics, prognosis, and patient survival analysis. *Dig Dis Sci* 2007; 52: 3290-5.
44. Wang K, Guo WX, Chen MS, et al. multimodality treatment for hepatocellular carcinoma with portal vein tumor thrombus: a large-scale, multicenter, propensity matching score analysis. *Medicine* 2016; 95: e3015.
45. Shi J, Lai EC, Li N, et al. Surgical treatment of hepatocellular carcinoma with portal vein tumor thrombus. *Ann Surg Oncol* 2010; 17: 2073-80.
46. Peng SY, Wang XA, Huang CY, et al. Better surgical treatment method for hepatocellular carcinoma with portal vein tumor thrombus. *World J Gastroenterol* 2018; 24: 4527-35.
47. Peng ZW, Guo RP, Zhang YJ, et al. Hepatic resection versus transcatheter arterial chemoembolization for the treatment of hepatocellular carcinoma with portal vein tumor thrombus. *Cancer* 2012; 118: 4725-36.
48. Liu PH, Lee YH, Hsia CY, et al. Surgical resection versus transarterial chemoembolization for hepatocellular carcinoma with portal vein tumor thrombosis: a propensity score analysis. *Ann Surg Oncol* 2014; 21: 1825-33.
49. Zheng N, Wei X, Zhang D, et al. Hepatic resection or transarterial chemoembolization for hepatocellular carcinoma with portal vein tumor thrombus. *Medicine* 2016; 95: e3959.
50. Chong JU, Choi GH, Han DH, et al. Downstaging with localized concurrent chemoradiotherapy can identify optimal surgical candidates in hepatocellular carcinoma with portal vein tumor thrombus. *Ann Surg Oncol* 2018; 25: 3308-15.
51. Li N, Feng S, Xue J, et al. Hepatocellular carcinoma with main portal vein tumor thrombus: a comparative study comparing hepatectomy with or without neoadjuvant radiotherapy. *HPB* 2016; 18: 549-56.
52. Ye JZ, Zhang YQ, Ye HH, et al. Appropriate treatment strategies improve survival of hepatocellular carcinoma patients with portal vein tumor thrombus. *World J Gastroenterol* 2014; 20: 17141-7.
53. Chen J, Huang J, Chen M, et al. Transcatheter arterial chemoembolization (TACE) versus hepatectomy in hepatocellular carcinoma with macrovascular invasion: a meta-analysis of 1683 patients. *J Cancer* 2017; 8: 2984-91.
54. Qi X, Wang D, Su C, et al. Hepatic resection versus transarterial chemoembolization for the initial treatment of hepatocellular carcinoma: a systematic review and meta-analysis. *Oncotarget* 2015; 6: 18715-33.
55. Liu W, Zhou JG, Sun Y, et al. Hepatic resection improved the long-term survival of patients with BCLC stage B hepatocellular carcinoma in Asia: a systematic review and meta-analysis. *J Gastrointest Surg* 2015; 19: 1271-80.
56. Zhang ZY, Dong KS, Zhang EL, et al. Resection might be a meaningful choice for hepatocellular carcinoma with portal vein thrombosis: a systematic review and meta-analysis. *Medicine* 2019; 98: e18362.
57. Liang L, Chen TH, Li C, et al. A systematic review comparing outcomes of surgical resection and non-surgical treatments for patients with hepatocellular carcinoma and portal vein tumor thrombus. *HPB* 2018; 20: 1119-29.
58. Yu JI, Choi GS, Lim DH, et al. Treatment of naïve HCC combined with segmental or subsegmental portal vein tumor thrombosis: liver resection versus TACE followed by radiotherapy. *Anti-cancer Res* 2018; 38: 4919-25.
59. Yin L, Li H, Li AJ, et al. Partial hepatectomy vs. transcatheter arterial chemoembolization for resectable multiple hepatocellular carcinoma beyond Milan Criteria: a RCT. *J Hepatol* 2014; 61: 82-8.
60. Zhang XP, Wang K, Li N, et al. Survival benefit of hepatic resection versus transarterial chemoembolization for hepatocellular

- carcinoma with portal vein tumor thrombus: a systematic review and meta-analysis. *BMC Cancer* 2017; 17: 902.
61. Bruix J, Raoul JL, Sherman M, et al. Efficacy and safety of sorafenib in patients with advanced hepatocellular carcinoma: subanalyses of a phase III trial. *J Hepatol* 2012; 57: 821-9.
62. Cheng AL, Guan Z, Chen Z, et al. Efficacy and safety of sorafenib in patients with advanced hepatocellular carcinoma according to baseline status: subset analyses of the phase III Sorafenib Asia-Pacific trial. *Eur J Cancer* 2012; 48: 1452-65.
63. Liu PH, Huo TI, Miksad RA. Hepatocellular carcinoma with portal vein tumor involvement: best management strategies. *Semin Liver Dis* 2018; 38: 242-51.
64. Su F, Chen KH, Liang ZG, et al. Comparison of three-dimensional conformal radiotherapy and hepatic resection in hepatocellular carcinoma with portal vein tumor thrombus. *Cancer Med* 2018; 7: 4387-95.
65. Zhang ZM, Lai EC, Zhang C, et al. The strategies for treating primary hepatocellular carcinoma with portal vein tumor thrombus. *Int J Surg* 2015; 20: 8-16.
66. Kumada K, Ozawa K, Okamoto R, et al. Hepatic resection for advanced hepatocellular carcinoma with removal of portal vein tumor thrombi. *Surgery* 1990; 108: 821-7.
67. Zhong JH, Rodríguez AC, Ke Y, et al. Hepatic resection as a safe and effective treatment for hepatocellular carcinoma involving a single large tumor, multiple tumors, or macrovascular invasion. *Medicine* 2015; 94: e396.
68. Ohkubo T, Yamamoto J, Sugawara Y, et al. Surgical results for hepatocellular carcinoma with macroscopic portal vein tumor thrombosis. *J Am Coll Surg* 2000; 191: 657-60.
69. Ban D, Shimada K, Yamamoto Y, et al. Efficacy of a hepatectomy and a tumor thrombectomy for hepatocellular carcinoma with tumor thrombus extending to the main portal vein. *J Gastrointest Surg* 2009; 13: 1921-8.
70. Zhang YF, Le Y, Wei W, et al. Optimal surgical strategy for hepatocellular carcinoma with portal vein tumor thrombus: a propensity score analysis. *Oncotarget* 2016; 7: 38845-56.
71. Ye HH, Ye JZ, Xie ZB, et al. Comprehensive treatments for hepatocellular carcinoma with tumor thrombus in major portal vein. *World J Gastroenterol* 2016; 22: 3632-43.
72. Matono R, Yoshiya S, Motomura T, et al. Factors linked to longterm survival of patients with hepatocellular carcinoma accompanied by tumour thrombus in the major portal vein after surgical resection. *HPB* 2012; 14: 247-53.
73. Mähringer-Kunz A, Steinle V, Düber C, et al. Extent of portal vein tumour thrombosis in patients with hepatocellular carcinoma: the more, the worse? *Liver Int* 2019; 39: 324-31.
74. Vailas M, Sotiropoulou M, Benetatos N, et al. Chyle leak after major pancreatic surgery. Is this an underestimated complication? A narrative review of the literature. *J BUON* 2021; 26: 1747-53.
75. Markopoulos G, Mulita F, Kehagias D, et al. Outcomes of percutaneous cholecystostomy in elderly patients: a systematic review and meta-analysis. *Gastroenterology Rev* 2021; 16: 188-95.
76. Kehagias D, Mulita F, Maroulis I, Benetatos N. Caudate lobe: the last barrier – an unusual place for a foreign body. *ANZ J Surg* 2022; 92: 1218-20.
77. Mulita F, Benetatos N, Maroulis I, Germanos S. Enlarged cystic artery. *BMJ Case Rep* 2021; 14: e240056.
78. Papadoulas S, Moulakakis K, Kouri N, et al. Iatrogenic tibial arteriovenous fistula after Fogarty balloon catheter graft thrombectomy. *Clin Case Rep* 2021; 9: e05050.
79. Papadoulas S, Kouri N, Mulita F, Katsanos K. Adjunctive vacuum-assisted aspiration thrombectomy in a patient with acute limb ischaemia and peronea arteria magna. *BMJ Case Rep* 2021; 14: e245490.

Received: 11.04.2022

Accepted: 19.05.2022