

Mediastinum & Esophagus: Case Report

Butterfly-Shaped Epicardial Lipoma of the Heart



Polyxeni Vlachea, MD,¹ Klaus Wenke, MD,¹
Kun Lu, MD,^{1,2} Christian Hagl, MD,^{1,2}
Gerd Juchem, MD,¹ and
Florian E. M. Herrmann, MD^{1,2}

Cardiac tumors are a rare entity with typically unspecific symptoms. We present the case of a 43-year old female patient with epigastric pain and palpitations with a long history of diagnostics prior to discovery of an epicardial mass. The epicardial tumor with arterial vascularization from the left anterior descending artery was resected in a beating heart procedure and was found to be a lipomatous soft tissue tumor. A lack of mouse double minute 2 gene amplification in fluorescent in situ hybridization confirmed the diagnosis of a benign cardiac lipoma. Resection led to a long-term resolution of symptoms.

(Ann Thorac Surg Short Reports 2024;2:695-698)

© 2024 The Authors. Published by Elsevier Inc. on behalf of The Society of Thoracic Surgeons. This is an open access article under the CC BY-NC-ND license (<http://creativecommons.org/licenses/by-nc-nd/4.0/>).

The first case of a cardiac tumor was documented 1559.¹ Since then an array of different tumors affecting the heart have been identified. The prevalence of primary cardiac tumors is estimated to be between 0.17% and 0.19%.² Among primary cardiac tumors, lipomas account for approximately 8% to 10%.^{3,4} While cardiac tumors remain rare, they are a relevant differential diagnosis in patients with unspecific symptoms attributed to the heart.⁴ Symptoms may mimic those of valvular heart disease, congestive heart disease, pulmonary or systemic embolism, or symptoms of arrhythmia. Like all tumors they can be classified as primary or secondary tumors. Primary forms can be

benign (eg, myxoma or papillary fibroelastoma) or malignant (eg, angiosarcoma) and develop in the heart itself. The majority of primary cardiac tumors are benign. Secondary forms are metastatic tumors that have spread by direct contact or venous spread (eg, melanoma or carcinomas of the breast, lung, and other organs). Metastatic involvement of the heart is mostly associated with end stage disease and subsequently high mortality.

Lipomas of the heart are benign primary tumors and can undergo malignant transformation to malignant liposarcoma. While liposarcomas have a dire outcome, the benign lipoma usually does not. However, lipomas can also cause intracavitary obstruction or compression and arrhythmias, which may also lead to morbidity and mortality.³ Subsequently, even benign cardiac lipoma may require operative treatment to improve the patient's prognosis.

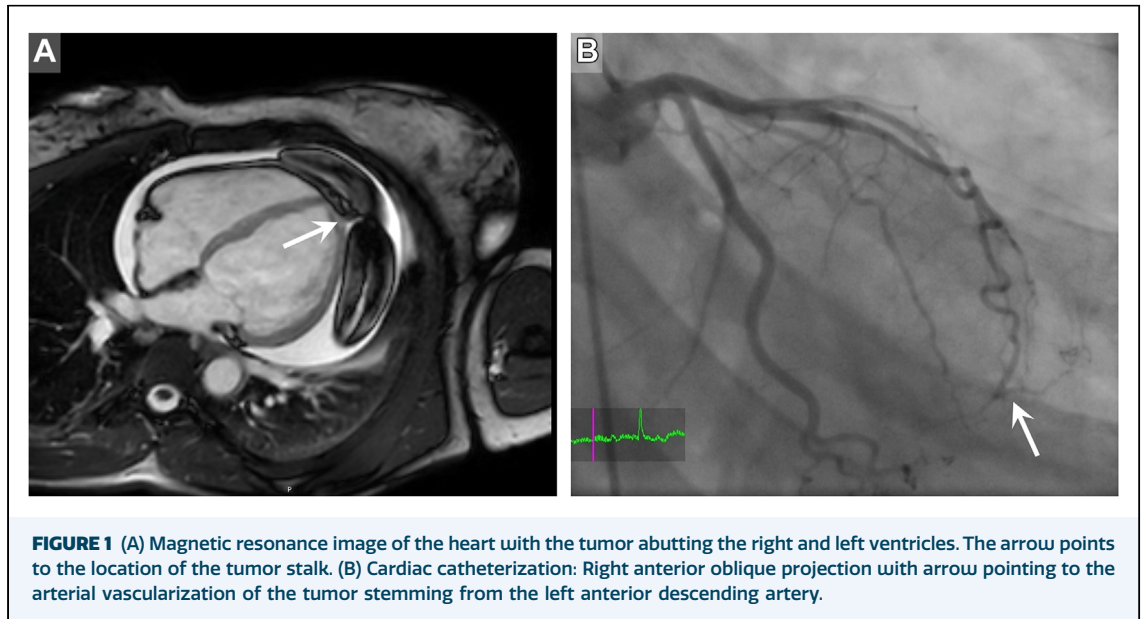
A 43-year-old female patient with a history of epigastric pain, exhaustion, and palpitations for the past 3 years was referred after an epicardial mass was detected upon transthoracic echocardiography. The patient had undergone lengthy diagnostics and treatment, including psychosomatic treatment, prior to detection of the mass in echocardiography. Signs of beginning ventricular chamber compression were evident. No further abnormalities were detected; the left ventricular ejection fraction was normal and no valvular pathologies were found. Cardiac magnetic resonance imaging (MRI) revealed a fatty tumor abutting both the left and right ventricle at the heart's apex (Figure 1A). It seemed to have a central stalk and 2 lobes, 1 towards the anterior and 1 towards the lateral surface of the heart. Cardiac catheterization revealed arterial vascularization of the tumor stemming from the left anterior descending artery (LAD; Figure 1B, Figure 2A).

Tumor resection was performed via median sternotomy approach. The heart was dislocated anteriorly and propped on a laparotomy sponge. This allowed us to gain full view and access to the stalk of the epicardial mass (Video). During this maneuver hemodynamics remained stable, thus cardiopulmonary bypass was not required. After

Accepted for publication May 4, 2024.

¹Department of Cardiac Surgery, LMU University Hospital, LMU Munich, Munich, Germany; and ²DZHK (German Center for Cardiovascular Research), Partner Site Munich Heart Alliance, Munich, Germany

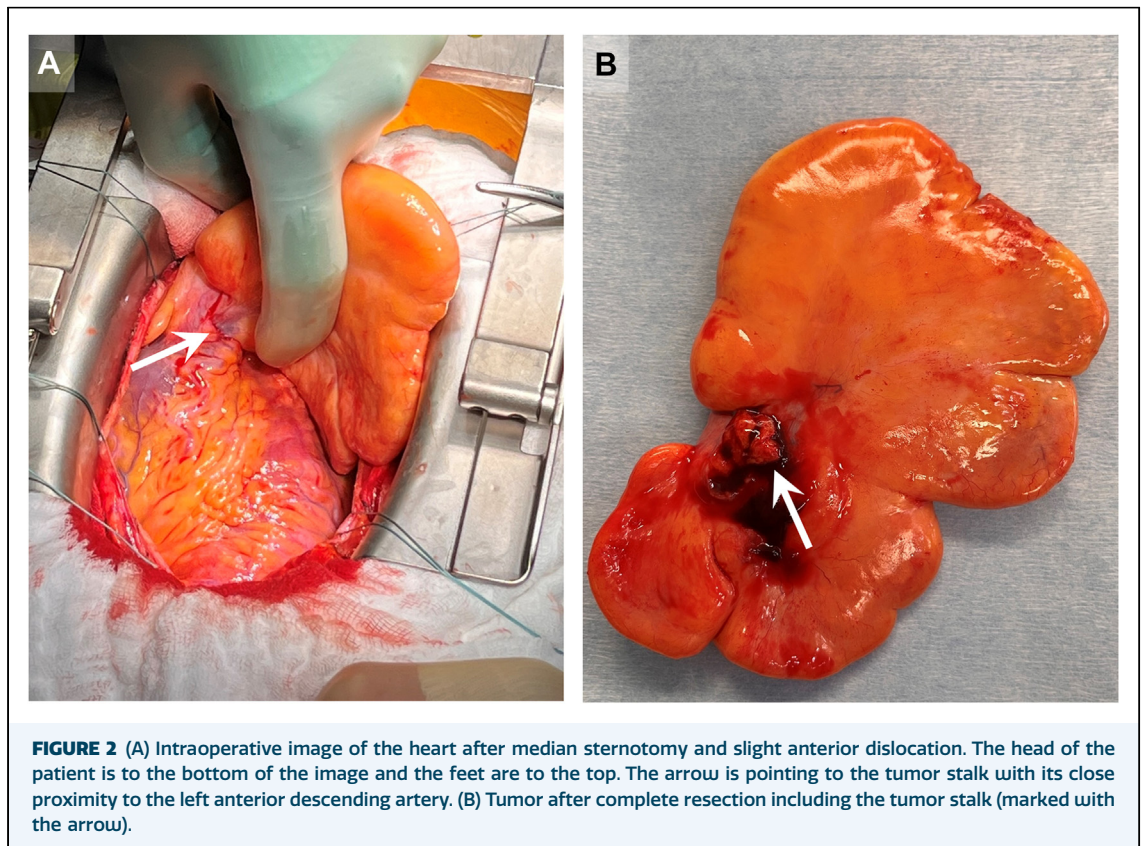
Address correspondence to Dr Vlachea, Department of Cardiac Surgery, LMU University Hospital, Marchioninistrasse 15, 81377 Munich, Germany; email: polyxeni.vlachea@med.uni-muenchen.de.



placement of a purse-string suture around the stalk of the tumor, the tumor's 5 × 5 mm epicardial stalk was carefully ligated and the tumor removed. The suture was tied, providing complete hemostasis. The bilobed butterfly-shaped

tumor measured 130 × 90 × 26 mm (Figure 2B) and weighed 339 g.

Absent immunohistochemical staining of the lipid cells for cyclin-dependent kinase 4 (CDK4) pointed to a mature lipoma. Fluorescent in situ



hybridization (FISH) showed no amplification of the MDM2 gene providing confirmation of benignity and allowed a differentiation of the tumor from a liposarcoma. Two years after the procedure the patient remains in good health with a complete resolution of symptoms. No recurrence of the lipoma has been detected in the regular transthoracic echocardiography performed since the procedure.

COMMENT

Primary cardiac lipomas are a rare entity. Autopsy studies have reported finding cardiac lipomas incidentally after death. Discovery of lipomas in the hearts of living patients remains rare. When detected, most typically these tumors are detected in echocardiography and can be further characterized by computed tomography or MRI. MRI allows an adequate characterization of the tumor tissue and can strengthen the presumptive diagnosis.

The localization of the lipoma determines the symptoms. Most common symptoms are dyspnea, palpitations, chest pain, and fatigue.^{1,5} Whereas intracardiac lipomas causing blood flow obstruction can cause syncope, arrhythmias, or even sudden death, epicardial lipomas typically cause symptoms linked to compression of cardiac chambers or the great vessels. Such compression can have negative prognostic consequences if the tumor is not resected. When symptomatic, radical resection of lipomas is indicated,^{5,6} after which symptom resolution should ensue.

In the presented case, due to the anterior location of the tumor cardiopulmonary bypass was not required for tumor resection. The arterial vascularization from the LAD posed a risk during the procedure. The aim was to resect as much of the tumor stalk as possible without affecting blood flow in the LAD. Closure of the described purse-string suture did not affect anterior wall contractility. Once this was confirmed the suture could be tied, allowing a complete resection of the tumor stalk.

The diagnosis benign lipoma was confirmed by pathologic evaluation of the tumor tissue. In this respect it is important to differentiate the benign

mature lipoma from the malignant liposarcoma as there are stark differences in prognosis. Immunohistologic staining for CDK4 provides the initial information on the tumor entity. CDK4 is involved in oncogenic transformation in various tumor entities. Absent staining of the lipoid cells speaks for a mature lipoma rather than a liposarcoma. However, mere evaluation of the resected tissue by CDK4 staining does not suffice. Further evaluation by FISH⁷ allows a more definite differentiation of the malign from the benign entities. In FISH analysis the amplification of the MDM2 gene in the tumor tissue is investigated. MDM2 is a regulator of p53 and overamplification of mouse double minute 2 is subsequently detected in various malignant tumors including the liposarcoma.

In conclusion, we presented the case of a woman with a butterfly-shaped epicardial tumor vascularized by the LAD. Tumor resection was performed in a beating heart technique, made possible by the anterior location of the tumor. In such cases, preoperatively, MRI is important to gain an insight into the tumor entity. In our case we suspected a lipoid tumor subsequent to tumor characterization in MRI. Postoperatively, immunohistochemical staining and FISH are key to differentiate the benign from the malignant lipoid tumors. The results of this investigation are immensely relevant regarding the prognosis of the disease. In our patient we diagnosed a mature lipoma, a rare benign mesenchymal tumor of the heart. Two years after successful complete removal of the tumor our patient currently remains free of remission and asymptomatic.

The [Video](#) can be viewed in the online version of this article [<https://doi.org/10.1016/j.atsr.2024.05.006>] on <http://www.annalsthoracicsurgery.org>.

FUNDING SOURCES

The authors have no funding sources to disclose.

DISCLOSURES

Polyxeni Vlachea reports a relationship with Getinge that includes: consulting or advisory. All other authors declare that they have no known competing financial interests or personal relationships that could have appeared to influence the work reported in this paper.

PATIENT CONSENT

Obtained.

REFERENCES

1. Shu S, Wang J, Zheng C. From pathogenesis to treatment, a systemic review of cardiac lipoma. *J Cardiothorac Surg*. 2021; 16:1.

2. D'Souza J, Shah R, Abbass A, Burt JR, Goud A, Dahagam C. Invasive cardiac lipoma: a case report and review of literature. *BMC Cardiovasc Disord*. 2017;17:28.

3. Li D, Wang W, Zhu Z, Wang Z, Xu R, Liu K. Cardiac lipoma in the interventricular septum: a case report. *J Cardiothorac Surg*. 2015;10:69.
 4. Reynen K. Frequency of primary tumors of the heart. *Am J Cardiol*. 1996;77:107.
 5. Sun X, Liu G, Kim H, Sun W. Left ventricular lipoma resected using thoracoscope-assisted limited sternotomy: a case report and literature review. *Medicine*. 2018;97:e11436.
 6. Ismail I, Al-Khafaji K, Mutyala M, et al. Cardiac lipoma. *J Community Hosp Intern Med Perspect*. 2015;5:284-49.
 7. Clay MR, Martinez AP, Weiss SW. MDM2 and CDK4 Immunohistochemistry: should it be used in problematic differentiated lipomatous tumors? A new perspective. *Am J Surg Pathol*. 2016;40:1647-1652.
-