

Long-term Outcome of Cochlear Implant in Patients with Chronic Otitis Media: One-stage Surgery Is Equivalent to Two-stage Surgery

Jeong Hun Jang,¹ Min-Hyun Park,²
Jae-Jin Song,³ Jun Ho Lee,^{4,5}
Seung Ha Oh,^{4,5} Chong-Sun Kim,³
and Sun O Chang⁶

¹Department of Otorhinolaryngology, Kyungpook National University College of Medicine, Daegu;

²Department of Otorhinolaryngology, Seoul Metropolitan Government-Seoul National University Boramae Medical Center, Seoul; ³Department of Otorhinolaryngology, Seoul National University Bundang Hospital, Seongnam; ⁴Department of Otorhinolaryngology, Seoul National University College of Medicine; ⁵Sensory Organ Research Institute, Seoul National University Medical Research Center, Seoul; ⁶Department of Otolaryngology-Head and Neck Surgery, Kangbuk Samsung Hospital, Sungkyunkwan University School of Medicine, Seoul, Korea

Received: 26 June 2014

Accepted: 29 August 2014

Address for Correspondence:

Sun O Chang, MD

Department of Otolaryngology-Head and Neck Surgery, Kangbuk Samsung Hospital, Sungkyunkwan University School of Medicine, 29 Saemunan-ro, Jongno-gu, Seoul 110-746, Korea
Tel: +82.2-2001-2263, Fax: +82.2-2001-2273
E-mail: suno@knu.ac.kr

Funding: This work was supported by Biomedical Research Institute grant, Kyungpook National University Hospital (2013).

INTRODUCTION

Profound sensorineural hearing loss (SNHL) can occur in patients with chronic otitis media (COM) as a secondary effect of labyrinthitis, a labyrinthine fistula, or iatrogenic injury during surgery. Cochlear implantation (CI) has become the mainstay of auditory rehabilitation in patients with profound SNHL. However, CI was initially contraindicated in COM patients, because insertion of foreign material through a contaminated field into a space featuring potential intracranial communication was thought to be inappropriate (1). As the audiological benefits afforded by CI became better understood, and as surgical skills and radiological techniques improved, CIs have been increasingly performed in patients with COM.

Recently, many reports on CI in patients with COM have appeared, addressing several issues, including candidate selection,

This study compared long-term speech performance after cochlear implantation (CI) between surgical strategies in patients with chronic otitis media (COM). Thirty patients with available open-set sentence scores measured more than 2 yr postoperatively were included: 17 who received one-stage surgeries (One-stage group), and the other 13 underwent two-stage surgeries (Two-stage group). Preoperative inflammatory status, intraoperative procedures, postoperative outcomes were compared. Among 17 patients in One-stage group, 12 underwent CI accompanied with the eradication of inflammation; CI without eradicating inflammation was performed on 3 patients; 2 underwent CIs via the transcanal approach. Thirteen patients in Two-stage group received the complete eradication of inflammation as first-stage surgery, and CI was performed as second-stage surgery after a mean interval of 8.2 months. Additional control of inflammation was performed in 2 patients at second-stage surgery for cavity problem and cholesteatoma, respectively. There were 2 cases of electrode exposure as postoperative complication in the two-stage group; new electrode arrays were inserted and covered by local flaps. The open-set sentence scores of Two-stage group were not significantly higher than those of One-stage group at 1, 2, 3, and 5 yr postoperatively. Postoperative long-term speech performance is equivalent when either of two surgical strategies is used to treat appropriately selected candidates.

Keywords: Cochlear Implantation; Otitis Media; Tympanomastoidectomy; Speech Performance

choice of surgical strategy, and postoperative complications (2-10). In patients with COM, complete eradication of infected foci in the middle ear cleft prior to CI is essential to avoid development of serious complications and subsequent explanation (8). Therefore, it is essential to consider disease activity status when planning the surgical strategy; either one- or two-stage surgery may be appropriate. Postoperative findings after CI in patients with COM have been evaluated in those treated with one- or two-stage procedures, but among-study differences in results are apparent (2, 3, 7, 9).

Hearing rehabilitation is the most important goal of CI, so the evaluation of postoperative speech performance is essential. However, such performance after CI in COM patients has been evaluated in only a few reports (4, 10) and comparisons of speech performance after application of various surgical strategies have not been performed. Hence, in the present study, we

analyzed the postoperative complication and post-CI long-term speech performance of patients with COM treated via one- or two-stage surgery.

MATERIALS AND METHODS

In the present work, we defined COM as a disease resulting from long-term damage to the middle ear usually caused by Eustachian tube dysfunction but that may also be caused by perforation of the eardrum that failed to heal after trauma, or acute infection of the middle ear. We divided COM patients into those with active COM (chronic suppurative otitis media), who exhibited persistent drainage from the middle ear through a perforated tympanic membrane (11, 12); and those with inactive COM (with a simple, dry, clean perforation of the tympanic membrane, or a retracted membrane, in an otherwise healthy ear, and dry, open, mastoid cavities).

Between November 1988 and October 2010, 39 patients with histories of COM who underwent CI were enrolled. Of these, 30 patients who were followed-up for more than 2 yr were included in the present study. Nine patients examined in the previous study of Kim et al. (5) were also included in the study. Medical records including those of otorhinolaryngological examinations, hearing status evaluations, high-resolution temporal bone computed tomography (TBCT), and magnetic resonance imaging (MRI), were reviewed retrospectively. Medical histories containing information of the principal complaint, symptom progression, and postoperative management of the implanted ear were also reviewed. Patients were followed-up for an average of 66.0 months (range, 24-213 months) after CI.

Patients were divided into two groups; these were 17 patients who received one-stage surgery (One-stage group) and the other 13 patients who underwent two-stage surgery (Two-stage group). The mean ages of patients in 2 groups were 56.0 yr (range, 39-68 yr) and 49.2 yr (range, 19-65 yr), respectively, and the mean follow-up periods 52.1 months (range, 26-133 months) and 84.2 months (range, 24-213 months). One-stage surgery featured simultaneous complete eradication of the pathological condition, and CI. In two-stage surgery, eradication of the pathological condition and mastoid obliteration were performed during the first stage and CI during the second stage, after a planned interval. Patients with histories of tympanomastoidectomy (TM) unrelated to staged-surgery were included in the study, and assigned to either of the two groups as appropriate. As an alternative to use of the conventional transmastoid facial recess technique, CI was performed using a transcanal approach in selected cases. The transcanal approach has been described by Jang et al. (13).

Speech performance was evaluated by open-set sentence testing using the Korean version of the Central Institute for the Deaf (K-CID) sentence set. Open-set sentence scores calculated

1, 2, 3, 5, and > 5 yr postoperatively were compared between the 2 groups. Statistical analysis was performed with the aid of SPSS version 17.0 (SPSS, Chicago, IL, USA). A $P < 0.05$ was considered to reflect statistical significance.

Ethics statement

This retrospective study was approved by the institutional review board of the Clinical Research Institute of Seoul National University Hospital (approval No. H-1206-112-415). The need for informed consent was waived.

RESULTS

The demographic characteristics of the 30 patients, including age at CI, duration of deafness, type of device implanted, operation name, preoperative PTA (pure tone average), and preoperative and the final open-set sentence score, are shown in Table 1. Seventeen patients were males and 13 females, with a mean age of 52.8 yr (range, 19-68 yr). The mean preoperative open-set sentence scores of two groups were $2.1\% \pm 8.7\%$, $8.5\% \pm 17.8\%$, respectively, which was not significantly different ($P = 0.250$). CI was performed to right side ear in 14 patients and left side ear in 16 patients. A total of 28 patients were postlingual hearing loss except 2 patients with prelingual hearing loss (Nos. 12 and 14) in One-stage group. The etiology of hearing loss was COM in all patients and cholesteatoma was accompanied in 7 patients (Nos. 3, 5, 8, 21, 22, 24, and 26). COM was accompanied by cholesteatoma in 7 patients. All patients except 2 patients (Nos. 12 and 14) showed postlingual deafness, and the mean duration of deafness was 7.5 yr (range, 0.3-23.9 yr). MRI was available in 23 patients (14 in One-stage group, 9 in Two-stage group) and the status of cochlear nerve was reviewed and patent in all patients. The Cochlear® device was implanted in 20 patients (66.7%); the Advanced Bionics® device in 6 (20%); and the MED-EL® device in 4 (13.3%). Electrode was fully inserted in all patients, which was identified in postoperative X-ray. One-stage group had 17 patients and the status of the tympanic membrane was as follows: 4 dry perforations, 3 retractions, and 10 intact drums after the TM. Fourteen patients underwent CI, accompanied by 6 closed-cavity TMs (CCs), 2 open-cavity TMs (OCs), and 4 subtotal petrosectomies (STPs); for 2 patients, CI was performed via the transcanal approach. Three patients showed healthy postoperative status after the TM unrelated to staged-surgery, so CI was performed as one-stage surgery. Of 13 patients of Two-stage group, eleven patients showed tympanic membranes with wet perforations of various diameters, accompanied by thick granular changes caused by chronic inflammation. Two patients had inactive COM, but underwent two-stage surgery to prevent cavity problem by mastoid obliteration. Four CCs, 8 OCs, and 1 STP were performed as first-stage surgery and CI was performed at the second surgical stage after a mean in-

Table 1. Demographic characteristics of 30 patients with chronic otitis media who underwent cochlear implantation

Group	No.	Age at CI (yr)	Duration of deafness (yr)	Device	Operation	Preoperative PTA (dB HL)	Open set sentence score* (% , yr)	
							Preoperative	Postoperative
One-stage group (N = 17)	1	53	0.8	A	STP+CI	110	0	34 (9)
	2	51	23.9	C	STP+CI	110	0	90 (2)
	3	55	20	C	STP+CI	110	0	28 (7)
	4	58	1	M	CI via canal approach	95	0	98 (2)
	5	65	7	M	STP+CI	110	0	28 (2)
	6	58	10	C	CC+CI	110	0	100 (5)
	7	58	10	C	CI via canal approach	110	0	28 (5)
	8	51	1	C	CC+CI	90	0	84 (3)
	9	51	10	M	OC+CI	105	0	98 (7)
	10	60	5	C	CC+CI	110	0	98 (2)
	11	64	8	C	CC+CI	110	0	96 (3)
	12	64	15	M	OC+CI	100	0	82 (5)
	13	68	1	A	CI	110	0	37 (2)
	14	47	24	A	CI	115	0	18 (3)
	15	57	3	C	CC+CI	95	0	58 (2)
	16	46	3	C	CC+CI	110	0	94 (9)
	17	39	0.3	C	CI	110	36	99 (3)
Two-stage group (N = 13)	18	19	5	C	OC/CI	110	0	92 (7)
	19	47	29	C	OC/CI	110	0	42 (13)
	20	33	0.5	C	OC/STP+CI	110	0	89 (12)
	21	51	1.1	C	OC/OC+CI	110	0	40 (7)
	22	39	1	A	CC/CI	110	16	78 (9)
	23	55	1.6	C	OC/CI	100	0	96 (11)
	24	61	0.5	A	CC/CI	110	0	66 (6)
	25	65	0.8	C	OC/CI	110	0	40 (7)
	26	62	6	C	OC/CI	110	0	85 (3)
	27	34	20	A	STP/CI	75	47	61 (3)
	28	64	14	C	OC/CI	110	48	96 (2)
	29	54	1	C	CC/CI	110	0	100 (3)
	30	56	2	C	CC/CI	110	0	98 (3)

*Open set sentence test using Korean version Central Institute for the Deaf. No, number; C, Cochlear; A, Advance Bionics; M, MED-EL; STP, subtotal petrosectomy; CC, closed cavity tympanomastoidectomy; OC, open cavity tympanomastoidectomy; CI, cochlear implantation; PTA, pure tone average.

interval of 8.2 months. Of all patients in Two-stage group, two underwent OC and STP concomitant with CI at the second stage due to the mastoid obliteration and cholesteatoma removal.

Fourteen patients had histories of the TM unrelated to staged-surgery. Of these, twelve patients in One-stage group (70.6% of One-stage group) had undergone 1 tympanoplasty, 6 CCs, and 5 OCs; whereas 2 patients in Two-stage group (15.4% of Two-stage group) had undergone 1 CC and 1 OC.

No patient in either group experienced recurrent infection or cholesteatoma recurrence or any intracranial complication. Two patients (nos. 18 and 26) of Two-stage group, who underwent OC as first-stage surgery, experienced device failure with electrode exposure in the mastoid cavity 10 yr and 2 yr after CI. The electrodes were repositioned and new electrode arrays were covered by superiorly based temporalis muscle flaps. There were no electrode problem and CI extraction in One-stage group. Other complications included pinpoint perforation transient dizziness, tinnitus, and hematoma; all complaints improved upon application of conservative management (Table 2).

The mean speech performance scores from open-set sentence testing at years 1, 2, 3, and 5 postoperatively are shown in Table 3. Overall, the open-set sentence scores were relatively good

Table 2. Comparison of complication between 2 groups

Groups	Complications (No.)
One-stage group	Pinpoint perforation (1) Transient dizziness (2) Tinnitus (1) Hematoma (1)
Two-stage group	Transient dizziness (3) Tinnitus (1) Electrode exposure (2)

(≥ 70%) at all tested times. When 2 groups were compared, the scores of Two-stage group were somewhat better than those of One-stage group at all times, but no significant difference was apparent ($P = 0.458, 0.234, 0.772, 0.931$). The difference in open-set sentence scores between the two groups tended to decrease as the follow-up period increased, as a result of improvement in the speech performance of One-stage group.

Nine patients (nos. 1, 3, 5, 7, 13, 14, 19, 21, and 25) exhibited poorer speech performance (open-set sentence scores < 50%) as the follow-up period increased (Table 4). Six such patients were in One-stage and 3 in Two-stage group. Two patients (nos. 13 and 19) underwent speech performance testing only once during follow-up and two patients (nos. 5 and 14) were tested twice.

Table 3. The comparison of long-term speech performance between 2 groups

Parameters		Preoperative open-set sentence score (%)	Postoperative open-set sentence score (%)			
			1 yr	2 yr	3 yr	5 yr
Mean value	One-stage group	2.1 ± 8.7	67.8 ± 34.1 (N = 11)	66.5 ± 30.1 (N = 12)	76.2 ± 26.4 (N = 11)	73.7 ± 28.5 (N = 7)
	Two-stage group	8.5 ± 17.8	77.5 ± 24.9 (N = 11)	80.9 ± 20.6 (N = 9)	79.1 ± 15.2 (N = 9)	78.3 ± 19.5 (N = 7)
	Total	4.9 ± 13.6	72.6 ± 29.5	72.7 ± 26.9	77.5 ± 21.6	75.8 ± 22.7
P value		0.250	0.458	0.234	0.772	0.931

Table 4. The comparison of patients with poor speech performance during follow-up

Groups		Postoperative open-set sentence score (%)				
		1 yr	2 yr	3 yr	5 yr	7 yr
One-stage group	Patient 1	-	-	80	68	52
	Patient 3	64	68	76	44	28
	Patient 5	6	28	-	-	-
	Patient 7	16	43	62	28	-
	Patient 13	-	37	-	-	-
	Patient 14	12	18	-	-	-
Two-stage group	Patient 19	-	-	-	-	-
	Patient 21	94	74	80	75	40
	Patient 25	84	86	70	26	40

DISCUSSION

In the current study, 17 (56.7%) of 30 patients underwent CI via one-stage surgery. Most previous reports have recommended staged surgery as the standard approach to CI in COM patients. Eradication of the pathological condition, with or without blind closure of the EAC, is performed first, followed by later CI after a planned interval (6, 14). However, one-stage surgery may alternatively be performed on appropriately selected patients, especially those with inactive COM, and several studies have reported data from one-stage surgical patients (2, 7, 10, 15). Such treatment avoids repeat general anesthesia and reduces the total cost of implantation.

Complications requiring surgical repair after CI in patients with inactive COM, although rare, have been reported (8, 16, 17). Such complications occurred after either one- or two-stage surgery. Postelmans et al. (3) analyzed 13 CI subjects with COM (4 with active disease, 9 inactive) and suggested that CI, performed as one-stage surgery, was relatively safe in patients with inactive COM, but development of serious complications remained possible, requiring subsequent explantation. However, serious complications (electrode exposure) occurred in only 2 patients of Two-stage group of our current study. Although our sample size was not large, our work reinforces the notion that CI using one-stage surgery is safe. Cholesteatoma developing after EAC closure may cause symptomatic destruction of the temporal bone and/or failure of the CI device (18). In our present patient series, cholesteatoma was detected pre- and intra-operatively in 7 patients (3, One-stage group; 4, Two-stage group), but was completely removed and did not recur during follow-up. This means that the recurrence of cholesteatoma is affected by

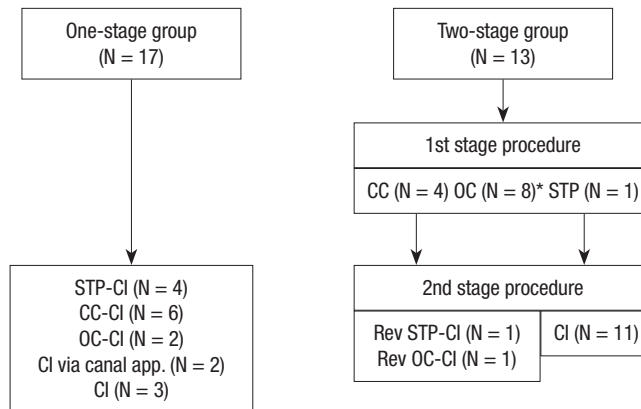


Fig. 1. The surgical algorithm used to plan cochlear implantation in patients with chronic otitis media. *Open cavity tympanomastoidectomy was performed in two patients to ensure mastoid obliteration. CI, cochlear implantation; CC, closed cavity tympanomastoidectomy; OC, open cavity tympanomastoidectomy; STP, subtotal petrosectomy; Rev, revision.

surgical skill rather than surgical strategies. Electrode exposure in the mastoid cavity is one possible serious complication that may cause a device to malfunction. This complication usually occurs when the canal wall-down (open cavity) technique is used. In this current study, OC was performed in 2 patients of One-stage group (11.8%) and 8 patients of Two-stage group (61.5%). On the contrary, STP was performed in 4 patients of One-stage group (23.5%) and 2 patients of Two-stage group (15.4%). This difference might be one of the explanations for the occurrence of electrode exposure in Two-stage group. Therefore, irrespective of the surgical strategies chosen, it could be important to obliterate the mastoid cavity to an extent adequate to allow coverage of the electrode array using well-vascularized soft tissue flaps, if the canal wall-down technique is employed.

The surgical algorithm we used is shown schematically in Fig. 1. Patients were managed based on the extent of disease activity, with reference to inflammatory status and the need to obliterate the mastoid. Patients with active COM underwent the TM as first-stage surgery, and CI after a planned interval. A history of previous surgery was not considered when enrolling patients in the present study. Thus, all patients underwent CI as indicated by the surgical algorithm, irrespective of any history of previous surgery.

In the time since CI in patients with COM commenced in 1993 (19), patients experiencing severe-to-profound SNHL caused by COM have undergone CI in many centers worldwide. Pre-

Table 5. Review of literature data concerning cochlear implantation in chronic otitis media

Authors	Subjects (one stage surgery/staged surgery)	Mean follow-up period	Comments
Incesulu et al. (20)	6 (1/5)	24.16 ± 7.6 months (range 17-39)	Two-stage operation is a safe procedure
Kojima et al. (10)	7 (6/1)	34 months (range 18-48)	One-stage operation can usually achieve safety
Xenellis et al. (2)	9 (0/9)	7.05 yr (18 months-12 yr)	Blind-sac closure of external auditory canal is a rather safe procedure as two-stage operation
El-Kashlan et al. (7)	8 (7/1)	3.85 yr (range 2-7)	One-stage operation can usually achieve safety
Leung et al. (4)	17 (7/10)	7 yr (range 3-11)	The obliteration with flap is an effective technique to facilitate safety
Postelmans et al. (3)	13 (9/4)	-	Surgical strategy should be decided according to the activity of chronic otitis media
Free et al. (15)	31 (31/0)	18-96 months	Subtotal petrosectomy is a procedure in specific indications and lowers the risk of repetitive infections
Wong et al. (21)	19 (7/12)	N.A	Cochlear implant in chronic otitis media is a safe and effective treatment irrespective of surgical strategies

N.A, not available.

vious studies have examined candidate selection, surgical methods and strategies, and postoperative complications. As shown in Table 5, most studies had only small numbers of patients in either One- or a Two-stage group, with the exception of a single study by Leung and Briggs (4). In addition, few reports have compared postoperative long-term speech performance with reference to the surgical strategy used. In our present study, the sample size of either group was similar; all patients were followed up for at least 2 yr; and postoperative speech performance scores were available. We found that the auditory performance of 2 surgical strategies showed statistically no significant difference, which also supported the equivalence of one-stage surgery to two-stage surgery (Table 3). The speech performance of One-stage group tended to improve as the duration of follow-up increased, as compared with that of Two-stage group. The follow-up loss of some patients in One-stage group (nos. 5, 13, and 14; Table 4), whose speech performance was poor, might be one of the reason. The long-term speech performance in most patients remained relatively stable in this current study. However, five patients with poor speech performance showed a decline in open-set sentence score, especially at 5 yr postoperatively (nos. 1, 3, 7, 21, and 25, 16.7%) (Table 4). Table 4 shows the patients with poor speech performance during follow-up. Various prognostic factors may play roles in post-CI outcomes rather than surgical strategies chosen. Such factors may include deafness of long duration (nos. 3, 7, 14, and 19); CI in prelingually deafened adults (nos. 14); absence of pre-CI rehabilitation with a hearing aid (nos. 1, 3, 7, 13, and 19); low educational level (nos. 3, 5, 7, 14, and 25); and narrow bony cochlear nerve canals (nos. 1, 3, 7, and 21).

Our surgical experience and our analysis of long-term speech performance after CI, described in the present study, suggest that 2 surgical strategies in patients with COM are equivalent with respect to postoperative complication and long-term auditory outcome if CI candidates are appropriately selected with reference to patient condition and the level of COM activity.

DISCLOSURE

Sun O Chang takes responsibility for the integrity of the content of the paper. All authors declare no conflicts of interest.

AUTHOR CONTRIBUTION

Conceived and designed the experiments: SO Chang, CS Kim. Performed the experiments: JH Jang, JJ Song. Analyzed the data: JH Jang, MH Park. Wrote the paper: JH Jang, JJ Song, MH Park. Agree with the manuscript results and conclusions: SO Chang, CS Kim, SH Oh, JH Lee. Enrolled patients: SO Chang, CS Kim, SH Oh, JH Lee.

ORCID

Jeong Hun Jang <http://orcid.org/0000-0003-1707-5714>
 Min-Hyun Park <http://orcid.org/0000-0003-4156-7639>
 Jae-Jin Song <http://orcid.org/0000-0002-6631-3232>
 Jun Ho Lee <http://orcid.org/0000-0002-5519-3263>
 Seung Ha Oh <http://orcid.org/0000-0003-1284-5070>
 Chong-Sun Kim <http://orcid.org/0000-0002-4273-5908>
 Sun O Chang <http://orcid.org/0000-0003-2944-2753>

REFERENCES

1. Belal A Jr. *Contraindications to cochlear implantation. Am J Otol* 1986; 7: 172-5.
2. Xenellis J, Nikolopoulos TP, Marangoudakis P, Vlastarakos PV, Tsangaroulakis A, Ferekidis E. *Cochlear implantation in atelectasis and chronic otitis media: long-term follow-up. Otol Neurotol* 2008; 29: 499-501.
3. Postelmans JT, Stokroos RJ, Linmans JJ, Kremer B. *Cochlear implantation in patients with chronic otitis media: 7 years' experience in Maastricht. Eur Arch Otorhinolaryngol* 2009; 266: 1159-65.
4. Leung R, Briggs RJ. *Indications for and outcomes of mastoid obliteration in cochlear implantation. Otol Neurotol* 2007; 28: 330-4.
5. Kim CS, Chang SO, Lee HJ, Shim WS, Oh SH, Kim YH. *Cochlear implan-*

- tation in patients with a history of chronic otitis media. *Acta Otolaryngol* 2004; 124: 1033-8.
6. Gray RF, Irving RM. Cochlear implants in chronic suppurative otitis media. *Am J Otol* 1995; 16: 682-6.
 7. El-Kashlan HK, Arts HA, Telian SA. Cochlear implantation in chronic suppurative otitis media. *Otol Neurotol* 2002; 23: 53-5.
 8. Donnelly MJ, Pyman BC, Clark GM. Chronic middle ear disease and cochlear implantation. *Ann Otol Rhinol Laryngol Suppl* 1995; 166: 406-8.
 9. Basavaraj S, Shanks M, Sivaji N, Allen AA. Cochlear implantation and management of chronic suppurative otitis media: single stage procedure? *Eur Arch Otorhinolaryngol* 2005; 262: 852-5.
 10. Kojima H, Sakurai Y, Rikitake M, Tanaka Y, Kawano A, Moriyama H. Cochlear implantation in patients with chronic otitis media. *Auris Nasus Larynx* 2010; 37: 415-21.
 11. Matsuda Y, Kurita T, Ueda Y, Ito S, Nakashima T. Effect of tympanic membrane perforation on middle-ear sound transmission. *J Laryngol Otol Suppl* 2009; 81-9.
 12. Wright D, Safranek S. Treatment of otitis media with perforated tympanic membrane. *Am Fam Physician* 2009; 79: 650, 4.
 13. Jang JH, Song JJ, Yoo JC, Lee JH, Oh SH, Chang SO. An alternative procedure for cochlear implantation: transcanal approach. *Acta Otolaryngol* 2012; 132: 845-9.
 14. Gray RF, Ray J, McFerran DJ. Further experience with fat graft obliteration of mastoid cavities for cochlear implants. *J Laryngol Otol* 1999; 113: 881-4.
 15. Free RH, Falcioni M, Di Trapani G, Giannuzzi AL, Russo A, Sanna M. The role of subtotal petrosectomy in cochlear implant surgery: a report of 32 cases and review on indications. *Otol Neurotol* 2013; 34: 1033-40.
 16. Bhatia K, Gibbin KP, Nikolopoulos TP, O'Donoghue GM. Surgical complications and their management in a series of 300 consecutive pediatric cochlear implantations. *Otol Neurotol* 2004; 25: 730-9.
 17. Harada T, Ishida K, Endo M, Takahashi M, Sakai M. Recurrent extrusion of cochlear implant at an interval of 5 years. *Otol Neurotol* 2003; 24: 83-5.
 18. El-Kashlan HK, Arts HA, Telian SA. External auditory canal closure in cochlear implant surgery. *Otol Neurotol* 2003; 24: 404-8.
 19. Parnes LS, Gagne JP, Hassan R. Cochlear implants and otitis media: considerations in two cleft palate patients. *J Otolaryngol* 1993; 22: 345-8.
 20. Incesulu A, Kocaturk S, Vural M. Cochlear implantation in chronic otitis media. *J Laryngol Otol* 2004; 118: 3-7.
 21. Wong MC, Shipp DB, Nedzelski JM, Chen JM, Lin VY. Cochlear implantation in patients with chronic suppurative otitis media. *Otol Neurotol* 2014; 35: 810-4.