

This article is licensed under the Creative Commons Attribution-NonCommercial 4.0 International License (CC BY-NC) (<http://www.karger.com/Services/OpenAccessLicense>). Usage and distribution for commercial purposes requires written permission.

## Single Case

# Concomitant Vancomycin-Resistant *Enterococcus faecium* and *Clostridium difficile* Colitis

Shehriyar Mehershahi<sup>a</sup> Haider Ghazanfar<sup>b</sup> Shoaib Ashraf<sup>b</sup>  
Danial H. Shaikh<sup>a</sup> Ariyo Ihimoyan<sup>a</sup>

<sup>a</sup>Department of Gastroenterology, Bronxcare Health System, Bronx, NY, USA; <sup>b</sup>Department of Medicine, Bronxcare Health System, Bronx, NY, USA

## Keywords

Colitis · Vancomycin-resistant *Enterococcus faecium* · *Clostridium difficile* · Intensive care unit

## Abstract

Colitis is a chronic gastrointestinal system disease characterized by inflammation of the inner lining of the colon. Infectious colitis is one of the most common causes of colitis and is associated with significant mortality and morbidity. One of the rare causes of colitis includes vancomycin-resistant *Enterococcus faecium* (VRE). Lately, the prevalence of VRE has significantly increased in hospitals. We present a case of a 32-year-old American man who was initially admitted because of bilateral lower extremity weakness. The hospital course was complicated, with acute hypoxic respiratory failure secondary to pneumonia. The patient was intubated and was started on broad-spectrum antibiotics. Later on, the patient had severe diarrhea and was found to have clostridium difficile infection. Patient symptoms persisted despite completing the course of antibiotics. Colonoscopy was performed, and the patient was found to have a diffuse area of severely altered vascular, congested, erythematous, friable with contact bleeding, hemorrhagic, inflamed, nodular, and ulcerated mucosa in the sigmoid colon, in the descending colon, and the transverse colon. A biopsy was sent, and the patient was found to be

growing VRE. Currently, there is no effective treatment available for VRE. Hospitals need to have an active surveillance program to identify these patients so that the infection does not spread to other patients.

© 2021 The Author(s)  
Published by S. Karger AG, Basel

## Introduction

Colitis is a chronic gastrointestinal system disease characterized by inflammation of the inner lining of the colon. Infectious colitis is one of the most common causes of colitis and is associated with significant mortality and morbidity. Infectious colitis can result from bacterial, viral, or parasitic infections. Patients usually present with fever, fatigue, abdominal pain, tenesmus, and bloody or non-bloody diarrhea.

Common causes of viral colitis include adenovirus, cytomegalovirus, norovirus, and rotavirus. Common causes of bacterial colitis include *Campylobacter jejuni*, *Clostridium difficile*, *Escherichia coli*, *Salmonella*, *Shigella*, *Mycobacterium tuberculosis*, and *Yersinia enterocolitica*. Common causes of parasitic colitis include *Cryptosporidium*, *Cyclospora*, *Entamoeba histolytica*, and *Giardia*. Sexually transmitted infections such as *Chlamydia trachomatis*, herpes simplex 1 and 2, *Neisseria gonorrhoeae*, and *Treponema pallidum* can also cause infectious colitis [1].

One of the rare causes of colitis includes vancomycin-resistant *Enterococcus faecium* (VRE). Lately, the prevalence of VRE has significantly increased in hospitals [2]. According to a multicenter study done in 25 intensive care units (ICUs) in North America, it was found out that about 28.4% of the enterococci were resistant to vancomycin [3]. We present a case of a 32-year-old that was found to have concomitant VRE and *C. difficile* colitis.

## Case Report

A 32-year-old African American man was admitted to the hospital with bilateral lower extremities weakness and inability to walk for 2 days. The patient states that he had progressive bilateral lower extremities weakness for the last 3 months, which is getting worse to the point that he is unable to walk. He also complained about slurred speech and deviation of the left eye for the past 2 weeks. The patient had a history of hypothyroidism and acquired immune deficiency syndrome with CD4+ T-lymphocyte cell (CD4) count <20 and plasma HIV RNA (viral load) of 206,000 6 months before the admission. Physical examination was remarkable for dysarthria, horizontal nystagmus bilaterally, dysmetria on finger-to-nose examination, and unsteady gait. Patient initial laboratory findings have been mentioned in Table 1.

The patient underwent MRI, which showed abnormal non-enhancing hyperintense T2 hypointense T1 signal extending from central cerebellar white matter, superior cerebellar peduncles, near entirety of the pons, cerebral peduncles, and left cortical spinal tract. The patient underwent lumbar puncture. The cerebrospinal fluid analysis was unremarkable.

The patient became hypoxic, hypotensive, and developed altered mental status on day 5 of admission. The patient was intubated and started on broad-spectrum antibiotics. The patient was transferred to the ICU for further management of acute hypoxic respiratory failure and septic shock. VRE peri-rectal surveillance cultures were sent at the time of arrival to ICU and were found to be negative. The patient failed multiple weaning attempts and underwent percutaneous tracheostomy and percutaneous endoscopic gastrostomy tube placement.

The patient developed severe watery diarrhea during the third week of hospitalization. The patient's stool was sent for further analysis. *C. difficile* glutamate dehydrogenase and toxin B tests came back positive, and the patient was started on oral vancomycin for 14 days. Patient diarrhea persisted despite completing a 14-day course of antibiotic. Patient developed bleeding per rectum on the last day of antibiotic course. Digital rectal exam showed solid brown stool with specks old blood, no fresh blood. The patient was scheduled for a colonoscopy. Colonoscopy showed a diffuse area of severely altered vascular, congested, erythematous, friable with contact bleeding; hemorrhagic, inflamed, nodular, and ulcerated mucosa was found in the sigmoid colon, in the descending colon, and in the transverse colon. This has been shown in Figures 1, 2. Biopsies were taken with cold forceps for histology.

The patient was started on oral and rectal vancomycin with metronidazole for a total of 14 days. The patient's blood culture and urine culture showed no growth of any organism. Tissue culture grew VRE. An echocardiogram showed no vegetation. Infectious disease was consulted, and the patient was advised to continue with oral and rectal vancomycin with metronidazole. The patient's clinical condition improved, and his diarrhea resolved. The patient was discharged to a nursing home with a follow-up appointment.

## Discussion

*Enterococcus* is a Gram-positive round-shaped bacterium that commonly lives in the gastrointestinal tract. Enterococci have intrinsic resistance to commonly used antibiotics and also have the ability to acquire resistance to newer antibiotics. In the past, all the enterococci were susceptible to vancomycin, but in the recent years, some enterococci have become resistant to vancomycin. There are five major phenotypes of vancomycin-resistant enterococci [4].

Patients with cancer, weak immune system, history of transplant, history of major surgery, history of chronic disease such as diabetes, having a urinary catheter for a long time, an intravenous catheter for a long time, taking antibiotics for a long time in the hospital, severely ill and admitted in ICUs are at an increased risk of getting severe VRE infections. Concomitant infection by VRE and *C. difficile* can happen as it shares the same risk factor [5]. According to a study, VRE was associated with 55.7% of *Clostridium difficile* infection. Patients who have a concomitant infection by VRE and *C. difficile* have a greater chance of having co-infection with other multidrug-resistant pathogens such as methicillin-resistant *Staphylococcus aureus* and *Acinetobacter* spp [5]. The prevalence of VRE in *C. difficile* patients has increased from 18% in 1999 to 47% in 2006 [5]. VRE strains have shown to have the ability to transfer vancomycin resistance to other bacteria such as MRSA.

Colonization by VRE, usually in the gastrointestinal tract, precedes VRE infection. Colonization in the gastrointestinal tract is usually associated with skin contamination. Contaminated skin can provide a route of entry into the bloodstream via vascular catheters [6]. Patients on a mechanical ventilator are more likely to be colonized with VRE than non-ventilated patients at the time of admission [6]. Disruption of gastrointestinal mucosal wall integrity during gastrointestinal manipulation can lead to the spread of VRE to the blood in a patient with VRE-colonized gastrointestinal tract [7]. In some patients, colonization by VRE does not lead to infection. These patients remain colonized for a prolonged period of time and can transmit VRE to other patients. There is no approved effective treatment for the decolonization of VRE [8].

VRE can survive on the surface for a long time. It usually spreads through contact with a contaminated surface or by touching a person who has VRE. VRE can quickly spread from one patient to another through healthcare workers if proper precautions are not taken. Healthcare providers should wash their hands with soap and water or use an alcohol-based sanitizer before and after seeing every patient prevent the spread of VRE. Rooms used by VRE patients need to be terminal clean with the bucket method as routine terminal disinfection is not completely effective [4]. Active surveillance needs to be done in high-risk units to identify patients with VRE colonization.

VRE can cause sepsis, abscesses, colitis, wound infection, pneumonia, endocarditis, meningitis, and urinary tract infection. VRE bacteremia has been associated with a 60–70% mortality rate [9]. The diagnosis of VRE is confirmed after it grows on culture. Currently, there is no optimal treatment available for VRE. Treatment of VRE should be individualized to the patient. Treatment is not warranted in patients who have been colonized with VRE but do not have the infection. Patients with the invasive disease need to be treated with antibiotics. Daptomycin, linezolid, oritavancin, quinupristin-dalfopristin, tigecycline, teicoplanin, and telavancin are effective against VRE strains. There is no vaccine available for VRE.

VRE is a major nosocomial pathogen and is associated with significant morbidity and mortality. Due to the lack of effective treatment options, it is imperative to prevent the spread of VRE. A urinary catheter and intravenous catheter should be removed when they are no longer needed. Hospitals need to have an active surveillance program so that patients colonized with VRE can be identified on admission and can be isolated.

### Statement of Ethics

Written informed consent was obtained from the patient's family for this submission.

### Conflict of Interest Statement

None.

## Funding Sources

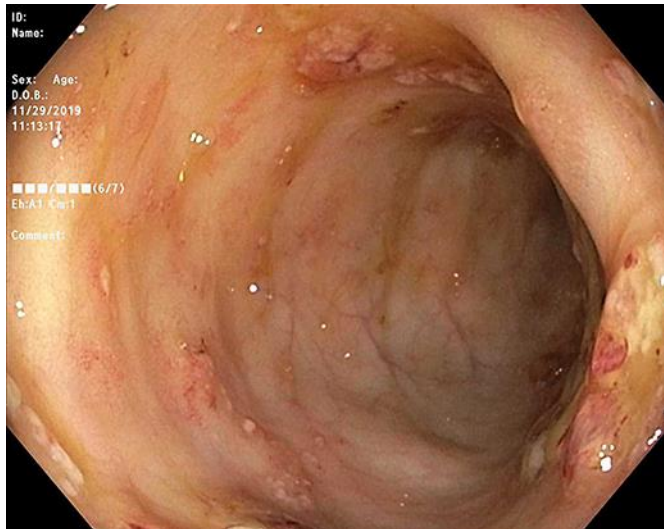
There was no external source of funding to support this case report.

## Author Contributions

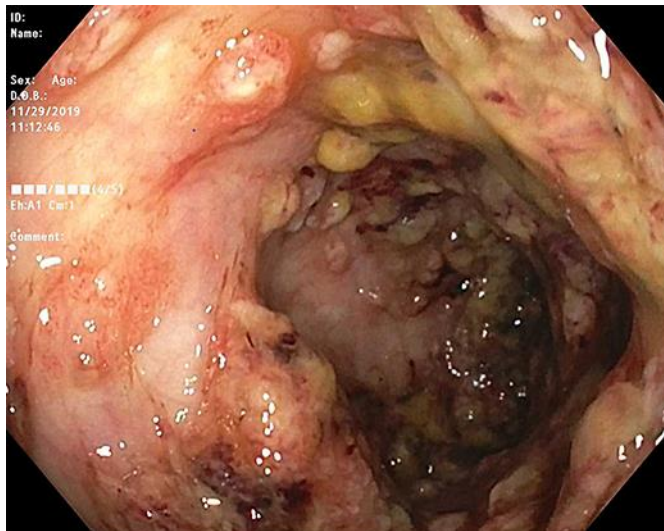
All the authors were involved in writing and finalizing the manuscript.

## References

- 1 Musher DM, Musher BL. Contagious acute gastrointestinal infections. *N Engl J Med*. 2004 Dec;351(23):2417–27.
- 2 Chiang HY, Perencevich EN, Nair R, Nelson RE, Samore M, Khader K, et al. Incidence and Outcomes Associated With Infections Caused by Vancomycin-Resistant Enterococci in the United States: Systematic Literature Review and Meta-Analysis. *Infect Control Hosp Epidemiol*. 2017 Feb;38(2):203–15.
- 3 Streit JM, Jones RN, Sader HS, Fritsche TR. Assessment of pathogen occurrences and resistance profiles among infected patients in the intensive care unit: report from the SENTRY Antimicrobial Surveillance Program (North America, 2001). *Int J Antimicrob Agents*. 2004 Aug;24(2):111–8.
- 4 Gold HS. Vancomycin-resistant enterococci: mechanisms and clinical observations. *Clin Infect Dis*. 2001 Jul;33(2):210–9.
- 5 Fujitani S, George WL, Morgan MA, Nichols S, Murthy AR. Implications for vancomycin-resistant Enterococcus colonization associated with Clostridium difficile infections. *Am J Infect Control*. 2011 Apr;39(3):188–93.
- 6 Bonten MJ, Hayden MK, Nathan C, van Voorhis J, Matushek M, Slaughter S, et al. Epidemiology of colonisation of patients and environment with vancomycin-resistant enterococci. *Lancet*. 1996 Dec;348(9042):1615–9.
- 7 Zaas AK, Song X, Tucker P, Perl TM. Risk factors for development of vancomycin-resistant enterococcal bloodstream infection in patients with cancer who are colonized with vancomycin-resistant enterococci. *Clin Infect Dis*. 2002 Nov;35(10):1139–46.
- 8 Hachem R, Raad I. Failure of oral antimicrobial agents in eradicating gastrointestinal colonization with vancomycin-resistant enterococci. *Infect Control Hosp Epidemiol*. 2002 Jan;23(1):43–4.
- 9 Cetinkaya Y, Falk P, Mayhall CG. Vancomycin-resistant enterococci. *Clin Microbiol Rev*. 2000 Oct;13(4):686–707.



**Fig. 1.** Diffuse congested, erythematous, and ulcerated mucosa of the descending colon.



**Fig. 2.** Diffuse congested, erythematous, nodular, and ulcerated mucosa of the sigmoid colon.

**Table 1.** Initial laboratory values at the time of admission

Investigation	Value
<i>Complete blood count</i>	
White blood cell count, ×1,000/μL	2.1 [4.8–10.8]
Neutrophil, %	53.4 [40–70]
Hemoglobin, g/dL	14.3 [12.0–16.0]
Hematocrit, %	43.1 [42.0–51.0]
Platelet, ×1,000/μL	155 [150–400]
<i>Basic metabolic panel</i>	
Sodium, mEq/L	138 [135–145]
Potassium, mEq/L	4.7 [3.5–5.0]
Bicarbonate, mEq/L	24 [24–30]
Chloride, mEq/L	99 [98–108]
Glucose, mEq/L	93 [70–120]
Blood urea nitrogen, mg/dL	21 [8–26]
Creatinine, mg/dL	1.1 [0.5–1.5]
Calcium, mg/dL	9.6 [8.5–10.5]
<i>Hepatic function panel</i>	
Albumin, g/dL	4.8 [3.4–4.8]
Total bilirubin, mg/dL	0.4 [0.2–1.2]
Alkaline phosphatase, U/L	70 [53–128]
Aspartate transaminase, U/L	63 [9–48]
Alanine aminotransferase, U/L	75 [5–40]