

Comparison between intrathecal morphine with paravertebral patient controlled analgesia using bupivacaine for intraoperative and post-thoracotomy pain relief

Haitham Abou Zeid,
Ahsan Khaliq Siddiqui,
Ehab F. A. Elmakarem,
Yasser Ghonaimy¹,
Awatif Al Nafea²

Departments of Anesthesiology,
¹Cardiothoracic Surgery and
²Hematology, King Fahd Hospital
of the University, University of
Dammam, Dammam, Saudi Arabia

Address for correspondence:

Dr. Ahsan Khaliq Siddiqui,
Department of Anesthesiology,
King Fahd Hospital of the University,
University of Dammam,
Dammam, Saudi Arabia.
E-mail: ahsansiddiqui@hotmail.com

ABSTRACT

Objectives: This study was designed to compare the intrathecal morphine and paravertebral block with bupivacaine given before induction of anesthesia for intra-operative and post-thoracotomy pain relief for 48 hours using patient controlled paravertebral analgesia in post-operative period. **Methods:** After taken an approval from the ethics committee of the University, 40 patients were randomly assigned to receive either preservative-free intrathecal morphine 0.3 mg in 3 ml normal saline together with paravertebral block (group I) or paravertebral block alone using bupivacaine (group II) before an induction of anesthesia. No continuous infusion of bupivacaine was started in both groups. Primary outcomes were Visual Analogue Score (VAS) at rest and on coughing. Hemodynamic and respiratory effects, bupivacaine consumption, patient's satisfaction, and side effects like nausea, vomiting, urinary retention, and itching were considered as secondary outcomes. All patients in both groups received paracetamol 1 gram (gm) IV every 6 hourly for the 1st 24 hr. Amount of rescue analgesic (pethidine 0.5 mg/kg IV) in both groups and total bupivacaine cumulative doses in 48 hrs were calculated. **Results:** VAS at rest and on coughing did not differ significantly between the 2 groups at 0, 1, 6, 12, 18, 24, and 48 hours ($P = > 0.1$). At 24 hours, VAS increased in both the groups, but the increase in VAS was comparable in both groups. There were insignificant incidences of nausea, purities, and urinary retention in intrathecal group compared with paravertebral group. The other side effects and patient satisfaction did not show any statistical significant difference between 2 groups. **Conclusion:** Intrathecal morphine 0.3 mg is safe and effective way to improves pain control for thoracic surgery and was comparable to paravertebral patient control analgesia (PPCA) with bupivacaine for the 1st 48 hours post-thoracotomy.

Key words: *Bupivacaine, intrathecal morphine, paracetamol, paravertebral patient control analgesia, post-operative pain, thoracic surgery*

INTRODUCTION

Pain after thoracic surgery may be the most recognized pain syndrome associated with a specific surgery.^[1] Inadequate pain control might lead to postoperative pulmonary complications, such as mucous plugging, hypoxia,

atelectasis and pulmonary infections due to additionally prolonged immobility related to pain.^[2] Several analgesic techniques, including intercostal, paravertebral, interpleural and epidural blocks with local anesthetics and opioids, have been used to provide pain relief after thoracotomy.^[3]

A survey of analgesic techniques after thoracotomy in Australian hospitals showed that 79% of respondents regarded epidural blockade as the best available technique.^[4] However, thoracic epidurals were associated with significantly higher adverse effects such as block failure, hypotension, urinary retention, pulmonary complications, and nausea than paravertebral analgesia.^[5] Thoracic paravertebral block (PVB) has enjoyed resurgence in recent years. Continuous thoracic paravertebral

Access this article online

Quick Response Code:



Website:

www.saudija.org

DOI:

10.4103/1658-354X.101204

analgesia is as effective as epidural blockade in controlling post-thoracotomy pain; in addition, it is associated with less hemodynamic effects.^[6]

The intrathecal administration of morphine in post-operative patients was 1st reported in 1979,^[7] whereas epidural opioid analgesia has enjoyed widespread popularity, the intrathecal route is associated with inferior safety, primarily because of a higher reported incidence of respiratory depression and somnolence.^[8] However, this analgesic modality stood the test of time and was shown to provide effective analgesia of long duration in the post-operative period. When patients assessed timely, small-dose of intrathecal opioids are safe, effective, and relatively inexpensive modalities for the routine management of acute post-operative pain after a variety of major surgical procedures.^[9] Nevertheless, intrathecal opioid administration has been investigated more recently in the context of major surgery, especially cardiac.^[10] Recently, lumbar spinal opioid analgesia is now considered as an alternative and comparable to thoracic epidural analgesia.^[5] Thoracic paravertebral block (PVB) is used frequently in our department as a perioperative pain relief technique for thoracic surgery. This technique may have some advantages such as a unilateral analgesia with unilateral sympathetic block, which may have less effect on patient's hemodynamics. Comparison between intrathecal administration of morphine and paravertebral block with local anesthetics for post-operative pain management after thoracotomy was not yet studied. Intrathecal opioid administration could be an easy technique to perform and simple alternative way to relief the intra-operative and post-thoracotomy pain in the 1st 48 hours. We hypothesise that intrathecal morphine technique has equal analgesic effect as paravertebral technique in thoracic surgical procedures.

Our aim in this prospective study was to compare the analgesic efficacy of intrathecally administered morphine with that of patient control paravertebral analgesia for 1st 48 hours post-thoracotomy and patient satisfaction.

METHODS

This study was started in March 2009 and completed in April 2011 in King Fahd Teaching Hospital of the university, University of Dammam, Dammam, Saudi Arabia. After an approval of the local Ethics Committee of the King Fahd Hospital of the university, a written informed consent was obtained from 40 consecutive patients undergoing thoracotomy. Patients, who were American Society of Anesthesiologists (ASA) physical status I-III and aged between 18 – 72 years, were included in the study. Patients were randomly allocated by sealed

opaque envelopes method into 2 groups (group): Group I; who received intrathecal preservative-free morphine 0.3 mg in 3 ml normal saline plus paravertebral patient control analgesia (PPCA) with bupivacaine and group II; paravertebral patient control analgesia (PPCA) with bupivacaine alone in sitting position. In our institution, the blocks for both thoracic and lumbar paravertebral block are carried out with patient in sitting position. Because of this ration, we gave spinal block using morphine in group 1.

Exclusion criteria included cardiac diseases, hepatic insufficiency, and renal failure. Infection at the operation site, coagulation disorders, and use of any analgesics during the last 48 hours before surgery, patients with a history of chronic pain, psychiatric disease, and allergy to local anesthetics, morphine, or drugs used in the study were also excluded.

During pre-operative visit, the potential benefits and side effects of both intrathecal morphine and paravertebral techniques were explained to the patients. VAS scoring system and the use of patient-controlled analgesia pump were also explained to every patients included in this study. All patients received premedication in the form of lorazepam 1-2 mg orally the night before surgery. On an arrival to operating room, a 0.05 mg/kg midazolam was injected intravenously 15 minutes before starting anesthetic procedure. Before an induction of general anesthesia and according to the randomization, group I patients received 0.3 mg preservative-free morphine in 3 ml normal saline intrathecally at the level of L3-4 or L4-5 interspinous space while in sitting position (via midline approach using 25-gauge spinal needle). Following intrathecal morphine administration and to ensure assessor blindness, a paravertebral catheter was inserted at the level of T5 using Touhy needle (Touhy needle-18G; Minipack epidural-catheter, Portex Ltd, England). Sterile dressing was used to cover L3-4 interspace to ensure blindness of the assessor. Patients in group II received 4 paravertebral injections (5 ml each of 0.25% bupivacaine) after which an epidural catheter was inserted in paravertebral space at T5 level. Sterile dressing was used to cover L3-4 interspace without skin puncture to ensure blindness of the assessor. For paravertebral space identification, midline was identified with by noting the spinous processes, and then the low-frequency ultrasound probe was used to scan laterally until the transverse processes, the costotransverse ligament, and the pleura could easily be identified. An 18 gauge, tuohy needle was advanced in-plane under ultrasound visualization. Once the paravertebral space was entered and we feel lose of resistance, a bolus of 5 ml 0.25 % bopivacaine was given. Tenting of the pleura could be seen and moving with the injection, which is the endpoint we use to confirm proper location in the paravertebral

space. A 21 gauge catheter was then placed through the needle 5 cm beyond the needle tip.

General anesthesia was induced using fentanyl 2 mg/kg, propofol 2 mg/kg, and rocuronium 0.6 mg/kg, and a left appropriate size double lumen tube (SumiO, Poland) was inserted for one lung anesthesia using fiberoptic scope. Anesthesia was then maintained with sevoflurane 1-1.5 MAC with 50% oxygen in air or according to oxygen requirements intra-operatively to keep patients oxygen saturation above 95%. All patients were anesthetized by anesthesiologists who were blinded to the analgesic technique and the study protocol. Total intra-operative fentanyl consumption was recorded in both groups.

In Post Anesthesia Care Unit (PACU), all patients were continuously monitored for hemodynamics, respiratory rate, hemoglobin oxygen saturation with pulse oximetry. Patients received post-operative supplemental oxygen via oxygen mask 5 liter/min. 1 gram paracetamol intravenously (perfalgan[®]; Bristol Meyers Squibb-France) was given during closure of the wound and then every 6 hourly regularly for 48 hours to all patients in both groups. In both study groups, paravertebral catheters were connected to (PCA) pumps 15 minutes before end of surgery, no continuous background paravertebral bupivacaine infusion was given. A bolus of 5 ml bupivacaine 0.25% with 10 minutes lock-out time with maximum 20 ml/4 hours was used according to the patient's demand.

Primary outcomes like Visual Analogue Score (VAS) at rest and on coughing and post-operative analgesic requirements were recorded by a trained nurse who was not informed about patient group assignment on arrival to recovery area 0 hour, 1 hour and then in ward or in surgical intensive care unit (SICU) at 6 hours, 12 hours, 18 hours, 24 hours, and 48 hours.

Side effects like nausea, vomiting, urinary retention, and itching with hemodynamic effects, and respiratory parameters were considered as secondary outcomes. Patients were discharged from recovery area to ward as soon as they reached a Modified Aldrete score of 9 points. Strict continuous monitoring and close observation were extended in the ward. Patients with complicated surgical course or with ASA physical status III were transferred to SICU. The degree of sedation was assessed using Ramsey Score graded from 1 to 6 where 1 is anxious or restless and 6 exhibits no response. Patients who develop sedation >4 were recorded. Post-operative nausea and vomiting (PONV) was scored by the same nurse who recorded VAS values, at the same intervals, by using a system of 0 - 2 where 0 means no nausea, 1 means nausea without vomiting and 2 for vomiting. Nausea lasting >10 min or vomiting

was treated with 1 mg granisetron intravenously. Number of patients who developed urine retention was recorded.

Rescue analgesic regimen in the form of pethidine 0.5 mg/Kg intravenously was given if the VAS on cough was >4. The number of patients who received rescue analgesic and frequency of rescue analgesic needed was recorded. Patient satisfaction was evaluated and recorded at the 48 hours after operation, rating 0% to 100%, varying from very unsatisfied to a very satisfied, respectively.

Statistical analysis

Statistical analysis was performed using SPSS 14 software (SPSS Inc., Chicago, Illinois). Data were tested for normality using Kolmogorov-Smirnov test. Un-paired Student's t test and *Mann-Whitney U* test were used as appropriate. For Comparison of the incidence of side effects, Chi-square test was required. Data were expressed as mean±SD, percentage, or median (range). A value of $P < 0.05$ was considered to represent statistical significance.

Based upon previous studies data, a prior power analysis indicated that 17 patients in each group would be a sufficient sample size to detect a 20% reduction in post-operative analgesic requirements, with type-I error of 0.05 and a power of approximately 80%. To compensate for possible dropouts, we increased the sample size to 20 patients in each group.

RESULT

Patients in the 2 treatment groups had similar demographic characteristics [Table 1]. Pre-operative diagnosis and surgical procedures are listed in Table 2. After an induction of anesthesia, no patient in both groups needed additional fentanyl doses throughout the surgery.

Table 1: Patient characteristics

| | Intrathecal morphine (n=20) | Paravertebral block (n=20) | P value |
|--|-----------------------------|----------------------------|---------|
| Age (yr) | 38.1 (±15.2) | 38.5 (±12.1) | 0.426 |
| Sex (M/F) | (16/4) | (14/6) | 0.157 |
| Weight (kg) | 76.3 (±16.6) | 74.6 (±13.0) | 0.174 |
| Height (cm) | 171.1 (±8.44) | 169.4 (±5.12) | 0.098 |
| Operative time (min) | 156.75 (±40.23) | 161.25 (±31.49) | 0.333 |
| Rescue drug | 4 patients | 2 patients | 0.0256* |
| Pethidine consumptions | 73.75 (±8.5) | 65 (±12) | 0.0256* |
| Total bupivacaine consumption in 1 st 24 h (mg) | 86±28 | 438±78 | |
| Total bupivacaine consumption in 2 nd 24 h (mg) | 104±32 | 493±69 | |

Data are expressed as mean±SD, P value < 0.05 is considered significant

On arrival to recovery room, up to 18 hours, there were no statistical differences in the visual analogue score (VAS) at rest [Figure 1] and on coughing [Figure 2] between both groups. However, VAS was significantly higher in both

groups at 24 hours at rest and on coughing ($P<0.001$), respectively.

Table 2: Preoperative diagnosis and surgical procedures in each group

| Surgical procedure | Group | | Total number | % | P value |
|--|---------------|-----|--------------|------|---------|
| | I | II | | | |
| Pulmonary resection (pneumonectomies, lobectomies, Segmentectomies) | 5 | 712 | 30 | NS | |
| Pericardiectomies | 3 | 2 | 5 | 12.5 | NS |
| Decortications | 3 | 4 | 7 | 17.5 | NS |
| Lung cyst excision | 4 | 4 | 8 | 20 | NS |
| Esophageal surgery | 3 | 2 | 5 | 12.5 | NS |
| Mediastinal mass excision | 2 | 1 | 3 | 7.5 | NS |
| Surgical procedure (total number) | 40 Procedures | | | | |

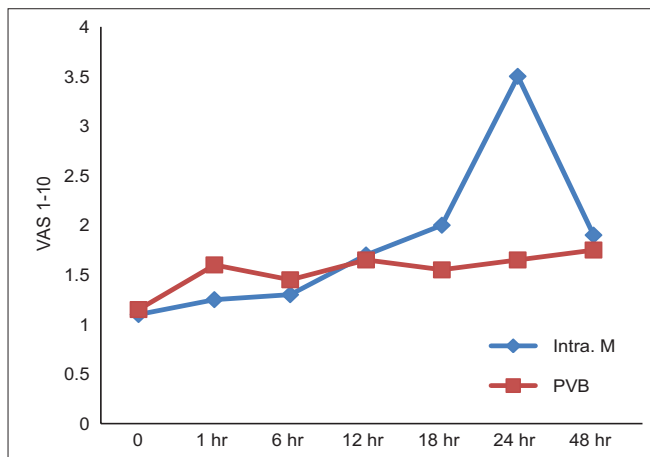


Figure 1: Visual analogue score of pain on rest

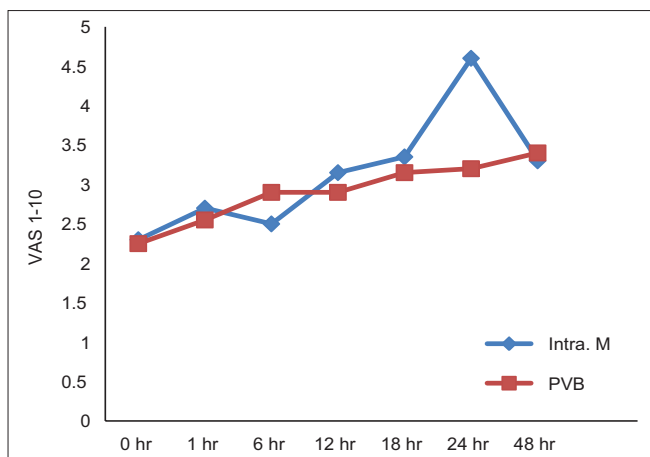


Figure 2: Visual analogue score of pain on cough

In group I (intrathecal morphine group), the total bupivacaine dose consumption in the 1st 24 hours was 86 ± 28 mg and in next 24 hours, 103 ± 41 mg, and also the bupivacaine consumption was significantly higher in 2nd 24 hours in comparison to 1st 24 hours. The total bupivacaine consumption in group II (PPCA) was 438 ± 78 mg in the 1st 24 hours and (493 ± 69 mg) in the next 24 hours. In comparison to group I, bupivacaine consumption was statistically highly significant in group II in 1st 24 hours as well as in 2nd 24 hours. ($P<0.001$). No patients in both groups required further analgesic rescue at 1, 6, 12 hours after operation. At 18 hours, 2 patients in group I required rescue pethidine vs. only 1 patient in group II ($P>0.05$). Only 2nd half of 24 hours, as a total 6 patients (30%), required rescue analgesia while in group II, only 2 patients (10%) required rescue analgesia ($P>0.05$). This is statistically not significant.

There was no incidence of hemodynamic instability in both groups throughout the study, and no patient developed desaturation ($SaO_2<95\%$) at any time through the study period. None of the patients in group I had post-dural puncture headache (PDPH) during hospital stay. Nausea and vomiting were higher in group I (25%) vs. in group II (10%) ($P>0.05$), which is statistically not significant.

In group I, 4 patients experienced pruritis that was treated once with promethazine 0.25 mg/kg intramuscularly, and 2 patients (10% of patients) developed mild sedation (score 2 with Ramsey score) but did not need any pharmacological intervention. 2 patients (10% of patients) in group I developed urinary retention and needed bladder catheterization [Table 3]. No signs of local anesthetic toxicity were detected in any of our patients who were under close observation, either those in SICU or those in the surgical ward during the 48 hours. At the end of 48 hours post-operatively, the degree of satisfaction did not show any statistical significance between both groups ($P>0.05$) [Table 3].

DISCUSSION

This study showed that intrathecal administration of morphine 0.3 mg before an induction of anesthesia for patients undergoing thoracotomy resulted in satisfactory reduction in visual analogue score (VAS), both at rest and on coughing, and the pain relieve is comparable to patients (group II) with paravertebral patient control analgesia (PPCA) with bupivacaine 0.25% in the 1st 48 hours post-operatively. In intrathecal morphine group (group I), the consumption of bupivacaine is almost 5 times less

Table 3: Secondary outcome in intrathecal and paravertebral groups

| | Intrathecal morphine gp | Paravertebral gp | P value |
|-----------------------------|-------------------------|------------------|---------|
| Nausea | 4/20 | 1/20 | 0.436 |
| Vomiting | 1/20 | 1/20 | 0.436 |
| Pruritis | 4/20 | 0/20 | 0.333 |
| Hypotension (>20% decrease) | 0/20 | 0/20 | NS |
| Sedation | 2/20 | 0/20 | 0.333 |
| Respiratory depression | 0/20 | 0/20 | NS |
| Urinary retention | 2/20 | 0/20 | 0.333 |
| ICU admission | 17/20 | 14/20 | 0.157 |
| Patient satisfaction | 79% | 86% | NS |

in 1st 24 hours postoperatively and about 4 time less in 2nd 24 hours. This is because in this group, patients were comfortable with the spinal morphine and they seldom used PCA. But, in group I, if we compare 1st 24 hours VAS and bupivacaine consumption to 2nd 24 hours, bupivacaine consumption by PPCA is significantly higher in 2nd 24 hours. It shows that after 24 hours, the effect of epidural morphine was not good enough to provide analgesia alone and require an addition of paravertebral block by bupivacaine. This idea to use intrathecal morphine with or without paravertebral block in order to know the effectiveness of intrathecal morphine was suggested before in an editorial published in British Journal of Anesthesia in 2007.^[5] Jebara *et al.* compared the analgesic efficacy of intrathecally administered combination of morphine and sufentanil with that of thoracic epidural for post-thoracotomy pain relief and showed that intrathecal opioid administration offered analgesia that is comparable with that of thoracic epidural infusion of bupivacaine and fentanyl.^[11]

The thoracic paravertebral block was compared with thoracic epidural for post-thoracotomy pain relief in many previous studies.^[12-16] In a recent systematic review and meta-analysis for comparison between thoracic epidural and paravertebral block for thoracotomy, it was found that there was no difference between both techniques in term of analgesia, however; paravertebral blockade was considered superior to thoracic epidural in terms of pulmonary function and reduction of complications.^[17] Another systematic review by Joshi *et al.* as a part of “The Procedure-Specific Postoperative Pain Management” (PROSPECT) working group in collaboration of anesthesiologists and surgeons who are working to formulate evidence –based recommendations for pain management that are specific for different surgical procedures stated that paravertebral block provide a comparable pain relief to thoracic epidural with superior side effect profile.^[18] This study is the 1st prospective, randomized study that compared intrathecal morphine

and thoracic paravertebral in terms of analgesia and side effects on patients undergoing thoracotomy for different procedures. Our results showed that lumbar intrathecal morphine, combined with intravenous paracetamol, provided an excellent level of analgesia both at rest and on cough for 24 hours and even comparable to group II in 2nd 24 hours. After 24 hours postoperatively in intrathecal morphine group, there were more consumption of pethidine in comparison to paravertebral block group, but pethidine consumption was comparable and not significantly high. It may be because, we used 0.3 mg of morphine instead of 0.2 mg morphine as used in previous randomized control trail in 30 patients given intrathecal morphine 0.2 mg with sufentanil 20 micro gram, and this randomized control trail was associated with significant reduction in pain intensity for 24 hours.^[19] But, when the study period extended to 48 post-operative hours, IV morphine consumption using PCA was found to be decreased only during the 1st 24 hours.^[20] A longer lasting analgesia, extending for an average of 30 hours, was reported with the use of a dose of 500 mg intrathecal morphine in patients undergoing coronary artery bypass grafting surgery. However, more side effects were encountered.^[21]

Patients were satisfied with this level of analgesia during 1st 24 hours postoperatively, based on the low frequency of rescue analgesic request. Usually, pain is most severe within the first post-operative day, and intrathecal opioids found to be efficacious for analgesia during this time. The 2nd 24 hours in spinal morphine group (group I) when effect of spinal morphine decreased, and VAS was increased, patients in this group started using PCA more and more, and total bupivacaine requirement was increased in 2nd 24 hours. Using of PCA to gather with intrathecal morphine was also suggested before, in an editorial discussing the optimal technique for post-thoracotomy pain relief.^[5]

Multimodal post-operative analgesia is a cornerstone of treatment for major thoracic and upper abdominal surgery.^[12] For this reason, we added paracetamol IV for both groups, and this may have contributed to the improved quality of analgesia during the 1st 24 hours in the intrathecal group. Concomitant parenteral opioid administration is a known risk factor for respiratory depression with the use of neuraxial opioids.^[22] Therefore, we relied on a non-opioid analgesic (paracetamol) 15 mg/kg/IV as regular analgesic supplement while pethidine 0.5 mg/kg IV was given only when the pain persists after paracetamol administration.

The incidence and severity of side effects in our study were acceptable and easily-controlled. There were no serious or life-threatening complications. Compared to complications of other techniques (as epidural hematomas, epidural abscess, and spinal cord injury in

case of thoracic epidural,^[16] or dural puncture-leading total spinal anesthesia, post-dural puncture headache^[23] and pulmonary hematomas^[24] that have been occasionally reported after thoracic paravertebral approach), intrathecal opioid administration is considered simple, easy, and safe alternative technique for pain relief after thoracotomy. In addition, these techniques need some level of skills and experiences to be performed safely. Added to the limitations with thoracic epidural or paravertebral catheters insertion, management of analgesia with these techniques need careful follow-up and observation and more manpower for refilling procedure. Also, dealing with these techniques need educated and dedicated nursing staff that are trained in the use of standardized acute pain service and can deliver the treatment properly.

The nausea and vomiting in our study is in the normal range of incidence compared with previous studies. One previous study, involving 5969 patients, reported the incidence of intrathecal opioid side effects like pruritis, nausea were 37, 25, and respiratory depression 3%, respectively.^[9] Nausea and vomiting in group II occurred in the same patient, and it was related to intravenous pethidine given to that patient. Not all patients admitted to intensive care unit as routine. Only those patients who need intensive care based on his ASA status or has comorbid diseases is the one admitted for closer observation.

In conclusion, intrathecal morphine 0.3 mg given preoperatively with concomitant paracetamol 1 gram intravenous every 6 hourly could be easy, safe, and adequate technique for post-operative pain relief for 48 hours after thoracic surgery with no significant side effects. The simplicity of this technique gives a solution in case of other techniques, like thoracic epidural or thoracic paravertebral block is not feasible due to lack of experience or difficulties in performance of these techniques.

REFERENCES

- Gottschalk A, Steven P. Cohen, Yang S, Ochroch EA. Preventing and treating pain after thoracic Surgery. *Anesthesiology* 2006;104:594-600.
- Ochroch EA, Gottschalk A, Augostides J, Carson KA, Kent L, Malayaman N, *et al.* Long-term pain and activity during recovery from major thoracotomy using thoracic epidural analgesia. *Anesthesiology* 2002;97:1234-44.
- Kavanagh B, Katz J, Sandler A. Pain control after thoracic surgery. *Anesthesiology* 1994;81:737-59.
- Cook TM, Riley RH. Analgesia following thoracotomy: A survey of Australian practice. *Anaesth Intensive Care* 1997;25:520-4.
- Ng A, Swanevelde J. Pain relief after thoracotomy: Is epidural analgesia the optimal technique? *Br J Anaesth* 2007;98:159-62.
- Casati A, Alessandrini P, Nuzzi M, Tosi M, Lotti E, Ampollini L, *et al.* A prospective, randomized, blinded comparison between continuous thoracic paravertebral and epidural infusion of 0.2% ropivacaine after lung resection surgery. *Eur J Anaesthesiol* 2006;23:999-1004.

- Wang JK, Nauss LA, Thomas JE. Pain relief by intrathecally applied morphine in man. *Anesthesiology* 1979;50:149-51.
- Gustafsson LL, Schildt B, Jacobsen K. Adverse effects of extradural and intrathecal opiates: Report of a nationwide survey in Sweden. *Br J Anaesth* 1982;54:479-86.
- Gwitz KH, Young JV, Byers RS, Alley C, Levin K, Walker SG, *et al.* The safety and efficacy of intrathecal opioid analgesia for acute postoperative pain: seven years' experience of 5969 surgical patients at Indiana University Hospital. *Anesth Analg* 1999;88:599-604.
- Yapici D, Altunkan ZO, Atici S, Bilgin E. Postoperative effects of low-dose intrathecal morphine in coronary artery bypass surgery. *J Card Surg* 2008;23:140-5.
- Jebara SM, Adaimé C, Yazigi A, Haddad F. Thoracic epidural and intrathecal analgesia have similar effects on pain relief and respiratory function after thoracic surgery. *Can J Anesth* 2005;52:710-6.
- Pertunen K, Nilsson E, Heinonen J, Hirvisalo E-L, Salo JA, Kalso E. Extradural, paravertebral and intercostal nerve blocks for post-thoracotomy pain. *Br J Anaesth* 1995;75:541-7.
- Richardson J, Sabanathan S, Eng J, Mearns AJ, Rogers C, Evans CS, *et al.* Continuous intercostal nerve block versus epidural morphine for postthoracotomy analgesia. *Ann Thorac Surg* 1993;55:377-80.
- Matthews PJ, Govenden V. Comparison of continuous paravertebral and extradural infusions of bupivacaine for pain relief after thoracotomy. *Br J Anaesth* 1989;62:204-5.
- Marret E, Bazelly B, Taylor G, Lambert N, Deleuze A, Mazoit J, Bonnet F. Paravertebral block with ropivacaine 0.5% versus systemic analgesia for pain relief after thoracotomy. *Ann Thorac Surg* 2005;79:2109-13.
- Richardson J, Sabanathan S, Jones J, Shah RD, Cheema S, Mearns AJ. A prospective randomized comparison of preoperative and continuous balanced epidural or paravertebral bupivacaine on post-thoracotomy pain, pulmonary function and stress response. *Br J Anaesth* 1999;83:387-92.
- Davies RG, Myles PS, Graham JM. A comparison of analgesic efficacy and side effects of paravertebral vs epidural blockade for thoracotomy- a systematic review and meta-analysis of randomized trials. *Br J Anaesth* 2006;96:418-26.
- Joshi GP, Bonnet F, Shah R, Wilkinson RC, Camu F, Fischer B, *et al.* A systematic review of randomized trials evaluating regional techniques for postthoracotomy analgesia. *Anesth Analg* 2008;107:1026-40.
- Mason N, Gondret R, Junca A. Intrathecal sufentanil and morphine for post-thoracotomy pain relief. *Br J Anaesth* 2001;86:236-40.
- Chaney MA, Furry P, Fluder EM, Slogoff S. Intrathecal morphine for coronary artery bypass grafting and early extubation. *Anesth Analg* 1997;84:241-8.
- Vanstrum GS, Bjornson KM, Ilko R. Postoperative effects of intrathecal morphine in coronary artery bypass surgery. *Anesth Analg* 1988;67:261-7.
- Shapiro A, Zohar E, Zaslansky R, Hoppenstein D, Shabat S, Fredman B. The frequency and timing of respiratory depression in 1524 postoperative patients treated with systemic or neuraxial morphine. *J Clin Anesth* 2005;17:537-42.
- Sharrock NE. Postural headache following thoracic somatic paravertebral nerve block. *Anesthesiology* 1980;52:360-2.
- Thomas PW, Sanders DJ, Berrisford RG. Pulmonary haemorrhage after percutaneous paravertebral block. *Br J Anaesth* 1999;83:668-9.

How to cite this article: Zeid HA, Siddiqui AK, Elmakrem EF, Ghonaimy Y, Al Nafea A. Comparison between intrathecal morphine with paravertebral patient controlled analgesia using bupivacaine for intraoperative and post-thoracotomy pain relief. *Saudi J Anaesth* 2012;6:201-6.

Source of Support: Nil, **Conflict of Interest:** None declared.