

## [ Athletic Training ]

# Grip Lock Injury in Male Gymnasts

Emily M. Bezek, MD,\* Ann E. VanHeest, MD,\*† and Douglas T. Hutchinson, MD‡

**Background:** Grip lock is a high bar injury in male gymnastics and occurs while the gymnast is rotating around the high bar. Its mechanism and treatment have been poorly documented.

**Study Design:** Case reports.

**Results:** One gymnast sustained an extensor tendon injury and ulnar styloid fracture and was treated nonoperatively. The second gymnast sustained open fracture of the radius and ulna with extensor tendon ruptures and was surgically treated. Both gymnasts healed and were able to return to collegiate gymnastics despite residual finger extensor lag.

**Conclusions:** Grip lock is a physically and psychologically devastating injury on the men's high bar that can cause forearm fractures and extensor tendon injuries at the wrist (Zone 8), which may result in residual extensor tendon lag. Injuries may be prevented with proper grip fit, appropriate maintenance of grips, and limited duration of use, as well as education of athletes, athletic trainers, and coaches

**Keywords:** gymnastics; wrist injuries; grip lock

Grip lock was first described in the medical literature by Samuelson et al<sup>11</sup> and is known to most male gymnasts, athletic trainers, and coaches. Over a 10-year period, the researchers reported that 38% of responding college coaches had a gymnast who sustained a grip lock injury and that 84% of coaches were aware of a gymnast who had sustained a grip lock injury.<sup>11</sup> The grip used in men's gymnastics for the high bar is a leather dowel that wraps around the wrist and middle 3 fingers (Figure 1). When the injury occurs, the leather dowel becomes locked around the high bar while the gymnast's momentum continues to carry his body through the element. The leather of the grip at the fingertips becomes caught around the bar near the palm as the grip tightens and locks (Figure 2). The bone and/or soft tissues of the forearm, wrist, and hand fail as the torque increases.

## CASE REPORT OF GYMNAST A

A 20-year-old right-hand-dominant male Division I college gymnast sustained a grip lock injury while preparing to dismount the high bar. As he used an overgrip position (ie, holding the bar with the palm facing away), his right dowel grip locked. A teammate supported him by providing counterweight while the injured athlete unwrapped his locked grip.

Twenty-four hours later, the athlete was brought to the orthopaedic clinic with superficial palm abrasions, large

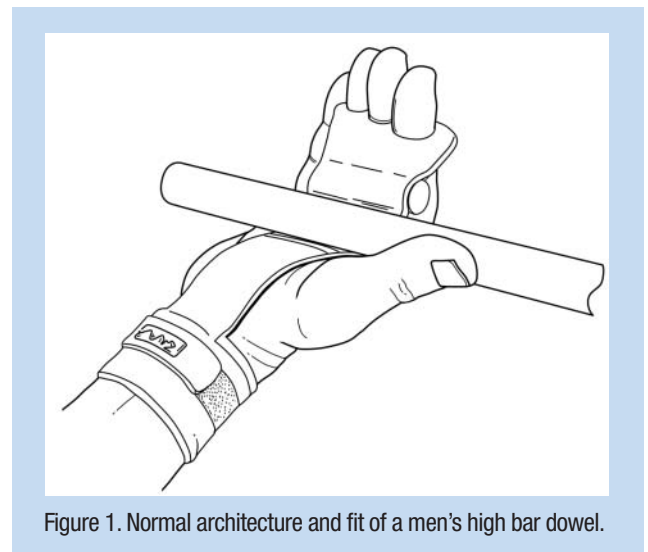


Figure 1. Normal architecture and fit of a men's high bar dowel.

ecchymoses, and edema dorsally over the wrist. Physical examination revealed an extension lag of his index finger at the metacarpophalangeal joint of 60°. Pain was reproducible with gentle, passive flexion of the fingers along the dorsal forearm. Radiographs demonstrated an ulnar styloid avulsion fracture, and a fluoroscopic exam showed a minimal increase

From the \*University of Minnesota, Minneapolis, Minnesota, and the ‡University of Utah, Salt Lake City, Utah

†Address correspondence to Ann E. VanHeest, University of Minnesota, Orthopaedic Surgery, 2450 Riverside Avenue, Suite R200, Minneapolis, MN 55454 (e-mail: vanhe003@umn.edu).

No potential conflict of interest declared.

DOI: 10.1177/1941738109347965

© 2009 The Author(s)

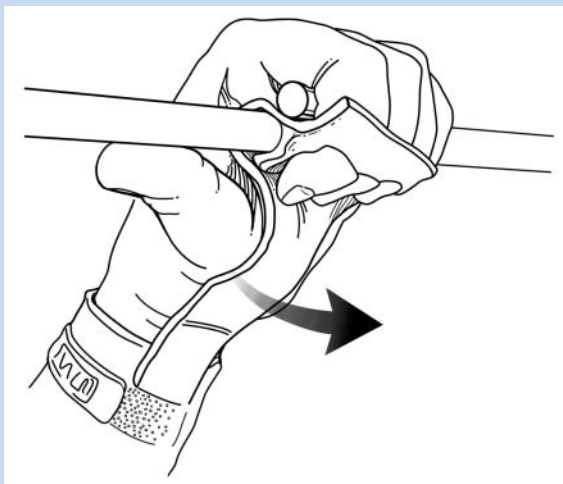


Figure 2. Mechanism of grip lock injury.

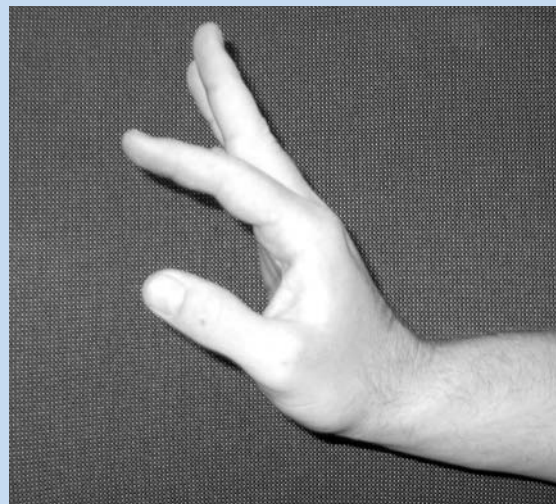


Figure 3. Gymnast A's residual deficit: extensor indicis proprius extension lag.

Table 1. Clinical progress of Gymnast A.<sup>a</sup>

	Wrist Extension	Wrist Flexion	Radial Deviation	Ulnar Deviation	Grip Strength	Index Finger Extensor Lag
Immediate postinjury	— / 10°	— / 25°				80°
3 months	75° / 60°	85° / 85°	25° / 20°	40° / 40°	95 / 75	40°
2.5 years	60° / 65°	55° / 75°	35° / 35°	20° / 20°	115 / 122	35°

<sup>a</sup>Left (unaffected) / right (injured).

in scapholunate interval. An MRI revealed signal alteration in the triangular fibrocartilage complex, strain of the pronator quadratus, edema of the extensor digitorum communis tendon at the muscular tendinous junction, effusion of the distal radial ulnar joint, and a dorsal ligament contusion. The recommended treatment was nonoperative: a short arm cast for 4 weeks. The index and long fingers were buddy-taped with limited passive flexion to protect the injured extensor digitorum communis.

One month postinjury, the cast was removed, and the index finger lag demonstrated 30° of improvement (ie, less extensor lag). The extensor indicis proprius and extensor digitorum communis tendon-muscle groups were protected, limiting passive flexion with a custom splint worn full-time for 1 month, then worn nighttime for an additional month.<sup>12</sup> Three months postinjury, radiographs showed union of the ulnar styloid. The splint was discontinued and strengthening exercises were started. Four months postinjury, some gymnastic activities were allowed, and then advanced over time with buddy-taping of his index and middle fingers and a wrist guard splint.

Full competition at a National Collegiate Athletic Association Division I level was allowed, which started at 5 months postinjury. At a 2.5-year follow-up, the athlete reported no pain but continued to feel apprehensive because of his previous injury. Range of motion and grip strength were normal, other than the 35° extensor indicis proprius lag (Table 1 and Figure 3). The distal radial ulnar joint was stable, but he did report crepitus in it.

### CASE REPORT OF GYMNAST B

An 18-year-old right-hand-dominant high school senior sustained a grip lock injury while preparing to dismount the high bar using an overgrip position (pronated). A nearby mobile apparatus was placed under his feet allowing him to unwrap his locked grip. There was a visible open fracture of his radius and ulna (Figure 4), as well as rapid and severe wrist swelling. The gymnast was taken to the operating room for an irrigation and debridement of the contaminated wound with subsequent reduction and plating of radial and ulnar fractures.<sup>1,3,4,9</sup> A complete rupture of the extensor digitorum

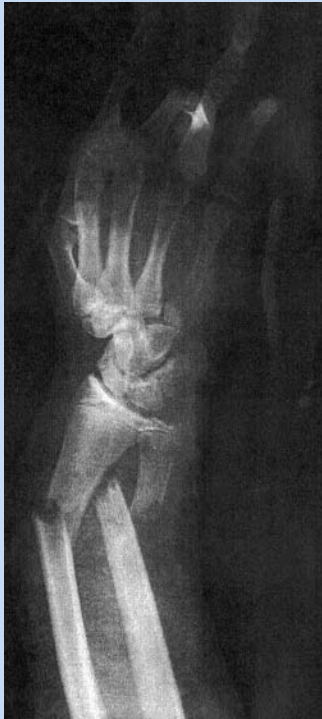

Figure 4. Gymnast B's anteroposterior radiograph of radius and ulna fractures at the time of injury.

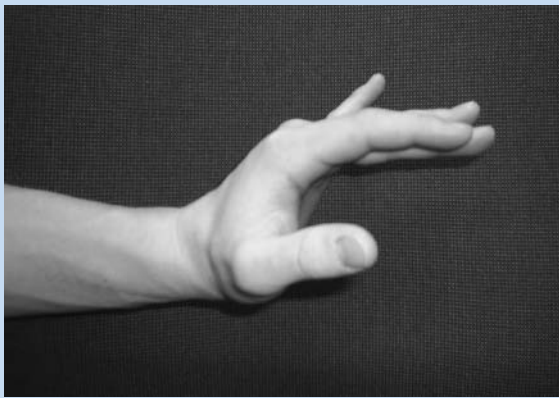


Figure 5. Gymnast B's residual deficit: extensor digitorum communis extension lag.

communis of the index finger at the musculotendinous junction was noted. The extensor digitorum communis to the middle, ring, and little fingers were elongated intramuscularly, as visualized at the time of surgery.

Clinic follow-up 10 days postoperatively showed a metacarpophalangeal extension lag of the middle 3 digits, indicating rupture of the extensor digitorum communis at the musculotendinous junction and thereby requiring a second repair.

At 10 weeks postinjury, the gymnast could actively extend fingers at the metacarpophalangeal joint with the wrist in neutral but not in extension. While making a fist, the gymnast was unable to flex his wrist beyond neutral. With fingers extended, he could flex his wrist  $10^\circ$  indicating extension contractures of the digit and wrist. An extensor tenolysis and extensor digitorum communis muscle-tendon unit lengthening was then performed in an attempt to improve wrist flexion. Postoperatively, the gymnast was splinted in neutral, allowing active and passive range of motion of the fingers during early rehabilitation.<sup>8</sup>

At 2.5 years postinjury, he had residual extension lag ( $10^\circ$ ) of his middle 3 fingers with his wrist in extension (Figure 5). He also had a  $45^\circ$  loss of wrist flexion.

## DISCUSSION

Grip lock injuries can produce a spectrum of extensor tendon injury and can cause forearm fractures. Evaluation should include radiographs and, if necessary, an MRI to evaluate the extent of tendon injury. Extensor tendon injuries can be treated conservatively or surgically, depending on the extent of injury. Extensor tendon lag and loss of wrist range of motion may occur.<sup>11</sup> Despite these residual deficits, both gymnasts returned to collegiate gymnastics.

The dowel grip used for men's high bar serves 2 functions: to decrease the shear forces created between the palm and the bar and to improve grip strength. The grip serves this utility well with little complication when maintained properly. Grip lock injuries can occur if the grip is well worn and stretched.<sup>2,11</sup>

Worn and stretched grips<sup>11</sup> are vulnerable to locking. Gymnasts often use the same grips for months to years for a variety of reasons (comfort, superstition, economy). Both these gymnasts had their hands in the overgrip (pronated) position when they grip-locked. Samuelson et al<sup>11</sup> found that 15 of 23 gymnasts were in a position of shoulder internal rotation with forearm hyperpronation at the time of grip lock injury. These grip positions lead to similar extensor tendon injuries.<sup>11</sup> Although traumatic rupture of extensor tendons at the musculotendinous junction is rare,<sup>6,10,12</sup> biomechanical models simulating stretched extensor tendon injuries demonstrate intramuscular elongation and eventual failure by rupture at the musculotendinous junction.<sup>5,7</sup>

Grip lock injuries in women have not been reported—likely because women compete on the large-diameter uneven bars, do not have dowels in their grips, have smaller hands, and usually weigh less than men. In addition, women do not create the repetitive large forces on the grips that men do in their routines.

Educating athletic trainers, coaches, parents, and most important, gymnasts is the key to preventing grip lock injuries. Gymnasts must be aware of this relatively rare but potentially serious injury.

## REFERENCES

1. Anderson LD, Sisk D, Tooms RE, Park WI III. Compression-plate fixation in acute diaphyseal fractures of the radius and ulna. *J Bone Joint Surg Am.* 1975;57:287-297.
2. Daly RM, Bass SL, Finch CF. Balancing the risk of injury to gymnasts: how effective are the counter measures? *Br J Sports Med.* 2001;35:8-18 (quiz 19).
3. Dobyys JH, Gabel JT. Gymnast's wrist. *Hand Clin.* 1990;6:493-505.
4. Gabel GT. Gymnastic wrist injuries. *Clin Sports Med.* 1998;17:611-621.
5. Garrett WEJ, Nikolaou PK, Ribbeck BM, Seaber AV. The effect of muscle architecture on the biomechanical failure properties of skeletal muscle under passive extension. *Am J Sports Med.* 1988;16:7-12.
6. Kameyama M, Shiraishi T. Traumatic rupture of the extensor digitorum communis and extensor digit minimi at the musculotendinous junction associated with volar dislocation of the distal radioulnar joint: a case report. *Hand Surg.* 2000;5:165-168.
7. McMaster PE. Tendon and muscle ruptures: clinical and experimental studies on the causes and location of subcutaneous ruptures. *J Bone Joint Surg Am.* 1933;15:705.
8. Minamikawa Y, Peimer CA, Yamaguchi T, Banasiak NA, Kambe K, Sherwin FS. Wrist position and extensor tendon amplitude following repair. *J Hand Surg [Am].* 1992;17:268-271.
9. Moss JP, Bynum D. Diaphyseal fractures of the radius and ulna in adults. *Hand Clin.* 2007;23:143-151.
10. Redden JF. Closed acute traumatic rupture of extensor pollicis longus tendon: a report of two cases. *Hand.* 1976;8:173-175.
11. Samuelson M, Reider B, Weiss D. Grip lock injuries to the forearm in male gymnasts. *Am J Sports Med.* 1996;24:15-18.
12. Takami H, Takahashi S, Ando M, Suzuki K. Traumatic rupture of the extensor tendons at the musculotendinous junction. *J Hand Surg [Am].* 1995;20:474-477.

For reprints and permission queries, please visit SAGE's Web site at <http://www.sagepub.com/journalsPermissions.nav>.