

Hybrid Treatment of Coexisting Renal Artery Aneurysm and Abdominal Aortic Aneurysm in a Gallbladder Cancer Patient

Hyuk Jae Jung and Sang Su Lee

Division of Vascular and Endovascular, Department of Surgery, Pusan National University Yangsan Hospital, Yangsan, Korea

Renal artery aneurysm (RAA) is uncommon, and the coexistence of an abdominal aortic aneurysm (AAA) is an extremely rare condition with potentially high life-threatening mortality in case of rupture. Aneurysms can be treated by endovascular intervention or open surgery. Although most of aneurysms are treated by endovascular intervention, open surgery is often necessary for RAAs associated with the proximal renal bifurcation or the branches in the distal renal arteries. We report a rare case of coexisting RAA with AAA treated by hybrid method, consisting of endovascular aneurysm repair for AAA and open surgery for RAA located adjacent to the distal branches of the renal artery.

Key Words: Renal artery aneurysm, Abdominal aortic aneurysm, Endovascular aneurysm repair, Open surgery

Received April 2, 2014

Revised May 6, 2014

Accepted May 7, 2014

Corresponding author: Sang Su Lee

Division of Vascular and Endovascular,
Department of Surgery, Pusan National
University Yangsan Hospital, 20 Geumo-
ro, Mulgeum-eup, Yangsan 626-770,
Korea

Tel: 82-55-360-2124

Fax: 82-55-360-2154

E-mail: phoenixdr@naver.com

Conflict of interest: None.

Copyright © 2014, The Korean Society for Vascular Surgery

This is an Open Access article distributed under the terms of the Creative Commons Attribution Non-Commercial License (<http://creativecommons.org/licenses/by-nc/3.0>) which permits unrestricted non-commercial use, distribution, and reproduction in any medium, provided the original work is properly cited.

Vasc Spec Int 2014;30(2):68-71 • <http://dx.doi.org/10.5758/vsi.2014.30.2.68>

INTRODUCTION

Coexisting renal artery aneurysm (RAA) and abdominal aortic aneurysm (AAA) is an extremely rare clinical entity with associated morbidities including hypertension and rupture, and the precise incidence has not been well reported. RAA is diagnosed in 0.015% to 1% of the general population [1]. RAA is the second most common visceral artery aneurysm after splenic artery aneurysm and before common hepatic artery aneurysm [2]. Four types of RAA have been described: macroaneurysms, dissecting RAA, aneurysms associated with fibromuscular dysplasia, and microaneurysms associated with arteritis [3,4]. We report a rare case of coexisting RAA with AAA treated by hybrid method, which consisted of endovascular aneurysm repair (EVAR) for AAA and open surgery for RAA located adjacent to the distal branches of the renal artery.

CASE

A 75-year-old man was admitted to our outpatient clinic complaining of an abdominal palpable mass. He also presented with intermittent pain on his left flank and epigastrium. He had been free from multiple myeloma for the last 5 years. He had no past history of cardiac and respiratory problems. On physical examination, a tender pulsatile mass was palpable around the umbilical area and other systems did not reveal any abnormal findings. His blood pressure was maintained between 120/80 mmHg and 130/90 mmHg, and hematological laboratory findings were found to be normal. A contrast enhanced computed tomography (CT) scan with 3-dimensional reconstruction showed an AAA measuring 5.0 cm×4.8 cm, another RAA measuring 3.0 cm×2.8 cm in the left renal artery, and suspected gallbladder (GB) cancer (Fig. 1). We decided to operate on the coexisting aneurysm and GB cancer, because

he his pain originated from the aneurysm, and the size of the AAA and RAA were 5.0 cm and 3.0 cm in diameter. All possible treatment modalities including open surgery and endovascular treatment were discussed, and we chose to start with insertion of a stent graft for RAA and EVAR for AAA.

On general anesthesia, the patient was placed in the supine position and open bilateral transfemoral access to the common femoral artery was obtained via femoral artery cutdown. After contralateral Jung and Lee 7F sheath insertion, a wire was successfully accessed into the left RAA. However, due to the distal location of the RAA the wire could not be passed into the branches of the renal artery distal to the RAA. We decided to change our plan, with the AAA being treated first by EVAR and the RAA and GB cancer were subsequently treated by open surgery. Using a Zenith endovascular graft (Cook Corp., Bloomington, IN, USA), the AAA was successfully treated by EVAR. After 9 days, we operated on the RAA and GB cancer by open surgery. The reason for the delayed operation was to allow the patient to recover from EVAR. A single incision was made along both subcostal borders, extending from the right mid-axillary line to the left

mid-axillary line. The peritoneal cavity was entered, and routine exploration was done. The small intestine was eviscerated and packed into a bowel bag, and the lateral peritoneal attachments of the left colon were dissected from the sigmoid colon to the splenic flexure. The left colon and mesentery were reflected medially. The RAA was safely exposed by meticulous dissection, and the multiple branches of the distal arteries at the level of the left renal hilum were visualized, as seen previously on angiography (Fig. 2). Intravenous heparin was injected before proximal and distal renal artery control with vessel loops. As the renal artery was redundant enough for direct anastomosis, total excision of RAA and end-to-end anastomosis was safely done (Fig. 3). Total clamping time of the renal artery was 10 minutes. After total excision of the RAA, the hepatobiliary surgical team performed the operation for GB cancer, which was done by partial hepatectomy around the GB including retropancreatic and hepatoduodenal lymph node dissection. Meticulous hemostasis was achieved and the wound was closed by layers. Postoperative laboratory findings including CBC and renal function tests were normal. The stage of GB cancer was T1bN0M0, stage IA. Postoperative CT scan with 3-dimensional reconstruction showed good

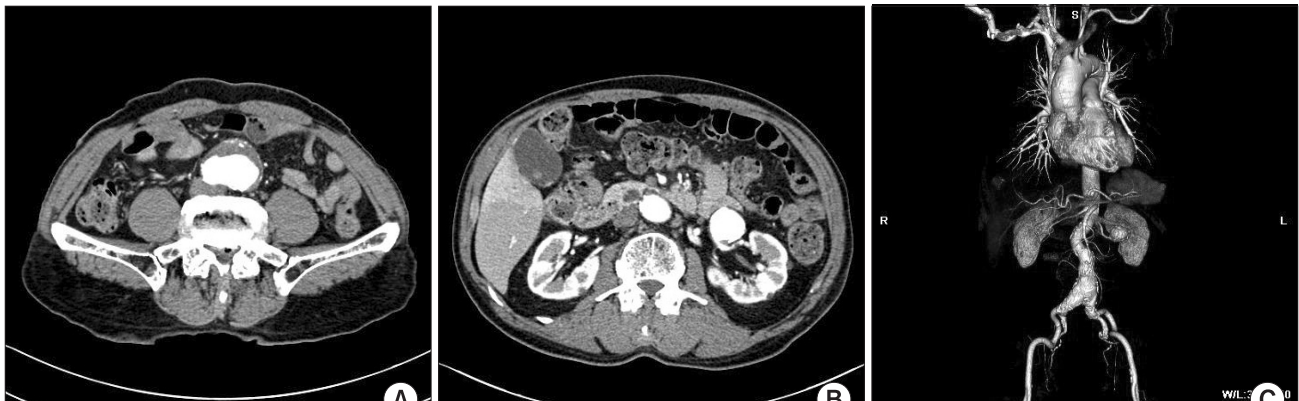


Fig. 1. Preoperative contrast enhanced computed tomography scan with 3-dimensional reconstruction showed abdominal aortic aneurysm (A) and renal artery aneurysm (B) in the left renal artery in axial and three dimensional reconstruction (C).

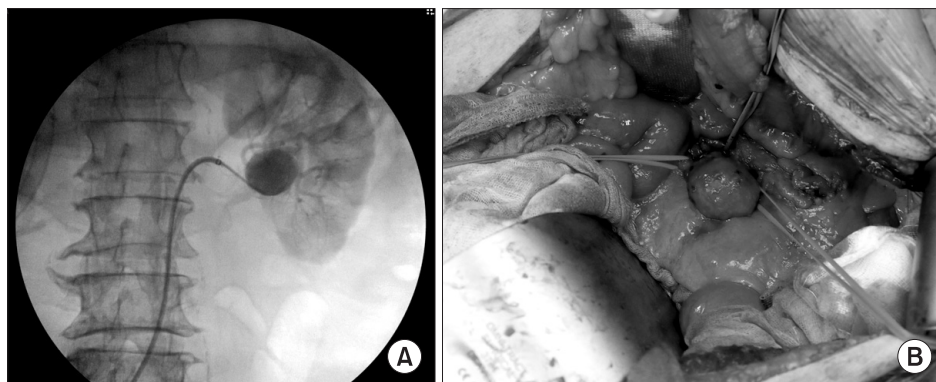


Fig. 2. Intraoperative angiogram showed renal artery aneurysm located distally (A), and 3 cm sized aneurysm in gross finding (B).

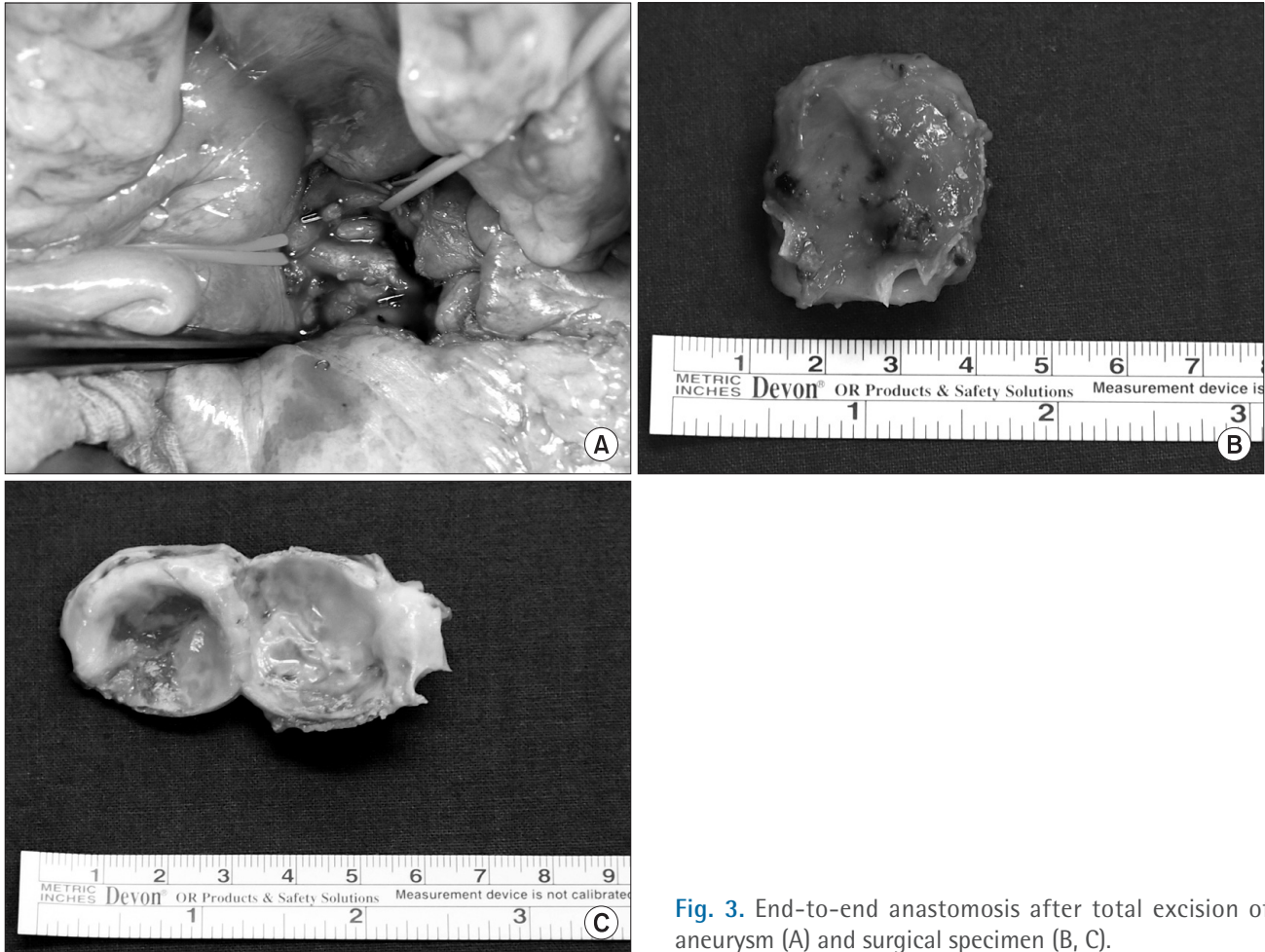


Fig. 3. End-to-end anastomosis after total excision of aneurysm (A) and surgical specimen (B, C).

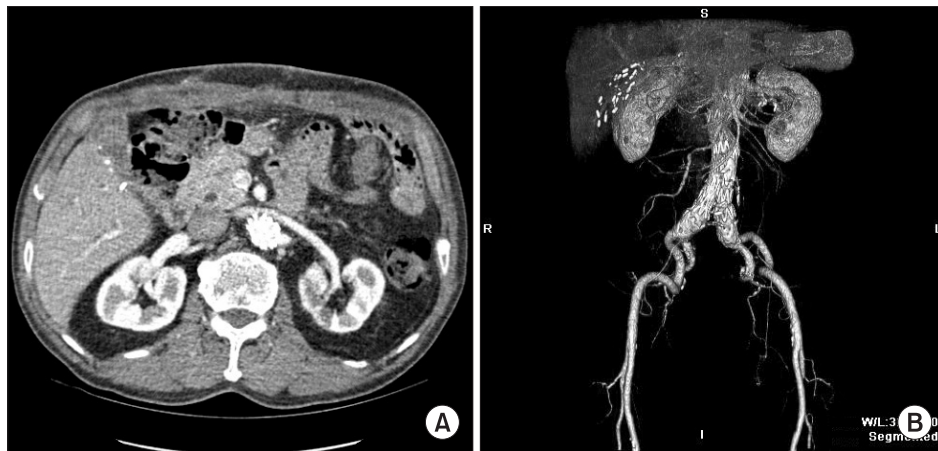

Fig. 4. Postoperative contrast enhanced computed tomography scan with 3-dimensional reconstruction showed intact renal artery in axial view (A) and complete aortic stent for abdominal aortic aneurysm (B).

renal artery blood flow without any signs of left kidney infarct, no endoleak around the aortic stent graft, and no bile leakage or bleeding around the liver (Fig. 4). The final pathologic report stated that the specimen of the RAA was 6.0×3.0 cm in size, showing extensive degeneration and hyalinization with calcification. The pathology of the GB

was adenocarcinoma. The patient was discharged without any complications.

DISCUSSION

Coexisting AAA and RAA is an extremely rare and

uncommon condition. Matsagas et al. [5] reported a case of RAA incidentally found during AAA operation. Callicutt et al. [6] also reported 12 cases of multiple idiopathic aneurysms in pediatric patients. Visceral aneurysms including RAA are also rare conditions, yet they have a high mortality rate of up to 70% in case of rupture [7]. Visceral artery aneurysms are seen more often these days with the more widespread use of ultrasound, CT and angiography [8]. The risk of rupture in RAA is generally low, no more than 5% [9], but in case of a rupture, the chance of nephrectomy is very high [9,10]. The indications for treatment of RAA are rupture, symptom presentation, enlarging nature, size larger than 2 cm, pregnancy and portal hypertension scheduled for liver treatment [10]. Even though endovascular stent

graft and coil embolization are usually indicated for RAA treatment [11], RAA located adjacent to the branches of the renal artery may require surgical repair such as direct anastomosis, bypass, aneurysmectomy, laparoscopic or robot-assisted repair [10]. We successfully treated AAA by EVAR and RAA by total excision of aneurysm and direct end-to-end anastomosis. Although endovascular treatment is a feasible technique for RAA, in case of RAA with multiple distal branches, it may require surgical approach for repair. We report a rare case of coexisting RAA with AAA successfully treated by hybrid method, consisting of EVAR for AAA and excision of aneurysm with direct end-to-end anastomosis for RAA due to the proximity with the distal branches of the renal artery in a GB cancer patient.

REFERENCES

- 1) Knobloch K, Wiebe K, Lichtenberg A, Fischer S, Gohrbandt B, Haverich A. Ex vivo repair and renal autotransplantation for complex renal artery aneurysms in a solitary kidney. *Ann Vasc Surg* 2005;19:407-410.
- 2) Pulli R, Dorigo W, Troisi N, Pratesi G, Innocenti AA, Pratesi C. Surgical treatment of visceral artery aneurysms: A 25-year experience. *J Vasc Surg* 2008;48:334-342.
- 3) Stanley JC, Rhodes EL, Gewertz BL, Chang CY, Walter JF, Fry WJ. Renal artery aneurysms. Significance of macroaneurysms exclusive of dissections and fibrodysplastic mural dilations. *Arch Surg* 1975;110:1327-1333.
- 4) Kang J, Kang WC, Choi ST, Lee WS, Kim JH. Symptomatic renal artery aneurysm dealt with aneurysmectomy and patch closure. *Korean J Vasc Endovasc Surg* 2012;28:48-51.
- 5) Matsagas MI, Mitsis M, Batsis C, Rigopoulos C, Kappas AM. A renal artery aneurysm incidentally found at operation. Should it be resected? *Int Angiol* 2004;23:189-191.
- 6) Callicutt CS, Rush B, Eubanks T, Abul-Khoudoud OR. Idiopathic renal artery and infrarenal aortic aneurysms in a 6-year-old child: case report and literature review. *J Vasc Surg* 2005;41:893-896.
- 7) Gehlen JM, Heeren PA, Verhagen PF, Peppelenbosch AG. Visceral artery aneurysms. *Vasc Endovascular Surg* 2011;45:681-687.
- 8) Henke PK, Cardneau JD, Welling TH 3rd, Upchurch GR Jr, Wakefield TW, Jacobs LA, et al. Renal artery aneurysms: a 35-year clinical experience with 252 aneurysms in 168 patients. *Ann Surg* 2001;234:454-462.
- 9) Chen R, Novick AC. Retroperitoneal hemorrhage from a ruptured renal artery aneurysm with spontaneous resolution. *J Urol* 1994;151:139-141.
- 10) Gallagher KA, Phelan MW, Stern T, Bartlett ST. Repair of complex renal artery aneurysms by laparoscopic nephrectomy with ex vivo repair and autotransplantation. *J Vasc Surg* 2008;48:1408-1413.
- 11) Klein GE, Szolar DH, Breinl E, Raith J, Schreyer HH. Endovascular treatment of renal artery aneurysms with conventional non-detachable microcoils and Guglielmi detachable coils. *Br J Urol* 1997;79:852-860.