



ELSEVIER

Contents lists available at ScienceDirect

JSES International

journal homepage: [www.jseinternational.org](http://www.jseinternational.org)

## Image-derived instrumentation vs. conventional instrumentation with 3D planning for glenoid component placement in reverse total shoulder replacements: a randomized controlled trial

Pamela Boekel, MBBS (Hons), MSc<sup>a,b,\*</sup>, Matthew Rikard-Bell, MBBS<sup>a,b</sup>,  
 Andrea Grant, BSpExSci<sup>a</sup>, Benjamin Brandon, MBBS<sup>a,b</sup>, Kenji Doma, PhD<sup>a,c</sup>,  
 William B. O'Callaghan, MBBS<sup>a,d</sup>, Matthew Wilkinson, MBBS<sup>a,e</sup>,  
 Levi Morse, BMBS (Hons)<sup>a,b</sup>

<sup>a</sup>Orthopaedic Research Institute of Queensland, Pimlico, Queensland, Australia

<sup>b</sup>Department of Orthopaedic Surgery, Townsville University Hospital, James Cook University, Townsville, Queensland, Australia

<sup>c</sup>Department of Sports and Exercise Science, James Cook University, Townsville, Queensland, Australia

<sup>d</sup>Department of Orthopaedic Surgery, Cairns Hospital, Cairns, Queensland, Australia

<sup>e</sup>Department of Orthopaedic Surgery, Royal Hobart Hospital and Calvary Care, University of Tasmania, Hobart, Tasmania, Australia

### ARTICLE INFO

#### Keywords:

Image-derived instrumentation  
 Reverse total shoulder arthroplasty  
 3D preoperative planning  
 Orthopedic surgery  
 Arthroplasty  
 Patient-specific instrumentation

Level of evidence: Level I; Randomized  
 Controlled Trial; Treatment Study

**Hypothesis:** Glenoid baseplate positioning for reverse total shoulder arthroplasty (rTSA) is important for stability and longevity, with techniques such as image-derived instrumentation (IDI) developed for improving implant placement accuracy. We performed a single-blinded randomized controlled trial comparing glenoid baseplate insertion accuracy with 3D preoperative planning and IDI jigs vs. 3D preoperative planning and conventional instrumentation.

**Methods:** All patients had a preoperative 3D computed tomography to create an IDI; then underwent rTSA according to their randomized method. Repeat computed tomography scans performed at six weeks postoperatively were compared to the preoperative plan to assess for accuracy of implantation. Patient-reported outcome measures and plain radiographs were collected with 2-year follow-up.

**Results:** Forty-seven rTSA patients were included (IDI  $n = 24$ , conventional instrumentation  $n = 23$ ). The IDI group was more likely to have a guidewire placement within 2mm of the preoperative plan in the superior/inferior plane ( $P = .01$ ); and exhibited a smaller degree of error when the native glenoid retroversion was  $> 10^\circ$  ( $P = .047$ ). There was no difference in patient-reported outcome measures or other radiographic parameters between the two groups.

**Conclusion:** IDI is an accurate method for glenoid guidewire and component placement in rTSA, particularly in the superior/inferior plane and in glenoids with native retroversion  $> 10^\circ$ , when compared to conventional instrumentation.

© 2023 The Author(s). Published by Elsevier Inc. on behalf of American Shoulder and Elbow Surgeons. This is an open access article under the CC BY-NC-ND license (<http://creativecommons.org/licenses/by-nc-nd/4.0/>).

The reverse total shoulder arthroplasty (rTSA) was initially developed as a treatment modality for chronic rotator cuff tear arthropathy in the elderly.<sup>5,27,47</sup> Over the past 10 years, rTSA has demonstrated excellent clinical outcomes and prosthesis longevity.<sup>1</sup> As a result, the indications and use of the rTSA has significantly expanded.<sup>29</sup> Critical to the overall success of any

Ethics committee approval was granted by Mater Health Service North Queensland (reference no. HREC/18/QTHS/133).

\*Corresponding author: Pamela Boekel, MBBS (Hons), MSc, FRACS (Orth), Orthopaedic Research Institute of Queensland, 7 Turner Street, Pimlico, Queensland, Australia 4812.

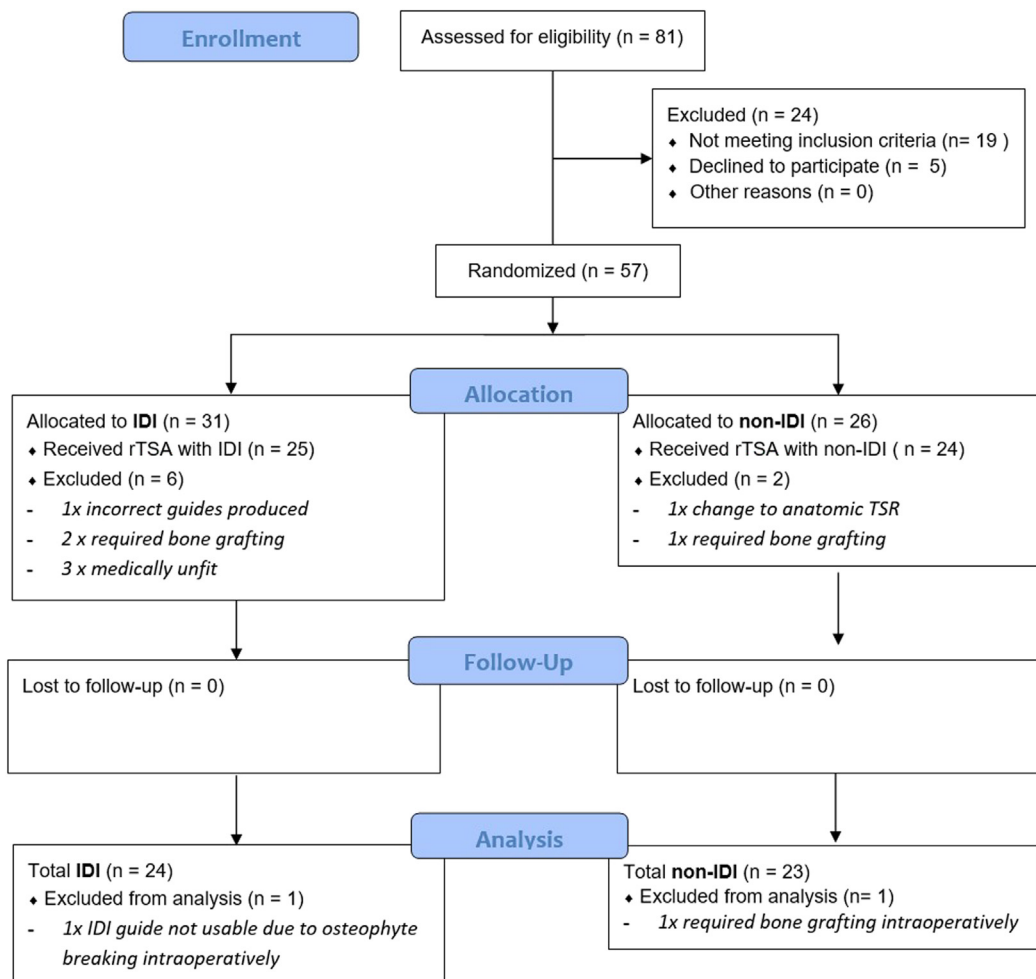
E-mail address: [pamboekel@hotmail.com](mailto:pamboekel@hotmail.com) (P. Boekel).

<https://doi.org/10.1016/j.jseint.2023.03.004>

2666-6383/© 2023 The Author(s). Published by Elsevier Inc. on behalf of American Shoulder and Elbow Surgeons. This is an open access article under the CC BY-NC-ND license (<http://creativecommons.org/licenses/by-nc-nd/4.0/>).

shoulder arthroplasty procedure is the accurate location and orientation of the glenoid implant,<sup>36,45</sup> as malpositioning of the glenoid component predisposes to prosthetic instability, loosening or even failure, necessitating revision surgery.<sup>3,4,15,16,35</sup>

The development of 3D computed tomography (CT) images as part of preoperative planning has been reported to improve the accuracy of glenoid placement.<sup>21,34</sup> Despite this, the surgeon's ability to accurately position the glenoid component can still be limited, particularly when facing complex glenoid deformities or when there are no reliable intraoperative landmarks for reference.<sup>44</sup> As a result, computer-assisted technologies, including image-derived instrumentation (IDI), have been developed in an attempt to improve the surgeon's intraoperative accuracy of



**Figure 1** CONSORT flow diagram of recruitment for our RCT. CONSORT diagram template accessed from <https://www.consort-statement.org/consort-statement/flow-diagram0>. CONSORT, Consolidated Standards Of Reporting Trials; RCT, randomized controlled trial; IDI, image-derived instrument.

glenoid placement when compared to conventional instrumentation (non-IDI) alone.<sup>34</sup>

IDI involves generating a custom surgical guide that can be utilized intraoperatively. It is often referred to as “patient-specific instrumentation;” however, this term is trademarked by a company not used in this study, so we will be referring to this technology using the alternative name. The surgical guide is derived from a preoperative 3D CT, with a digital plan for guidewire, glenoid baseplate, and screw placement which is planned by the surgeon using the planning software. A 3D rendered model is fabricated, with a separate jig for guidewire placement which uses bony landmarks to assist in accurate placement. In the case of the IDI guides used for this study, the guide is clipped onto the glenoid using a u-shaped cuff which sits around the base of the coracoid and superior glenoid. A paper hardcopy of this digital plan is also printed, with static images in several planes available for additional reference. This surgical guide enables the surgeon to preoperatively visualize and plan prosthesis placement; and in patients with severe deformity, to plan for bone grafting or a specialized prosthesis. It also serves as an intraoperative tactile surgical tool that can guide glenoid guidewire (and therefore baseplate) accuracy, ensuring appropriate version and inclination.<sup>37</sup> The implementation of IDI has been validated across several cadaveric and clinical studies as an accurate and reliable means of executing the preoperative 3D plan in vitro and in vivo.<sup>10,17-19,31,40,46</sup> However, there remains a

paucity of in vivo clinical studies comparing whether IDI is more accurate than non-IDI.<sup>44</sup>

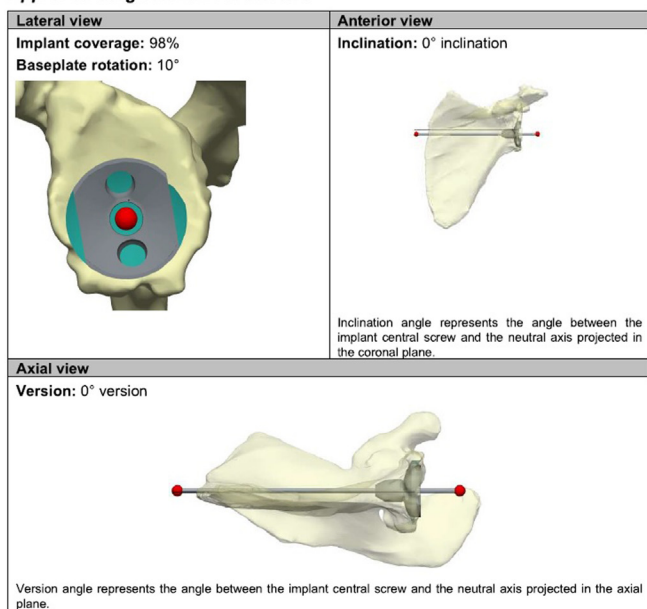
This prospective randomized controlled trial (RCT) was designed to compare the accuracy of glenoid baseplate placement when using IDI with 3D planning vs. 3D planning alone in patients undergoing rTSA. Our secondary aim was to assess if use of the IDI guide leads to differences in patient-reported outcome measures (PROMS), postoperative complications (eg. dislocation or fracture), and radiographical outcomes (loosening, lysis or scapular notching).

### Methods

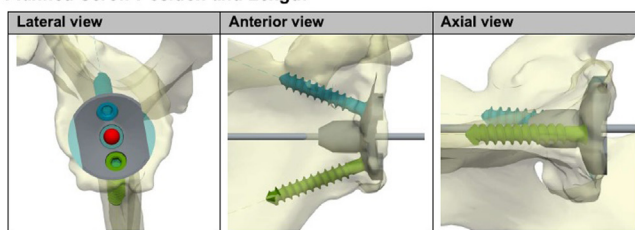
This study was conducted as a single-center, single-blinded, prospective randomized clinical trial that was registered with anzctr.org.au (ACTRN12618001011279) and approved by the institutional review board (approval no. HREC/18QTHS/133). Study consent was obtained with procedure consent by the senior investigating surgeon, who performed all operations for the study (L.M.).



All eligible consecutive patients between May 2019 and August 2020 who were booked for a primary rTSA and who agreed to undergo a 6-week postoperative 3D CT were asked to participate in the study (Fig. 1). Patients were deemed eligible if they were able to provide informed consent and had primary osteoarthritis of the

**Approved Surgical Plan Parameters**



**Planned Screw Position and Length**



Screw	Planned length
	35mm
	40mm

Parameter	Approved value
Implant	L1 Primary MB
Baseplate size	STD
Sup(+)/Inf(-) inclination	0°
Ante(+)/Retro(-) version	0°
Baseplate rotation	10°
Implant coverage*	98%
Central reaming depth*	4mm
Glenosphere	44mm UHMWPE (not in US)
Glenosphere rotation	0°

\* Implant coverage and central reaming depth values are for reference only and subject to intraoperative variables.

**Figure 2** Excerpts of the preoperative 3D surgical plan, which is printed and available for viewing during surgery, to assist visualization of guidewire and baseplate placement.

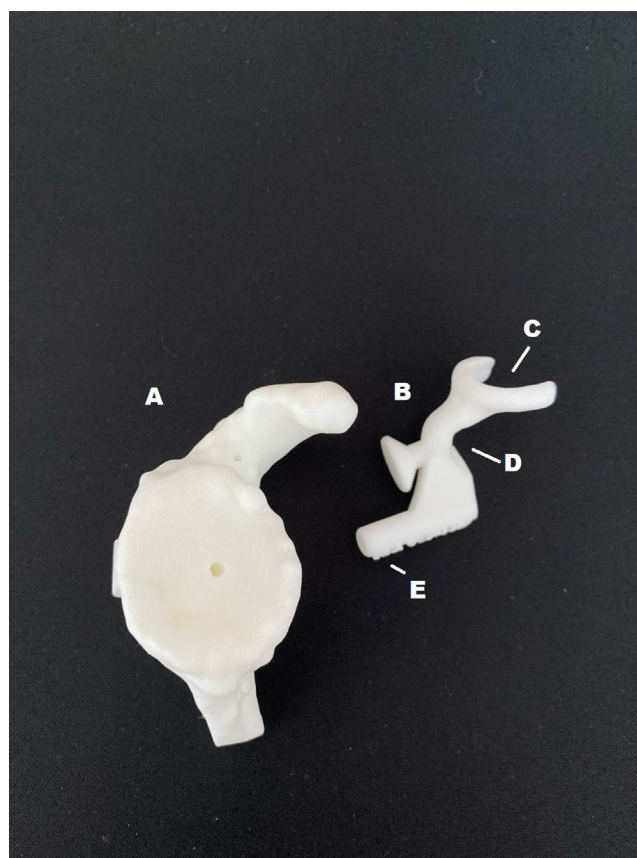
shoulder or rotator cuff arthropathy that required a primary rTSA. Exclusion criteria from the study included the following: revision arthroplasty operations, operations requiring bone grafting or other glenoid sided augmentations, rheumatoid arthritis, fracture, or post-traumatic arthritis. These patients were excluded as their presentations and baseline anatomy were either not amenable to a standard Lima Systema Multiplana Randelli (SMR) rTSA or so heterogeneous that it would add an unacceptable bias into our results. All patients received a preoperative 3D CT to permit preoperative planning using Materialise (Materialise, Leuven, Belgium) software before undergoing surgery, regardless of whether they were randomized to IDI or non-IDI groups. The senior investigating surgeon completed the preoperative plan for all patients to place the glenoid in an optimal position for baseplate contact with the glenoid. All patients received a Lima SMR rTSA (Lima Corporate, Udine, Italy). Both companies involved were blinded to patient randomization preoperatively, and Materialise were blinded when reviewing the follow-up CT scans postoperatively.

**Randomization**

Randomization occurred at the time of enrollment in the study and was performed offsite by the nonclinical research coordinator (A.G.) to limit randomization bias. Randomization was performed with a 1:1 allocation ratio with a block-of-X randomization method using our institution’s research database program. Neither the consenting physician nor the patients were aware of the block size, order of randomization, or allocation. Patients remained blinded throughout the entirety of the treatment. The treating surgeon was informed of the group allocation immediately after randomization. No patient was reassigned after randomization.

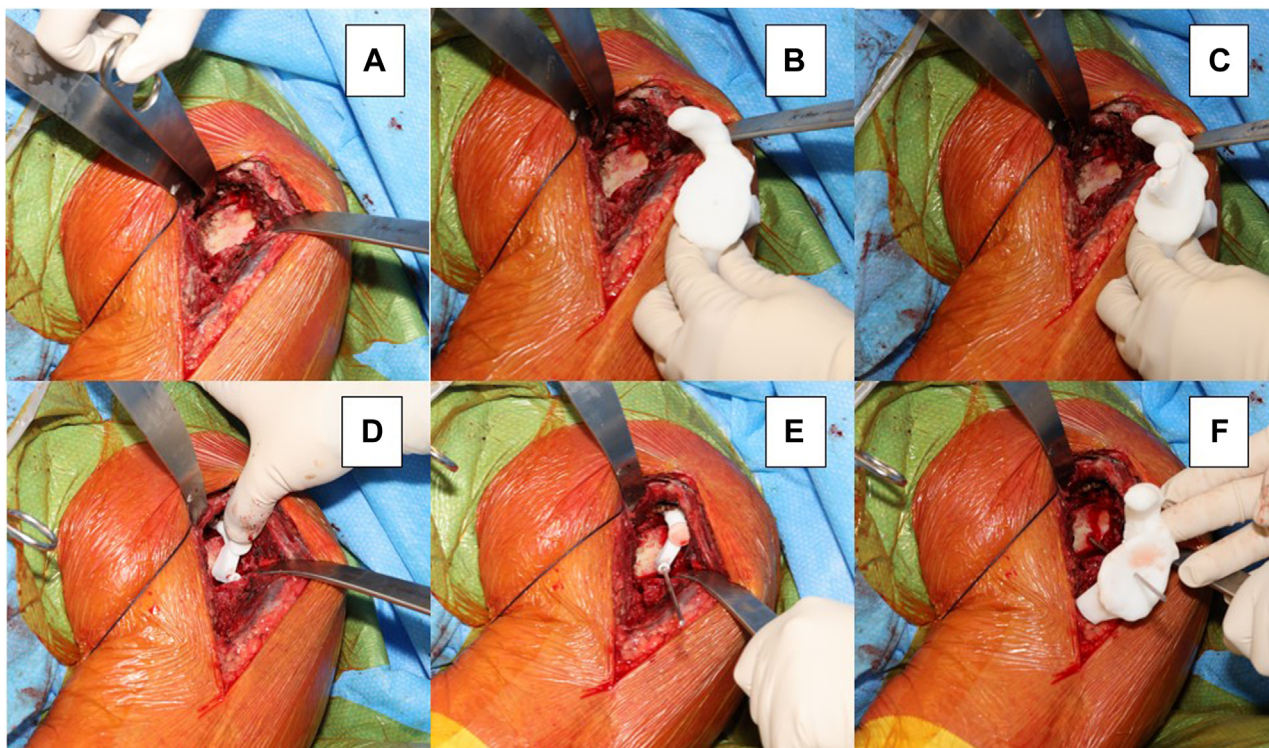
**Sample size**

A priori sample size calculation was conducted (G\*power 3.1.9.2) for 2 independent groups (IDI vs. non-IDI). The effect size (ES), statistical power, and alpha level were set as 0.25, 0.80 and 0.05, respectively, which generated a total sample size of 44 (22 per



**Figure 3** A CT derived 3D model of a patient’s glenoid, which is sterilized for use intraoperatively (A), the “image-derived instrument” (B), which attaches to the base of the coracoid (C) and is contoured to fit the glenoid anatomy (D) to ensure a secure fit. This allows accurate passage of the glenoid guidewire (E). CT, computed tomography.

group). To compensate for potential follow-up loss, 50 patients were recruited in total (25 per group). This would yield a similar sample size to that of Iannotti,<sup>24</sup> a similar RCT investigated IDI with



**Figure 4** Surgical steps for using the IDI guide: (A) Prepare the glenoid, exposing the base of the coracoid; (B) Use the 3D guide to help visualize guidewire placement; (C) See how the IDI guide seats on the glenoid face and base of coracoid on the model; (D) Seat the IDI guide to the position of best fit; (E) Pass the guidewire for the glenoid reamer through the IDI guide; (F) Secondary check of guidewire placement with 3D model. *IDI*, image-derived instrument.

**Table 1**  
Demographic information for IDI vs. non-IDI rTSA.

Demographic	IDI	Non-IDI	P Value	ES or $\chi^2$
Gender			.10	$\chi^2 = 2.56$
Male	16 (61.5%)	10 (38.5%)		
Female	8 (38.1%)	13 (61.9%)		
Side			.55	$\chi^2 = 0.03$
Left	10 (52.6%)	9 (47.4%)		
Right	14 (50%)	14 (50%)		
Age	69.3 ± 6.8	69.8 ± 7.3	.81	ES = 0.07
BMI	31.8 ± 5.9	29.6 ± 6.7	.23	ES = 0.35
Diagnosis			.41	$\chi^2 = 1.88$
Osteoarthritis	15 (55.6%)	12 (44.4%)		
Cuff arthropathy	8 (42.1%)	11 (57.9%)		
Other	1 (100.0%)	0 (0.0%)		
Glenoid classification			.37	$\chi^2 = 4.27$
A1	8 (53.3%)	7 (46.7%)		
A2	2 (40.0%)	3 (60.0%)		
B1	11 (50.0%)	11 (50.0%)		
B2	2 (100.0%)	0 (0.0%)		
C	0 (0.0%)	2 (100.0%)		
Surgical time	78.4 ± 16.3	74.8 ± 10.3	.42	ES = 0.27

BMI, body mass index; *IDI*, image-derived instrument; *ES*, effect size; *rTSA*, reverse total shoulder arthroplasty.

### 3D planning compared to conventional instrumentation with 2D planning.

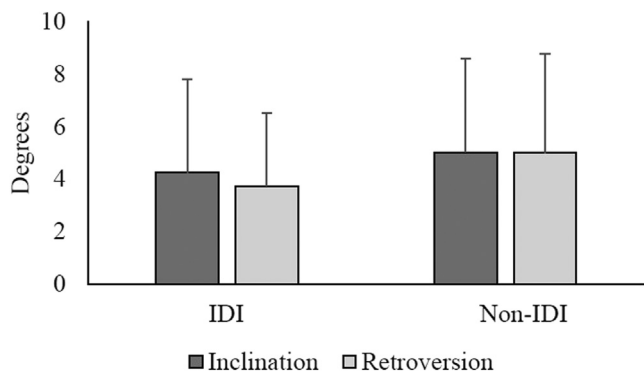
#### Preoperative planning

All patients underwent a 3D CT to permit software modeling by Materialise. A Digital Imaging and Communications in Medicine file was sent for each patient to Materialise for the creation of a pre-operative plan using their proprietary planning software. The senior investigating surgeon planned the implant position using the

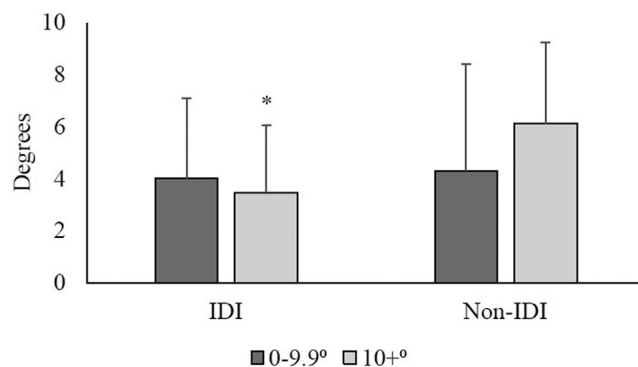
Materialise software for all patients prior to randomization. Following approval, Materialise executed the surgeon’s preoperative glenoid placement parameters (as seen in Fig. 2). The Materialise engineers were blinded to group allocation for both pre- and post-plan evaluation. The same engineer cohort used for Materialise’s regular commercial activities were utilized to perform these tasks using standard company operating parameters and protocols. Once approved, the completed plan for the IDI group was manufactured by Materialise and shipped to the hospital site for sterilization and used during the procedure if needed; those patients randomized to standard instrumentation had their jigs discarded at time of surgery. The IDI guides required a round time of three weeks for manufacturing and delivery.

#### Surgical technique

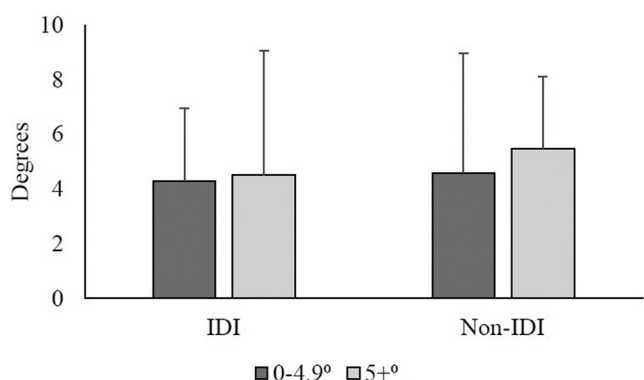
All rTSA were performed according to standard protocols used by the senior investigating surgeon. The deltopectoral approach was used for all participants included in the analyses. The recommended surgical technique for the implantation of prostheses was in keeping with the Lima SMR surgical technique, which uses the Grammont-style implant of a medialized glenoid and medialized humerus. The key surgical difference between groups was the preparation of the glenoid and insertion of the glenoid guidewire to permit face reaming. In the non-IDI control group, this portion of the procedure was performed as per standard Lima surgical technique with sufficient clearance of glenoid labrum and soft tissues to permit identification of bony landmarks and thereby permit appropriate orientation and insertion of the glenoid reaming guidewire. For this technique, the printed preoperative plan was viewed (Fig. 2), but the 3D guide and jig were not used (Fig. 3). The surgical steps for the IDI group are seen in Fig. 4; the base of the coracoid was exposed to allow exact seating of the 3D printed guide



**Figure 5** Bar graph depicting changes from planned to actual measures for inclination and retroversion between the IDI and non-IDI groups. *IDI*, image-derived instrument.



**Figure 7** Bar graphs depicting changes from planned to actual measures between the IDI and non-IDI groups, for patients where their natural retroversion was  $\leq 9.9^\circ$  or  $\geq 10.0^\circ$ . (Significantly lower degree of error for IDI group when glenoid retroversion  $\geq 10.0^\circ$  denoted with \*). *IDI*, image-derived instrument.



**Figure 6** Bar graphs depicting changes from planned to actual measures for patients where their natural inclination was  $\leq 4.9^\circ$  or  $\geq 5.0^\circ$  between the IDI and non-IDI groups. *IDI*, image-derived instrument.

placement between the two groups when compared to the original preoperative plan. A difference of  $>2$  mm from the planned guidewire placement was chosen as an acceptable margin of error.

*Follow-up*

Patients are undergoing the routine follow-up by the investigating surgeon. This includes recording PROMS preoperatively, then at six months postoperatively, and yearly intervals thereafter. The PROMS used are the Oxford Shoulder Score (OSS), the American Shoulder and Elbow Surgeons Shoulder score (ASES), and the Constant-Murley Shoulder Outcome score (CMS). Due to the COVID-19 pandemic and limited face-to-face consultations, the CMS was only collated to the one-year postoperative time point. Plain radiographs of the shoulder were also collated at these same time points; and assessed for complications such as dislocation, loosening, and scapular notching (using the Sirveaux method<sup>38</sup>). Complications were also noted as part of these postoperative follow-up reviews.

*Statistical analysis*

All data were analyzed using the Statistical Package of Social Sciences (SPSS version 25; IBM, Armonk, NY, USA). According to the Shapiro-Wilk’s test, the majority of the parameters were normally distributed. Thus, the continuous parameters were reported as mean  $\pm$  standard deviation, while categorical parameters were reported as frequency and proportions. Independent samples t-test was used to compare the continuous parameters between the IDI and non-IDI groups. The categorical parameters were compared between the IDI and non-IDI groups using the chi-square test. The inferential statistics were conducted with the alpha level set at 0.05. The magnitude of differences between the IDI and non-IDI groups for the continuous parameters were determined using ES calculations (Cohen’s d), with values of 0.2, 0.5, and 0.8 considered as small, moderate, and large ES calculations.<sup>9</sup> With regards to PROMS, intention to treat analysis was used, assigning the “worst case scenario” score when data were not available or missing.

**Results**

*Patient recruitment*

Of 81 eligible patients, 57 participants were enrolled in the study. Twenty-four declined to participate (n = 5) or did not meet all inclusion criteria (n = 19). Eight patients were withdrawn

to facilitate guidewire insertion. The IDI jig was referenced against the provided 3D model to visually confirm correct jig placement by the treating surgeon. Following glenoid preparation, there was no further difference in standard rTSA surgical technique. Data points were recorded prospectively through the case by the research coordinator (Table 1).

**Postoperative protocol**

All rTSA study patients received standard postoperative care; with an additional 3D CT scan performed six weeks postoperatively to permit radiographic evaluation of the glenoid baseplate implant position. An orthopedic metal artefact reduction algorithm was applied to the scan data to improve image quality.

Postoperative CTs were assessed by Materialise engineers (who were blinded to the method used) to determine the final glenoid baseplate parameters. To do so, for each sample, the postoperative scapula 3D model (with glenoid baseplate) was registered against the preoperative scapula 3D model. The postoperative glenoid baseplate position parameters were calculated as per the preoperative coordinate system. The deviation in parameters were established by comparing the postoperative data to the planned (preoperative) glenoid baseplate position, version, and inclination. Accuracy of guidewire placement between the IDI and non-IDI groups was compared using the preoperative guidewire placement plan as the reference point. Translational guidewire accuracy was assessed in the anterior/posterior and superior/inferior planes, that measured in millimeters the difference in guidewire

**Table II**  
Comparison of mean preoperative PROMS in rTSA with IDI and non-IDI standard instrumentation.

Group	CMS	ASES	OSS
IDI	(n = 24) 30.17 ± 17.56	(n = 22) 33.66 ± 15.11	(n = 24) 24.28 ± 7.54
Non-IDI	(n = 23) 26.61 ± 16.27	(n = 23) 35.43 ± 10.45	(n = 23) 23.13 ± 6.09
P value	.48	.64	.57

Data are presented as (number of completed PROMS), mean ± standard deviation. PROMS, patient-reported outcome measures; CMS, Constant-Murley Score; ASES, American Shoulder and Elbow Surgeons Shoulder Score; OSS, Oxford Shoulder Score; IDI, image-derived instrumentation; n, number.

**Table III**  
Comparison of mean 6-month postoperative PROMS in rTSA with IDI and non-IDI standard instrumentation.

Group	CMS	ASES	OSS
IDI	(n = 24) 68.56 ± 13.79	(n = 23) 78.07 ± 15.96	(n = 24) 40.72 ± 5.73
Non-IDI	(n = 22) 60.27 ± 16.29	(n = 23) 75.29 ± 18.84	(n = 23) 38.39 ± 6.57
P value	.06	.58	.20

Data are presented as (number of completed PROMS), mean ± standard deviation. PROMS, Patient-reported outcome measures; CMS, Constant-Murley Score; ASES, American Shoulder and Elbow Surgeons Shoulder Score; OSS, Oxford Shoulder Score; IDI, image-derived instrumentation; n, number.

from the study due to various reasons including the following: medically unfit for surgery (n = 3), surgery changed to anatomic TSR (n = 1), correct IDI guide not available on the day of surgery (n = 1), and lastly due the requirement of glenoid bone grafting (n = 3). During the analysis phase, a further 2 patients were withdrawn—one had an intraoperative fracture of a bony osteophyte with the edge of the superior glenoid, rendering the IDI jig unusable as the underlying anatomy had changed, the other required bone grafting which was identified at the time of surgery. Therefore, a total of 47 patients completed the 6-week radiographic investigations for the definitive postoperative glenoid implant positioning (IDI group n = 24, non-IDI group n = 23; Fig. 1).

**Demographics**

Table I depicts the demographic information for the IDI and non-IDI groups. The predominant diagnosis was primary osteoarthritis in both groups (P = .41). The predominant glenoid classification in both groups was B1 (P = .37). According to the continuous parameters, no significant differences were identified between the IDI and non-IDI groups for age (P = .81), body mass index (P = .23) and surgical time (P = .42).

**Accuracy**

The magnitude of change from planned to actual measures for inclination and retroversion are displayed in Fig. 5. Overall, no significant differences were found between the IDI and non-IDI groups for inclination (P = .46) and retroversion (P = .20), with small ES calculations (d = 0.22 and 0.39, respectively). Furthermore, there were no differences in inclination between IDI and non-IDI groups for patients where their natural inclination was ≤ 4.9° (P = .69) or ≥ 5.0° (P = .55), with small ES calculations (d = 0.17 and 0.27, respectively) (Fig. 6). Similarly, no differences were identified in retroversion between the IDI (n = 13) and non-IDI group (n = 13) for patients where their natural retroversion was ≤ 9.9° (P = .84) with a small ES calculation (d = 0.08). However, there was a greater degree of error for the non-IDI group (n = 11) when compared to the IDI group (n = 10) for patients where their natural retroversion was ≥ 10.0° (P = .047), with a large ES calculation (d = 0.93) (Fig. 7).

Regarding the guidewire placement accuracy, there was a significant difference in accuracy of the guidewire placement in the

superior/inferior plane in the IDI group. The IDI group was significantly more likely to have the guidewire placed within 2mm of the planned guidewire position (n = 22) compared to the non-IDI group (n = 14), (χ<sup>2</sup> = 6.21; P = .01). There was no significant difference between the two groups in terms of anteroposterior position accuracy within 2mm of preoperative plan (IDI n = 20, non-IDI n = 18), (χ<sup>2</sup> = 0.19; P = .66).

**PROMS**

Regarding the baseline preoperative PROMS, there was no significant difference between the IDI and non-IDI groups in either the CMS, ASES or OSS (Table II).

There was a significant improvement in CMS in from preoperative to 1-year postoperative using a paired t-test for the IDI group, from 30.50 ± 17.90 to 78.54 ± 9.43 (P < .001) and for the non-IDI group, from 26.61 ± 16.27 to 71.17 ± 15.23 (P < .001). However, there was no significant difference in CMS when comparing IDI with non-IDI at 6-months (Table III) or 1-year (Table IV).

There were similar improvements seen in the ASES and OSS from preoperative scores to 2-year postoperative scores using a paired t-test for both the IDI group (ASES 35.72 ± 13.92 to 83.78 ± 14.44, P < .001; OSS 24.28 ± 7.54 to 43.88 ± 4.07, P < .001) and the non-IDI group (ASES 35.43 ± 10.45 to 81.81 ± 17.42, P < .001; OSS 23.13 ± 6.09 to 39.91 ± 8.88, P < .001).

However, when comparing the IDI to non-IDI groups, there was no significant difference in ASES scores at 6-months (Table III) or 2-years (Table IV).

With the OSS, there was a significant difference between the IDI and non-IDI groups at the 2-year mark—with a significantly better score in the IDI group (43.88 ± 4.07) compared to the non-IDI group (39.91 ± 8.88), P = .04. However, given this difference is smaller than the recognized minimal clinically important difference for the OSS of a 6-point or 13% difference,<sup>26</sup> this is likely to be of little clinical effect.

**Follow-up radiographs**

In the IDI group, 13 patients had plain radiographs at the 2-year postoperative mark, with the remaining 11 patients having a 1-year postoperative radiograph. There were no complications seen of fracture, or loosening at this stage. Two patients had Sirveaux grade 1 scapular notching first seen on their 2-year X-ray.

**Table IV**  
Comparison of mean 1-year or 2-year postoperative PROMS in rTSA with IDI and non-IDI standard instrumentation.

Group	CMS (1-year)	ASES (2-year)	OSS (2-year)
IDI	(n = 23) 78.42 ± 9.01	(n = 23) 80.27 ± 18.39	(n = 24) 43.88 ± 4.07
Non-IDI	(n = 23) 71.17 ± 15.23	(n = 23) 81.81 ± 17.42	(n = 23) 39.91 ± 8.88
P value	.053	.77	.04*

PROMS, patient-reported outcome measures; CMS, Constant-Murley Score; ASES, American Shoulder and Elbow Surgeons Shoulder Score; OSS, Oxford Shoulder Score; IDI, image-derived instrumentation; n, number.

Data are presented as (number of completed PROMS), mean ± standard deviation.

\*Denotes statistical significance.

In the non-IDI group, 2 patients did not have retrievable plain radiographs. Of the remaining 21 patients, 10 had plain radiographs at the 2-year postoperative mark, with the remaining 11 patients having a 1-year postoperative radiograph. There were no complications seen of fracture, dislocation or loosening. Two patients had Sirveaux Grade 1 scapular notching (one seen on a 1-year X-ray, the other first seen on a 2-year X-ray), and 1 patient had Sirveaux Grade 2 scapular notching seen on their 1-year X-ray.

Despite the difference in numbers of notching between the two groups (IDI n = 2, non-IDI n = 3); a Mann-Whitney test indicated that this difference was not statistically significant,  $U(N_{IDI} = 24, N_{non-IDI} = 21) = 246, z = -0.35, P = .73$ , with small ES calculation ( $d = 0.11$ ). Given the small ES (small magnitude of difference between two groups) and the large U value, this sample size population is likely not large enough to detect a difference between the two groups.

### Complications

One patient in the IDI group unfortunately developed recurrent dislocations of his rTSA. He was a 65-year-old man with cuff tear arthropathy, his subscapularis tendon was not repairable at the time of index surgery; and he had an anterior dislocation following a fall in the third postoperative week, and did not seek medical attention for this until his routine follow-up at the 6-week postoperative mark. He underwent a closed reduction in the operating theater; however, he unfortunately redislocated again requiring revision surgery. At the time of revision surgery, it was noted that there was a large amount of dense scar tissue posteroinferior to the glenohumeral joint, which levered the proximal humerus anteriorly during range of movement. This scar tissue was released, the humeral stem was upsized and inserted in a 10° anteverted position with a long + lateralized liner. He had no further dislocations following this. Furthermore, he reports at 2 years to be “satisfied” with his rTSA, with an ASES of 61.67, an OSS of 36; and his CMS was 89 at 1 year; which was above his age/sex matched standard [8].

One further complication was an 82-year-old man from the non-IDI group, who developed subacromial bursitis following an influenza vaccination in his ipsilateral shoulder at the 6 months’ postoperative mark. This resolved with oral anti-inflammatory medications and with an ultrasound-guided corticosteroid injection into the subacromial space.

### Discussion

Accurate glenoid component placement is critical in the prevention of early loosening and improving long-term functional outcomes for rTSAs.<sup>14,17,20</sup> Intraoperatively, this can be challenging,<sup>17</sup> and has been aided with the development of preoperative 3D CT modelling.<sup>23,24</sup> In addition, the use of IDI guides has demonstrated to be an accurate and reliable means of executing the preoperative 3D plan intraoperatively in vivo and in vitro.<sup>2,6,10,12,13,18,19,21,23,24,30-32,34,39-41,43,44</sup> All studies have

reported significantly reduced errors or a significantly increased likelihood of achieving the planned presurgical positions with IDI compared to non-IDI.<sup>6,12,13,18,19,21,24,32,34,40</sup> Our study also confirms that IDI provides accurate and reproducible guidewire placement and glenoid baseplate positioning and orientation in rTSA relative to the preoperative 3D CT plan.

Our study demonstrated a significant improvement in accuracy in with IDI in 2 parameters: in translation in the superior/inferior plane; and when the patients’ natural retroversion was  $\geq 10^\circ$ . In all other instances, glenoid guidewire placement was consistent with the plan across the various translational planes, version and inclination between the IDI and non-IDI groups.

It is known that excessive implant retroversion of the glenoid baseplate is the cause of early loosening and failure,<sup>14,20,42,48</sup> and that accurate correction of moderate to severe glenoid retroversion is difficult.<sup>22</sup> Furthermore, malpositioning of the baseplate in the superior/inferior plane increases the risk of scapular notching, as this impacts on peg glenoid rim distance and sphere bone overhang distance.<sup>11</sup> Regarding the acceptable margin for error in the superior/inferior translational plane, we used 2mm as our cutoff value, as a 2mm change in sphere bone overhang distance<sup>8</sup> and peg glenoid rim distance<sup>28</sup> has been shown to increase rates of scapular notching. Our results suggest that the use of IDI improves the accuracy to within 2mm of the superior/inferior plane plan, and offers additional accuracy in more complicated glenoid morphologies with retroversion of  $\geq 10^\circ$ .

Furthermore, we see a benefit in generating the preoperative plan and viewing this printed preoperative plan during surgery add to the accuracy of guidewire placement (and therefore glenoid baseplate placement) in the non-IDI group. A similar finding has been previously reported by Iannotti et al,<sup>24</sup> who observed no significant differences between 3D planning and IDI, although both techniques improved accuracy significantly. However, they used 2D CT imaging for their conventional instrumentation group. The use of 3D preoperative planning has improved glenoid baseplate positioning and guidewire placement as surgeons do not rely on their ability to replicate one’s intended glenoid position through manual examination intraoperatively, which is often limited due to inconsistent anatomical landmarks.<sup>10,44</sup> To our knowledge to date, this is the first RCT using 3D preoperative planning in both experiment groups. In Australia, the National Joint Replacement Registry records whether IDI was used intraoperatively for shoulder arthroplasty.<sup>1</sup> However, there is no delineation as to whether 3D preoperative planning was used in isolation or in conjunction with IDI guides. This will make long-term survivorship data from the registry difficult to interpret—are we viewing the effect of 3D preoperative planning, or the effect of IDI on survivorship?

A limitation in our study is that we did not include a separate third arm with conventional instrumentation and without 3D preoperative plan. We did not include this arm because 3D preoperative planning was the standard of care for the operative surgeon and is known to improve accuracy of baseplate placement.<sup>23</sup> Additionally, we had difficulties obtaining full data sets for face-to-face outcome measures

(eg. CMS and follow-up X-rays) during the COVID-19 pandemic. Further limitations of this study are that we did not control for rotation of the baseplate or reaming depth, which are both important factors in determining correct glenoid placement.<sup>44</sup> Furthermore, this study does not assess the impact of baseplate positioning on long-term survivorship, with only 2-year follow-up. Finally, we did not include patients who required glenoid bone grafting; we felt that this would introduce heterogeneity into our cohort and subsequently introduce the potential for bias into our results.

Our results have yet to demonstrate a clinically or radiographically significant difference. This could be due to the relatively short follow-up period of 2 years, as it is known that issues with the glenoid baseplate (such as scapular notching and loosening) tend to become apparent with longer follow-up.<sup>33</sup> The rate of scapular notching on the postoperative radiographs (8% in the IDI group and 14% in the non-IDI group) are consistent with rates in the literature, ranging from 10% to 96%.<sup>25</sup>

Dislocation is a known complication of rTSA,<sup>3,4</sup> and is often due to an imbalance in soft tissue tensioning and component positioning.<sup>4</sup> For the patient who had anterior instability in our study, his issue resolved once his humeral component was repositioned, a longer and lateralized liner was used, and the interposed soft tissue scarring was removed. One could therefore postulate that therefore the glenoid positioning was not the problem in this scenario.

The other complication seen in our study, of subacromial bursitis following an influenza vaccination close to the rTSA is a known phenomenon,<sup>7</sup> and unrelated to glenoid baseplate placement.

## Conclusion

IDI is significantly more accurate in glenoid component placement in the superior/inferior plane compared to conventional instrumentations even when using 3D preoperative planning. Additionally, IDI glenoid insertion accuracy is superior to conventional in more complex morphologies where the native retroversion is > 10°. There were no significant clinical or radiographic differences seen between the two groups with 2-year follow-up; however, the benefits of glenoid placement accuracy may become apparent with longer follow-up. IDI is an accurate method for glenoid guidewire and component placement in rTSA.

## Acknowledgments

The authors would like to acknowledge several people for their contributions to this paper: Dr. Genevieve Graw, Dr. Ivana Jovanovic, and Dr. Sarah Brereton for their assistance in developing the research protocol, ethics submission and initial collation of data. We would like to acknowledge the team at Materialise, especially Ms Tine Proesmans and Dr. Wouter Houthoofd, for their assistance in coordinating the CT-based assessments.

## Disclaimers:

**Funding:** This paper is a result of investigator-initiated research, with ORIQL receiving a grant for funding from Lima Orthopaedics. The funding was used to pay for all non-standard-of-care imaging and postoperative imaging mapping and calculations from Materialise. Lima Orthopaedics was approached for a grant, as the supervising surgeon, Dr. Levi Morse, routinely uses their implants for reverse total shoulder arthroplasty. The funders had no role in the study design, data collection and analysis, decision to publish or preparation of the manuscript. The Orthopaedic Research Institute of Queensland receives funding for research from Stryker Corporation, Zimmer Biomet, Lima Orthopaedics and Arthrex. They had no input into the study design or interpretation of results.

**Conflicts of interest:** The authors, their immediate families, and any research foundation with which they are affiliated did not receive any financial payments or other benefits from any commercial entity related to the subject of this article.

## References

1. AOANJRR [Australian Orthopaedic Association National Joint Replacement Registry]. Hip, knee & shoulder arthroplasty: 2021 annual report. Available at: <https://aoanjrr.sahmri.com/annual-reports-2021>; 2021. Accessed February 25, 2022.
2. Berhouet J, Rol M, Spiry C, Slimane M, Chevalier C, Favard L. Shoulder patient-specific guide: first experience in 10 patients indicates room for improvement. *Orthopaedics Traumatol Surg Res* 2018;104:45-51. <https://doi.org/10.1016/j.otsr.2017.11.005>.
3. Bohsali KI, Bois AJWM. Complications of shoulder arthroplasty. *J Bone Joint Surg* 2017;99:256-69. <https://doi.org/10.2106/JBJS.16.00935>.
4. Bohsali KI, Wirth MA, Rockwood CA. Current concepts review: complications of total shoulder arthroplasty. *J Bone Joint Surg* 2006;88:2279-92. <https://doi.org/10.2106/JBJS.F.00125>.
5. Boileau P, Watkinson DJ, Hatzidakis AM, Balg F. Grammont reverse prosthesis: design, rationale, and biomechanics. *J Shoulder Elbow Surg* 2005;14:S147-61. <https://doi.org/10.1016/j.jse.2004.10.006>.
6. Cabarcas BC, Cvetanovich GL, Gowd AK, Liu JN, Manderle BJ, Verma NN. Accuracy of patient-specific instrumentation in shoulder arthroplasty: a systematic review and meta-analysis. *JSES Open Access* 2019;3:117-29. <https://doi.org/10.1016/j.jses.2019.07.002>.
7. Cagle PJ. Shoulder injury after vaccination: a systematic review. *Rev Bras Ortop* (Sao Paulo) 2021;56:299-306. <https://doi.org/10.1055/s-0040-1719086>.
8. Choi CH, Kim SG, Lee JJ, Kwack BH. Comparison of clinical and radiological results according to glenosphere position in reverse total shoulder arthroplasty: a short-term follow-up study. *CiOs Clin Orthop Surg* 2017;9:83-90. <https://doi.org/10.4055/cios.2017.9.1.83>.
9. Cohen J. *The effect size" statistical power analysis for the behavioral sciences*. 2nd Edition. New York: Routledge; 1988.
10. Dallalana R, McMahon R, East B, Geraghty L. Accuracy of patient-specific instrumentation in anatomic and reverse total shoulder arthroplasty. *Int J Shoulder Surg* 2016;10:59-66. <https://doi.org/10.4103/0973-6042.180717>.
11. Duethman NC, Aibinder WR, Nguyen NT, Sanchez-Sotelo J. The influence of glenoid component position on scapular notching: a detailed radiographic analysis at midterm follow-up. *JSES Int* 2020;4:144-50. <https://doi.org/10.1016/j.jses.2019.11.004>.
12. Elliott RSJ, Dallalana RJ. Patient-specific instrument-assisted structural glenoid bone grafting in reverse shoulder arthroplasty. *Tech Shoulder Elb Surg* 2017;18:145-50. <https://doi.org/10.1097/BTE.0000000000000123>.
13. Eraly K, Stoffelen D, vander Sloten J, Jonkers I, Debeer P. A patient-specific guide for optimizing custom-made glenoid implantation in cases of severe glenoid defects: an in vitro study. *J Shoulder Elbow Surg* 2016;25:837-45. <https://doi.org/10.1016/j.jse.2015.09.034>.
14. Farron A, Terrier A, Büchler P. Risks of loosening of a prosthetic glenoid implanted in retroversion. *J Shoulder Elbow Surg* 2006;15:521-6. <https://doi.org/10.1016/j.jse.2005.10.003>.
15. Favre P, Sussmann PS, Gerber C. The effect of component positioning on intrinsic stability of the reverse shoulder arthroplasty. *J Shoulder Elbow Surg* 2010;19:550-6. <https://doi.org/10.1016/j.jse.2009.11.044>.
16. Fevang BTS, Lie SA, Havelin LI, Skredderstuen A, Furnes O. Risk factors for revision after shoulder arthroplasty: 1,825 shoulder arthroplasties from the Norwegian Arthroplasty Register. *Acta Orthop* 2009;80:83-91. <https://doi.org/10.1080/17453670902805098>.
17. Gauci MO, Boileau P, Baba M, Chaoui J, Walch G. Patient-specific glenoid guides provide accuracy and reproducibility in total shoulder arthroplasty. *Bone Joint J* 2016;98-B:1080-5. <https://doi.org/10.1302/0301-620X.98B8.37257>.
18. Hendel MD, Bryan JA, Barsoum WK, Rodriguez EJ, Brems JJ, Evans PJ, et al. Comparison of patient-specific instruments with standard surgical instruments in determining glenoid component position: a randomized prospective clinical trial. *J Bone Joint Surg* 2012;94:2167-75. <https://doi.org/10.2106/JBJS.K.01209>.
19. Heylen S, van Haver A, Vuylsteke K, Declercq G, Verborgt O. Patient-specific instrument guidance of glenoid component implantation reduces inclination variability in total and reverse shoulder arthroplasty. *J Shoulder Elbow Surg* 2016;25:186-92. <https://doi.org/10.1016/j.jse.2015.07.024>.
20. Ho JC, Vani SJ, Iannotti JP. Glenoid component retroversion is associated with osteolysis. *J Bone Joint Surg* 2013;95:e82. <https://doi.org/10.2106/JBJS.L.00336>.
21. Iannotti J, Baker J, Rodriguez E, Brems J, Ricchetti E, Mesiha M, et al. Three-dimensional preoperative planning software and a novel information transfer technology improve glenoid component positioning. *J Bone Joint Surg Am* 2014;96:e71. <https://doi.org/10.2106/JBJS.L.01346>.
22. Iannotti JP, Greeson C, Downing D, Sabesan V, Bryan JA. Effect of glenoid deformity on glenoid component placement in primary shoulder arthroplasty. *J Shoulder Elbow Surg* 2012;21:48-55. <https://doi.org/10.1016/j.jse.2011.02.011>.



23. Iannotti JP, Walker K, Rodríguez E, Patterson TE, Jun BJ, Ricchetti ET. Accuracy of three-dimensional planning, implant templating, and patient-specific instrumentation in anatomic total shoulder arthroplasty. *J Bone Joint Surg* 2019;101:446-57. <https://doi.org/10.2106/JBJS.17.01614>.
24. Iannotti JP, Weiner S, Rodríguez E, Subhas N, Patterson TE, Jun BJ, et al. Three-dimensional imaging and templating improve glenoid implant positioning. *J Bone Joint Surg* 2015;97:651-8. <https://doi.org/10.2106/JBJS.N.00493>.
25. Jang Y, Lee J, Kin S. Effect of scapular notching on clinical outcomes after reverse total shoulder arthroplasty. *Bone Joint J* 2020;102:1438-45. <https://doi.org/10.1302/0301-620X.102B11.BJJ-2020-0449.R1>.
26. Jones IA, Togashi R, Heckmann N, Vangness CT. Minimal clinically important difference (MCID) for patient-reported shoulder outcomes. *J Shoulder Elbow Surg* 2020;29:1484-92. <https://doi.org/10.1016/j.jse.2019.12.033>.
27. Khan WS, Longo UG, Ahrens PM, Denaro V, Maffulli N. A systematic review of the reverse shoulder replacement in rotator cuff arthropathy, rotator cuff tears, and rheumatoid arthritis. *Sports Med Arthrosc Rev* 2011;19:366-79. <https://doi.org/10.1097/JSA.0b013e318224e44e>.
28. Kim MS, Rhee YG, Oh JH, Yoo JC, Noh KC, Shin SJ. Clinical and radiologic outcomes of small glenoid baseplate in reverse total shoulder arthroplasty: a prospective multicenter study. *CiOS Clin Orthop Surg* 2022;14:119-27. <https://doi.org/10.4055/cios20301>.
29. Kozak T, Bauer S, Walch G, Al-karawi S, Blakeney W. An update on reverse total shoulder arthroplasty: current indications, new designs, same old problems. *EFORT Open Rev* 2021;6:189-201. <https://doi.org/10.1302/2058-5241.6.200085>.
30. Lau SC, Keith PPA. Patient-specific instrumentation for total shoulder arthroplasty: not as accurate as it would seem. *J Shoulder Elbow Surg* 2018;27:90-5. <https://doi.org/10.1016/j.jse.2017.07.004>.
31. Levy JC, Everding NG, Frankle MA, Keppler LJ. Accuracy of patient-specific guided glenoid baseplate positioning for reverse shoulder arthroplasty. *J Shoulder Elbow Surg* 2014;23:1563-7. <https://doi.org/10.1016/j.jse.2014.01.051>.
32. Lewis GS, Stevens NM, Armstrong AD. Testing of a novel pin array guide for accurate three-dimensional glenoid component positioning. *J Shoulder Elbow Surg* 2015;24:1939-47. <https://doi.org/10.1016/j.jse.2015.06.022>.
33. Mollon B, Mahure SA, Roche CP, Zuckerman JD. Impact of scapular notching on clinical outcomes after reverse total shoulder arthroplasty: an analysis of 476 shoulders. *J Shoulder Elbow Surg* 2017;26:1253-61. <https://doi.org/10.1016/j.jse.2016.11.043>.
34. Nguyen D, Ferreira LM, Brownhill JR, King GJW, Drosdowech DS, Faber KJ, et al. Improved accuracy of computer assisted glenoid implantation in total shoulder arthroplasty: an in-vitro randomized controlled trial. *J Shoulder Elbow Surg* 2009;18:907-14. <https://doi.org/10.1016/j.jse.2009.02.022>.
35. Norris TR, Iannotti JP. Functional outcome after shoulder arthroplasty for primary osteoarthritis: a multicenter study. *J Shoulder Elbow Surg* 2002;11:130-5. <https://doi.org/10.1067/mse.2002.121146>.
36. Nyffeler RW, Werner CML, Gerber C. Biomechanical relevance of glenoid component positioning in the reverse Delta III total shoulder prosthesis. *J Shoulder Elbow Surg* 2005;14:524-8. <https://doi.org/10.1016/j.jse.2004.09.010>.
37. Rodríguez JA, Entezari V, Iannotti JP, Ricchetti ET. Pre-operative planning for reverse shoulder replacement: the surgical benefits and their clinical translation. *Ann Jt* 2019;4:4. <https://doi.org/10.21037/aoj.2018.12.09>.
38. Sirveaux F, Favard L, Oudet D, Huquet D, Walch G, Molé D, et al. Grammont inverted total shoulder arthroplasty in the treatment of glenohumeral osteoarthritis with massive rupture of the cuff results of a multicentre study of 80 shoulders. *J Bone Joint Surg [Br]* 2004;86:388-95. <https://doi.org/10.1302/0301-620X.86B3>.
39. Suero EM, Citak M, Lo D, Krych AJ, Craig Ev, Pearle AD. Use of a custom alignment guide to improve glenoid component position in total shoulder arthroplasty. *Knee Surg Sports Traumatol Arthrosc* 2013;21:2860-6. <https://doi.org/10.1007/s00167-012-2177-1>.
40. Throckmorton TW, Gulotta LV, Bonnarens FO, Wright SA, Hartzell JL, Rozzi WB, et al. Patient-specific targeting guides compared with traditional instrumentation for glenoid component placement in shoulder arthroplasty: a multi-surgeon study in 70 arthritic cadaver specimens. *J Shoulder Elbow Surg* 2015;24:965-71. <https://doi.org/10.1016/j.jse.2014.10.013>.
41. Throckmorton TW, Vogt W, Wasmaier J, Hurst JM, Frostick S, Sperling JW. Patient-specific targeting guides for glenoid component placement in shoulder arthroplasty: technique and initial clinical experience. *Tech Shoulder Elb Surg* 2014;15:103-8. <https://doi.org/10.1097/BTE.000000000000029>.
42. Trouilloud P, Gonzalez M, Martz P, Charles H, Handelberg F, Nyffeler RW, et al. Duocentric® reversed shoulder prosthesis and Personal Fit® templates: innovative strategies to optimize prosthesis positioning and prevent scapular notching. *Eur J Orthopaedic Surg Traumatol* 2014;24:483-95. <https://doi.org/10.1007/s00590-013-1213-2>.
43. Verborgt O, Hachem AI, Eid K, Vuylsteke K, Ferrand M, Hardy P. Accuracy of patient-specific guided implantation of the glenoid component in reversed shoulder arthroplasty. *Orthopaedics Traumatol Surg Res* 2018;104:767-72. <https://doi.org/10.1016/j.otsr.2018.01.010>.
44. Villatte G, Muller AS, Pereira B, Mulliez A, Reilly P, Emery R. Use of Patient-Specific Instrumentation (PSI) for glenoid component positioning in shoulder arthroplasty: a systematic review and meta-analysis. *PLoS One* 2018;13:e0201759. <https://doi.org/10.1371/journal.pone.0201759>.
45. Walch G, Mesiaha M, Boileau P, Edwards TB, Lévine C, Moineau G, et al. Three-dimensional assessment of the dimensions of the osteoarthritic glenoid. *Bone Joint J* 2013;95 B:1377-82. <https://doi.org/10.1302/0301-620X.95B10.32012>.
46. Walch G, Vezeridis PS, Boileau P, Deransart P, Chaoui J. Three-dimensional planning and use of patient-specific guides improve glenoid component position: an in vitro study. *J Shoulder Elbow Surg* 2015;24:302-9. <https://doi.org/10.1016/j.jse.2014.05.029>.
47. Wall B, Nové-Josserand L, O'Connor DP, Edwards TB, Walch G. Reverse total shoulder arthroplasty: a review of results according to etiology. *J Bone Joint Surg - Ser A* 2007;89:1476-85. <https://doi.org/10.2106/JBJS.F.00666>.
48. Werner BS, Hudek R, Burkhart KJ, Gohlke F. The influence of three-dimensional planning on decision-making in total shoulder arthroplasty. *J Shoulder Elbow Surg* 2017;26:1477-83. <https://doi.org/10.1016/j.jse.2017.01.006>.