



Case report

Traumatic obturator dislocation of the hip joint: About 2 cases and review of the literature

Z.F. Zengui^{*}, O. El Adaoui, M. Fargouch, O. Adnane, Y. El Andaloussi, M. Fadili

Department of Trauma Surgery and Orthopaedics, Ibn Rochd University Hospital Center, Casablanca, Morocco
 Faculty of Medicine and Pharmacy of Casablanca, Hassan II University, Morocco

ARTICLE INFO

Keywords:

Hip dislocation
 Obturator dislocation
 Functional treatment

ABSTRACT

Introduction: Traumatic dislocation of the hip is a serious lesion, and its obturator variety is rarely reported. It always reflects a high-energy trauma and represents a therapeutic emergency that requires a reduction in less than 6 h due to the risk of aseptic necrosis of the femoral head in the long term.

Case report: We reported 2 cases of hip obturator dislocation in patients aged 21 and 45 years respectively, which occurred following a road accident, received for pain and functional impairment of the hip, and in a typical attitude with hip flexion, abduction, rotation and knee flexion with no downstream limb vascular-nervous injury. The emergency reduction in <6 h, in two cases, followed by functional treatment by offloading for 8 weeks and support of the limb with the resumption of walking had been authorized at 3 months with a return to sport at 16 weeks; made it possible to obtain satisfactory results at 18 months of follow-up, with an absence of a functional gene, stiffness and without signs of necrosis of the femoral head.

Discussion and conclusion: Traumatic obturator dislocation of the hip constitutes serious lesions and requires early and appropriate management, reduced to closed focus, treated functionally give excellent results in the medium term. The patient must be carefully monitored over the long term and be warned of the risks he runs.

1. Introduction

The hip joint is deep, unique in having a high degree of stability and mobility. Hip dislocation is frequently associated with other lesions involving the patient's vital prognosis. The traumatic obturator dislocation of the hip is a less common injury and often occurs in the context of polytrauma secondary to high kinetic energy accidents [1–4]. It's a therapeutic emergency that requires a reduction in less than 6 h, as the long-term prognosis depends on it. The fear of the orthopaedic surgeon remains its long-term evolution towards aseptic necrosis of the head and coxarthrosis [5–8]. We present two cases report of the anteroinferior hip joint dislocation reduced to closed focus and treated functionally. This study aimed to present the management of the obturator hip dislocation and evaluate the results of these injuries in the medium term. This manuscript has been reported in line with SCARE's 2020 Criteria [9].

2. Patients and methods

2.1. Observation 1

Forty-five-year-old athlete, amateur football, who was a victim of a road accident, a motorcycle had hit a pole because of an imbalance, with the direct impact of the knee on abduction and flexion during the collision. This trauma caused the pain and functional impotence of the left lower limb without an initial loss of consciousness. He was admitted 1 h later after the trauma at the Trauma Surgical Emergency in Ibn Rochd University Hospital Center of Casablanca. The examination at the arrival noted a conscious patient, stable on the hemodynamic and respiratory plane. We noted a vicious attitude of the lower limb, hip flexion, abduction and external rotation and with a bent knee, with no downstream limb vascular-nerve injury.

Conventional X-ray of the pelvis revealed an anterior dislocation of the right hip in its obturator variety (Fig. 1). A computed tomography scan of the pelvis showed vacuity of the acetabulum with the head of the femur facing the obturator foramen, no bone lesion was detectable before reduction (Fig. 2).

^{*} Corresponding author.

E-mail address: zifazengui@gmail.com (Z.F. Zengui).

<https://doi.org/10.1016/j.ijscr.2022.106983>

Received 4 February 2022; Received in revised form 22 February 2022; Accepted 24 March 2022

Available online 30 March 2022

2210-2612/© 2022 Published by Elsevier Ltd on behalf of IJS Publishing Group Ltd. This is an open access article under the CC BY-NC-ND license (<http://creativecommons.org/licenses/by-nc-nd/4.0/>).

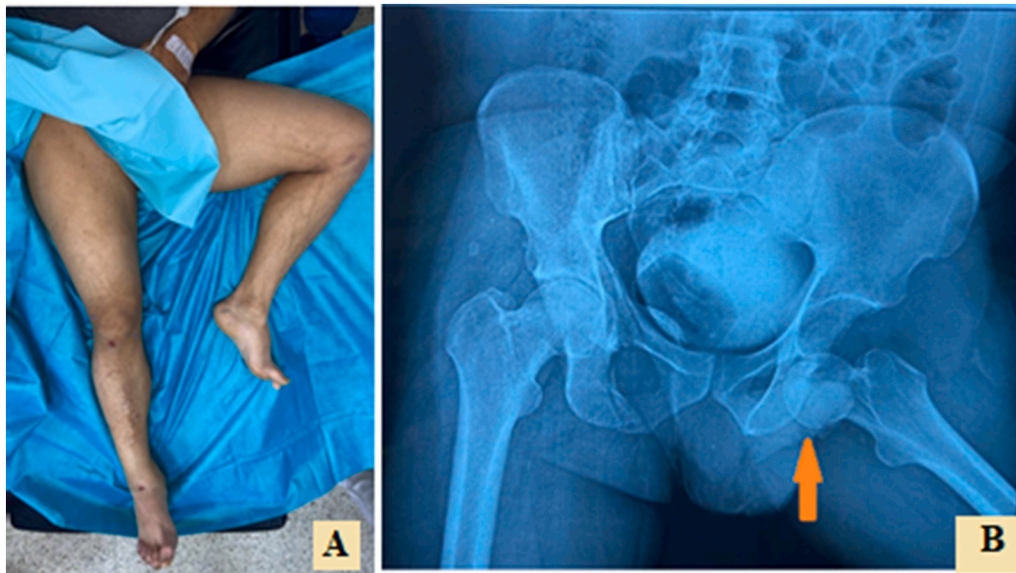


Fig. 1. Case 1: A. Vicious attitude in flexion, abduction and external rotation of the left hip characteristic of obturator anterior dislocations of the hip. B, An X-ray of the pelvis showing the dislocation in its obturator variety.

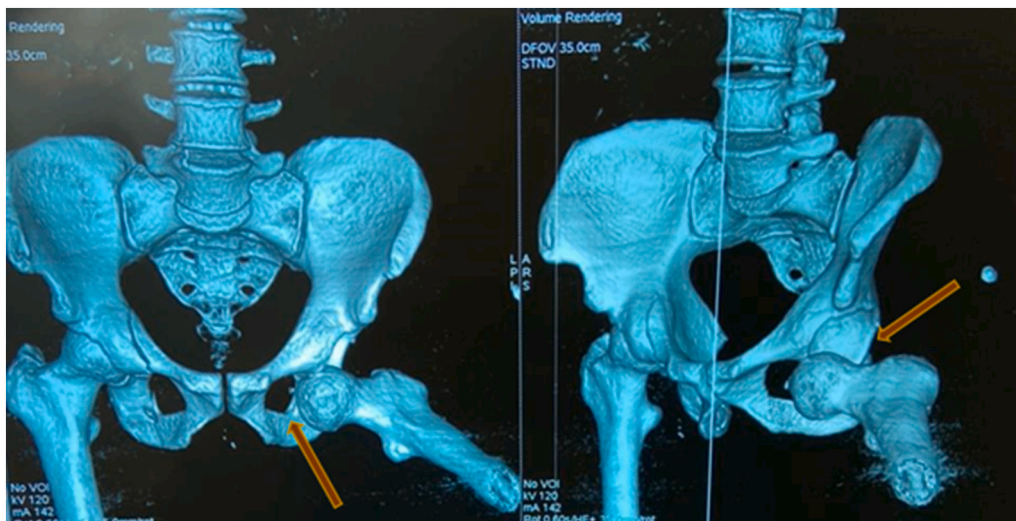


Fig. 2. Case 1: CT scan of the pelvis with 3D reconstruction showing vacuity of the acetabulum with the femoral head next to the obturator foramen.

We performed a reduction 2 h after the trauma, under general anaesthesia by external manoeuvres consisting of traction in the axis of the limb in the first instance then secondary flexion of the hip associated with adduction and internal rotation. The sensation of an audible jerk confirmed the reduction of the dislocation. The hip was stable in flexion-extension, internal and external rotation, abduction and adduction, the length of the limbs and the vascular nervous examination post-reduction were normal.

A control X-ray of the pelvis presented the reintegration of the femoral head. An additional CT scan ruled out associated injuries and the absence of intra-articular fragments (Fig. 3). After reduction, the treatment was functional and included an 8-week discharge period combined with antithrombotic prophylaxis with oral anticoagulants. Limb weight-bearing with the re-establishment of walking was authorized at 9 weeks. And the return of sports activities was allowed at 16 weeks. At an 18-month follow-up, the patient showed no hip pain or stiffness, with control X-rays that were unremarkable.

2.2. Observation 2

Twenty-one-year-old patient, who was the victim of a public road accident. The patient on board a motorcycle had collided with a car, causing blunt trauma to the right hip with pain and functional impotence of the limb with initial loss of consciousness, without vomiting. He was admitted 2 h later to the Trauma Surgery and Orthopaedics in Ibn Rochd University Hospital Center of Casablanca.

The examination on arrival noted a conscious patient was stable hemodynamically and respiratory. The left limb was in a vicious attitude in flexion, abduction and external rotation and flexed knees and ecchymosis on the anterior surface of the right knee (Fig. 4). We noted no downstream vascular-nervous deficits.

A frontal X-ray of the pelvis showed an antero-inferior dislocation of the right hip, obturator, without bone lesions of the femoral head and acetabulum (Fig. 5); computed tomography confirmed the dislocation and noted the osteochondral lesions at the level of the head at the posterosuperior part of the femoral head.

The brain scanner noted lesions of temporal contusions without

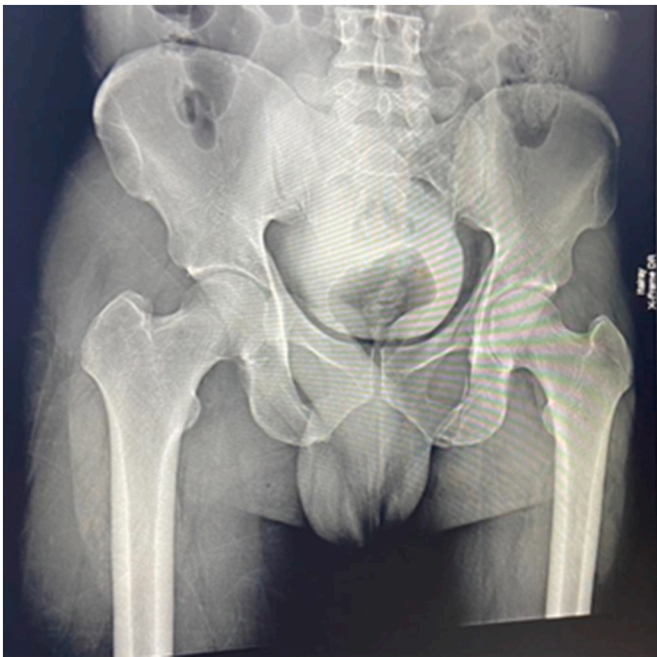


Fig. 3. Case 1: X-ray of the control pelvis showing the head of the femur in place of the acetabulum, without bone lesion.

other associated signs.

The emergency reduction was performed 3 h after the trauma, under general anaesthesia by traction in the axis of the limb combined with important flexion and abduction. The reduction was confirmed by an audible jerk and the limbs' isolating length; the pelvis's control X-ray confirmed the dislocation's reduction and the existence of a notch in the posterosuperior part of the femoral head. A CT scan of the pelvis noted the presence of osteochondral lesions at the level of the femoral head without intra-articular fragments (Fig. 6).

The treatment was functional after reduction consisting specifically of eight weeks discharge associated with antithrombotic prophylaxis.

Weight-bearing of the limb with the resumption of walking had been authorized for three months. And the re-establishment of sports activities had authorized 16 weeks.

At the 18-month follow-up, the patient complained of intermittent pain in the hip, without stiffness, with control radiographs which were unremarkable.

3. Discussion

Traumatic hip dislocation is the permanent displacement of the femoral head outside the acetabular cavity. It can be pure or associated with a fracture of the femoral head. It's a serious injury, the consequence of a violent trauma often with associated lesions that must seek because often involves the vital prognosis of the patient. It's a therapeutic emergency that often requires a reduction of the dislocation, by external manoeuvres, under anaesthesia in good conditions. Sometimes, the presence of associated lesions, specifically, fracture of the femoral head or the femoral neck, or due to fragmentary incarceration, makes the dislocation irreducible and requires a surgical approach to reduce and synthesise [2,10–15]. It's a serious lesion because it involves the prognosis of the femoral head in the medium and long term with the main complications dominated by the risk of osteoarthritis and post-traumatic necrosis. [2,3,8]. Anterior dislocation is much rarer, they represent a quarter of hip dislocations. It can be obturator in 15%, or pubic in 10%. Hip position and the point of impact during the trauma are decisive and condition the direction of the bone pieces. The energy required to dislocate a hip explains the frequency of associated injuries such as

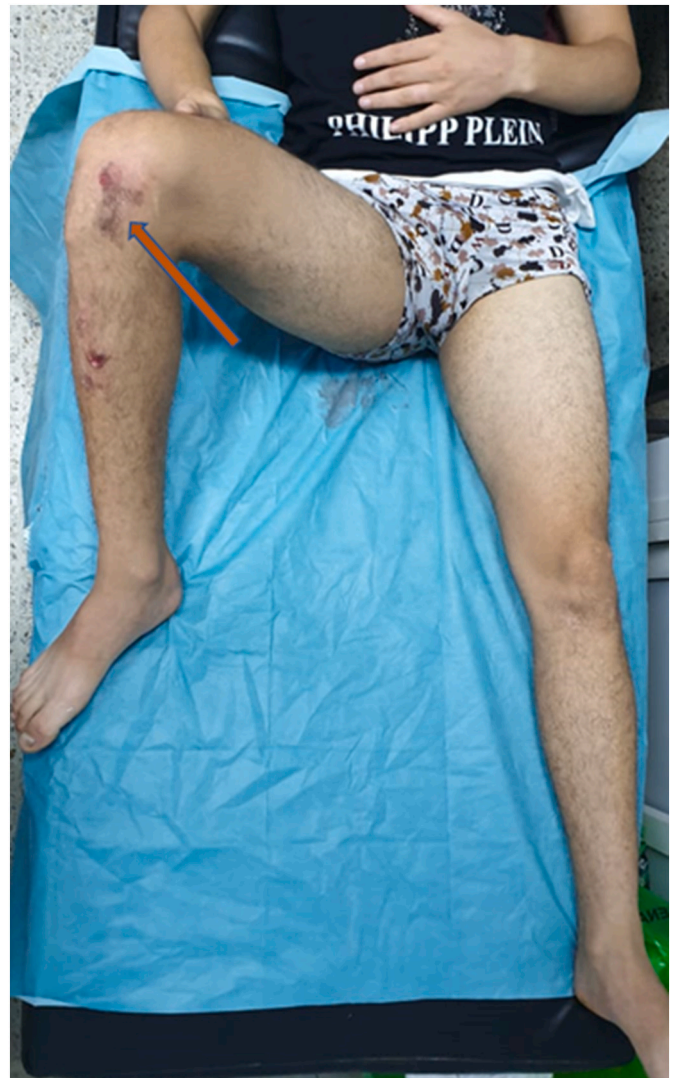

Fig. 4. Case 2: Vicious attitude of the right lower limb in hip flexion, abduction and external rotation with knee flexion and ecchymosis on the front of the knee and leg.

fractures of the acetabulum, neck or femoral head. It occurs in high kinetic trauma with a direct impact on the medial side of the knee in flexion. Generally, on a hip in flexion-abduction position and external rotation in maximum abduction. The greater trochanter collides with the ilium causing the extraction of the femoral head from the acetabulum.

Computed tomography has made it possible to make a precise assessment of the infraradiological osteochondral lesions and to plan a possible surgical approach, but it shouldn't delay treatment.

All the authors in the literature remain consensual for an emergency reduction of hip dislocations [8]. However, the ideal time frame for the reduction to be achieved remains open to discussion. Many authors defend an ideal delay of fewer than 6 h. Hougaard and Thomsen, in a retrospective study of 127 hip dislocations concluded that the risk of avascular necrosis occurred most often in hips had undergone reduction after a delay of >6 h. He had observed 4.8% necrosis before 6 h versus 58.8% after this time [8]. Thus, it seems logical to reduce dislocations before 6 h unless the patient's condition or the presence of other lesions involving immediate vital prognosis prevents immediate treatment [5,16].

The reduction must always be done under general anaesthesia and in a relaxed patient. The manoeuvres must be gentle and, if possible, non-

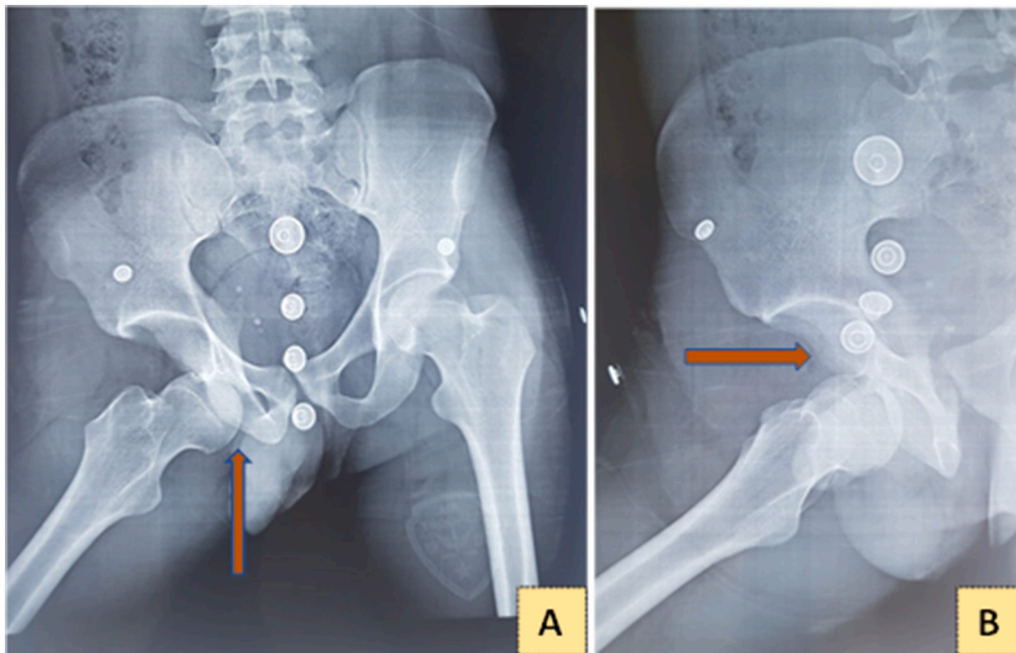


Fig. 5. Case 2: A and B. X-rays of the pelvis AP and 3/4 alar of the hip showing obturator dislocation with vacuity of the acetabulum.

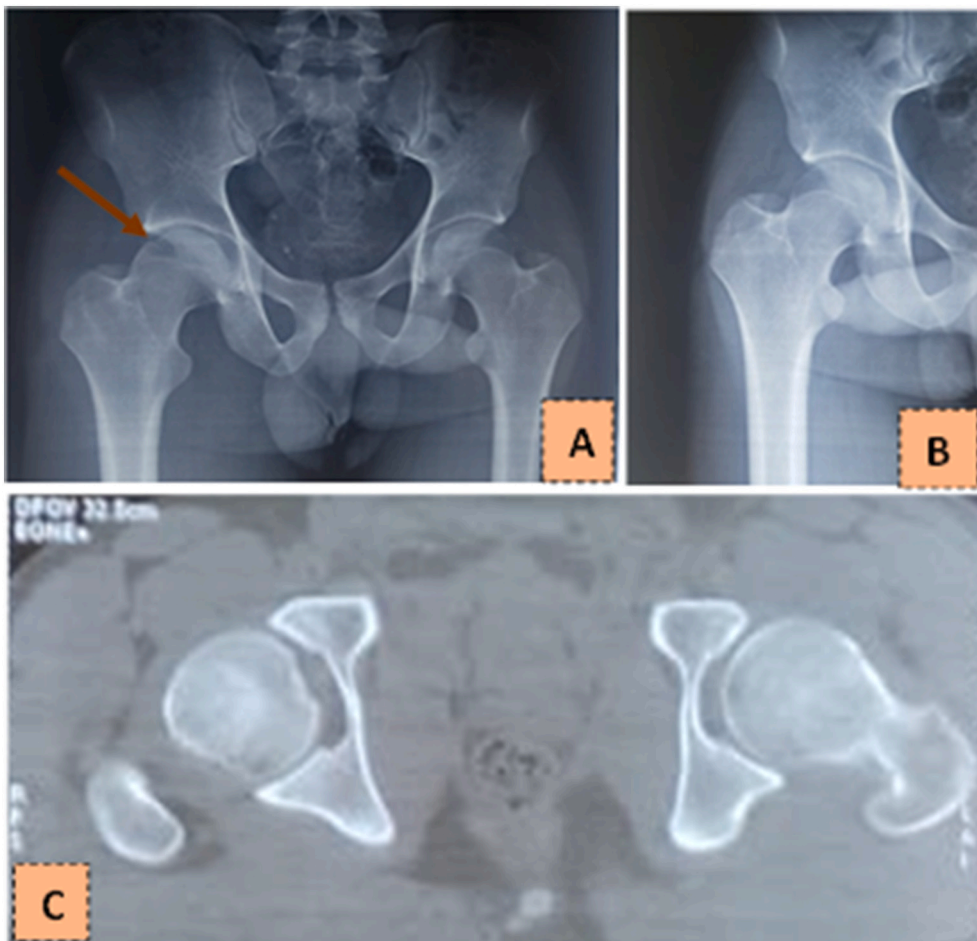


Fig. 6. Case 2: A and B. Control AP radiograph of the pelvis showing the reduction and the presence of a notch in the posterosuperior part of the femoral head. C. CT scan on transverse sections: good head-acetabular congruence and absence of intra-articular fragment.

repetitive, so as not to aggravate or cause other injuries. It consists, as in both, of gentle traction in the axis, flexion of the hip and internal rotation. The reintegration of the femoral head is confirmed by an audible jerk and an identical length of the limbs.

Performing a control AP pelvic X-ray makes it possible to ensure perfect joint congruence and to look for an associated bone injury that would have gone unnoticed on the dislocated X-rays. Delayed emergency computed tomography of the hip is systematically done. It allows a careful lesion assessment, specifically very frequent chondral injuries before or after reduction such as fractures of the acetabulum, of the head, or intraarticular fragments that have gone unnoticed [11,12,15].

Post-reduction management remains non-consensual and depends on whether the dislocation is pure or associated with bone lesions. Some authors recommend, lacking associated lesions that would require specific additional treatment, to set up transosseous traction and gentle active rehabilitation under cover of traction. The duration of traction is of the order of 3 to 6 weeks depending on the teams, this duration varies according to the teams [2,3]. This aims to pass the acute painful phase and reduce intra-articular pressures to reduce the risk of necrosis head femoral. This empirical attitude stays debatable. We had opted in our cases for functional treatment with early rehabilitation and unloading of the limb without prior traction. Indeed, some studies have determined that no increase of the necroses number in the event of immediate gentle mobilisation without traction, but the decline in these remote analyses remains to be assessed [5,17,18].

The classically recommended period of full discharge is 2 to 3 months and full weight bearing is prohibited for 3 months. However, this attitude is dictated only by caution, because some studies have concluded that no danger in immediate partial support [16].

4. Conclusion

Traumatic hip dislocation is a rare and serious entity, which nevertheless gives good results when reduction by external manoeuvre is achieved within <6 h, treatment by simple discharge followed by early range of motion. The patient must therefore be carefully monitored in the long term and warned of the risks involved.

Sources of funding

None.

Ethical approval

N/A.

Consent

Written informed consent was obtained from the patient for publication of this case report and accompanying images. A copy of the written consent is available for review by the Editor-in-Chief of this journal on request.

Author contribution

Francis Zifa ZENGUI: designed the study, wrote the protocol and the first draft of the manuscript.

Oussama El Adaouia: managed the analyses, and the correction of the manuscript.

Mohamed Fargouch: managed the analyses, and the correction of the manuscript.

Adnane Oussama: managed the analyses, and the correction of the

manuscript.

Yassir El Andaloussi: managed the analyses, and the correction of the manuscript.

Mustapha Fadili: managed the analyses, and the correction of the manuscript.

All authors read and approved the final manuscript.

Research registration number

NA.

Guarantor

ZENGUI Francis Zifa.

Provenance and peer review

Not commissioned, externally peer-reviewed.

Declaration of competing interest

None.

References

- [1] R. Hani, M. Kharmaz, M.S. Berrada, Traumatic obturator dislocation of the hip joint: a case report and review of the literature, *Pan Afr. Med* 21 (2015) 55.
- [2] H.C. Epstein, D.A. Wiss, Traumatic anterior dislocation of the hip, *Orthopedics* 8 (1) (janv 1985) 132–134, 130.
- [3] K. Hougaard, P.B. Thomsen, Traumatic posterior dislocation of the hip—prognostic factors influencing the incidence of avascular necrosis of the femoral head, *Arch. Orthop. Trauma Surg. Arch. Orthopädische Unf-Chir.* 106 (1) (1986) 32–35.
- [4] A. Gibbs, Bilateral obturator dislocation of the hip joint, *Injury* 12 (3) (1 nov 1980) 250–251.
- [5] R.D. Wojahn, C.P. Kleweno, J. Agel, M.F. Githens, Anterior hip dislocation: characterization of a rare injury and predictors of functional outcome, *Injury* 52 (8) (2021) 2327–2332, aóft.
- [6] A.Ç. Tekin, H. Çabuk, C.D. Büyükkurt, S.S. Dedeoğlu, Y. İmren, H. Gürbüz, Inferior hip dislocation after falling from height: a case report, *Int. J. Surg. Case Rep.* 22 (1 janv 2016) 62–65.
- [7] S. Patel, R.B. Thimmegowda, R. John, T.R. Sunil Kumar, R.H.H. Arjun, Total hip arthroplasty in neglected, obturator type, hip dislocation in a young adult – an unusual case and literature review, *J. Arthrosc. Jt. Surg.* 4 (1) (1 janv 2017) 50–53.
- [8] K. Hougaard, P.B. Thomsen, Coxarthrosis following traumatic posterior dislocation of the hip, *J. Bone Joint Surg. Am.* 69 (5) (juin 1987) 679–683.
- [9] R.A. Agha, T. Franchi, C. Sohrabi, G. Mathew, for the SCARE Group, The SCARE 2020 guideline: updating consensus Surgical Case Report (SCARE) guidelines, *Int. J. Surg.* 84 (2020) 226–230.
- [10] M. Allagui, B. Touati, I. Aloui, M.F. Hamdi, M. Koubaa, A. Abid, Obturator dislocation of the hip with ipsilateral femoral neck fracture: a case report, *J. Clin. Orthop. Trauma* 4 (3) (1 sept 2013) 143–146.
- [11] L. Ceri, L. Zanna, R. Buzzi, P. De Biase, Obturator dislocation of the hip associated with ipsilateral quadrilateral plate fracture: a rare case report, *Trauma Case Rep.* 32 (2021), 100451 avr.
- [12] I. Daskalakis, G.M. Kontakis, T.H. Tosounidis, Anterior hip dislocation with simultaneous anterior column and anterior wall acetabular fracture: a case report, *Trauma Case Rep.* 31 (1 févr 2021), 100391.
- [13] S.T. Canale, A.H. Manugian, Irreducible traumatic dislocations of the hip, *J. Bone Joint Surg. Am.* 61 (1) (1979) 7–14, janv.
- [14] Q. Tao, F. Zhong, C. Wang, H. Wang, C. Chen, F. Wu, et al., Traumatic obturator dislocation of the hip joint associated with greater trochanter fracture: a case report, *Orthop. Surg.* 13 (2) (2021) 673–677, avr.
- [15] R.J. Izquierdo, D. Harris, Obturator hip dislocation with subcapital fracture of the femoral neck, *Injury* 25 (2) (1994) 108–110, 1 mars.
- [16] V. Vécsei, E. Schwendenwein, G. Berger, Hip dislocation without bone injuries, *Orthopäde* 26 (4) (1997) 317–326, avr.
- [17] H.-G. Park, Y.-E. Shin, S.-H. Kim, The cause of primary reduction failure in hip dislocation with or without hip fracture, *J. Korean Fract. Soc.* 30 (1) (20 janv 2017) 9–15.
- [18] R. Kochbati, M. Jlailia, A rare post-traumatic dislocation of the hip: anterior obturator type dislocation, *Pan Afr. Med. J.* 24 (2016) 122.