

# Changes in regional cerebral blood flow with Chaihu-Shugan-San in the treatment of major depression

Juan Qiu<sup>1,2</sup>, Sui-Yu Hu<sup>2</sup>, Guang-Qing Shi<sup>1</sup>, Su-e Wang<sup>2</sup>

<sup>1</sup>Department of Nuclear Medicine, Third Xiangya Hospital, Central South University, NO.138 Tongzipo Road, Changsha 410013, <sup>2</sup>Department of Integrative Medicine, Institute of Integrated Traditional Chinese and Western Medicine, Xiangya Hospital, Central South University, No. 87 Xiangya Road, Changsha 410008, Hunan, China

Submitted: 13-09-2013

Revised: 28-10-2013

Published: 26-09-2014

## ABSTRACT

**Background:** Chaihu-Shugan-San (CHSGS) is a well-known Chinese traditional prescription used for depression. **Objective:** To observe the regional cerebral blood flow (rCBF) changes in patients with major depression and to investigate rCBF and clinical response to CHSGS. **Materials and Methods:** A total of 33 unmedicated patients with major depression and 12 healthy comparison subjects underwent single photon emission computed tomography (SPECT) imaging. A total of 33 unmedicated patients with major depression all met the diagnostic criteria of stagnation of liver qi of traditional Chinese medicine and were divided into two groups: CHSGS group ( $n = 20$ ) and fluoxetine group ( $n = 13$ ). SPECT imaging was restudied in posttreatment. **Results:** SPECT detected abnormalities in all (100.0%) patients both in CHSGS group and fluoxetine group. All healthy subjects were normal results. The depressed patients showed rCBF decreased in the multiple regions. The semiquantitative values of bilateral frontal and left temporal lobes both in CHSGS group and fluoxetine group were lower than that in healthy group ( $P < 0.05$ ). Reexamined SPECT after 8 weeks treatment with CHSGS showed the consistency between the increase in perfusion defects and the improvement of clinical cerebral symptoms. The semiquantitative values increased in posttreatment, when compared with pretreatment ( $P < 0.05$ ). **Conclusion:** SPECT represents a sensitive tool to detect the major depressive disorder, which show the rCBF decreased. rCBF perfusion defects can be reversed and clinical symptoms can be improved by CHSGS treatment. CHSGS treatment is effective, well-tolerated, and safe for depression. By semiquantitative analysis, SPECT can objectively detect rCBF changes that is useful for guiding treatment.

**Key words:** Brain, Chaihu-Shugan-San, major Depression, single photon emission computed tomography

## Access this article online

### Website:

www.phcog.com

### DOI:

10.4103/0973-1296.141775

### Quick Response Code:



## INTRODUCTION

Depression is a common psychological disorder, which seriously impaired patient's daily life. Currently, medications play the predominant role in the treatment rather than conventional psychotherapy. Selective serotonin reuptake inhibitor (SSRI) is the most common medication prescribed. But some patients discontinued their medication due to severe side-effects that can be either subjective or objective. Some clinicians reported fatigue, motor agitation, decreased appetite and headache, self-harm, and emotional side effects.<sup>[1,2]</sup> These findings

suggest the need for additional, minimal side-effect treatment alternatives depression. Traditional Chinese medicines (TCMs) have attracted the world's attention due to their antiquity, unique theories, and historical clinical practice. Chaihu-Shugan-San (CHSGS) is one of the most widely used TCM clinical treatments for depression in China. Previous studies have reported abnormal findings in functional neuroimaging in patients with depression.<sup>[3,4]</sup> SPECT is a valuable tool in the investigation of depression and has been widely used in depression research.<sup>[5,6]</sup> Some studies reported the regional cerebral blood flow (rCBF) changes before and after treatment of the illness.<sup>[7]</sup> Vangu *et al.*, and Bonne *et al.*,<sup>[7,8]</sup> reported that patients with major depression showed the increased brain tracer uptake after successful treatment, while the patients who did not respond to the treatment showed unchanged rCBF. These studies indicated that successful treatment would reverse the rCBF changes and SPECT could monitor therapy in patients with depression.<sup>[8]</sup>

### Address for correspondence:

Prof. Sui-Yu Hu. Department of Integrative Medicine, Institute of Integrated Traditional Chinese and Western Medicine, Xiangya Hospital, Central South University, No. 87, Xiangya Road Changsha - 410008, Hunan, China.  
E-mail: tangzl@163.com

To our knowledge, few of the researches about the application of SPECT to investigate the rCBF changes with TCM in the treatment of depression were reported. In this study, one might expect the use of SPECT brain imaging to monitor therapy in major depressive disorder with CHSGS. The aim of this study was to observe the rCBF changes in major depressive disorders and to evaluate the rCBF and clinical response to CHSGS.

## MATERIALS AND METHODS

### Subjects and diagnostic criteria

A total of 33 patients with major depression and 20 healthy control subjects were enrolled in the study. A total of 33 depressed patients were divided into two groups: 20 patients were treated with CHSGS (CHSGS group,  $n = 20$ ) and 13 patients were treated with fluoxetine (fluoxetine group,  $n = 13$ ). All patients with major depression were obtained from the Institute of Integrated Traditional Chinese and Western Medicine at the Xiangya Hospital of Central South University. They all fulfilled the Diagnostic Statistical Manual criteria (DSM-IV)<sup>[9]</sup> for current unipolar major depression and all had scores of at least 22 (with the mean of 34.8; standard deviation = 9.3) on the 17 items of the Hamilton Depression Rating Scale (HAMD).<sup>[10]</sup> All patients met the stagnation of Liver-Qi with TCM syndrome differentiation.<sup>[11,12]</sup> A total of 20 nondepressed, healthy volunteers subjects (healthy group,  $n = 20$ ) were obtained from the Department of Health Management Center at the Xiangya Hospital. Demographic and clinical data for all subjects are presented in Table 1. All participants matched for sex and mean age at the moment of instrumental evaluation. Subject written informed consent was obtained and the design of the work has been approved by local ethical committee. All subjects underwent physical examination by a doctor of TCM and a psychiatrist. None of the patients were taking antidepressant medications and had a history of neurological, uremia, infections, drugs, head injury, or any psychiatric disease other than depression. Exclusion

criteria included mental retardation, organic brain syndrome, pervasive developmental disorder, history of hypomania or mania, psychosis, eating disorder, substance abuse, and treatment with central nervous system-acting agent.

### SPECT rCBF imaging

<sup>99m</sup>Tc-ethyl cysteinate dimer (<sup>99m</sup>Tc-ECD) (Jiangsu Atom Medicine Research Institute Jiangyuan Pharmaceutical Factory, China) was prepared according to the manufacturer's recommendations. After their informed consent was obtained, every subject was put at rest in a quiet room with dim lights, remaining awake with closed eyes during the 15 min period. SPECT imaging was performed on 10 min after the intravenous injection of 925 MBq (25 mCi) of <sup>99m</sup>Tc-ECD. Brain SPECT was carried out with GE Starcam 3200XR/T, equipped with a low-energy high-resolution collimator. Data were acquired in a 128 × 128 matrix over a 360° rotation, energy peak 140 Kev, window width 20% and zoom 1.6. 60 views were collected, acquisition time 35 sec/view. SPECT construction was processed using attenuation correction, with Butterworth filter (Power 5.0; cut-off frequency 0.30). Subsequently, reconstruction was executed with ramp. Transaxial slices 2 pixels thickness (pixel size = 6.2 mm) were reconstructed. To identify areas of perfusion, the SPECT images from each subject was visually interpreted twice, in random order, by three independent, experienced observers who were blinded to the clinical information about the patients. Normal <sup>99m</sup>Tc-ECD brain imaging findings consisted of homogeneous rCBF in the gray matter of the cerebral cortex and basal ganglia/thalamus, without focal hypoperfusion or visible asymmetry. Abnormal findings were defined as heterogeneous rCBF with focal hypoperfusion/hyperperfusion or visible asymmetry at least two consecutive slices noted twice by at least two observers.

### SPECT semiquantitative analysis

Regions of interest (ROI) was delineated by selecting three connective cross-sections. Shape and size (4 × 4 pixel) of ROI were the same in the CHSGS groups, the fluoxetine group and the healthy group. ROIs were assigned by consensus of two independent investigators to three adjacent transaxial slices of the following regions: frontal, temporal, parietal, occipital lobe, basal ganglia, thalamus, white matter, caudate nucleus, and cerebellar. ROIs analyses were performed by specific values of semiquantitative. Cerebellar of all subjects was normal results. So, cerebellar was chosen as a reference, which generated semiquantitative specific value (semiquantitative value = ROI uptake/cerebellum uptake) and results were compared among the CHSGS group, the fluoxetine group and healthy group. The semiquantitative values of the different groups were compared between in pretreatment and posttreatment.

**Table 1: Demographic and clinical characteristics of study sample**

Demographic variables and clinical characteristic	CHSGS (n=20)	Fluoxetine (n=13)	Healthy (n=20)
Age (years)	30.6±8.9	30.1±9.0	28.5±8.1
Gender (male/female)	8/12	4/9	9/11
Gender (% , men)	40	31	45
Baseline score of HAMD	34.8±9.3	31.7±12.3	4.2±3.0

All values are mean±SD. SD: Standard deviation, CHSGS: CHSGS group, Fluoxetine: Fluoxetine group, HAMD: Hamilton depression rating scale, Healthy: Healthy group

### Administration of CHSGS and fluoxetine

After the baseline SPECT, antidepressant treatment (either CHSGS or fluoxetine) was started. Oral CHSGS taken by 20 patients of CHSGS group. According to The People's Republic of China Pharmacopoeia 1<sup>st</sup> volume conventional dosage, the CHSGS prescription and dosage are as follows: Radix bupleuri 9 g, Aurantii nobilis pericarpium 9 g, Szechwan Lovage rhizome 9 g, Nutgrass Galingale rhizome 9 g, Fructus aurantii 9 g, Paeonia 15 g, and Glycyrrhiza uralensis 5 g. All herbal medicines were purchased from Hunan Herbal Materials Company (Changsha, China) and authenticated by Professor P. Lei, Xiangya Hospital, Central South University. All herbal medicines were put into the casserole with water immerse 60 min and decocted 60 min, subsequently, taking TCM juice 300 mL twice daily. These patients were administered at the set of CHSGS twice daily for 8 weeks.

The other 13 patients with major depression received fluoxetine treatment and adjusted to standard therapeutic dose 20-40 mg QD., for 8 weeks. Fluoxetine hydrochloride was purchased from Eli Lilly and Company (Suzhou, China). The healthy group did not received any drug treatment in the period of 8 weeks.

### Follow-up

A follow-up SPECT was performed on all subjects after 8 weeks treatment and depressive symptoms were related on the HAMD.

### Statistical analysis

Group difference in demographic variables involving data (age, gender%, and HAMD) were computed using one-way analysis of variance (ANOVA) for variables. Between-group comparison involving SPECT results was assessed using Fisher's exact test. Rank sum test and ANOVA were used in semiquantitative values comparisons among the groups. T tests were carried out to assess the HAMD scores and semiquantitative values between pre- and post-CHSGS depressed patients. The same comparisons were made between pre- and postfluoxetine and between pre- (the first) and post- (the second) tscan of healthy. Pre-CHSGS treatment, the relationship between HAMD scores and ages using Spearman rank correlation coefficients in depression patients. The Statistical Package treatment for the Social Sciences (SPSS; Information Technology Services) was used to analyze the data. In all tests,  $P < 0.05$  were considered as statistically significant.

## RESULTS

### Clinical assessment

The subjects consisted of 20 major depressed patients treated with CHSGS, 13 major depressed patients treated with fluoxetine, and 20 healthy comparison

subjects. Demographic and clinical characteristics for all subgroups are presented in Table 1. There were no statistically significant difference in age and sex among these groups ( $P = 0.521$ ;  $P = 0.769$ , respectively). The baseline HAMD scores among the CHSGS group, the fluoxetine group, and the healthy group were statistically significant difference ( $P < 0.001$ ). There was no statistically significant difference in HAMD scores between the CHSGS group and the fluoxetine group ( $P = 0.342$ ). Correlations were not found between baseline HAMD scores and age of depression both in the CHSGS and in the fluoxetine ( $P = 0.25$ ;  $P = 0.31$ , respectively). After treatment, all of the patients with major depression both in the CHSGS group and in the fluoxetine group were rescanned using SPECT. Of the 20 healthy controls, two did not attend follow-up visits. The 20 CHSGS-treatment depressed patients were not found any side-effects. The four of the 13 fluoxetine-treatment patients reported the side-effects including sleepiness ( $n = 2$ ), light-headed ( $n = 1$ ), and weight gain ( $n = 1$ ).

### Visual assessment

SPECT abnormalities were detected in all depressed patients including the CHSGS and the fluoxetine group (100.0%), whereas all healthy controls were observed normal SPECT rCBF imaging. There were statistically significant difference ( $P < 0.001$ ). Before treatment, the depressed patients both in the CHSGS group and in the fluoxetine group were found rCBF abnormality at least one brain region that were involved in frontal lobe, temporal lobe, parietal lobe, occipital lobe, and caudate nucleus. The lesions number in CHSGS group was 72, distributed in left frontal ( $n = 16$ ), right frontal ( $n = 10$ ), left temporal ( $n = 12$ ), right temporal ( $n = 8$ ), left parietal ( $n = 8$ ), right parietal ( $n = 5$ ), left occipital ( $n = 5$ ), right occipital ( $n = 3$ ), left caudate nucleus ( $n = 3$ ), and right caudate nucleus ( $n = 2$ ). In the fluoxetine group, the lesions number was 45, distributed in left frontal ( $n = 12$ ), right frontal ( $n = 8$ ), left temporal ( $n = 8$ ), right temporal ( $n = 4$ ), left parietal ( $n = 3$ ), right parietal ( $n = 2$ ), left occipital ( $n = 3$ ), right occipital ( $n = 3$ ), and left caudate nucleus ( $n = 2$ ). [Figure 1: Major patients showed significant rCBF decreases in left frontal, left temporal, and left parietal.]

rCBF semiquantitative values comparisons among the three groups in pretreatment

Semiquantitative analysis showed that specific values (semiquantitative value) of the CHSGS, fluoxetine group, and healthy group in pretreatment are shown in Table 2. Statistically significant differences were observed in the frontal lobes (including left and right) and the left temporal lobes, with uptake defects in depressed patients both of the CHSGS group and the fluoxetine



group ( $P < 0.05$ ). There was no statistical difference in each brain region between in the CHSGS group and the fluoxetine group ( $P > 0.05$ ).

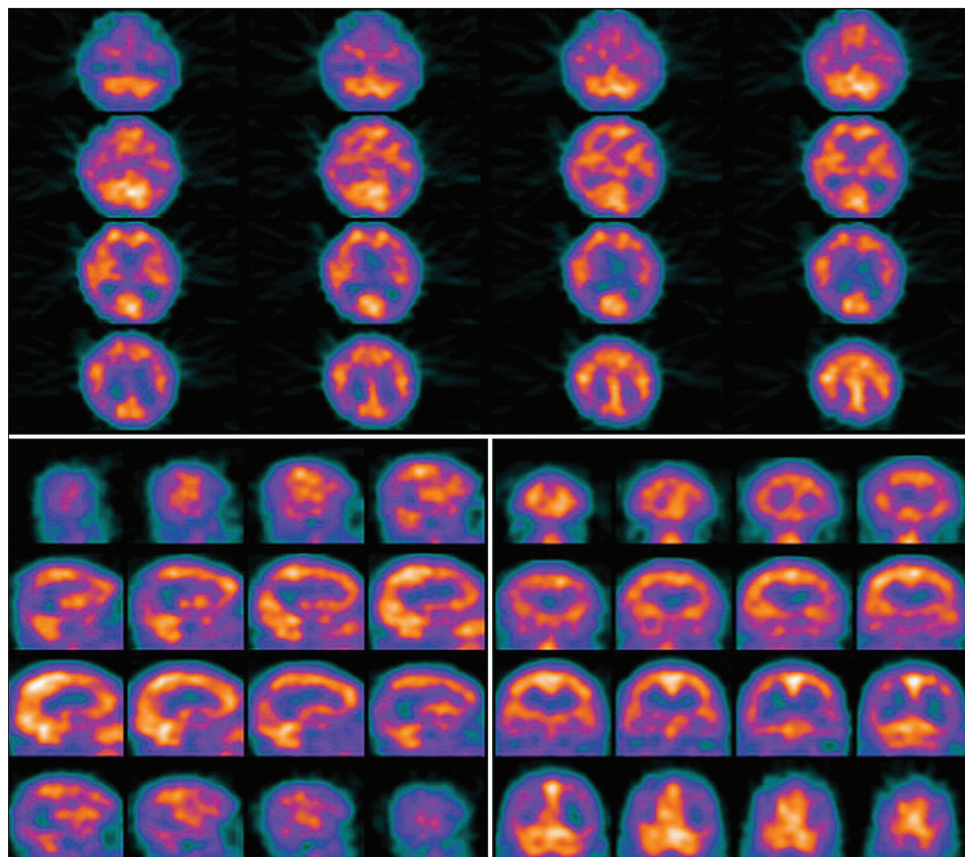
**Table 2: Comparisons of semi-quantitative values among different groups in pretreatment**

Brain regions	CHSGS (n=20)	Fluoxetine (n=13)	Healthy (n=20)
L frontal	0.64±0.14*	0.65±0.17*	0.92±0.01
R frontal	0.90±0.06#	0.87±0.05*	0.93±0.02
L temporal	0.87±0.07*	0.88±0.07*	0.93±0.02
R temporal	0.92±0.04	0.91±0.05	0.94±0.02
L parietal	0.92±0.04	0.91±0.08	0.93±0.01
R parietal	0.93±0.04	0.92±0.06	0.95±0.02
L occipital	0.93±0.04	0.93±0.03	0.95±0.03
R occipital	0.91±0.04	0.92±0.05	0.93±0.02
L thalamus	0.93±0.03	0.93±0.02	0.94±0.02
R thalamus	0.93±0.03	0.94±0.02	0.95±0.01
L basal ganglia	0.92±0.02	0.91±0.03	0.94±0.02
R basal ganglia	0.93±0.02	0.92±0.04	0.93±0.02
L white matter	0.95±0.02	0.96±0.04	0.95±0.03
R white matter	0.95±0.02	0.94±0.05	0.94±0.03
L caudate nucleus	0.92±0.04	0.92±0.03	0.93±0.02
R caudate nucleus	0.92±0.03	0.92±0.04	0.93±0.02

CHSGS: CHSGS group; Fluoxetine: Fluoxetine group; Healthy: Healthy group; L: Left; R: Right, All values are mean±standard deviation (mean±SD). \*Compared with healthy group  $P < 0.01$ ; #Compared with healthy group  $P < 0.05$ , rCBF: Regional cerebral blood flow; CHSGS: Chaihu-Shugan-San

Between pre- and posttreatment rCBF semiquantitative values and HAMD scores comparisons in the CHSGS group, the fluoxetine group, and the healthy control group.

The 20 major depressed patients were treated with CHSGS in a period of 8 weeks. HAMD scores tests were repeated and SPECT imaging reexamined in posttreatment. With the clinical cerebral symptoms improved, these depressed patients whose HAMD scores were reduction with varying extent showed rCBF perfusion defects had improved significantly or even disappeared (radioactive filled or partially filled) and were not found new lesions. Semiquantitative analysis were performed and the rCBF semiquantitative values were compared in the corresponding lesions between pre- and posttreatment [Table 3]. The 13 major depressed patients were treated with fluoxetine in a same period of 8 weeks. Their HAMD scores were reduction in posttreatment with clinical cerebral symptoms improved and rCBF perfusion defects in corresponding brain region were reversed. The rCBF semiquantitative values were compared between pre- and postfluoxetine [Table 3]. The 18 of the 20 healthy controls were reexamined SPECT imaging after 8 weeks. Their physical conditions and the results of rCBF imaging were found no changes ( $P > 0.05$ ).



**Figure 1:** Patients with major depression showed significant rCBF decreased in left frontal, left temporal and left parietal

**Table 3: Semi-quantitative values and Hamilton depression rating scale scores comparisons in the Chaihu-Shugan-San, the fluoxetine groups and the healthy control group between pre- and posttreatment**

Region	CHSGS group			Fluoxetine group			Healthy group		
	Pre	Post	P	Pre	Post	P	Pre	Post	P
L frontal	0.64±0.13	0.82±0.09	0.01	0.62±0.03	0.78±0.11	0.01	0.92±0.01	0.93±0.02	1.32
R frontal	0.86±0.04	0.87±0.04	0.01	0.84±0.04	0.89±0.03	0.01	0.93±0.02	0.92±0.03	0.25
L temporal	0.82±0.03	0.86±0.03	0.01	0.84±0.05	0.88±0.06	0.01	0.93±0.02	0.94±0.01	2.13
R temporal	0.84±0.04	0.85±0.04	0.04	0.85±0.04	0.89±0.03	0.03	0.94±0.02	0.95±0.01	1.43
L parietal	0.85±0.03	0.88±0.03	0.01	0.79±0.08	0.86±0.05	0.41	0.93±0.01	0.92±0.03	1.58
R parietal	0.87±0.02	0.89±0.02	0.12	0.85±0.04	0.88±0.01	0.59	0.95±0.02	0.96±0.01	1.49
L occipital	0.90±0.02	0.91±0.01	0.12	0.86±0.04	0.90±0.02	0.18	0.95±0.03	0.95±0.04	3.12
R occipital	0.91±0.02	0.91±0.04	0.11	0.89±0.03	0.90±0.03	0.06	0.93±0.02	0.91±0.04	0.96
L caudate	0.85±0.04	0.88±0.02	0.03	0.88±0.03	0.91±0.01	0.50	0.93±0.02	0.92±0.03	1.38
R caudate	0.89±0.02	0.90±0.02	0.53	0.90±0.02	0.91±0.02	0.56	0.93±0.03	0.93±0.02	3.22
HAMD	34.82±9.31	27.74±10.23	0.01	31.74±12.30	26.22±13.03	0.02	4.27±3.03	4.11±3.21	3.88

L: Left; R: Right, All values are mean±SD. L caudate: L caudate nucleus; R caudate: Caudate nucleus; CHSGS: Chaihu-Shugan-San

## DISCUSSION

Changes in rCBF during and after treatment have been documented. Previously using  $^{99m}\text{Tc}$ -hexamethylpropylene-amine oxime ( $^{99m}\text{Tc}$ -HMPAO) brain SPECT have shown rCBF changes involved: Global cerebral blood flow (CBF) decreased,<sup>[13]</sup> left frontal CBF decreased,<sup>[3]</sup> CBF decreased both in the left and right anterior frontal<sup>[14]</sup> and in temporal lobe,<sup>[7]</sup> as well as in thalamus, right posterior cingulate, right parietal cortex, and right caudate nucleus<sup>[15]</sup> in depressed patients when compared with normal controls.

In the pretreatment studies, we found frontal and temporal regions were most commonly affected both in the CHSGS group and the fluoxetine group, followed by parietal, occipital, and caudate nucleus regions. Basal ganglia, white matter, and cerebellum were not found abnormalities. According to semiquantitative analysis, the semiquantitative values of frontal and temporal particularly in the left hemisphere were significantly lower in the CHSGS group and the fluoxetine group than that in the healthy group. Frontal lobes are considered as our emotional control center and home to our personality, which are involved in emotions, memory, learning, motor function, problem solving, spontaneity, language, initiation, judgment, impulse control, social, and sexual behavior. While temporal lobes are connection with speech, memory, reading, emotional, auditory, visual, and olfactory responses. Therefore, we think rCBF decrease in frontal and temporal are most common manifestations in the patients with major depression who met the diagnostic criteria of the stagnation of Liver-qi with TCM syndrome differentiation.

Fluoxetine belongs to a class of drugs known as SSRIs as a treatment for depression. The efficacy of SSRIs in the treatment of depression has been demonstrated. However, the extant indicated that SSRIs, such as fluoxetine, would

result in an adequate clinical responses in only 60% of patients<sup>[16]</sup> Furthermore, reports of fluoxetine side-effects such as fluoxetine-induced agitation and suicidality have begun to emerge in recent years and there is a growing concern regarding the safety profile of this class, especially in the pediatric population.<sup>[17,18]</sup> In the current study, of the 13 major depression treated with fluoxetine, 4 (31%) were reported side-effects. The 20 depressed patients treated with CHSGS had no discomfort in the period of treatment. According to the TCM theory, the basic pathogenesis of depression is that the liver fails to maintain the normal flow of qi and the stagnation of liver qi, and the basic rule to treat depression is to regulate qi-movement. After long-term of liver-qi stagnation, the blood aspect will be involved and the blood circulation will be unsmooth and finally result in blood stasis. CHSGS has the effect of soothing liver, promoting the circulation of qi and blood as well as relieving pain. So CHSGS was applied to soothe the liver, disperse the stagnation, and activate blood. So far, CHSSG is the most classical representative formula in treating the stagnation of qi due to depression of the liver.

In the current study, the psychiatric symptoms were improved and HAMD scores decreased in post-CHSGS treatment depressed patients. CHSGS was as effective as fluoxetine in the treatment of depression that proved the CHSGS treatment has an antidepressant effect with minimal side-effect. Repeated SPECT examinations were no new cerebral blood flow lesions. SPECT imaging showed significant improvement or even disappearance of perfusion defects and the semiquantitative values were commonly increased, especially, in bilateral frontal, temporal, and left parietal cortex. As aforementioned, SPECT imaging result was consistent with the effect of treatment and rCBF reversed by effective treatment with CHSGS.

In this study, both visual and semiquantitative assessments were used to analyze the data. In pre-CHSGS treatment studies, perfusion abnormality was visualized mainly in the frontal and temporal lobes. Other brain lobes were also observed the rCBF reduced. Compared with the visual results, semiquantitative analysis only showed rCBF decreased in frontal and left temporal lobes. In the post-CHSGS treatment images of the current study, all depressed patients who responded to CHSGS and fluoxetine showed perfusion defects were improvement by visual assessment. When the semiquantitative method was applied, significant changes were found in bilateral frontal, temporal, and left parietal. The author considered that the reasons of discrepancy between visual and semiquantitative results may be the lesions were widely distributed, which affected the semiquantitative value in patient group. Therefore, we need further studies to reconcile the discrepancy.

Limitations: Since our sample size was still relatively small, the current results require replication and further clarification in a larger patient population. Second, Statistical Parametric Mapping method based on the functional brain information may be more effective than the ROI based on the structural information. This new method should be applied in the further studies.

In conclusion, SPECT represents a sensitive tool to detect the major depressive disorder, which show the rCBF decreased, especially in the frontal and temporal lobe. rCBF perfusion defects can be reversed and clinical symptoms can be improved by CHSGS treatment. The current study suggests that CHSGS treatment is effective, well-tolerated, and safe for depression. By semiquantitative analysis, SPECT can objectively detect rCBF changes that is useful in follow-up, particularly for guiding treatment.

## REFERENCES

- Price J, Cole V, Goodwin GM. Emotional side-effects of selective serotonin reuptake inhibitors: Qualitative study. *Br J Psychiatry* 2009;195:211-7.
- Zhang Y, Cui XL, Yang LP, Jia Y, Liu J, Pan H. Adverse drug reaction induced by antidepressants of SSRI and SNRI. *Chin J Pharmacol Vigilance* 2010;9:554-6.
- Cho MJ, Lyoo IK, Lee DW, Kwon JS, Lee JS, Lee DS, *et al.* Brain single photon emission computed tomography findings in depressive pseudodementia patients. *J Affect Disord* 2002;69:159-66.
- Videbech P. PET measurements of brain glucose metabolism and blood flow in major depressive disorder: A critical review. *Acta Psychiatr Scand* 2000;101:11-20.
- Wu H, Lou C, Huang Z, Shi G. SPECT imaging of dopamine transporters with (99m) Tc-TRODAT-1 in major depression and Parkinson's disease. *J Neuropsychiatry Clin Neurosci* 2011;23:63-7.
- Simth DJ, Cavanagh JT. The use of single photon emission computed tomography in depressive disorders. *Nucl Med Commun* 2005;26:197-203.
- Vangu MD, Esser JD, Boyd IH, Berk M. Effects of electroconvulsive therapy on regional cerebral blood flow measured by 99mtechnetium HMPAO SPECT. *Pro Neuropsychopharmacol Biol Psychiatry* 2003;27:15-9.
- Bonne O, Krausz Y, Shapira B, Bocher M, Karger H, Gorfine M, *et al.* Increase cerebral blood flow in depressed patients responding to electroconvulsive therapy. *J Nucl Med* 1996;37:1075-80.
- American Psychiatric Association. *Diagnostic and Statistical Manual of Mental Disorders*. 4<sup>th</sup> ed. Washington, DC: American Psychiatric Association; 1994. p.27-40.
- Hamilton M. A rating scale for depression. *J Neurol Neurosurg Psychiatry* 1960;23:56-62.
- Gong SL, editor. *Depression*. Beijing: People's Medical Publish House; 2003. p.1-4, 8-56.
- Hu SY. Study on liver controlling dispersion. *J Tradit Chin Med Univ Hunan* 2010;30:6-8.
- Ohgami H, Nagayama H, Akiyoshi J, Tsuchiyama K, Komaki S, Takaki H, *et al.* Contributing factors to changes of cerebral blood flow in major depressive disorder. *J Affect Disord* 2005;87:57-63.
- Navarro V, Gastó C, Lomeña F, Mateos JJ, Marcos T, Portella MJ. Normalization of frontal cerebral perfusion in remitted elderly major depression: A 12-month follow-up SPECT study. *Neuroimage* 2002;16:781-7.
- Curran SM, Murray CM, Van Beck M, Dougall N, O'Carroll RE, Austin MP, *et al.* A single photo emission computed tomography study of regional brain function in elderly patients with major depression and with Alzheimer-type dementia. *Br J Psychiatry* 1993;163:155-65.
- Tsapakis EM, Soldani F, Tondo L, Baldessarini RJ. Efficacy of antidepressants in juvenile depression: Meta-analysis. *Br J Psychiatry* 2008;193:10-7.
- Schirman S, Kronenberg S, Apter A, Brent D, Melhem N, Pick N, *et al.* Effectiveness and tolerability of citalopram for the treatment of depression and anxiety disorders in children and adolescents: An open-label study. *J Neural Transm* 2010;117:139-45.
- Fang Y, Yuan C, Xu Y, Chen J, Wu Z, Cao L, *et al.* Comparisons of the efficacy and tolerability of extended-release venlafaxine, mirtazapine and paroxetine in treatment-resistant depression: A double-blind, randomized pilot study in Chinese population. *J Clin Psychopharmacol* 2010;30:357-64.

**Cite this article as:** Qiu J, Hu S, Shi G, Wang S. Changes in regional cerebral blood flow with Chaihu-Shugan-San in the treatment of major depression. *Phcog Mag* 2014;10:503-8.

**Source of Support:** Nil, **Conflict of Interest:** None declared.