

Vitiligo associated with polycaprolactone-based collagen stimulator filler



Chun-Hsien Huang, MD,^a and Chau Yee Ng, MD, PhD^{a,b,c,d}
Taipei, Linkou and Taoyuan City, Taiwan

Key words: case reports; dermal fillers; injection site reaction; polycaprolactone; vitiligo.

INTRODUCTION

Injectable collagen stimulators are commonly used as dermal fillers to treat aging and volume loss in aesthetic practices. Injection site reactions, such as edema and redness, are not uncommon after receiving injectables.¹ The polycaprolactone (PCL)-based filler Ellansé (Sinclair Pharmaceuticals) is a collagen stimulator with a proven safety profile. However, complications, such as nodularity and granulomas due to the host's immune factors, can occur. Vitiligo is a chronic depigmentation disorder that is difficult to treat and may be irreversible. To our knowledge, vitiligo associated with injectable collagen stimulators has not been reported previously in the literature. Herein, we report the first case of a 23-year-old woman with vitiligo after receiving a PCL-based collagen stimulator filler.

CASE REPORT

An otherwise healthy, 23-year-old woman presented to our clinic with a 2-cm depigmented oval patch on the lower portion of her right eyelid, 2 weeks after receiving a PCL-based filler to treat her tear-trough deformity (Fig 1, A). She also developed asymptomatic subcutaneous nodularity at the treated area, which persisted for a year. The patient had a family history of lupus erythematosus and autoimmune thyroid disease. Laboratory examinations were unremarkable, indicating normal thyroid function and negative antinuclear antibodies. A Wood's lamp examination revealed purple fluorescence, indicating a depigmentation process with the loss of melanocytes, favoring a diagnosis of vitiligo

Abbreviation used:

PCL: polycaprolactone

(Fig 1, B). The patient received topical 0.1% tacrolimus ointment and biweekly, 308-nm excimer light treatment. The lesion subsided 5 months later and remained stable for a year (Fig 2).

DISCUSSION

Vitiligo is a common, psychologically devastating, autoimmune, skin depigmentation disease that results from the cytotoxic T cell-mediated destruction of melanocytes. It is characterized by asymptomatic, well-defined, white macules and patches that may be irreversible when the damage is too advanced. The mechanism of vitiligo is multifactorial, encompassing genetic susceptibility and environmental stimuli. Recent studies have shown that derailed immunity plays a crucial role in the pathogenesis of vitiligo. Aberrant oxidative stress removal capabilities cause the release of damage-associated molecular proteins and attract innate immune cells to initiate the autoimmune process. In adaptive immunity, autoreactive CD8⁺ T cells have been shown to induce melanocyte apoptosis and regulatory T cell deficiencies, further inducing unrestricted autoreactive immunity.²

De Boule et al³ published a review of patient factors that influenced complications of dermal fillers. Autoimmune diseases, including dermatomyositis, lupus erythematosus, rheumatoid arthritis,

From the Department of Dermatology, Chang Gung Memorial Hospital, Taipei, Linkou,^a The School of Medicine, College of Medicine,^b Graduate Institute of Clinical Medical Sciences, Chang Gung University, Taoyuan City,^c and Vitiligo Clinic and Research Center, Chang Gung Memorial Hospital, Taipei.^d

Funding sources: Supported by the Medical Research Council, Chang Gung Memorial Hospital [grant number CMRPGBJ0023] and the Ministry of Science and Technology of Taiwan [grant number MOST 110-2314-B-182A-155-MY3].

IRB approval status: Approved [IRB number 202100735B0].

Correspondence to: Chau Yee Ng, MD, PhD, Department of Dermatology, Chang Gung Memorial Hospital, Linkou, 5,

Fuxing St, Guishan Dist, Taoyuan 33305, Taiwan. E-mail: cyn87@cgmh.org.tw.

JAAD Case Reports 2022;24:35-7.

2352-5126

© 2022 by the American Academy of Dermatology, Inc. Published by Elsevier, Inc. This is an open access article under the CC BY-NC-ND license (<http://creativecommons.org/licenses/by-nc-nd/4.0/>).

<https://doi.org/10.1016/j.jdc.2022.04.007>

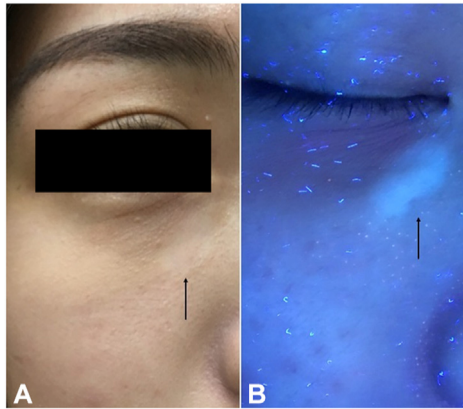


Fig 1. A well-defined, depigmented oval patch developed on the lower portion of the right eyelid 2 weeks after the patient received a polycaprolactone-based collagen stimulator filler injection for tear-trough soft-tissue augmentation. **A**, Room light. **B**, Wood's lamp.

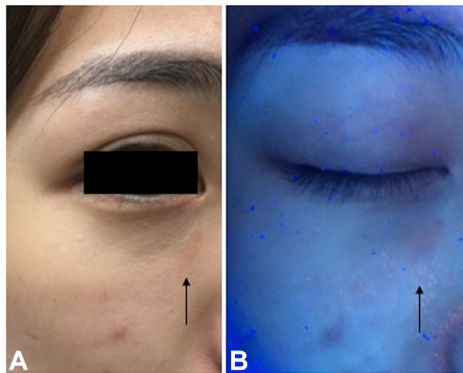


Fig 2. Complete repigmentation of the lesion after topical 0.1% tacrolimus ointment and biweekly excimer light treatment for 5 months. **A**, Room light. **B**, Wood's lamp.

active Hashimoto disease, and mixed connective tissue disease, were listed as contraindications or treated at the physician's discretion. Vitiligo was not contraindicated in this context owing to a lack of reports in the previous literature.

Our patient developed a depigmented patch 2 weeks after receiving a PCL-based collagen stimulator injection to correct her tear-trough deformity. According to the literature review and to our knowledge, no cases of vitiligo associated with PCL-based collagen stimulator fillers have been reported previously. The PCL-based fillers induced collagenesis through 3 main phases: inflammation, proliferation, and remodeling.⁴ Based on these mechanisms, we postulate that the inflammation stage following PCL-based filler injections may attract autoreactive immune cells in susceptible individuals. These inflammatory cells produce cytokines or chemokines that attract more autoreactive immune cells, causing melanocyte apoptosis.

Inflammatory cytokines, such as interferon gamma, can also directly affect melanogenesis and result in increased cellular stress or even cell death in melanocytes.^{5,6} Under cellular stress, damage-associated molecular proteins are generated and attract innate immunity, which initiates the autoimmune pathogenesis.

The Koebner phenomenon is an isomorphic response, commonly found in autoimmune skin diseases, whereby new skin lesions arise at previously unaffected skin sites secondary to trauma.⁷ The occurrence of vitiligo may be a Koebner phenomenon and not caused by the contents of the PCL filler. The intradermal injection of insulin and antigens has been shown to induce the Koebner phenomenon in the psoriasis model but has been rarely reported in vitiligo.⁸ Hedges et al⁹ reported the first case of intradermal insulin injection–induced vitiligo and lipohypertrophy. Chemical leukoderma is a condition in which the chemical substance of a particular product induces the loss of pigment in the contact area.¹⁰ Such events have been reported following contact with consumer products (hair dye, deodorant, detergent, rubber gloves, etc).¹⁰ Products containing phenol and catechol derivatives can more easily induce oxidative stress and melanocytotoxicity, initiating the vitiligo process.¹⁰ Although injectable collagen stimulators have not been reported to do so, the possibility cannot be excluded. Further functional studies are needed to clarify the causal relationship between injectables and vitiligo and the associated pathologic mechanism.

In conclusion, herein, we report an interesting case of vitiligo associated with an injection of a PCL-based collagen stimulator filler. We believe that this case report can serve as a reminder that vitiligo may occur after injectables. Patients with pre-existing vitiligo or autoimmune diseases should be informed about this possible side effect. To avoid the Koebner phenomenon, traumatic procedures should be postponed until the disease activity is stabilized. Further studies are needed to confirm the safety of collagen stimulator fillers in patients with autoimmune disorders such as vitiligo.

The authors thank Chang Gung Memorial Hospital Research Grant and Ministry of Science and Technology of Taiwan for the funding support and patient participation in this case study.

Conflicts of interest

None disclosed.

REFERENCES

1. Lin SL, Christen MO. Polycaprolactone-based dermal filler complications: a retrospective study of 1111 treatments. *J*

- Cosmet Dermatol.* 2020;19(8):1907-1914. <https://doi.org/10.1111/jocd.13518>
- Chen J, Li S, Li C. Mechanisms of melanocyte death in vitiligo. *Med Res Rev.* 2021;41(2):1138-1166. <https://doi.org/10.1002/med.21754>
 - De Boule K, Heydenrych I. Patient factors influencing dermal filler complications: prevention, assessment, and treatment. *Clin Cosmet Investig Dermatol.* 2015;8:205-214. <https://doi.org/10.2147/ccid.s80446>
 - Christen MO, Vercesi F. Polycaprolactone: how a well-known and futuristic polymer has become an innovative collagen-stimulator in esthetics. *Clin Cosmet Investig Dermatol.* 2020;13:31-48. <https://doi.org/10.2147/ccid.s229054>
 - Fu C, Chen J, Lu J, et al. Roles of inflammation factors in melanogenesis (review). *Mol Med Rep.* 2020;21(3):1421-1430. <https://doi.org/10.3892/mmr.2020.10950>
 - Yang L, Wei Y, Sun Y, et al. Interferon-gamma inhibits melanogenesis and induces apoptosis in melanocytes: a pivotal role of CD8+ cytotoxic T lymphocytes in vitiligo. *Acta Derm Venereol.* 2015;95(6):664-670. <https://doi.org/10.2340/00015555-2080>
 - Taieb A, Picardo M. Clinical practice. Vitiligo. *N Engl J Med.* 2009;360(2):160-169.
 - Madhavan P, Hamann L, Shoukri K, Dulipsingh L. Koebner phenomenon from insulin injection. *Cleve Clin J Med.* 2021; 88(5):264. <https://doi.org/10.1056/nejmcp0804388>
 - Hedges K, Poole RB. Vitiligo and lipohypertrophy surrounding insulin injection sites in a patient with type 1 diabetes. *Pract Diabetes.* 2016;33(1):27-28a. <https://doi.org/10.1002/pdi.1994>
 - Harris JE. Chemical-induced vitiligo. *Dermatol Clin.* 2017;35(2): 151-161. <https://doi.org/10.1016/j.det.2016.11.006>