



# Gastrointestinal complications (gangrene or perforation) after corona virus disease 2019 — A series of ten patients

Sudarshan B. Chaugale<sup>1</sup> · Vikas Singhal<sup>1</sup>  · Deeksha Kapoor<sup>1</sup> · Amanjeet Singh<sup>1</sup>

Received: 1 July 2021 / Accepted: 19 August 2021 / Published online: 26 April 2022  
© Indian Society of Gastroenterology 2022

## Abstract

During the recent second wave of corona virus disease 2019 (COVID-19) pandemic in India, we managed a series of gastrointestinal complications in patients with COVID-19. We aim to highlight the key presentation and clinical course and emphasize the lessons we learnt from our series of such patients. A case review of ten consecutive patients with either bowel gangrene or perforation who were managed at our centre from March 20, 2021 to June 10, 2021. Clinical-demographic details, possible etiology, radiological findings, management and outcomes have been described. Of the 10 patients, 2 presented with bowel gangrene and 8 with perforation. In our series, all these patients were diagnosed with the help of computed tomography (CT) abdomen during the 3rd week after diagnosis of COVID-19. All had received steroid medication. Both patients with bowel gangrene and 4 of 8 patients with perforation underwent surgery, while 4 were managed non-operatively. Barring one patient, all the operated patients succumbed within 5 days of surgery after rapid clinical deterioration. Non-operative management in selected patients with perforation including placement of percutaneous drains, bowel rest and antibiotics was successful. Emergency surgery for COVID-19 related intestinal gangrene or perforation was associated with high mortality in our series. Non-operative management which avoids the added stress of a major emergency surgery particularly in patients just recovering from COVID-19 may be considered in stable patients in whom perforation appears to be contained.

**Keywords** Angiotensin Converting Enzyme- 2 (ACE-2) receptor · Bowel gangrene · Bowel perforation · COVID-19 · Cytotoxic effect · Intestinal complications · Pandemic · Steroids · Thromboembolism · Tocilizumab

---

✉ Vikas Singhal  
singhalvik@gmail.com

<sup>1</sup> Department of GI Surgery, GI Oncology, Minimal Access and Bariatric Surgery, Medanta Medicity Hospital, Sector 38, Islampur, 122 001, Gurugram, India

### **Bullet points of the study highlights**

#### ***What is already known?***

- Corona virus disease 2019 (COVID-19) may cause bowel gangrene and perforation.
- Etiology can be either direct cytopathic effect, thromboembolism or medication induced.
- Treatment is typically emergency surgical exploration.

#### ***What is new in this study?***

- Intestinal complications occur during the recovery phase of COVID-19 infection mostly in the 3rd week.
- Surgical exploration is associated with very high mortality due to added surgical stress.

#### ***What are the future clinical and research implications of the study findings?***

- Low threshold to investigate new onset gastrointestinal symptoms during recovery phase typically in 3rd week of COVID-19 with computed tomography.
- Bowel perforation with localized collection can be managed nonoperatively.

## **Introduction**

As corona virus disease 2019 (COVID-19) pandemic continues to ravage the world, India is currently emerging from its second wave of infections, during which gastrointestinal (GI) manifestations of COVID-19 have been increasingly experienced. Mao et al. in their systematic review and meta-analysis reported the prevalence of GI symptoms such as nausea, vomiting and diarrhea in 15% of 6064 patients [1]. Highly fatal intestinal complications such as perforation, ischemia and gangrene have also been reported from all over the world [2].

The Angiotensin Converting Enzyme-2 (ACE-2) receptor is a well-recognized receptor of the virus found in the epithelial cells of GI tract apart from the pulmonary alveolar cells [3]. While immunopathogenesis of intestinal complications remains unclear, direct viral injury, imbalanced host immune responses [4], thromboembolic phenomenon and use of tocilizumab may be a factor in their etiology [5]. Use of steroids, often in high doses, especially in an unmonitored setting also remains a possible cause of intestinal perforation.

As a tertiary care referral centre in northern India, we recently managed a spurt of cases with intestinal complications. We report our series of 10 patients with post-COVID-19 bowel complications, and discuss the clinical course, management and outcomes.

## **Case series**

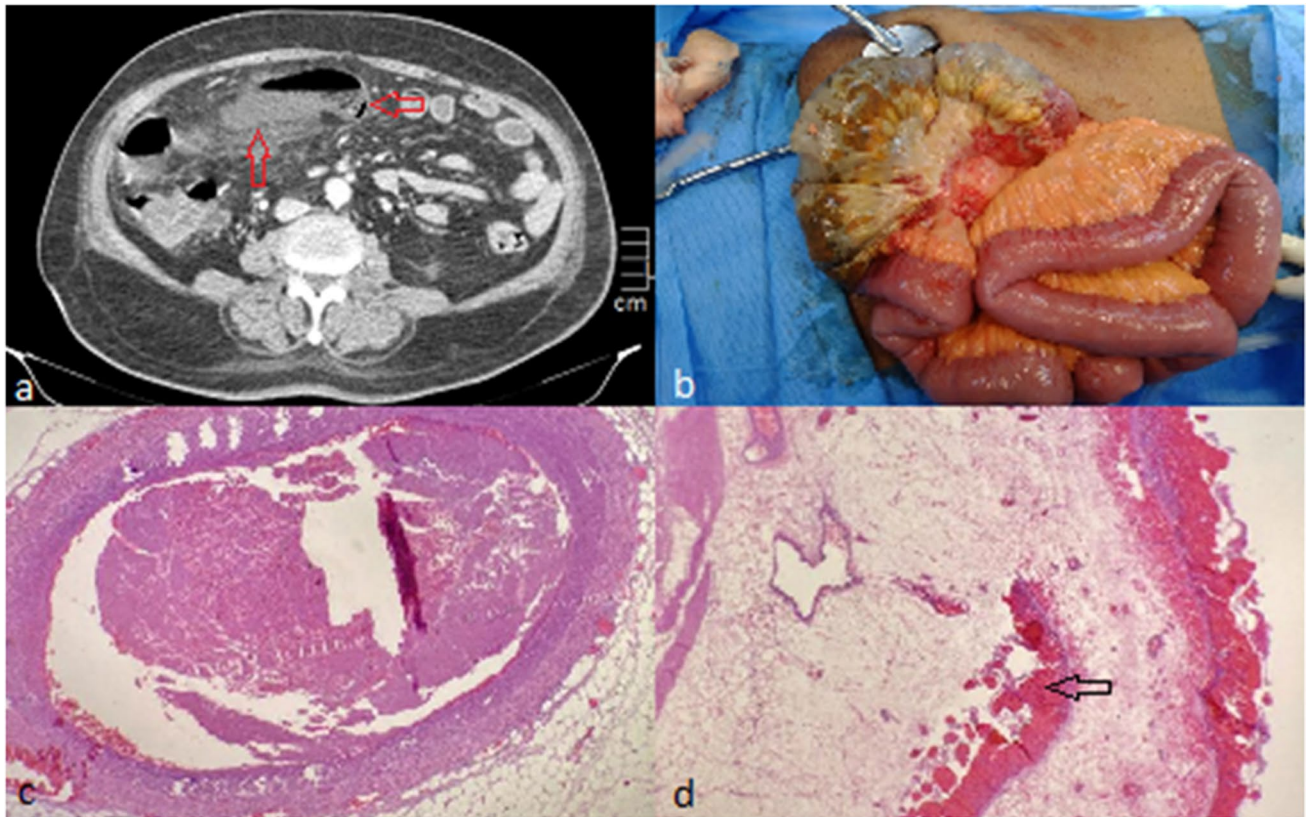
From March 20, 2021 to June 10, 2021, ten patients underwent management for post-COVID bowel complications at our Institute. Records of these patients were obtained from the medical records department. Clinical and demographic details, radiological findings and management strategies were studied (Table 1).

Of the 10 cases, 8 had intestinal perforation while 2 had intestinal gangrene. Most were men in their 5–7th decade of life with complaints of abdominal pain (9/10), vomiting (4/10), inability to pass flatus/stools (4/10) and abdominal distension (1/10). Eight of these patients had diabetes mellitus (DM) and two had hypertension (HTN). One had a history of ischemic heart disease (IHD) with chronic kidney disease (CKD) and one had Child C liver cirrhosis. Most patients presented during the third/fourth week of COVID-19 (Table 1). Most received steroids and two had received tocilizumab. Case 5 had received vaccination (Covishield, Serum Institute of India, Pune, India) with a gap of 7 weeks, however developed fever and tested positive for COVID 2 days after the second dose. Case 8 had received the first dose of Covishield, but 15 days later developed fever and was diagnosed having COVID-19. All were evaluated with computed tomography (CT) scan of the abdomen (Table 1). Two patients had hypo-enhancing bowel loops suggestive of ischemia/gangrene (case 1 — image 1A and case 2), while others had pneumoperitoneum with abdominal collections (cases 3–10).

**Table 1** Patient clinical details, characteristics and imaging

Case	1	2	3	4	5	6	7	8	9	10
Age in years	40	72	70	56	71	50	68	57	72	25
Gender	Male	Male	Male	Male	Male	Male	Female	Female	Male	Male
Comorbidities	DM, HTN	DM, HTN	HTN	DM	DM, HTN	DM	CLD, Child C	None	HTN, CKD, IHD	None
COVID Vaccination	No	No	No	No	Both doses of Covishield	No	No	1 dose of Covishield	No	No
CTSS	32/40	28/40	13/40	10/25	5/25	13/25	11/25	9/25	10/40	11/25
COVID severity	Severe	Moderate	Moderate	Severe	Moderate	Severe	Severe	Severe	Moderate	Moderate
CRP (mg/L)	65	72	148	324	17	182.1	149	106	243	234
D-dimer (ng/mL)	6013	410	71.93	1440	2772		3851		2068	703
Steroids	IV	IV	Oral	IV	Oral	IV	Oral	IV	Oral	Oral
TZ <sup>c</sup>	Yes	No	No	Yes	No	No	No	No	No	No
Anticoagulants	Yes	Yes	No	Yes	Yes	No	Yes	Yes	Yes	No
Day of GI symptoms	15	13	18	24	17	18	16	19	18	22
Computed tomography findings	Short segment of hypo-enhancing jejunum	Long segment of hypo-enhancing terminal ileum	Pneumo-peritoneum	Pneumo-peritoneum and distended large bowel	Pneumo-peritoneum and distended large bowel	Pneumo-peritoneum and retroperitoneal collection	Pneumo-peritoneum and contrast leak from sigmoid colon and abdominal collections	Cecal/ascending colon perforation and localized collection	Cecal perforation and localized collection	Ascending colon perforation with localized collection

Cases 1, 2, 3 and 9 — CTSS out of 40 (CTSS was defined by summing up individual score from 20 lung regions; scores of 0, 1 and 2 were assigned to each region)  
 Cases 4, 5, 6, 7, 8 and 10 — CTSS out of 25 (CTSS was calculated based on the extent of lobar involvement. Each of the 5 lung lobes was visually scored on a scale of 0–5) computed tomography  
 CTSS Computed Tomography Severity Score, CRP C-reactive protein, TZ tocilizumab, GI gastrointestinal, DM diabetes mellitus, HTN hypertension, CLD chronic liver disease, CKD chronic kidney disease, IHD ischemic heart disease, IV intravenous

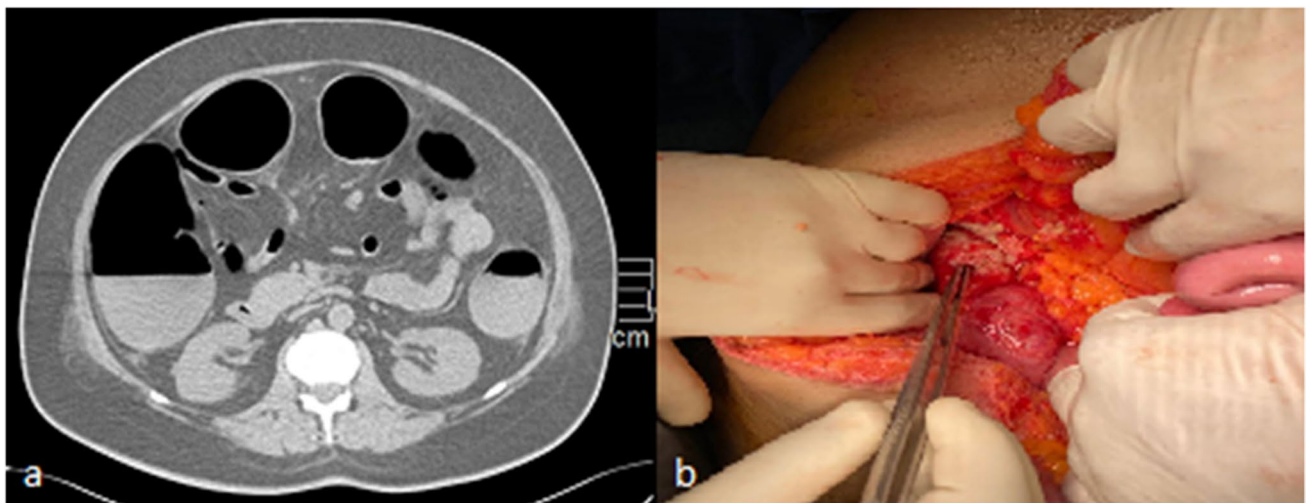


**Fig. 1** **a** Axial computed tomography abdomen with hypoenhancing ileal loop (vertical arrow) with intramural air (horizontal arrow). **b** Long segment ileal gangrene. **c, d** Microvascular thrombosis and submucosal necrosis with hemorrhage (arrow)

### Management and postoperative outcomes

The management of these patients was decided on the basis of clinical signs, imaging findings and the ability to tolerate general anesthesia.

**Cases 1 and 2** The patients presenting with intestinal gangrene were operated. In case 1 (Fig. 1a and b, there was a 40-cm gangrenous ileal segment, 10 cm proximal to ileocecal junction. An ileocecal resection with ileo-ascending anastomosis and diversion loop ileostomy was performed



**Fig. 2** **a** Axial computed tomography abdomen with dilated large bowel and pneumoperitoneum. **b** Ascending colon perforation

with an uneventful postoperative course and was discharged on postoperative day 7. The other patient (case 2) had a 5-cm segment of jejunal gangrene 20 cm distal to the ligament of Treitz. He underwent segmental jejunal resection with double barrel jejunostomy. He succumbed to septic shock on postoperative day 2. Histopathology of both the patients revealed organizing thrombus with microvascular thrombosis (Fig. 1c and d).

Of the eight patients presenting with intestinal perforation, four patients who had generalized peritoneal signs underwent surgical exploration. Others who were hemodynamically stable with localized peritoneal signs, underwent trial of non-operative management as described below. One patient with advanced chronic liver disease (CLD) was managed non-operatively with multiple percutaneous drains in spite of generalized peritoneal signs as she was felt to be very high risk for surgery.

**Cases 3, 4, 5 and 6 (operated patients)** The site of perforation was multiple pinpoint jejunal perforations (case 3), ascending colon (case 4 — Fig. 2a and b), sigmoid colon (case 5) and duodenum (case 6). Case 3 had multiple skip perforations in jejunum, extending 20 cm from duodeno-jejunal flexure to distal ileum. The intervening bowel was normal with good mesenteric vascular pulsations. Repair of perforations with abdominal drainage was performed. Cases 4 and 5 underwent repair of the colonic perforations with additional diversion loop ileostomy. Case 4 had an associated history of pulmonary thrombosis and left lower limb deep venous thrombosis. He developed type 1 respiratory failure in the postoperative period, following which he could not be salvaged. Case 6 was operated on day 20 of COVID recovery when he presented with acute abdomen for 2 days. Multiple duodenal perforations were encountered in the second and third parts of duodenum which were repaired and a feeding jejunostomy performed. Despite an initial clinical improvement in all cases except case 6, the patients eventually succumbed to septic shock and multiorgan dysfunction within the first week of surgery.

**Case 7** A 68-year-old lady with cryptogenic liver cirrhosis with sigmoid perforation was managed non-operatively. Multiple percutaneous abdominal drains were placed as the CT abdomen revealed multiple intra-abdominal collections with leak of rectal contrast from sigmoid colon. Despite her high-risk status with generalized peritoneal signs, she recovered and was discharged after 12 days of hospital stay. The drains were sequentially removed on an out-patient basis.

**Cases 8, 9 and 10** These patients presented with cecal/ascending colon perforations during recovery from COVID-19. The CT abdomen in all these patients revealed contained

perforations with confined pericolic collections. Ultrasound-guided percutaneous drainage was performed for 8th and 10th patients, while case 9 was managed with bowel rest and intravenous antibiotics. All three improved on non-operative management and were discharged.

## Discussion

Intestinal complications in COVID-19 have been found to be fatal. This case series stands important as with the possibility of subsequent waves of COVID-19, an understanding of these complications may guide their management. We observed that the intestinal complications occurred primarily during recovery from COVID-19, mostly in the third week. A similar observation was made in previous case reports [6, 7]. All patients had been treated with steroids, mostly for over a week. At the time of diagnosis of the intestinal complication, almost all patients had recovered from the COVID pneumonia. Generally, patients were hemodynamically stable with generalized/localized abdominal signs. Inflammatory markers were not consistently elevated. Since most patients had received steroids, reliable suggestions of sepsis could not be made solely on the basis of laboratory parameters. Ultimately, radiological evaluation with CT abdomen, in patients presenting with abdominal symptoms, helped in establishing a diagnosis.

Both the bowel gangrene patients were diabetic, had high CTSS (Computed Tomography Severity score) without any history of thromboembolic events. One had received tocilizumab, while both received steroids and prophylactic anticoagulants. The CT in neither revealed any major vascular thrombosis, while the surgical specimen was suggestive of thromboembolic vasculopathy, possibly due to direct cytopathic effect [8]. Elevated levels of Von-Willebrand factor as the virus affects the ACE-2 receptors expressed on the vascular endothelium, have also been proposed as a cause for microvascular thrombosis.

Of the 8 patients with intestinal perforation, all the 4 operated patients succumbed to the disease, while 3 managed non-operatively recovered. All except one operated patients with intestinal perforation showed some improvement in clinical condition for the initial 24 h; however, subsequently had a rapid clinical decline and died within 5 days of surgery. Although no conclusions can be drawn from a series of 10 patients, our series suggests that non-operative management may play a role in the management of stable patients with intestinal perforation and localized collections or patients at high risk for surgery. The recovery in these patients could be attributed to careful case selection and monitoring, with avoidance of surgical stress. Abate et al. in their meta-analysis showed a high postoperative mortality rate of 20% in patients with active severe acute respiratory

syndrome corona virus-2 (SARS-CoV-2) infection, highest being in emergency surgery of 29% [9]. This suggests that we may need to have a high threshold to operate patients even with intestinal perforation if non-operative treatment can be attempted.

In our series two patients presented with colonic ileus and associated perforation. There are a few case reports of COVID-related infectious colitis causing colonic ileus. A neuronal injury due to neuro-invasive propensity is regarded as a possible pathogenic mechanism [10]. These patients may benefit from timely colonic decompression and early imaging to rule out complications. Circumstances of the pandemic have dictated that patients in home isolation also received steroids often at improper doses. The RECOVERY trial [11] on use of steroids for moderate to severe COVID pneumonia demonstrated survival benefit in COVID-19 patients; however, GI complications were not evaluated. Interleukin-6 (IL-6) maintains mucosal integrity and colonic perforation is a known complication of IL-6 inhibition with tocilizumab [8].

To conclude, new onset GI symptoms during recovery from COVID-19 pneumonia in the third or fourth week warrant a low threshold for imaging with CT abdomen. The intestinal complications may be masked due to steroid use and have a high mortality. Though most patients require emergency surgery, non-operative management with percutaneous drainage may have a role in hemodynamically stable patients with localized collections under close observation as it avoids additional surgical stress that may lead to resurgence of the virus and its cytokine storm.

## Declarations

**Conflict of interest** BC, VS, DK, and AS declare that they have no conflict of interest.

**Disclaimer** The authors are solely responsible for the data and the contents of the paper. In no way, the Honorary Editor-in-Chief, Editorial Board Members, the Indian Society of Gastroenterology or the printer/publishers are responsible for the results/findings and content of this article.

**Ethics approval** The study was performed conforming to the Helsinki declaration of 1975, as revised in 2000 and 2008 concerning human and animal rights, and the authors followed the policy concerning informed consent as shown on Springer.com. This article was approved by the ethical committee of Medanta Hospital and research centre, Gurgaon.

## References

1. Mao R, Qiu Y, He JS, et al. Manifestations and prognosis of gastrointestinal and liver involvement in patients with COVID-19: a systematic review and meta-analysis. *Lancet Gastroenterol Hepatol.* 2020;5:667–78.
2. Bulte JP, Postma N, Beukema M, Inberg B, Stegeman AG, van der Hoeven H. COVID 19 and the risk of gastro-intestinal perforation: a case series and literature review. *J Crit Care.* 2022;67:100–103.
3. Zou X, Chen K, Zou J, Han P, Hao J, Han Z. Single-cell RNA-seq data analysis on the receptor ACE2 expression reveals the potential risk of different human organs vulnerable to 2019-nCoV infection. *Front Med.* 2020;14:185–92.
4. Blanco-Melo D, Nilsson-Payant BE, Liu WC, et al. Imbalanced host response to SARS CoV-2 drives development of COVID-19. *Cell.* 2020;181:1036–45.e9.
5. Jagpal A, Curtis JR. Gastrointestinal perforations with biologics in patients with rheumatoid arthritis: implications for clinicians. *Drug Saf.* 2018;41:545–53.
6. Soeselo DA, Hambali W, Theresia S. Bowel necrosis in patient with severe case of COVID-19: a case report. *BMC Surg.* 2021;21:97.
7. De Nardi P, Parolini DC, Ripa M, Racca S, Rosati R. Bowel perforation in a Covid-19 patient: case report. *Int J Colorectal Dis.* 2020;35:1797–800.
8. Xiao F, Tang M, Zheng X, Liu Y, Li X, Shan H. Evidence for gastrointestinal infection of SARS-CoV-2. *Gastroenterology.* 2020;158:1831–3.e3.
9. Abate SM, Mantefardo B, Basu B. Postoperative mortality among surgical patients with COVID-19: a systematic review and meta-analysis. *Patient Saf Surg.* 2020;14:37.
10. Conde Cardona G, Quintana Pájaro LD, Quintero Marzola ID, Ramos Villegas Y, Moscote Salazar LR. Neurotropism of SARS-CoV 2: mechanisms and manifestations. *J Neurol Sci.* 2020;412:116824.
11. RECOVERY Collaborative Group, Horby P, Lim WS, et al. Dexamethasone in hospitalized patients with Covid-19. *N Engl J Med.* 2021;384:693–704.

**Publisher's note** Springer Nature remains neutral with regard to jurisdictional claims in published maps and institutional affiliations.