

RESEARCH ARTICLE

Editorial Process: Submission:06/18/2022 Acceptance:11/25/2022

## A Comparison of the Characteristics of Cytokine Storm between Lichen Planus and Oral Squamous Cell Carcinoma

Salmeh Kalbassi<sup>1</sup>, Lida Radfar<sup>2</sup>, Mohammadreza Azimi<sup>3</sup>, Simin Shadanpoor<sup>4</sup>, Ali Ghorbani Ranjbary<sup>5\*</sup>

### Abstract

**Introduction:** Lichen planus (LP) is a relatively common chronic mucocutaneous disease that affects the skin and mucous membranes, including oral mucosa. The etiology of the disease is unknown. Some evidence suggests that the immune system and inflammation may play a role in the formation and progression of lichen planus. Some authorities believe that LP is a precancerous condition. The purpose of this study was to investigate the serum levels of the inflammatory cytokines CRP, IL-1, IL-6, and TNF- $\alpha$  in patients with oral lichen planus and oral squamous cell carcinoma (OSCC), as well as to assess the relationship between these cytokine levels and clinical symptoms. **Methods:** A total of 75 subjects, with 25 in each group of oral lichen planus, healthy control, and oral squamous cell carcinoma, participated in this cross-sectional study. Serum levels of IL-1 $\alpha$ , TNF- $\alpha$ , IL-6, and CRP were determined and compared. In comparison to the healthy control group, the lichen planus and oral squamous cell carcinoma groups had higher levels of CRP, IL-1 $\alpha$ , IL-6, and TNF- $\alpha$ . **Results:** We discovered that the mean mRNA and protein levels of CRP, IL-1 $\alpha$ , IL-6, and TNF- $\alpha$  were significantly higher in the blood and tissue of lichen planus and OSCC patients than in normal controls. **Conclusion:** Higher levels of CRP, IL-1 $\alpha$ , IL-6, and TNF- $\alpha$  may be linked to OLP and oral carcinogenesis. More research with larger groups is required.

**Keywords:** Oral lichen planus- oral squamous cell carcinoma- serum cytokines- CRP- TNF- $\alpha$

*Asian Pac J Cancer Prev*, 23 (11), 3843-3849

### Introduction

Lichen planus (LP) is a relatively common chronic mucocutaneous disease that affects mostly the middle-aged adult population. The worldwide estimated prevalence of Oral LP (OLP) ranges from 0.22 to 5%, with a reported incidence of 2.2% (Rosa et al., 2015; Danielsson et al., 2018; Razmara et al., 2020). Oral lichen planus is slightly more common in females (Rosa et al., 2015; DeRossi et al., 2005), with an average age of 55 years at diagnosis (Razmara et al., 2020). There is no particular racial predilection for this disease (Danielsson et al., 2018). Oral LP lesions have been reported in about 50-70% of patients with cutaneous lichen planus, but nearly 23% of patients have only oral lesions, and 15-28% of patients have both skin and oral lesions concomitantly (DeRossi et al., 2005; Cheng et al., 2016). In contrast to dermal LP, oral mucosal lesions are refractory to treatment (Sharma

et al., 2008). Oral LP has various clinical presentations, including reticular, papular, plaque-like, bullous, atrophic, erythematous, and ulcerative (erosive) lesions (Razmara et al., 2020). The etiology of LP is unknown, but it is known that LP is a T-cell-mediated immunological disease with an unknown antigen (Rosa et al., 2015). Specifically, CD8+ T cells have been present in the basal keratinocytes of the epithelium (Lavanya et al., 2011). Upregulation of inflammatory cytokines associated with a Th1 immune response such as interferon (IFN)- $\gamma$ , tumor necrosis factor (TNF)- $\alpha$ , interleukin (IL)-1 $\alpha$ , and IL-8 is indicative of a possible role of these cytokines in the pathogenesis of LP (Hussein 2007; Chen et al., 2007; Rhodus et al., 2007). Oral LP is considered a premalignant lesion, but the risk of malignant transformation is reported to be 0.2%. Erosive LP is more prone to malignant transformation. In symptomatic patients, regular assessment of the lesions for the probability of malignant transformation is

<sup>1</sup>Specialist in Orthodontics and Dentofacial Orthopedics, Private Clinic in Iran (Tehran, Isfahan), UAE(Dubai), Oman(Muscat).  
<sup>2</sup>Department of Oral Diagnosis and Radiology, University of Oklahoma College of Dentistry, Oklahoma City, OK, USA.  
<sup>3</sup>Department of Biochemistry, Medical Faculty, Saveh Branch, Islamic Azad University, Saveh, Iran. <sup>4</sup>School of Veterinary Medicine, Ferdowsi University of Mashhad, Mashhad, Iran. <sup>5</sup>Department of Pathobiology, Section Biotechnology, Faculty of Veterinary Medicine and Institute of Biotechnology, Ferdowsi University of Mashhad, Mashhad, Iran. \*For Correspondence: ali.ghorbaniranjbary@mail.um.ac.ir

recommended (Cheng et al., 2016).

Squamous cell carcinoma of the head and neck accounts for about 4% of all cancers. Oral cancer, as part of head and neck cancers, is the eleventh most common cancer in the world (Petersen 2003).

Risk factors associated with oral squamous cell carcinoma (OSCC) include tobacco use, alcohol use, Epstein-Barr virus, and human papillomavirus. Several oral lesions are known to be precancerous, including erosive LP, submucosal fibrosis, leukoplakia, and erythroplakia (Yardimci et al., 2014). Precancerous as well as cancer cells are reported to secrete multiple cytokines, including tumor necrosis factor alpha (TNF- $\alpha$ ), IL-1, IL-6, and IL-8. These cytokines, with their local and systemic effects as well as their pro-inflammatory properties, could have a role in the pathogenesis of oral cancers (Chang et al., 2013; Chen et al., 1999).

A number of studies have attempted to show the progression of OLP from its initial stages to OSCC (Brailo et al., 2012; Khandavilli et al., 2009; Fitzpatrick et al., 2014; Fatahzadeh et al., 2004). A recent meta-analysis and systemic review of 16 studies with a total of 7,806 patients with oral LP in 2014 reported malignant transformation to OSCC in 85 patients. The rate of transformation was from 0.4 to 12.5%, with an average of 1.09% (Fitzpatrick et al., 2014). Fatahzadeh et al. reported a case of OSCC arising from OLP. They emphasized the necessity of histological examination and follow-up of patients with lichenoid lesions (Fatahzadeh et al., 2004).

The proinflammatory cytokines in inflammatory conditions have been studied in the serum and saliva in the past. In a study conducted by Brailo et al. in 2006, salivary TNF- $\alpha$  and IL-6 levels were higher in patients with oral leukoplakia when compared to normal control individuals. Later, Brailo et al. (2012) compared serum and salivary concentration levels of IL-1 $\beta$ , IL-6, and TNF- $\alpha$  in patients with oral leukoplakia, oral cancer, and healthy individuals. They found a higher concentration of inflammatory cytokines IL-1 and IL-6 in the saliva of OSCC patients ( $p < 0.05$ ), but no significant level of TNF- $\alpha$  in any of the three groups (Brailo et al., 2012). Sato et al. (2010) reported a higher level of IL-6 in the serum and saliva of patients with OSCC before treatment, and the value returned to the normal level after treatment (Sato et al., 2010). Kaur et al. also measured IL-8, IL-6, and TNF- $\alpha$  levels in saliva and serum in patients with oral leukoplakia, oral lichen planus, and oral submucous fibrosis. Their results showed a high concentration of all cytokine levels (Kaur et al., 2015).

The objectives of this study were to determine the levels of these cytokines in peripheral blood, compare serum levels of CRP, IL-1, IL-6, and TNF- $\alpha$  in OLP, OSCC, and healthy control groups, and evaluate the relationship between these cytokine levels and clinical symptoms.

## Materials and Methods

### Subjects

This analytical, cross-sectional study was carried out in the Central Lab at the Ferdowsi University of Mashad,

City of Mashhad, during 2018-2021. The patients were selected from 3 different ethnic regions in Iran, including Dr. Kalbassi's dental clinics in Tehran and Isfahan, as well as the pathology and oral disease department of the dental faculty of Mashhad University, from 2018 to 2021. All patients signed a written consent form.

The study population included 25 individuals with oral lichen planus, 25 patients with oral cancer, and 25 normal control individuals. All three groups were age and gender matched. Patients with other malignancies, autoimmune diseases, infectious diseases, diabetes, hepatitis, and pregnant women were excluded from the study. Also, all suspicious clinical lesions were assessed by incisional biopsy to confirm OLP and OSCC.

The demographic information and clinical symptoms of the patients were extracted from their charts. Clinical symptoms include burning sensations and pain, irritation, bleeding when brushing teeth, and sensitivity to hot, acidic, or spicy foods.

### ELISA

Serum samples stored at -20 °C and in solid CO<sub>2</sub> at -80 °C, respectively, were used for measurement of CRP, IL-1 $\alpha$ , IL-6, and TNF- $\alpha$ . In order to determine serum levels of CRP, the immunoturbidometric method was applied, and the levels within 0 to 0.6 mg/dl were considered as normal. To assess serum levels of IL-1 and IL-6, a commercially available sandwich ELISA kit with a detection sensitivity of 0.12 ng/ml was used. TNF- $\alpha$  concentrations were also measured with a commercially available sandwich ELISA kit with a sensitivity of 1.56 pg/ml based on the instructions provided by the manufacturer (UCSN Kit, Thermo Fisher Scientific). For data analysis, we used GraphPad Prism software version 8.

### RT-qPCR

Extracted RNA (with kit, Roche Diagnostics, Indianapolis, IN) was purified from blood and tissue samples ( $n=25$  in each group) and reverse transcribed to cDNA using a commercially available cDNA synthesis kit for qPCR assays of C-RP, IL-1, IL-6, and TNF- $\alpha$  mRNA expression (Fermentas, Finland). Exon junction or intron-spanning primers were designed for five pairs of primers (CRP, IL-1 $\alpha$ , IL-6, and TNF- $\alpha$  and  $\beta$ -actin, as the reference genes). The qPCRs for all genes were carried out (in triplicate) with a cycling program including holding for 10 minutes at 95°C, followed by cycling 45 times with 20 seconds each at 94°C melting temperature, 57-60°C annealing temperature, and 72°C extension temperature, accompanied by melting curve analyses and agarose gel electrophoresis to ascertain the specificity of the reactions or the absence of non-specific PCR products (data not shown). Using GenEX Version 6 software (MultiD, Göteborg, Sweden) and the Relative Expression Software Tool (REST; QIAGEN, Hilden, Germany), the normalization and analysis of the qPCR data were calculated accordingly (Azimi et al., 2021).

The designed primers (Beacon Designer v8) were as follows: for IL-1 $\alpha$ , F: 5'-CGCCAATGACTCAGAGGAAGA-3', and R: 5'-AGGGCGTCATTCAGGATGAA-3'; for C-RP,

F: 5'-AGACATGTCGAGGAAGGCTTTT-3', and R: 5'-TCGAGGACAGTTCCTGTAGAA-3'; for TNF- $\alpha$ , F: 5'-CCCAGGCAGTCAGATCATCTTC-3', and R: 5'-AGCTGCCCTCAGCTTGA-3'; for IL6, F: 5'-GGTACATCCTCGACGGCATCT-3', and R: 5'-GTGCCTCTTTGCTGCTTTTAC-3'; for  $\beta$ -actin: F: 5'-CTACCTTCAACTCCATCA-3', and R: 5'-GAGCAATGTCTTGATCTTC-3'.

T-tests and Mann-Whitney tests were conducted to determine whether there was a significant difference between each pair of groups. P-values of less than 0.05 were considered significant.

#### Western blot (WB) analysis

WB analysis for detection of TNF- $\alpha$ , CRP, IL-1 $\alpha$ , and IL-6 was performed as previously described. Briefly, biopsy tissue samples (0.1gm) were lysed in 0.9 ml of lysis buffer [50 mM Tris-HCl (pH 8.0), 150 mM NaCl, 0.5% Nonidet P-40, 0.5% CHAPS], including 0.1% protease inhibitor cocktail III (Calbiochem, San Diego, CA, USA). The tissue lysates were kept on ice for 30 minutes and centrifuged at 16000  $\times$ g for 10 minutes to remove tissue debris. The total protein level of tissue lysates was measured using the bicinchoninic acid assay (BCA) kit (Thermo Scientific). Samples were separated by 12% sodium dodecyl sulfate-polyacrylamide gel electrophoresis (SDS-PAGE) and transferred onto polyvinylidene difluoride membranes (PVDF, Roche, Germany). The membranes were blocked overnight by 5% skimmed milk in TBS 0.1% Tween-20 at 4°C. After incubation of membranes with the primary antibodies (rabbit anti-human TNF- $\alpha$ , CRP, IL-1 $\alpha$ , and IL-6 (Ab; ab6671, ab185558, ab206410, and ab233706 Abcam) and anti- $\beta$ -actin (ab8227) at a dilution of 1:1000 and anti-rabbit HRP-conjugated secondary antibody (Cell signaling technology, USA) at a dilution of 1:5000, visualization was performed using enhanced CL-based

Clarity Western ECL Substrate (Bio-Rad) in combination with an ECL imaging system (Uvitec, Germany). Signals on WB were quantified by Image J 1.42q software (Wayne Rasband, NIH, Bethesda, MA), and the results were eventually normalized to  $\beta$ -actin.

#### Statistical Analyses

All experiments were conducted in duplicate, and the results were expressed as the mean standard error of the mean (SEM) of three independent experiments. The t-test, one-way ANOVA, and Mann-Whitney tests were utilized to analyze the collected data. All analyses were conducted with GraphPad Prism 8.

## Results

#### Demographical

A total of 75 subjects participated in this study. The mean age of the subjects was 43.9 $\pm$ 10.3. The ratio of males to females was 1.5 (Table 1). The location of the lesions with OLP was on the buccal mucosa (n=11), gingiva, and alveolar ridge (n=15), followed by the tongue (n=5), palate (N=1), and upper vestibule (N=1). They were mainly mixed lesions (in 24 patients) of erosive and plaque types, and only four patients had the erosive type solely. In patients with OSCC, most tumors were classified as stage IV based on the TNM classification (tumor size, lymph node involvement, and metastasis) (n=12), followed by stages III, II, and I. The most common locations for OSCC were the tongue, retromolar pad, and floor of the mouth, followed by the soft tissue of the palate, vestibule, and buccal mucosa (Table 1).

#### IL-1 $\alpha$ , TNF- $\alpha$ , IL-6, and CRP levels in blood

One-way analysis of variance showed statistically significant differences in the average concentrations of IL-6, IL-1 $\alpha$ , CRP, and TNF- $\alpha$  among the OLP, OSCC,

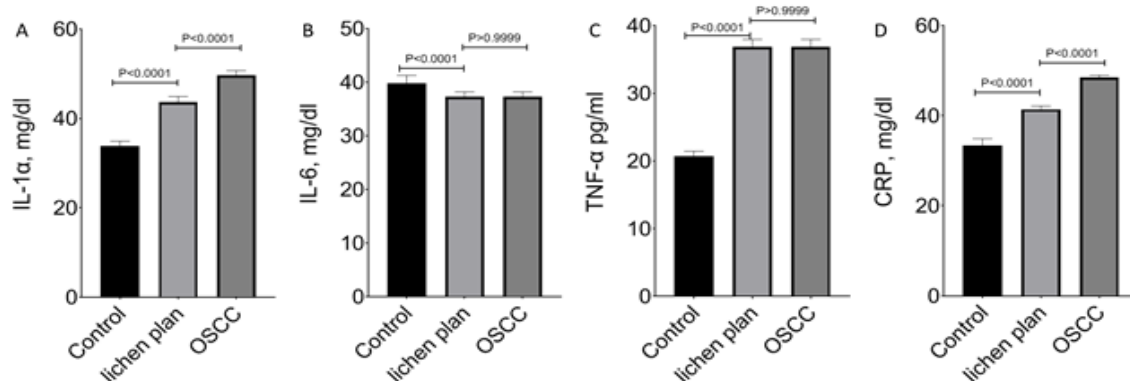


Figure 1. Cytokine (IL1-  $\alpha$ , IL-6, CRP, and TNF-  $\alpha$ ) Levels (Mean  $\pm$  SE) in OLP, OSCC, and Control Groups

Table 1. Demographic Data and the Location of the Lesions in OPL and OSCC.

Subjects	N (M/F)	Age (range)	Location of lesions
OSCC	25 (17/8)	44.5 (26-82)	Tongue, retromolar pad, floor of the mouth palate, vestibule buccal mucosa
OLP	25 (17/8)	44 (25-83)	Buccal, gingiva, alveolar mucosa, tongue, vestibule
Control	25 (17/8)	43.5 (25-81)	-
Total	75 (51/24)	44 (25-82)	-

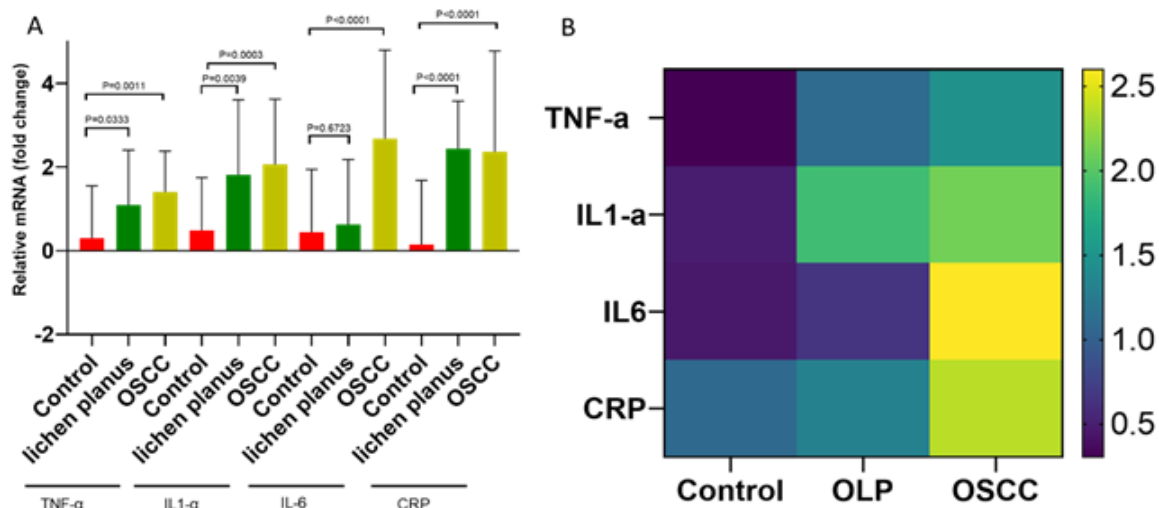


Figure 2 A & B. Correlation between the mRNA (CRP, IL-1α, IL-6, and TNF-α) Levels of Control, Lichen Planus and OSCC.

and control groups. Mann-Whitney Tests were performed in order to compare dual groups statistically. The results revealed that in those with OSCC, the average levels of IL-1α, TNF-α, CRP, and IL-6 were significantly higher than in the control group. A statistical comparison of the group with OLP revealed that a significant increase was only observed in IL-6 serum levels. TNF-α differed statistically significantly (P-value < 0.005) in all three groups (Figure 1).

*qPCR trends*

The results of globally comparative whole blood qPCR assays for CRP, IL-1α, IL-6, and TNF-α and related heat-map analyses (shown in Figures 2 A and B), revealed that CRP, IL-1α and TNF-α mRNA levels were higher in both the Lichen planus and OSCC groups when compared to controls. In contrast, IL-6 mRNA levels were only elevated in the OSCC group (Figure 2 A, P<0.001).

Clinical symptoms in both the OSCC and OLP groups included burning sensation/pain, irritation, bleeding with

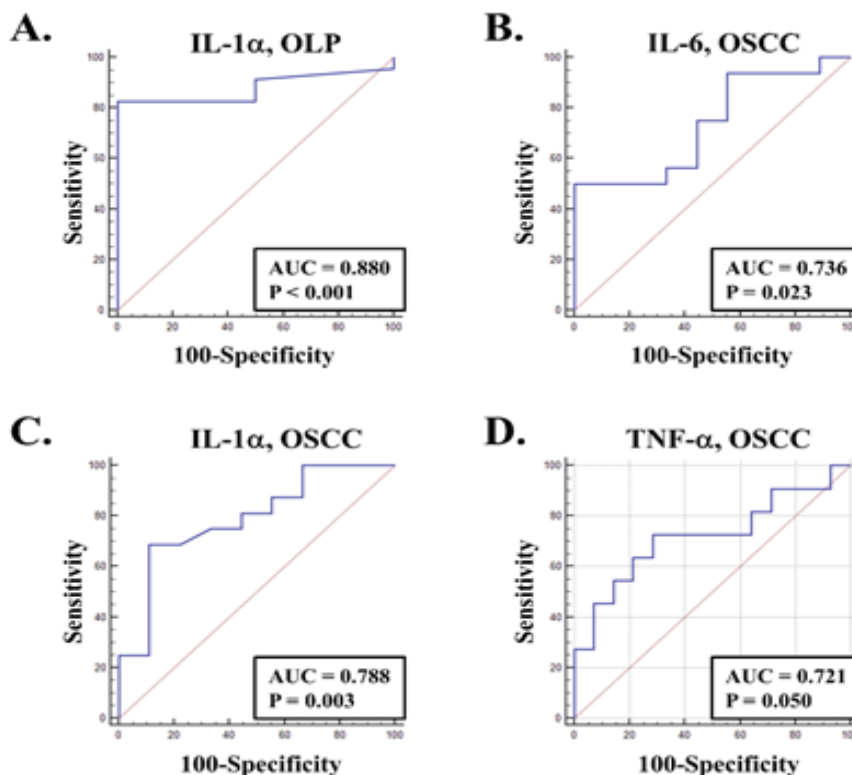


Figure 3. ROC Curve Analysis Showing the Correlation between Different LP and OSCC Symptoms and Cytokines. A, correlation between burning sensation and pain and IL-1 level in LP patients (p < 0.001). B, correlation between sensitivity to hot, acidic or spicy foods and IL-6 level in OSCC patient (p < 0.023). C, correlation between sensitivity to hot, acidic or spicy foods and IL-1α level in OSCC patient (p < 0.003). D, correlation between irritation and bleeding when brushing teeth and TNF-α level in OSCC patient (p < 0.05).



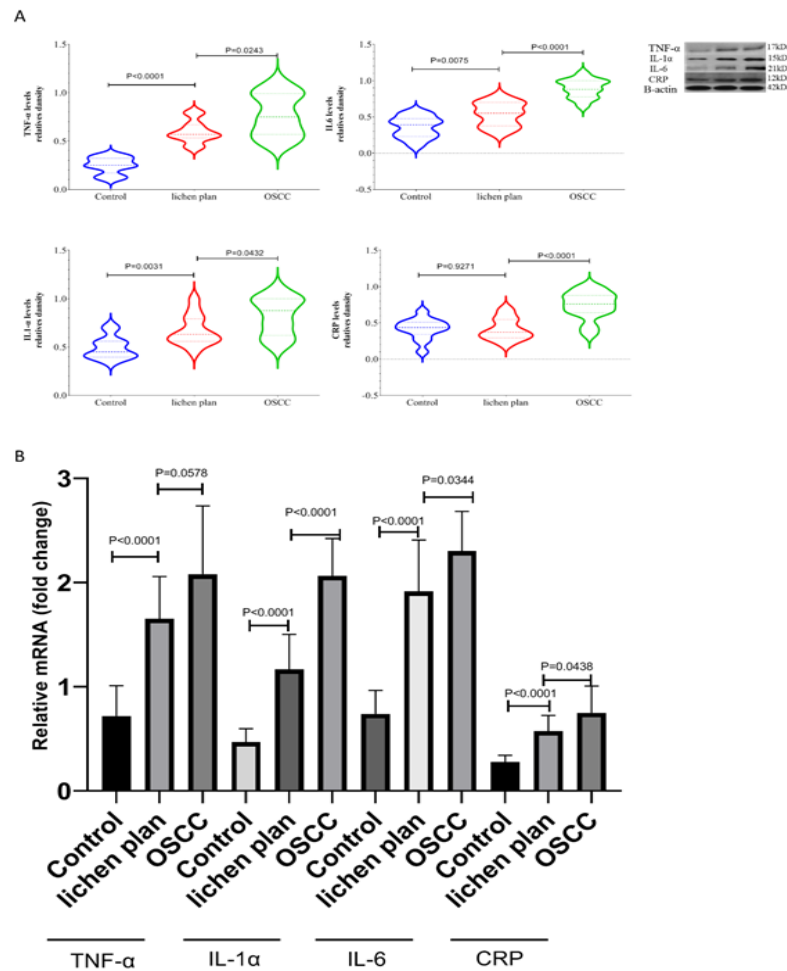


Figure 4. Comparative Western Blotting Results of TNF, IL-1, IL-6, CRP Protein, and mRNA Levels in Control, Lichen Planus, and OSCC (n=25, with Various p-values done with t-test). A, protein levels; B, mRNA level.

tooth brushing, and sensitivity to hot, acidic, or spicy foods. In patients with OLP, only serum IL-1 $\alpha$  levels correlated with burning sensation/pain (ROC curve analysis,  $p<0.001$ ) (Figure 3A). TNF- $\alpha$  levels were correlated with bleeding and irritation when brushing teeth in OSCC patients (ROC curve analysis,  $p=0.050$ ) (Figure 3D), whereas IL-6 and IL-1 levels were correlated with sensitivity to hot, acidic, or spicy foods (ROC curve analysis,  $p=0.023$ ,  $p=0.003$  respectively) (Figure 3B and 3C).

#### IL-1 $\alpha$ , TNF- $\alpha$ , IL-6, and CRP levels in tissues

OSCC tumor tissue had significantly higher mRNA and protein levels of IL-1 $\alpha$ , TNF- $\alpha$ , IL-6, and CRP than OLP ( $P<0.0001$ ). Also, the levels of IL-1 $\alpha$ , TNF- $\alpha$ , IL-6, and CRP were higher in mRNA and protein levels in OLP than in control tissue (Figure 4 A and B).

## Discussion

The results of this study revealed that the average levels of IL-1 $\alpha$ , IL-6, CRP, and TNF- $\alpha$  in patients with OSCC were increased compared to the OLP and control groups. However, only CRP and IL-1 $\alpha$  levels showed statistical significance in all three groups.

Previous studies have shown that increased IL-6 levels cause CRP production in the liver and a corresponding

rise in blood (Balkwill and Mantovani, 2001). The IL-6 cytokine activates a wide range of messaging pathways such as NF- $\kappa$ B and the JNK, ERK, and p38 MAP kinase pathways in tumor tissues, ultimately leading to endothelial cell stimulation, angiogenesis, and developing tumor growth. A rise in CRP in tumor tissue is known to be related to increased IL-6 levels (Robak et al., 1998). In our study, increased IL-6 levels were selectively associated with the presence of tumor tissue in the oral cavity. Although CRP levels were elevated in both the OSCC and OLP groups compared to healthy controls, patients with OLP had lower levels than those with OSCC.

Previous studies showed that this cytokine increases in inflamed tissue of lichen planus lesions, which in turn stimulates inflammatory cells such as lymphocytes and macrophages that further promote the production of this cytokine (Bhol et al., 2000). These results are in accordance with the findings in our present study.

The importance of the cytokines CRP and IL6 has also been linked to tumor size, staging, grading, and cancer prognosis (Khandavilli et al., 2009). In a study of 74 patients with colorectal cancer, Nikiteas et al. found that the average serum levels of CRP, IL-6, and TNF- $\alpha$  were higher than in normal individuals, and the increased levels were associated with tumor size. In addition, higher levels of IL6 and CRP were inversely associated with the patient's survival. The study showed that the

pre-surgery CRP level is decisive in the final diagnosis and determining patient prognosis (Nikiteas et al., 2005). In 2009, Khandavilli et al. investigated the relationship between pre-surgery CRP serum levels, characteristics of clinical pathology, and patients' prognosis. The study revealed a correlation between pre-surgery CRP elevation, tumor size, and tumor stage, and a decline in overall survival (Khandavilli et al., 2009).

In 1963, Rudolf Virchow was the first to propose that chronic inflammation may have a role in carcinogenesis (Balkwill and Mantovani, 2001). Chronic inflammation has been proposed as a pathological response in the host, influencing cell homeostasis and some metabolic pathways, including at the genomic level (Vallée and Lecarpentier, 2017). Tumor-associated macrophages and T lymphocytes are the main sources of cytokine production. T cells release cytokines such as IL-1, IL-6, TNF- $\alpha$ , and others, while macrophages release enzymes and mediators that affect angiogenesis, cell proliferation, and metastasis [Allavena et al., 2008; Grivennikov et al., 2010].

In OLP, which is a mucocutaneous chronic inflammatory disease, cytokines (IL-1, -2, -4, -5, -6, -8, and -10) are involved in pathogenesis. Monocytes, macrophages, keratinocytes, and endothelial cells are shown to be the sources of the cytokines in OLP (Allavena et al., 2008). We found a link between clinical symptoms and IL-1 $\alpha$ , IL-6, and TNF- $\alpha$  in OSCC patients and IL-1 $\alpha$  in LP patients (Figure 2, 3, 4, and 5). IL-1 $\alpha$ , which is a highly inflammatory cytokine and can upregulate host defenses and act as an immuno-adjuvant, was the only cytokine associated with clinical symptoms in both LP and OSCC.

Studies have indicated that pro-inflammatory cytokine levels are increased in inflammatory conditions. Some literature questions the possibility of using these cytokines as biomarkers for oral precancerous and cancerous lesions. We need more studies to answer this question. Higher salivary and serum levels of inflammatory cytokines such as IL-6 and TNF- $\alpha$  and may be used as potential clinical diagnostic markers in precancerous lesions such as oral leukoplakia, oral lichen planus, and oral submucosal fibrosis (Brailo et al., 2006; Sato et al., 2010; Kaur et al., 2015). Lichen planus has the potential for malignant transformation. For this inflammatory disease, it is important to explore possible risk factors, follow the patients, and perform histopathological examinations as needed. Developing diagnostic markers will help risk assessment of OLP and other premalignant oral lesions, guiding clinicians to take appropriate measures to prevent malignant transformation.

In conclusion, understanding the biological characteristics and development of biological markers in precancerous lesions such as OLP can aid in the prognostic assessment of these lesions. Our study indicated a significant increase in cytokine levels (protein and mRNA) in precancerous and OSCC patients. Cytokine levels as a diagnostic biomarker could be useful, but more research is needed. The association between different cytokines, lichen planus, and oral cavity cancer has been identified. The present study's results confirm the cytokines (CRP, IL-1 $\alpha$ , IL-6, and TNF- $\alpha$ ) involved in the pathogenesis of lichen planus and cancer. Further analysis

with larger groups is warranted.

## Author Contribution Statement

Salmeh Kalbassi, Lida Radfar, and Ali Ghorbani Ranjbar performed the experiments, conceived and designed the study, and wrote, analyzed, funded, and critically revised the manuscript. Mohammadreza Azimi and Simin Shadanpoor also actively helped in the experiments and participated in study design, study implementation, and manuscript revision.

## Acknowledgements

The authors thank Dr. Reza Rastegar University of Tehran Laboratory, Saveh Branch, Islamic Azad University and Ferdowsi University of Mashhad Central Laboratory for their cooperation.

### Ethical Approval

The Ethics Committee approved this study at the Saveh Branch, Islamic Azad University, Iran.

### Data Availability

The datasets generated and/or analyzed during the current study are available upon reasonable request from the corresponding author.

### Conflicts of Interest

The authors declare that they have no conflicts of interest.

## References

- Allavena P, Garlanda C, Borrello MG, Sica A, Mantovani A (2008). Pathways connecting inflammation and cancer. *Curr Opin Genet Dev*, **18**, 3-10.
- Azimi M, Mehrzad J, Ahmadi A, Ahmadi E, Ghorbani Ranjbar A (2021). Apoptosis induced by Ziziphora tenuior essential oil in human colorectal cancer cells. *Biomed Res Int*, **2021**, 5522964.
- Balkwill F, Mantovani A (2001). Inflammation and cancer: back to Virchow?. *Lancet*, **57**, 539-45.
- Brailo V, Vucićević-Boras V, Cekić-Arambasin A, et al (2006). The significance of salivary interleukin 6 and tumor necrosis factor alpha in patients with oral leukoplakia. *Oral Oncol*, **42**, 370-3.
- Brailo V, Vucicevic-Boras V, Lukac J, et al (2012). Salivary and serum interleukin 1 beta, interleukin 6 and tumor necrosis factor alpha in patients with leukoplakia and oral cancer. *Med Oral Patol Oral Cir Bucal*, **17**, e10-5.
- Bhol KC, Rojas AI, Khan IU, Ahmed AR (2000) Presence of interleukin 10 in the serum and blister fluid of patients with pemphigus vulgaris and pemphigoid. *Cytokine*, **12**, 1076-83.
- Chang KP, Kao HK, Wu CC, et al (2013). Pretreatment interleukin-6 serum levels are associated with patient survival for oral cavity squamous cell carcinoma. *Otolaryngol Head Neck Surg*, **148**, 786-91.
- Chen Z, Malhotra PS, Thomas GR, et al (1999). Expression of proinflammatory and proangiogenic cytokines in patients with head and neck cancer. *Clin Cancer Res*, **5**, 1369-79.
- Chen X, Liu Z, Yue Q (2007). The expression of TNF- $\alpha$  and ICAM-1 in lesions of lichen planus and its implication. *J Huazhong Univ Sci Technol Med Sci*, **27**,

739-41.

- Cheng YS, Gould A, Kurago Z, Fantasia J, Muller S (2016) Diagnosis of oral lichen planus: a position paper of the American Academy of Oral and Maxillofacial Pathology. *Oral Surg Oral Med Oral Pathol Oral Radiol*, **122**, 332-54.
- Danielsson K, Nylander E, Sjöström M, Ebrahimi M (2018). Epstein-Barr virus is not detected in mucosal lichen planus. *Med Oral Patol Oral Cir Bucal*, **23**, 560-3.
- DeRossi SS, Ciarrocca KN (2005). Lichen planus, lichenoid drug reactions, and lichenoid mucositis. *Dent Clin North Am*, **49**, 77-89.
- Fitzpatrick SG, Hirsch SA, Gordon SC (2014). The malignant transformation of oral lichen planus and oral lichenoid lesions: a systematic review. *J Am Dent Assoc*, **145**, 45-56.
- Fatahzadeh M, Rinaggio J, Chiodo T (2004). Squamous cell carcinoma arising in an oral lichenoid lesion. *J Am Dent Assoc*, **135**, 754-9.
- Grivennikov SI, Greten FR, Karin M (2010). Immunity, inflammation, and cancer. *Cell*, **140**, 883-99.
- Hussein MR (2007). Evaluation of angiogenesis in normal and lichen planus skin by CD34 protein immunohistochemistry: preliminary findings. *Cell Biol Int*, **31**, 1292-5.
- Kaur J, Jacobs R (2015). Proinflammatory cytokine levels in oral lichen planus, oral leukoplakia, and oral submucous fibrosis. *J Korean Assoc Oral Maxillofac Surg*, **41**, 171-5.
- Khandavilli SD, Ceallaigh PO, Lloyd CJ, Whitaker R (2009). Serum C-reactive protein as a prognostic indicator in patients with oral squamous cell carcinoma. *Oral Oncol*, **45**, 912-4.
- Lavanya N, Jayanthi P, Rao UK, Ranganathan K (2011). Oral lichen planus: An update on pathogenesis and treatment. *J Oral Maxillofac Pathol*, **15**, 127-32.
- Nikiteas NI, Tzanakis N, Gazouli M, et al (2005). Serum IL-6, TNF $\alpha$  and CRP levels in Greek colorectal cancer patients: prognostic implications. *World J Gastroenterol*, **11**, 1639-43.
- Petersen PE, (2003). The World Oral Health Report 2003: continuous improvement of oral health in the 21st century- the approach of the WHO Global Oral Health Programme. *Community Dent Oral Epidemiol*, **31**, 3-23.
- Razmara F, Khayamzadeh M, Shabankare G (2020). Applying dental implant therapy in patients with oral lichen planus: a review of literature. *Int J Implant Dent*. **6**, 21.
- Rhodus NL, Cheng B, Ondrey F (2007). Th1/Th2 cytokine ratio in tissue transudates from patients with oral lichen planus. *Mediators Inflamm*, **2007**, 19854.
- Rosa EA, Lia EN, Macedo SB, Amorim RF (2015) In situ carcinoma developed over oral lichen planus: a case report with analysis of BUB3, p16, p53, Ki67 and SOX4 expression. *J Appl Oral Sci*, **23**, 442-7.
- Sato J, Goto J, Murata T (2010). Changes in saliva interleukin-6 levels in patients with oral squamous cell carcinoma. *Oral Surg Oral Med Oral Pathol Oral Radiol Endod*, **110**, 330-6.
- Sharma S, Saimbi CS, Koirala B (2008) Erosive oral lichen planus and its management: a case series. *JNMA J Nepal Med Assoc*, **47**, 86-90.
- Vallée A, Lecarpentier Y (2018) Crosstalk between peroxisome proliferator-activated receptor gamma and the canonical WNT/ $\beta$ -Catenin pathway in chronic inflammation and oxidative stress during carcinogenesis. *Front Immunol*, **9**, 745.
- Yardimci G, Kutlubay Z, Engin B, Tuzun Y (2014) Precancerous lesions of oral mucosa. *World J Clin Cases*, **2**, 866-72.



This work is licensed under a Creative Commons Attribution-Non Commercial 4.0 International License.