

Endovascular treatment of refractory iatrogenic femoral artery pseudoaneurysm using Amplatzer vascular plugs following unsuccessful retrograde Angio-Seal deployment

Eu Jhin Loh, Robert Allen¹

Department of General Surgery, Calvary Mater Hospital, Waratah, NSW, ¹Department of Medical Imaging, The Canberra Hospital, Garran, ACT, Australia

Correspondence: Dr. Eu Jhin Loh, Department of General Surgery, Calvary Mater Newcastle, Edith Street and Platt Street, Waratah 2298, NSW, Australia. E-mail: eu.j.loh@gmail.com

Abstract

Iatrogenic common femoral artery pseudoaneurysm is a well-known vascular access complication of angiography and transfemoral intervention. Thrombin injection is a well-accepted technique in treating these pseudoaneurysms but possess a significant risk of distal lower extremity thrombosis leading to severe consequences. Several case reports described the novel approach to closing these pseudoaneurysms via a retrograde deployment of an Angio-Seal vascular closure device. We describe a case of a successful treatment of refractory iatrogenic femoral artery pseudoaneurysm using Amplatzer vascular plugs following unsuccessful retrograde deployment of an Angio-Seal vascular closure device.

Key words: Amplatzer; Angio-Seal; common femoral artery; iatrogenic; pseudoaneurysm

Introduction

Femoral artery pseudoaneurysm is a well-known complication of angiography and transfemoral interventions, particularly with low punctures, with a reported incidence of between 0.2 and 7%.^[1] It is postulated that the formation of these pseudoaneurysms are related to the severe calcification of these arteries preventing vessel wall healing post cannulation.^[2]

Direct thrombin injection is a widely accepted and generally a safe method of treating these pseudoaneurysms in a minimally invasive fashion. However, several fatal complications have been reported, with a failure rate of between 4 and 9%.^[3] The risk of microembolization is directly related to the length of the channel between artery and pseudoaneurysm.^[4]

The other proposed methods of treating these pseudoaneurysms include ultrasound-guided

Videos Available on: www.ijri.org

Access this article online

Quick Response Code:



Website:
www.ijri.org

DOI:
10.4103/ijri.IJRI_332_18

This is an open access journal, and articles are distributed under the terms of the Creative Commons Attribution-NonCommercial-ShareAlike 4.0 License, which allows others to remix, tweak, and build upon the work non-commercially, as long as appropriate credit is given and the new creations are licensed under the identical terms.

For reprints contact: reprints@medknow.com

Cite this article as: Loh EJ, Allen R. Endovascular treatment of refractory iatrogenic femoral artery pseudoaneurysm using Amplatzer vascular plugs following unsuccessful retrograde Angio-Seal deployment. *Indian J Radiol Imaging* 2019;29:211-4.

compression,^[5] selective embolization of the neck with *n*-butyl cyanoacrylate^[6] or coil embolization,^[7] stent grafts deployment,^[8] and surgical repair.^[9] In recent times, there were several case reports^[10-12] describing a novel technique of treating these pseudoaneurysms via retrograde deployment of an Angio-Seal vascular closure device with considerable success and safety.

In this report, we present a case of a femoral pseudoaneurysm repair using Amplatzer vascular plugs following several unsuccessful attempts of retrograde approach through the neck of the pseudoaneurysm via wire capture technique and deployment of Angio-Seal (St Jude Medical, St Paul, MN, USA) vascular closure device.

Case Report

A 65-year-old man with a background of sarcoidosis presented with an acute myocardial infarction and underwent emergency percutaneous coronary intervention and revascularization of his left anterior descending artery with an 8-Fr sheath access of the right common femoral artery. The patient was anticoagulated with unfractionated heparin during the procedure. The intervention went uneventfully and the arteriotomy site was closed with an Angio-Seal vascular closure device. The patient recovered well and was discharged after 2 days and was commenced on dual antiplatelet therapy.

One week following his cardiac intervention, he was noted to have a pulsatile mass in his right groin with an associated bruit. He underwent a Duplex arterial ultrasound scan, which showed a bilobed pseudoaneurysm (superficial aneurysm measures 20 mm in transverse diameter with a shallow neck 0.8 mm; deep aneurysm measures 12 mm in transverse diameter which extends off a 6 mm neck) arising just lateral to the femoral artery puncture site [Figure 1A].

He went on to have an ultrasound-guided percutaneous injection of the pseudoaneurysm with thrombin. The procedure proved to be extremely challenging due to rapid blood flow and the wide pseudoaneurysm neck (6 mm). Following 10 min of direct sonographic probe pressure, complete occlusion of the superficial pseudoaneurysm was observed but a small residual fleck of flow on power Doppler was evident to suggest an incomplete occlusion of the deep component of the pseudoaneurysm [Figure 1B]. This was confirmed on repeat Duplex ultrasound scan the following day [Figure 1C].

The patient refused surgical repair and was offered a novel approach using an Angio-Seal vascular closure device. Informed consent was obtained from the patient for the "off-label" use of this device. A 6-Fr contralateral sheath was positioned in the distal right external iliac artery from the left common femoral artery and angiography

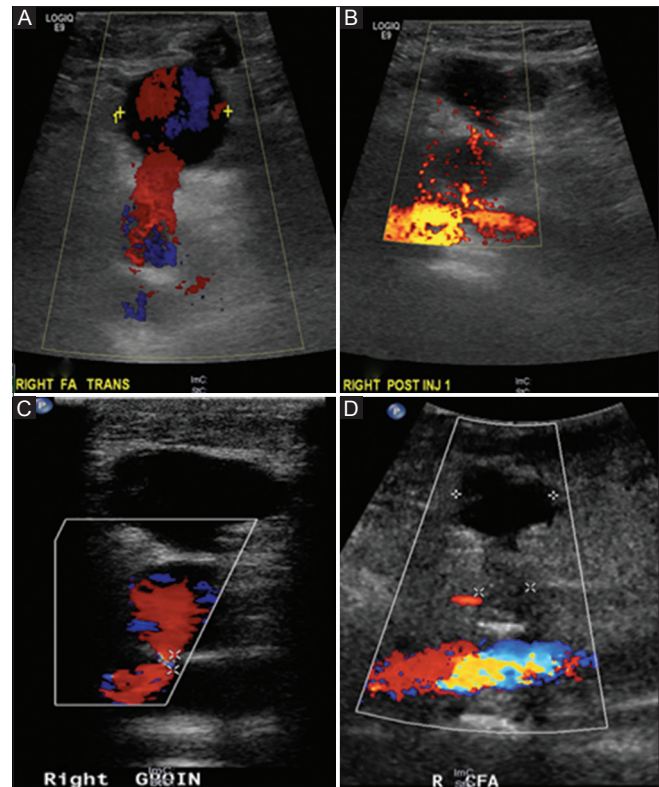


Figure 1 (A-D): (A) Bilobed pseudoaneurysm arising from the right common femoral artery seen on Duplex ultrasound. (B) Ultrasound-guided thrombin injection with successful sealing of the superficial component of the pseudoaneurysm. (C) Demonstration of persistent flow in the deep component of the pseudoaneurysm on Duplex ultrasound; (D) Successful embolization with no flow within the pseudoaneurysm post Amplatzer plug deployment

was performed which demonstrated the pseudoaneurysm arising from the anterolateral aspect of the right common femoral artery [Figure 2A]. Percutaneous right access of pseudoaneurysm was achieved using a wire capture technique. The pseudoaneurysm neck was catheterized and the catheter directed anteriorly. A 0.014-inch straight wire was advanced into the wall of the pseudoaneurysm, which acted as a marker to the location of the pseudoaneurysm neck. A parallax was formed via multiple projections based on the straight wire to guide the entry point of the micropuncture needle at the skin surface. An 18G × 15 cm needle was inserted percutaneously, and advanced with rotation in order to engage the straight wire end [Figure 2B]. Following successful wire capture, a 0.014-inch wire was advanced through the 18G needle and a 5-Fr microsheath was inserted over the wire into the right external iliac artery. This allowed a 0.035-inch wire to be advanced through the sheath into the right external iliac artery. An 8-Fr Angio-Seal device was inserted in a retrograde manner ensuring that the polymer anchor is pulled firmly against the neck of the pseudoaneurysm. The toggle of the Angio-Seal device failed to hold at the artery wall. The procedure was repeated with a similar result. It was thought that the wide pseudoaneurysm neck was the reason for the

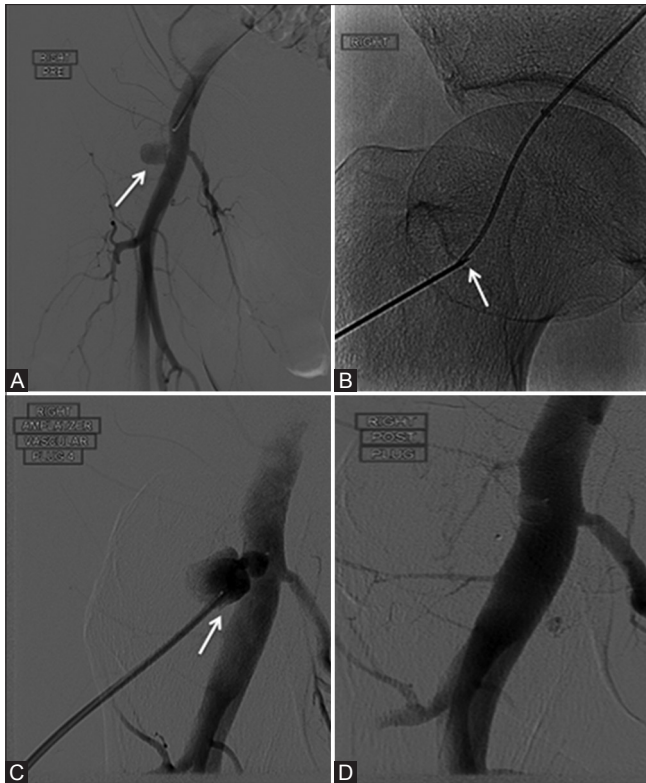


Figure 2 (A-D): (A) Refractory pseudoaneurysm seen on angiography arising from the anterolateral aspect of the right common femoral artery (*white arrow*); (B) Micropuncture needle seen engaged with the end of the straight wire at the pseudoaneurysm neck (*white arrow*); (C) Amplatzer 4 vascular plugs deployed to occlude the pseudoaneurysm (*white arrow*); (D) Post deployment angiogram demonstrated successful closure of the pseudoaneurysm

failure of Angio-Seal deployment. A decision was made to use an Amplatzer 4 (St Jude Medical, St Paul, MN, USA) vascular plug device to occlude the pseudoaneurysm. A 0.038-inch guidewire was advanced via the left common femoral artery access and a 7-Fr sheath was inserted over the wire and advanced to the pseudoaneurysm neck at the right common femoral artery. The Amplatzer 4 vascular plug was deployed successfully [Figure 2C]. Post deployment, angiography demonstrated effective sealing of the right common femoral artery at the level of the vessel wall [Figure 2D]. Repeat of Duplex ultrasound scan the next day demonstrated successful embolization with no flow within the pseudoaneurysm [Figure 1D]. The patient did well with no immediate complications and was discharged home 24 h postprocedure.

Discussion

In this case, we describe the challenges faced in treating a refractory iatrogenic femoral artery pseudoaneurysm using the technological armamentarium available to the endovascular specialist. Thrombin injection is a widely accepted and effective technique of treating pseudoaneurysms with experienced interventionalists.^[3]

However, it does come with significant risk of distal lower limb embolization with serious outcomes.^[4] The Angio-Seal vascular closure device started gaining popularity in 1994 and had become a gamechanger in the closure of arteriotomy sites.^[13] The learning curve in using the Angio-Seal to treat femoral artery pseudoaneurysms can be easily overcome due to the familiarity of this vascular closure device with most endovascular specialist. Robken *et al.*^[10] concluded that the procedure would benefit a specific cohort of patients who have large pseudoaneurysms often measuring >3 mm in size with a neck diameter <5 mm, on anticoagulation or not being able to tolerate direct compression. This case supports the findings of Robken *et al.*,^[10] in which the major limitation of this procedure is that it is less likely to be successful in pseudoaneurysms with necks or orifices measuring >5 mm, because of the inability of the polymer anchor to sit in an orifice of this size. However, using other devices available such as the Amplatzer vascular plug has proven to be a safe and feasible alternative to sealing the pseudoaneurysm.

Conclusion

This report describes the successful endovascular treatment of an iatrogenic refractory femoral artery pseudoaneurysm using an Amplatzer 4 vascular plug, following unsuccessful retrograde deployment of an Angio-Seal vascular closure device via wire capture technique. It is important for the endovascular specialist to identify the right cohort of patients to treat using this novel technique and to consider all technological armamentarium available when technical difficulties are encountered. Allen R, Pseudoaneurysm repair using Amplatzer vascular plug [Videos 1-7].

Declaration of patient consent

The authors certify that they have obtained all appropriate patient consent forms. In the form the patient(s) has/have given his/her/their consent for his/her/their images and other clinical information to be reported in the journal. The patients understand that their names and initials will not be published and due efforts will be made to conceal their identity, but anonymity cannot be guaranteed.

Financial support and sponsorship

Nil.

Conflicts of interest

We have no conflicts of interest to declare.

References

1. Knight CG, Healy DA, Thomas RL. Femoral artery pseudoaneurysms: Risk factors, prevalence, and treatment options. *Ann Vasc Surg* 2003;17:503-8.
2. Imsand, Hayoz. Current treatment options of femoral pseudoaneurysms. *Vasa* 2007;36:91-5.
3. Gabrielli R, Rosati MS, Vitale S, Millarelli M, Chiappa R, Siani A, *et al.* Fatal complication after thrombin injection for

- post-catheterization femoral pseudoaneurysm. *Thorac Cardiovasc Surg* 2011;59:372-5.
4. Luedde M, Krumsdorf U, Zehelein J, Ivandic B, Dengler T, Katus HA, *et al.* Treatment of iatrogenic femoral pseudoaneurysm by ultrasound-guided compression therapy and thrombin injection. *Angiology* 2007;58:435-9.
 5. Huang TL, Liang HL, Huang JS, Yang TL, Chen YJ, Huang PY, *et al.* Ultrasound-guided compression repair of peripheral artery pseudoaneurysm: 8 years' experience of a single institute. *J Chin Med Assoc* 2012;75:468-73.
 6. Nakai M, Sato M, Sanda H, Ikoma A, Kawai N, Minamiguchi H, *et al.* Percutaneous fluoroscopically guided n-butyl cyanoacrylate (NBCA) injection for iatrogenic femoral arterial pseudoaneurysm under temporary balloon occlusion of arterial blood flow. *Jpn J Radiol* 2012;30:365-9.
 7. Waldherr, Kickuth, Ludwig, Do, Triller. Superselective embolization of deep femoral artery branch pseudoaneurysm with a coaxial microcatheter system. *Vasa* 2006;35:45-9.
 8. Orimoto Y, van Keulen JW, Waasdorp EJ, Moll FL, van Herwaarden JA. Treatment of a recurrent false aneurysm of the femoral artery by stent-graft placement from the brachial artery. *Ann Vasc Surg* 2011;25:841.e1-4.
 9. Borioni R, Garofalo M, De Paulis R, Albano P, Caprara E, Fratticci L, Chiariello L. Surgical treatment of femoral artery pseudoaneurysms after cardiac catheterization. *Minerva Chir* 2008;63:277-82.
 10. Robken J, Shammas NW. Novel technique to treat common femoral artery pseudoaneurysm using Angio-Seal closure device. *Int J Angiol* 2016;25:266-70.
 11. Xiang DC, Hillegass WB, Luo GX, He JX. Treatment of refractory iatrogenic femoral artery pseudoaneurysm with a vascular closure device. *J Vasc Interv Radiol* 2009;20:1639-40.
 12. Hadziomerovic A, Jetty P, Gupta A. Angioseal-assisted closure of iatrogenic refractory femoral arterial pseudoaneurysm. *JACC: Cardiovasc Interv* 2016;9:e55-7.
 13. Resnic FS, Arora N, Matheny M, Reynolds MR. A cost-minimization analysis of the Angio-Seal vascular closure device following percutaneous coronary intervention. *Am J Cardiol* 2007;99:766-70.