



Thermal Ablation for Renal Cell Carcinoma: Expert Consensus from the Asian Conference on Tumor Ablation

Byung Kwan Park¹, Shu-Huei Shen², Masashi Fujimori³, Yi Wang⁴

¹Department of Radiology, Samsung Medical Center, Sungkyunkwan University School of Medicine, Seoul, Korea; ²Department of Radiology, Taipei Veterans General Hospital, Taipei, Taiwan; ³Department of Radiology, Mie University School of Medicine, Tsu, Japan; ⁴Department of Urology, Peking University Wujieping Urology Center, Peking University Shougang Hospital, Beijing, China

INTRODUCTION

Incidental detection of renal cell carcinoma (RCC) has become more frequent in patients who undergo ultrasound (US), computed tomography (CT), and magnetic resonance imaging (MRI) for unrelated reasons. Since 2000, thermal ablation has become more widely available in clinical practice. Recently, radiofrequency ablation (RFA), cryoablation, and microwave ablation (MWA) have become the main thermal ablation modalities. However, experts' consensus for Asian patients with renal tumors has not been established, although the Asian Conference of Tumor Ablation (ACTA) has been held for many years. A total of four Asian doctors, who were selected from Korea, Taiwan, Japan, and China, participated in gathering their experience on thermal ablation of RCC to draw an ACTA expert consensus for the treatment of Asian patients with RCC.

Consideration before Thermal Ablation

Indications to Thermal Ablations

Despite the lack of strong evidence, the American and European Urologic Associations recommend thermal

ablation as a primary treatment option for patients with RCC who cannot undergo surgery because of the high risk of postoperative morbidity [1,2]. These conditions include poor cardiopulmonary function, chronic kidney disease, bleeding tendency, coagulopathy, and other severe comorbidities. Furthermore, thermal ablation can be a good alternative treatment option for hereditary [3,4], single kidney [5-7], central [8-10], and recurrent [11-13] RCCs following surgery or thermal ablation. Prior to thermal ablation, fever should be detected and controlled. Platelet count should be more than 50000/ μ L and the internationalized normalized ratio should be maintained at less than 1.5 [14].

Pre-Ablation Imaging: Advantage, Disadvantage, and Preference

The advantage of pre-ablation imaging is to perform pre-ablation plans, such as characterizing or localizing the renal mass, and determining how to approach/prevent complications [15,16]. The disadvantages are increased medical costs and radiation exposure to patients [17,18]. CT is preferred over MRI because of its shorter scan time, lower medical cost, fewer imaging artifacts, and greater availability [15,16,19]. Generally, US cannot replace CT or MRI because it is not sufficient to perform pre-ablation plans.

Preparations for Thermal Ablations

Patients must fast for 6–8 hours prior to thermal ablation. Otherwise, aspiration may occur when patients vomit during the ablation procedure. Urethra catheterization is useful for predicting the amount of urine produced or detecting gross hematuria. Antibiotic treatment is not mandatory if aseptic techniques are performed.

Received: May 28, 2020 **Revised:** March 16, 2021

Accepted: March 19, 2021

Corresponding author: Byung Kwan Park, MD, Department of Radiology, Samsung Medical Center, Sungkyunkwan University School of Medicine, 81 Irwon-ro, Gangnam-gu, Seoul 06351, Korea.

• E-mail: 1436park@gmail.com

This is an Open Access article distributed under the terms of the Creative Commons Attribution Non-Commercial License (<https://creativecommons.org/licenses/by-nc/4.0>) which permits unrestricted non-commercial use, distribution, and reproduction in any medium, provided the original work is properly cited.

Types of Anesthesia

Local anesthesia is frequently performed during cryoablation because most patients tolerate pain [20]. General anesthesia is useful during RFA or MWA because pain is more severe in these procedures [21,22]. However, the type of anesthesia should be chosen based on the clinical situation.

Percutaneous versus Laparoscopic Approaches

The percutaneous approach is less invasive than the laparoscopic approach because of a smaller amount of bleeding or lack of a skin scar (Figs. 1, 2). Subsequently, percutaneous thermal ablation requires a shorter hospital stay than laparoscopic thermal ablation [23,24]. Laparoscopic thermal ablation can be used to remove as many RCCs as possible in patients with von Hippel-Lindau disease (Fig. 3).

Avoiding Thermal Damage

Ureter catheterization and pyeloperfusion are necessary to reduce thermal damage during thermal ablation for RCC that is close to the ureteropelvic junction [15,25-27]. Hydrodissection is necessary to avoid thermal damage to bowel loops if the RCC-to-bowel distance is < 0.5 cm (Fig. 1) [15,25,28].

Renal Mass Biopsy

Prior to ablation, percutaneous biopsy is mandatory to avoid unnecessary treatment for benign tumors [15,16], including angiomyolipoma and oncocytoma [29,30]. However, knowing the subtypes of RCC or metastasis is useful for further management after thermal ablation.

Choosing Thermal Ablations

The size or location of the RCC influences the choice of thermal ablation due to different oncologic outcomes. If the RCC size is > 3 cm, cryoablation or MWA is useful because these techniques can create a larger ablation area than RFA using a single electrode [31,32]. If an RCC is centrally located or protruding into the renal sinus, cryoablation is more useful for reducing urothelial damage than RFA [9,33,34] or MWA. If an RCC is less than 3 cm, all types of thermal ablations provide acceptable oncologic outcomes.

Choosing Guiding Modalities

CT is preferred to guide an ablation needle because interventional oncologists are familiar with CT-guided

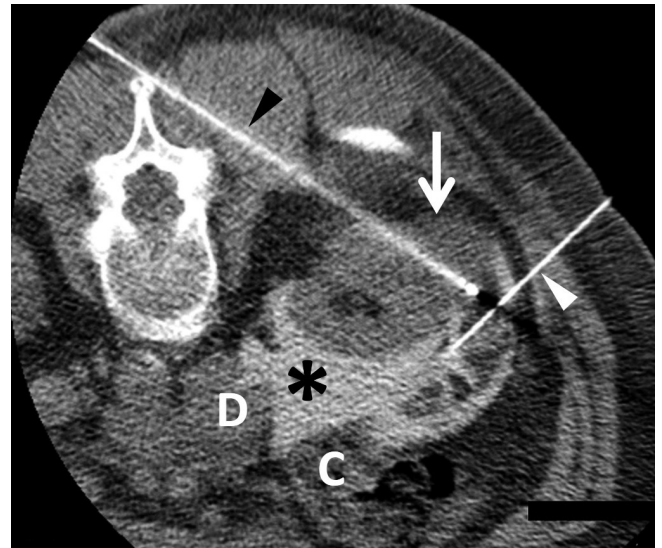


Fig. 1. Percutaneous RFA in a 70-year-old female. Non-contrast axial CT image showing hyperattenuating iodine-containing fluid (asterisk) instilled for hydrodissection through a 22-gauge needle (white arrowhead), leading to the displacement of the colon (C) and duodenum (D) neighboring the renal cell carcinoma. One (black arrowhead) of the three RF electrodes is placed within the tumor (arrow), and RFA is performed using a switching controller. RFA = radiofrequency ablation

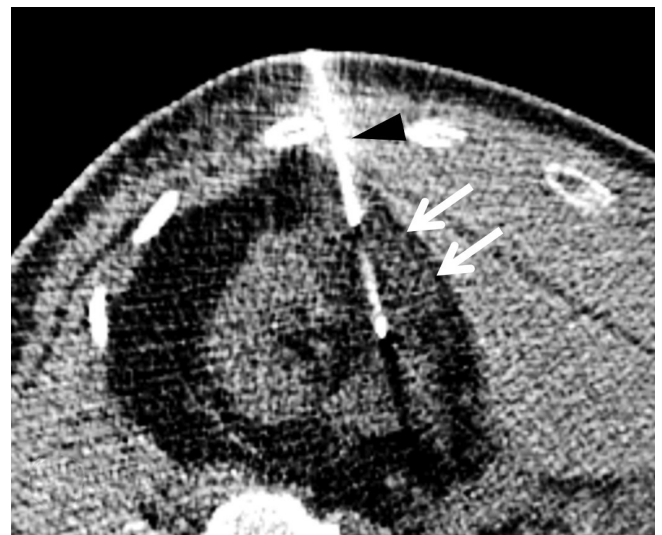

Fig. 2. Percutaneous cryoablation in a 63-year-old male. Non-contrast axial CT image showing one (arrowhead) of two cryo-applicators placed in the right renal cell carcinoma. An ice ball (arrows) was created to ablate the tumor.

procedures (Figs. 1, 2) [15,16]. Furthermore, this imaging modality clearly shows the ablation margin during cryoablation procedures. In contrast, the ablation margins during RFA or MWA are relatively unclear. A high radiation dose is a challenge when CT is used for guidance [19]. The low-dose CT protocol is useful for Asian patients with relatively lower body mass indices [18]. US is a useful

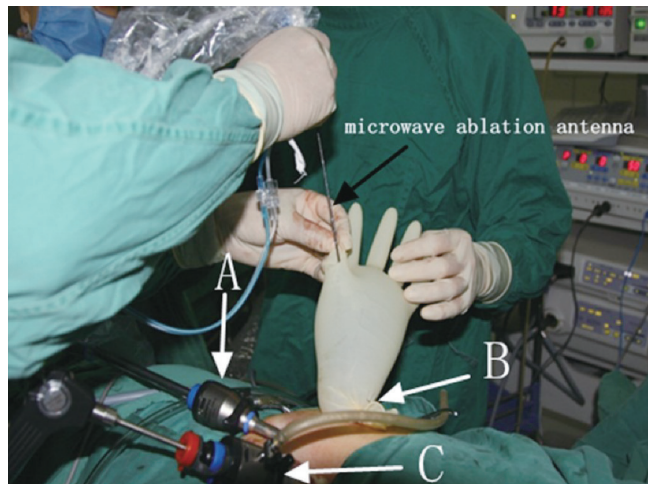


Fig. 3. BLaparoscopic microwave ablation in a 73-year-old male. A, B, and C (white arrows) are the trocars in three different positions. Microwave antenna (black arrow) enters the tumor through the glove and trocar B. Gloves are mainly used to prevent leakage of carbon dioxide gas.

imaging modality for treating exophytic RCC in slim Asian patients [35,36]. However, local tumor progression tends to be more frequent because posterior US shadowing resulting from echogenic ablation area makes it difficult to determine if the tumor margin and RCC are completely ablated [21].

Cystic Renal Mass

Park et al. [37,38] showed that RFA achieves a higher recurrence-free survival rate in patients with Bosniak III or IV cysts, most of which were not proven to be RCC. Cryoablation and MWA have the potential to provide excellent treatment outcomes in treating these cysts [39,40]. The investigations dealing with long-term outcomes of treating cystic renal masses are scarce that the evidence level of recommendation is not high. Therefore, thermal ablation should be performed selectively in patients who cannot undergo surgery.

Influence on Renal Function

Increasing tumor size, endophytic tumor location, increasing number of tumors, and increasing number of sessions are more likely to result in loss of renal function [41]. These conditions increase the volume of the tumor margin to be ablated [41].

Thermal Ablation Modalities

RFA

RFA is the most widely used thermal ablation therapy for

the treatment of solid cancers. RFA utilizes an oscillating electrical current of 375–500 kHz to induce tissue hyperthermia, and a tissue temperature exceeding 60°C can lead to immediate cell death (Fig. 1) [42–45]. Five-year overall survival and cancer-specific survival rates among patients with T1 RCC after RFA were reported to range from 72% to 97% and 96% to 97%, respectively [46–49]. Comparable 5-year overall survival and cancer-specific survival rates have been reported in Asia, ranging from 78% to 90% and 96% to 100%, respectively [50–52]. Hemorrhage is the most frequent complication; however, more than 80% of cases are self-limiting [47,53–55]. Urothelial injury after RFA develops more frequently than cryoablation, and the reported incidence rate ranges from 2% to 10% [47,49,55,56].

Cryoablation

Cryoablation is a minimally invasive technique that causes cell death by freezing (Fig. 2). Cryoablation causes direct cell injury based on two biophysical changes [57]: osmotic dehydration of cells [58] and formation of intracellular ice. A complete cryoablation session consists of a double freeze-thaw cycle with 10–15 minutes of freezing and 8–10 minutes of thawing. For RCCs < 4 cm (T1a), cryoablation offers excellent local control results with a 5-year recurrence-free survival rate of > 90% [17,59,60]. For renal tumors ≥ 4 cm (T1b), cryoablation is also a valid treatment alternative to surgery, although the local recurrence rate is higher than that with surgery [61–64]. The most common complication of cryoablation is bleeding, followed by frozen injury to adjacent vulnerable organs, including ureter stricture, colon perforation or fistula, and nerve injury [17,59,65–67].

MWA

MW energy causes cell death due to the agitation of water molecules (Fig. 3). MWA offers several advantages, including higher intratumoral temperatures, less ablation time, and less dependence on the electrical conductivity of tissue [68–70]. In particular, MWA is useful for treating renal tumors because it has fewer heat sink effects [68–70]. A single antenna was used for tumors ≤ 3.0 cm in diameter, and ≥ 2 antennas were used simultaneously for tumors > 3.0 cm in diameter. In a recent meta-analysis, no significant difference was observed in local recurrence and cancer-specific mortality between MWA and nephron-sparing surgery [71]. MWA has a relatively low complication

rate [71], which is similar to that of other techniques.

Post Ablation Imaging Follow Up

Pre- and post-contrast CT and MRI are the best imaging modalities to assess renal tumor ablation if normal renal function is preserved [17,46-52,59,60,72]. If renal function is subnormal or impaired, unenhanced MRI, including diffusion-weighted imaging, may be used [73]. Generally, a 6-month interval until 2 years post-ablation is considered acceptable [17,46-52,59,60,72]. Thereafter, a one-year follow-up is recommended until 5 years post-ablation [17,46-52,59,60,72].

CONCLUSION

Thermal ablation for RCC is expected to become more popular in Asian countries, as the necessity for minimally invasive treatments increases. Therefore, interventional oncologists should be familiar with the ACTA expert consensus to perform safe and precise renal tumor ablation in Asian patients.

Key words

Thermal ablation; Renal cell carcinoma; Radiofrequency ablation; Cryoablation; Microwave ablation

Conflicts of Interest

The authors have no potential conflicts of interest to disclose.

Author Contributions

Conceptualization: all authors. Data curation: all authors. Formal analysis: all authors. Investigation: all authors. Methodology: all authors. Resources: all authors. Supervision: Byung Kwan Park. Validation: all authors. Visualization: Byung Kwan Park.

ORCID iDs

Byung Kwan Park

<https://orcid.org/0000-0002-4114-8859>

Shu-Huei Shen

<https://orcid.org/0000-0002-2776-4671>

Masashi Fujimori

<https://orcid.org/0000-0002-8244-3176>

Yi Wang

<https://orcid.org/0000-0002-3089-9403>

REFERENCES

- Campbell S, Uzzo RG, Allaf ME, Bass EB, Cadeddu JA, Chang A, et al. Renal mass and localized renal cancer: AUA guideline. *J Urol* 2017;198:520-529
- Ljungberg B, Albiges L, Abu-Ghanem Y, Bensalah K, Dabestani S, Fernández-Pello S, et al. European association of urology guidelines on renal cell carcinoma: the 2019 update. *Eur Urol* 2019;75:799-810
- Park BK, Kim CK. Percutaneous radio frequency ablation of renal tumors in patients with von Hippel-Lindau disease: preliminary results. *J Urol* 2010;183:1703-1707
- Park BK, Kim CK, Park SY, Shen SH. Percutaneous radiofrequency ablation of renal cell carcinomas in patients with von Hippel Lindau disease: indications, techniques, complications, and outcomes. *Acta Radiol* 2013;54:418-427
- Xiaobing W, Wentao G, Guangxiang L, Fan Z, Weidong G, Hongqian G, et al. Comparison of radiofrequency ablation and partial nephrectomy for tumor in a solitary kidney. *BMC Urol* 2017;17:79
- Bhindi B, Mason RJ, Haddad MM, Boorjian SA, Leibovich BC, Atwell TD, et al. Outcomes after cryoablation versus partial nephrectomy for sporadic renal tumors in a solitary kidney: a propensity score analysis. *Eur Urol* 2018;73:254-259
- Lin Y, Liang P, Yu XL, Yu J, Cheng ZG, Han ZY, et al. Percutaneous microwave ablation of renal cell carcinoma is safe in patients with a solitary kidney. *Urology* 2014;83:357-363
- Park BK, Gong IH, Kang MY, Sung HH, Jeon HG, Jeong BC, et al. RFA versus robotic partial nephrectomy for T1a renal cell carcinoma: a propensity score-matched comparison of mid-term outcome. *Eur Radiol* 2018;28:2979-2985
- Rosenberg MD, Kim CY, Tsivian M, Suberlak MN, Sopko DR, Polascik TJ, et al. Percutaneous cryoablation of renal lesions with radiographic ice ball involvement of the renal sinus: analysis of hemorrhagic and collecting system complications. *AJR Am J Roentgenol* 2011;196:935-939
- Maciolek KA, Abel EJ, Posielski NM, Hinshaw JL, Lubner MG, Lee FT Jr, et al. Tumor location does not impact oncologic outcomes for percutaneous microwave ablation of clinical T1a renal cell carcinoma. *Eur Radiol* 2019;29:6319-6329
- Hudspeth TN, Abdelsalam ME, Sabir SH, Kusin SB, Matin SF, Wood CG, et al. Minimally invasive image guided thermal ablation for recurrent renal cell carcinoma (RCC) after ipsilateral partial nephrectomy. *J Clin Oncol* 2018;36:e16557
- Park SY, Park BK, Kim CK, Lee HM, Jeon SS, Seo SI, et al. Percutaneous radiofrequency ablation of renal cell carcinomas in patients with von Hippel Lindau disease previously undergoing a radical nephrectomy or repeated nephron-sparing surgery. *Acta Radiol* 2011;52:680-685
- Okhunov Z, Chamberlin J, Moreira DM, George A, Babaian K, Shah P, et al. Salvage percutaneous cryoablation for locally recurrent renal-cell carcinoma after primary cryoablation. *J Endourol* 2016;30:632-637

14. Uppot RN, Gervais DA. Imaging-guided adrenal tumor ablation. *AJR Am J Roentgenol* 2013;200:1226-1233
15. Higgins LJ, Hong K. Renal ablation techniques: state of the art. *AJR Am J Roentgenol* 2015;205:735-741
16. Krokidis ME, Orsi F, Katsanos K, Helmberger T, Adam A. CIRSE guidelines on percutaneous ablation of small renal cell carcinoma. *Cardiovasc Intervent Radiol* 2017;40:177-191
17. Georgiades CS, Hong K, Bizzell C, Geschwind JF, Rodriguez R. Safety and efficacy of CT-guided percutaneous cryoablation for renal cell carcinoma. *J Vasc Interv Radiol* 2008;19:1302-1310
18. Park BK. Low-dose CT protocols for guiding radiofrequency ablation for the treatment of small renal cell carcinomas. *Int J Hyperthermia* 2018;34:877-882
19. Park BK, Morrison PR, Tatli S, Govindarajulu U, Tuncali K, Judy P, et al. Estimated effective dose of CT-guided percutaneous cryoablation of liver tumors. *Eur J Radiol* 2012;81:1702-1706
20. Okhunov Z, Juncal S, Ordon M, George AK, Lusch A, del Junco M, et al. Comparison of outcomes in patients undergoing percutaneous renal cryoablation with sedation vs general anesthesia. *Urology* 2015;85:130-134
21. Park BK, Kim CK, Choi HY, Lee HM, Jeon SS, Seo SI, et al. Limitation for performing ultrasound-guided radiofrequency ablation of small renal masses. *Eur J Radiol* 2010;75:248-252
22. Chan P, Vélasco S, Vesselle G, Boucebci S, Herpe G, Debaene B, et al. Percutaneous microwave ablation of renal cancers under CT guidance: safety and efficacy with a 2-year follow-up. *Clin Radiol* 2017;72:786-792
23. Finley DS, Beck S, Box G, Chu W, Deane L, Vajgrt DJ, et al. Percutaneous and laparoscopic cryoablation of small renal masses. *J Urol* 2008;180:492-498; discussion 498
24. Pessoa RR, Autorino R, Laguna MP, Molina WR, Gustafson D, Nogueira L, et al. Laparoscopic versus percutaneous cryoablation of small renal mass: systematic review and cumulative analysis of comparative studies. *Clin Genitourin Cancer* 2017;15:513-519.e5
25. Park BK, Kim CK. Complications of image-guided radiofrequency ablation of renal cell carcinoma: causes, imaging features and prevention methods. *Eur Radiol* 2009;19:2180-2190
26. Wah TM, Koenig P, Irving HC, Gervais DA, Mueller PR. Radiofrequency ablation of a central renal tumor: protection of the collecting system with a retrograde cold dextrose pyeloperfusion technique. *J Vasc Interv Radiol* 2005;16:1551-1555
27. Hwang SI, Cho JY, Kim SH, Jun SR, Lee HJ, Moon KC, et al. Protection of the renal collecting system during radiofrequency ablation with antegrade cold dextrose infusion. *Radiology* 2010;256:759-766
28. Park BK, Kim SH, Byun JY, Kim YS, Kwon GY, Jang IS. CT-guided instillation of 5% dextrose in water into the anterior pararenal space before renal radiofrequency ablation in a porcine model: positive and negative effects. *J Vasc Interv Radiol* 2007;18:1561-1569
29. Silverman SG, Gan YU, Morteale KJ, Tuncali K, Cibas ES. Renal masses in the adult patient: the role of percutaneous biopsy. *Radiology* 2006;240:6-22
30. Silverman SG, Israel GM, Herts BR, Richie JP. Management of the incidental renal mass. *Radiology* 2008;249:16-31
31. Hegarty NJ, Gill IS, Desai MM, Remer EM, O'Malley CM, Kaouk JH. Probe-ablative nephron-sparing surgery: cryoablation versus radiofrequency ablation. *Urology* 2006;68:7-13
32. Laeseke PF, Lee FT Jr, Sampson LA, van der Weide DW, Brace CL. Microwave ablation versus radiofrequency ablation in the kidney: high-power triaxial antennas create larger ablation zones than similarly sized internally cooled electrodes. *J Vasc Interv Radiol* 2009;20:1224-1229
33. Brashears JH, Raj GV, Crisci A, Young MD, Dylewski D, Nelson R, et al. Renal cryoablation and radio frequency ablation: an evaluation of worst case scenarios in a porcine model. *J Urol* 2005;173:2160-2165
34. Janzen NK, Perry KT, Han KR, Kristo B, Raman S, Said JW, et al. The effects of intentional cryoablation and radio frequency ablation of renal tissue involving the collecting system in a porcine model. *J Urol* 2005;173:1368-1374
35. WHO Expert Consultation. Appropriate body-mass index for Asian populations and its implications for policy and intervention strategies. *Lancet* 2004;363:157-163
36. Jih J, Mukherjea A, Vittinghoff E, Nguyen TT, Tsoh JY, Fukuoka Y, et al. Using appropriate body mass index cut points for overweight and obesity among Asian Americans. *Prev Med* 2014;65:1-6
37. Park JJ, Park BK, Park SY, Kim CK. Percutaneous radiofrequency ablation of sporadic Bosniak III or IV lesions: treatment techniques and short-term outcomes. *J Vasc Interv Radiol* 2015;26:46-54
38. Park BK, Kim CK, Lee HM. Image-guided radiofrequency ablation of Bosniak category III or IV cystic renal tumors: initial clinical experience. *Eur Radiol* 2008;18:1519-1525
39. Aoun HD, Littrup PJ, Jaber M, Memon F, Adam B, Krycia M, et al. Percutaneous cryoablation of renal tumors: is it time for a new paradigm shift? *J Vasc Interv Radiol* 2017;28:1363-1370
40. Carrafiello G, Dionigi G, Ierardi AM, Petrillo M, Fontana F, Floridi C, et al. Efficacy, safety and effectiveness of image-guided percutaneous microwave ablation in cystic renal lesions Bosniak III or IV after 24 months follow up. *Int J Surg* 2013;11 Suppl 1:S30-S35
41. Park SY, Park BK, Kim CK. Thermal ablation in renal cell carcinoma: what affects renal function? *Int J Hyperthermia* 2012;28:729-734
42. Knavel EM, Brace CL. Tumor ablation: common modalities and general practices. *Tech Vasc Interv Radiol* 2013;16:192-200
43. Chu KF, Dupuy DE. Thermal ablation of tumours: biological mechanisms and advances in therapy. *Nat Rev Cancer* 2014;14:199-208
44. Nikfarjam M, Muralidharan V, Christophi C. Mechanisms of focal heat destruction of liver tumors. *J Surg Res* 2005;127:208-223

45. Sommer CM, Lemm G, Hohenstein E, Stampfl U, Bellemann N, Teber D, et al. Bipolar versus multipolar radiofrequency (RF) ablation for the treatment of renal cell carcinoma: differences in technical and clinical parameters. *Int J Hyperthermia* 2013;29:21-29
46. Andrews JR, Atwell T, Schmit G, Lohse CM, Kurup AN, Weisbrod A, et al. Oncologic outcomes following partial nephrectomy and percutaneous ablation for cT1 renal masses. *Eur Urol* 2019;76:244-251
47. Iannuccilli JD, Dupuy DE, Beland MD, Machan JT, Golijanin DJ, Mayo-Smith WW. Effectiveness and safety of computed tomography-guided radiofrequency ablation of renal cancer: a 14-year single institution experience in 203 patients. *Eur Radiol* 2016;26:1656-1664
48. Olweny EO, Park SK, Tan YK, Best SL, Trimmer C, Cadeddu JA. Radiofrequency ablation versus partial nephrectomy in patients with solitary clinical T1a renal cell carcinoma: comparable oncologic outcomes at a minimum of 5 years of follow-up. *Eur Urol* 2012;61:1156-1161
49. Dai Y, Covarrubias D, Uppot R, Arellano RS. Image-guided percutaneous radiofrequency ablation of central renal cell carcinoma: assessment of clinical efficacy and safety in 31 tumors. *J Vasc Interv Radiol* 2017;28:1643-1650
50. Chang X, Liu T, Zhang F, Ji C, Zhao X, Wang W, et al. Radiofrequency ablation versus partial nephrectomy for clinical T1a renal-cell carcinoma: long-term clinical and oncologic outcomes based on a propensity score analysis. *J Endourol* 2015;29:518-525
51. Takaki H, Yamakado K, Soga N, Arima K, Nakatsuka A, Kashima M, et al. Midterm results of radiofrequency ablation versus nephrectomy for T1a renal cell carcinoma. *Jpn J Radiol* 2010;28:460-468
52. Hasegawa T, Yamanaka T, Gobara H, Miyazaki M, Takaki H, Sato Y, et al. Radiofrequency ablation versus cryoablation for T1b renal cell carcinoma: a multi-center study. *Jpn J Radiol* 2018;36:551-558
53. Zhou W, Arellano RS. Thermal ablation of T1c renal cell carcinoma: a comparative assessment of technical performance, procedural outcome, and safety of microwave ablation, radiofrequency ablation, and cryoablation. *J Vasc Interv Radiol* 2018;29:943-951
54. Takaki H, Soga N, Kanda H, Nakatsuka A, Uraki J, Fujimori M, et al. Radiofrequency ablation versus radical nephrectomy: clinical outcomes for stage T1b renal cell carcinoma. *Radiology* 2014;270:292-299
55. Atwell TD, Carter RE, Schmit GD, Carr CM, Boorjian SA, Curry TB, et al. Complications following 573 percutaneous renal radiofrequency and cryoablation procedures. *J Vasc Interv Radiol* 2012;23:48-54
56. Weizer AZ, Raj GV, O'Connell M, Robertson CN, Nelson RC, Polascik TJ. Complications after percutaneous radiofrequency ablation of renal tumors. *Urology* 2005;66:1176-1180
57. Hoffmann NE, Bischof JC. The cryobiology of cryosurgical injury. *Urology* 2002;60:40-49
58. Mazur P. Freezing of living cells: mechanisms and implications. *Am J Physiol* 1984;247:C125-C142
59. Atwell TD, Schmit GD, Boorjian SA, Mandrekar J, Kurup AN, Weisbrod AJ, et al. Percutaneous ablation of renal masses measuring 3.0 cm and smaller: comparative local control and complications after radiofrequency ablation and cryoablation. *AJR Am J Roentgenol* 2013;200:461-466
60. Pirasteh A, Snyder L, Boncher N, Passalacqua M, Rosenblum D, Prologo JD. Cryoablation vs. radiofrequency ablation for small renal masses. *Acad Radiol* 2011;18:97-100
61. Thompson RH, Atwell T, Schmit G, Lohse CM, Kurup AN, Weisbrod A, et al. Comparison of partial nephrectomy and percutaneous ablation for cT1 renal masses. *Eur Urol* 2015;67:252-259
62. Kunkle DA, Egleston BL, Uzzo RG. Excise, ablate or observe: the small renal mass dilemma--a meta-analysis and review. *J Urol* 2008;179:1227-1233; discussion 1233-1234
63. Klatte T, Grubmüller B, Waldert M, Weibl P, Remzi M. Laparoscopic cryoablation versus partial nephrectomy for the treatment of small renal masses: systematic review and cumulative analysis of observational studies. *Eur Urol* 2011;60:435-443
64. Caputo PA, Zargar H, Ramirez D, Andrade HS, Akca O, Gao T, et al. Cryoablation versus partial nephrectomy for clinical T1b renal tumors: a matched group comparative analysis. *Eur Urol* 2017;71:111-117
65. Garnon J, Van Strijen MJ, Nielsen TK, King AJ, Montauban Van Swijndregt AD, Cazzato RL, et al. Safety of percutaneous renal cryoablation: an international multicentre experience from the EuRECA retrospective percutaneous database. *Eur Radiol* 2019;29:6293-6299
66. Schmit GD, Schenck LA, Thompson RH, Boorjian SA, Kurup AN, Weisbrod AJ, et al. Predicting renal cryoablation complications: new risk score based on tumor size and location and patient history. *Radiology* 2014;272:903-910
67. Zargar H, Atwell TD, Cadeddu JA, de la Rosette JJ, Janetschek G, Kaouk JH, et al. Cryoablation for small renal masses: selection criteria, complications, and functional and oncologic results. *Eur Urol* 2016;69:116-128
68. Sommer CM, Sommer SA, Mokry T, Gockner T, Gnutzmann D, Bellemann N, et al. Quantification of tissue shrinkage and dehydration caused by microwave ablation: experimental study in kidneys for the estimation of effective coagulation volume. *J Vasc Interv Radiol* 2013;24:1241-1248
69. Brace CL. Radiofrequency and microwave ablation of the liver, lung, kidney, and bone: what are the differences? *Curr Probl Diagn Radiol* 2009;38:135-143
70. Yu J, Liang P, Yu X, Liu F, Chen L, Wang Y. A comparison of microwave ablation and bipolar radiofrequency ablation both with an internally cooled probe: results in ex vivo and in vivo porcine livers. *Eur J Radiol* 2011;79:124-130
71. Uhlig J, Strauss A, Rücker G, Seif Amir Hosseini A, Lotz J, Trojan L, et al. Partial nephrectomy versus ablative techniques for small renal masses: a systematic review and network meta-

- analysis. *Eur Radiol* 2019;29:1293-1307
72. Atwell TD, Vlaminc JJ, Boorjian SA, Kurup AN, Callstrom MR, Weisbrod AJ, et al. Percutaneous cryoablation of stage T1b renal cell carcinoma: technique considerations, safety, and local tumor control. *J Vasc Interv Radiol* 2015;26:792-799
73. Lee HJ, Chung HJ, Wang HK, Shen SH, Chang YH, Chen CK, et al. Evolutionary magnetic resonance appearance of renal cell carcinoma after percutaneous cryoablation. *Br J Radiol* 2016;89:20160151