

Case  
Report

# Early LVAD Implantation in a Patient with Left Ventricular Failure after Aortic Dissection with Left Main Stem Involvement

Hazem El Beyrouti, MD, Angela Kornberger, MD, Nancy Halloum,  
Andres Beiras-Fernandez, MD, PhD, and Christian-Friedrich Vahl, MD, PhD

**Background:** Coronary involvement in aortic dissection heralds a poor outcome. Involvement of the left main stem may lead to left ventricular (LV) failure requiring mechanical circulatory support.

**Case Report:** A staged approach was applied in a 24-year-old female who suffered extensive infarction due to aortic dissection with left main stem involvement. After replacement of the ascending aorta and grafting of the left internal thoracic artery to the left anterior descending artery following a failed attempt at reconstruction of the left coronary ostium, she failed to wean from cardiopulmonary bypass (CPB) and underwent implantation of an extracorporeal life support (ECLS) system as a bridge to decision. Subsequent implantation of a left ventricular assist device (LVAD) as a bridge to recovery/transplantation was followed by an uneventful further course.

**Conclusions:** Our experience suggests that early implantation of a ventricular assist device (VAD) as bridge to recovery/transplantation is an alternative to prolonged ECLS in patients who suffered extensive myocardial infarction in the course of aortic dissection.

**Keywords:** aortic dissection, coronary involvement, heart failure, LVAD

## Introduction

Stanford type A aortic dissection (AAD) is one of the most lethal cardiovascular emergencies. Poor outcomes must be expected, in particular, in cases where AAD has resulted in extensive coronary malperfusion and heart failure. Data from the International Registry of Acute Aortic

Dissection (IRAD) showed that signs of myocardial ischemia were present on the initial electrocardiography (ECG) in 19.9% of those who underwent surgery for AAD, while myocardial infarction with new Q waves or ST elevations was present in 6.0%.<sup>1)</sup> According to other studies, the incidence of acute myocardial ischemia due to coronary involvement in AAD ranges from 5.7% to 11.3%.<sup>2-4)</sup>

The importance of coronary involvement in AAD is highlighted by the fact that the IRAD listed myocardial ischemia, infarction and necessity to perform coronary artery bypass grafting (CABG) among the statistically significant predictors of death after surgical repair of AAD.<sup>1)</sup> In keeping with these findings, other studies also demonstrated significantly higher mortality rates for patients with coronary malperfusion than for those without. Kawahito et al.,<sup>2)</sup> for example, reported a mortality rate of 33.3% in patients with coronary malperfusion versus 8.1% in those without, while Neri et al.<sup>4)</sup> found that 20% of their patients with AAD and coronary malperfusion had died. Of note, all deaths in those with

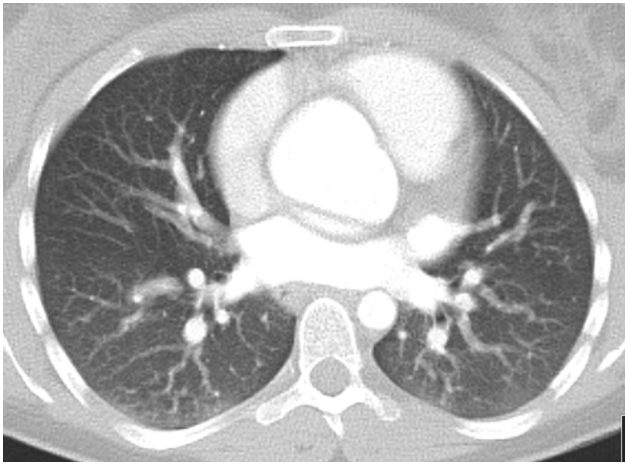
*Department of Cardiothoracic and Vascular Surgery, University Hospital, Johannes Gutenberg University, Mainz, Germany*

Received: December 11, 2017; Accepted: February 5, 2018  
Corresponding author: Angela Kornberger, MD. Department of Cardiothoracic and Vascular Surgery, University Hospital of Johannes Gutenberg University, Langenbeckstr. 1, 55131 Mainz, Germany  
Email: Angela.Kornberger@unimedizin-mainz.de

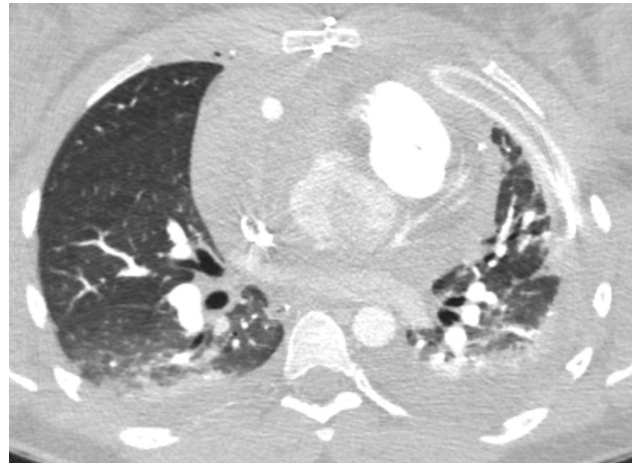


This work is licensed under a Creative Commons Attribution-NonCommercial-NoDerivatives International License.

©2020 The Editorial Committee of *Annals of Thoracic and Cardiovascular Surgery*



**Fig. 1** Preoperative CT showing dissection with compressed true lumen. The left main stem is absent due to occlusion of the left main stem. CT: computed tomography



**Fig. 2** Postoperative CT showing the left coronary artery still detached from the aorta but with perfusion provided by the LITA graft. CT: computed tomography; LITA: left internal thoracic artery

coronary malperfusion in these two studies had been due to heart failure.

From this, it follows that centers providing surgery for AAD must be prepared to handle devastating heart failure caused by coronary malperfusion. While extracorporeal life support (ECLS) may be used as a bridge to decision, need for a permanent ventricular assist device (VAD) as a bridge to recovery/transplantation or as destination therapy should be anticipated.

## Case Report

Computed tomography (CT) was performed at a peripheral hospital in a 24-year-old female who had complained of persisting chest and back pain and been treated with analgesics for nearly 2 weeks after an event of acute thoracic pain. She was finally diagnosed with AAD that had led to compromise of the left coronary ostium (**Figs. 1** and **2**). Echocardiography demonstrated a poor left ventricular (LV) ejection fraction that was in keeping with the finding of severely compromised coronary perfusion. She was transferred to our hospital for surgery, and a staged approach anticipating need for postoperative mechanical circulatory support was agreed upon.

Intraoperative inspection of the dissected aorta and the LV myocardium yielded findings perfectly compatible with a process that had been ongoing since the patient had experienced the initial event of thoracic pain. After transection and direct true lumen cannulation of the ascending aorta, the left coronary ostium was found to have collapsed without, however, being irreversibly

occluded. Therefore, antegrade cardioplegia was administered via the coronary ostia.

Subsequently, supracoronary replacement of the ascending aorta was implemented in deep hypothermic circulatory arrest. When it was found that repair of the left coronary ostium had failed, the left internal thoracic artery was grafted to the patient's extremely narrow left anterior descending artery. Grafting of the circumflex artery turned out to be unfeasible due to the extremely narrow caliber of the circumflex system. When weaning from cardiopulmonary bypass (CPB) turned out to be impossible, the patient was put on ECLS using a side-graft (6 mm Dacron prosthesis) sewn to the aortic prosthesis for central cannulation (Nova Port Single Lumen Cannula, Novalung GmbH). The venous cannula (Bio-Medicus Multi-Stage Femoral Venous Cannula, Medtronic Inc.) was placed in the right femoral vein.

The ECLS system provided adequate circulatory support and the patient remained hemodynamically stable. Upon discontinuation of sedatives, her neurologic status was found normal. Considering that coronary malperfusion had been ongoing for some time preceding the surgical repair, and given the devastating LV damage seen intraoperatively and evidenced by CK and CK-MB levels of 8816 and 884 U/L and a troponin level of 488 899 pg/ml, respectively, sufficient recovery of the LV myocardium in the short run appeared unlikely. To prevent complications associated with prolonged ECLS, left ventricular assist device (LVAD) implantation as a bridge to recovery/transplantation was scheduled for the second day after the aortic procedure.

After re-sternotomy, the arterial cannula was moved from the aorta to the femoral artery and the patient was switched back from ECLS to CPB. After implantation of the pump (HVAD, HeartWare Inc., Framingham, MA, USA), the aortic prosthesis was side-clamped, the side-graft attached to the aorta was removed, and the LVAD outflow graft was joined to the aortic prosthesis. When chest closure turned out to be impossible due to massive edematous swelling of the heart, the patient was transferred back to the intensive care unit (ICU) with the sternotomy wound temporarily covered.

After regression of her massive cardiac edema and chest closure 2 days later, the patient took an unremarkable further course. She was transferred to the ward after 16 days in the ICU and discharged to a rehabilitation facility after a total hospital stay of 27 days.

## Discussion

More than a decade ago, the mortality rates published for coronary involvement in AAD were so high that some authors argued that exclusion criteria should be established for emergent surgery in patients with AAD and extensive myocardial infarction because of the dismal salvation rate in these cases.<sup>5)</sup>

At that time, the threshold to VAD therapy was still high. Today, in contrast, the availability of and experience with VAD therapy must be taken into account when it comes to evaluate the prognosis of young patients with extensive myocardial damage secondary to coronary involvement in AAD.

While the association between extensive myocardial infarction, VAD therapy and heart transplantation is obvious, our review of the literature yielded but few reports directly linking aortic dissection with heart transplantation. In a case that resembles our own, a patient was successfully bridged to transplantation for 173 days with a total artificial heart after sustaining cardiac arrest secondary to STEMI caused by Stanford type A dissection involving the left coronary ostium.<sup>6)</sup> Others pointed out that total artificial heart implantation may be indicated in patients with conditions that increase the risk of right ventricular failure post-LVAD implantation and listed aortic root dissection as one of the possible indications for a total artificial heart,<sup>7)</sup> which may be considered a definite way of routing a patient toward transplantation.

Considering that it was occlusion of the left main trunk and devastating myocardial infarction in the setting of aortic dissection that led to our patient's dismal prognosis,

our case is not only one of LVAD implantation following aortic dissection, but also falls within the category of mechanical circulatory support following acute myocardial infarction involving the left main trunk.

This is an issue more extensively covered by literature. Yamauchi et al., for example, recently investigated the long-term clinical results in 27 patients who required percutaneous cardiopulmonary support after acute myocardial infarction involving the left main trunk and reported death from low output or brain damage in 33.3%, LVAD implantation in 37%, and survival without LVAD implantation in the remaining 29.6%. Finding that 50% of those who received an LVAD had suffered preoperative organ failure and survived no more than 6 months, they suggested that timely LVAD insertion before the onset of complications might lead to better survival. At 1, 2, and 3 years, 40%, 30%, and 20% of the LVAD recipients were alive, thus demonstrating that LVAD implantation after devastating myocardial infarction following left main trunk occlusion offers potential benefits but is associated with considerable mortality in the long run, too.<sup>8)</sup>

While LVAD implantation in these cases as well as in our own followed a period on a temporary cardiopulmonary support system, others recommended primary implantation of durable LVADs as initial therapy for refractory cardiogenic shock including cases caused by acute myocardial infarction.<sup>9)</sup> While it may be argued that patients should be given time to recover on temporary circulatory support before implantation of a durable LVAD, it should also be taken into account that myocardial recovery after devastating infarction will usually not be achieved within a few days.

In fact, the likelihood of relevant myocardial recovery after extensive infarction such as may be found after a longer period of left main occlusion is low. This is in keeping with reports suggesting that patients requiring LVAD support for ischemic heart failure/myocardial infarction rarely recover sufficiently to allow device explantation.<sup>10)</sup> In a study specifically investigating the issue of myocardial recovery, patients supported with LVADs for at least 6 months were compared, and it was found that 21% of those with non-ischemic but only 5% of those with ischemic cardiomyopathy had achieved a LV ejection fraction >40%.<sup>11)</sup>

Our case demonstrates that early LVAD implantation is feasible in the highly distinct subgroup of patients with devastating myocardial infarction caused by aortic dissection. We believe, however, that implantation of a permanent VAD should not be performed as part of the aortic repair procedure. Patients failing to wean from

CPB or developing severe heart failure after aortic repair should initially be supported with an ECLS system. The possibility of subsequent VAD implantation should, however, be kept in mind, and preparations should be made to prevent delays caused by the need for further diagnostics or administrative requirements once the definite indication for VAD implantation has been established.

Considering that ECLS carries considerable morbidity and mortality, adequate timing of the VAD implantation procedure is essential. It should be scheduled as soon as there is agreement that sufficient recovery of the patient's cardiac function on ECLS is unlikely and before complications of prolonged ECLS therapy occur. In our case, LVAD implantation was performed particularly early because we considered rapid myocardial recovery after delayed diagnosis and therapy of AAD with coronary involvement extremely unlikely but were aware that the probability of occurrence of ECLS-associated complications increased with every day of support.

## Conclusion

Our experience suggests that early implantation of a VAD as bridge to recovery/transplantation is an alternative to prolonged ECLS in patients who suffered extensive myocardial infarction in the course of aortic dissection.

## Disclosure Statement

The authors declare that they have no competing interests.

## Authors' contributions

HE, NH, and AK collected and evaluated the data, drafted the manuscript, and prepared the illustrations. ABF and CFV critically reviewed the manuscript. ABF and CFV gave the consent for publication. All authors read and approved the final manuscript.

## References

- 1) Trimarchi S, Nienaber CA, Rampoldi V, et al. Contemporary results of surgery in acute type A aortic dissection: the international registry of acute aortic dissection experience. *J Thorac Cardiovasc Surg* 2005; **129**: 112-22.
- 2) Kawahito K, Adachi H, Murata S, et al. Coronary malperfusion due to type A aortic dissection: mechanism and surgical management. *Ann Thorac Surg* 2003; **76**: 1471-6; discussion 1476.
- 3) Pêgo-Fernandes PM, Stolf NA, Hervoso CM, et al. Management of aortic dissection that involves the right coronary artery. *Cardiovasc Surg* 1999; **7**: 545-8.
- 4) Neri E, Toscano T, Papalia U, et al. Proximal aortic dissection with coronary malperfusion: presentation, management, and outcome. *J Thorac Cardiovasc Surg* 2001; **121**: 552-60.
- 5) Kazui T. Invited commentary on coronary malperfusion due to aortic dissection. *Ann Thorac Surg* 2003; **76**: 1476.
- 6) Attia T, Robich M, Lincoff AM, et al. Successful treatment of aortic root dissection complicated with extensive myocardial infarction using the total artificial heart. *J Surg Case Rep* 2017; **2017**: rjx123.
- 7) Tang DG, Shah KB, Hess ML, et al. Implantation of the syncardia total artificial heart. *J Vis Exp* 2014; 50377.
- 8) Yamauchi T, Masai T, Fujii K, et al. Long-term clinical results of acute myocardial infarction at the left main trunk requiring percutaneous cardiopulmonary support. *J Artif Organs* 2017; **20**: 303-10.
- 9) Pawale A, Schwartz Y, Itagaki S, et al. Selective implantation of durable left ventricular assist devices as primary therapy for refractory cardiogenic shock. *J Thorac Cardiovasc Surg* 2018; **155**: 1059-68.
- 10) Simon MA, Kormos RL, Murali S, et al. Myocardial recovery using ventricular assist devices: prevalence, clinical characteristics, and outcomes. *Circulation* 2005; **112**: I32-6.
- 11) Wever-Pinzon J, Selzman CH, Stoddard G, et al. Impact of ischemic heart failure etiology on cardiac recovery during mechanical unloading. *J Am Coll Cardiol* 2016; **68**: 1741-52.