

A Case of Blind Loop Syndrome Caused by Infection with *Giardia duodenalis* Diagnosed with Double Balloon Enteroscopy

Tomoo Nakagawa^a Tatsuro Katsuno^b Yasushi Mandai^a Masaya Saito^a
Sayuri Yoshihama^a Keiko Saito^a Shoko Minemura^a Daisuke Maruoka^a
Tomoaki Matsumura^a Makoto Arai^a Osamu Yokosuka^a

^aDepartment of Gastroenterology and Nephrology (K1), Graduate School of Medicine, and

^bCenter for Environment, Health and Field Sciences, Chiba University, Chiba, Japan

Key Words

Blind loop syndrome · Double balloon enteroscopy · *Giardia duodenalis* · Polymerase chain reaction-restriction fragment length polymorphism

Abstract

A 75-year-old man who had undergone partial gastrectomy was referred to our hospital due to worsening leg edema, loose stools and malnutrition. Double balloon enteroscopy followed by insertion of an indwelling ileus tube was performed to investigate the microbial flora and for washing inside the blind loop. Trophozoites of *Giardia* were detected in the sampled fluid from the blind loop and DNA analysis disclosed an assemblage of genotype A-II of *Giardia duodenalis*. Treatment with oral metronidazole was effective. This case emphasizes the importance of a correct diagnosis when treating patients with blind loop syndrome in the digestive tract.

© 2014 S. Karger AG, Basel

Introduction

Blind loop syndrome often causes diarrhea, body weight loss and malnutrition. This condition is caused by bacterial overgrowth in a bypassed intestinal loop. Small intestinal bacterial overgrowth is a probable etiology in malnutrition in older people who have undergone partial gastrectomy. Blind loop syndrome leads to loss of defense mechanisms

Tomoo Nakagawa, MD
Department of Gastroenterology and Nephrology (K1)
Graduate School of Medicine, Chiba University
1-8-1 Inohana, Chuo-ku, Chiba City 260-8670, Chiba (Japan)
E-Mail tom20852@hospital.chiba-u.jp

against enteric bacteria due to decreased intestinal motility and reduced gastric acid, immunologic and antibacterial secretions [1, 2].

Infections with *Giardia* have been reported in Japan, with most cases of human giardiasis related to travel, particularly to tropical and subtropical areas. Here we report a case of blind loop syndrome caused by persistent *Giardia* infection that was diagnosed with double balloon enteroscopy. The assemblage of *Giardia* genotypes was determined by polymerase chain reaction-restriction fragment length polymorphism (PCR-RFLP). These approaches enabled analysis of the microbiota from the intestinal fluid in the blind loop.

Case Report

A 75-year-old man was referred to our hospital due to worsening edema and loose stools. Anemia and malnutrition had been diagnosed in blood tests performed at a local clinic, but no malignant disease had been detected. In January 2008, about 6 months before referral, the patient had first recognized edema in both legs. His medical history included appendectomy at age 30 years and simultaneous cholecystectomy and partial gastrectomy (Billroth operation II) performed 4 years later. He had been taking medication to control diabetes for 5 years and control was good. He had not traveled overseas or had contact with animals for at least 1 year.

Physical examination showed mild tachycardia without arrhythmia, anemic palpebral conjunctiva and pretibial pitting edema. Routine blood tests showed iron deficiency anemia and severe hypoalbuminemia (total protein 38 g/l, albumin 18 g/l), malnutrition (total cholesterol 96 mg/dl, choline esterase 75 mg/dl) and mild liver dysfunction. HIV, urine, fecal occult blood and fecal culture tests gave no critical findings. However, Sudan III staining for fecal fat was strongly positive and α 1 anti-trypsin clearance was slightly elevated. Upper gastrointestinal endoscopy and colonoscopy revealed no important findings. Video capsule endoscopy showed normal small intestinal mucosa. Abdominal enhanced CT imaging and ^{99m}Tc -labeled human serum albumin scintigraphy revealed no significant findings.

These findings led us to suspect blind loop syndrome due to bacterial overgrowth in a blind loop produced by Billroth operation II. Double balloon enteroscopy (EN450T/W, Fujifilm, Japan) was performed to investigate bacterial overgrowth in the blind loop and to place an indwelling ileus tube for continuous monitoring inside the loop over a few days. An ileus tube for collection of fluid samples and for treatment by washing and administration of drugs (fig. 1) was inserted into the blind loop using double balloon enteroscopy. Briefly, an inner endoscope with an over-tube was inserted into the blind loop and a long guidewire and biptome were inserted into the inner endoscope. After removal of the inner endoscope, the ileus tube was inserted into the blind loop by guidance with the over-tube and guidewire. Hood attachment and rubber bands to fasten the front balloon of the inner endoscope were not used to pull the scope from the over-tube because these attachments made the tip diameter of the scope larger than the inside over-tube diameter. In our hospital, surgical thread or fishline is used to tie the front balloon of the scope.

Teardrop-shaped microorganisms characterized as trophozoites of *Giardia* were detected in fluid collected from the blind loop after Gram staining and microscopic observation (fig. 2a). Malabsorption syndrome due to persistent *Giardia* infection in the blind loop was diagnosed. Treatment with 750 mg metronidazole for 2 weeks produced rapid improvement of nutrition. The same procedure performed 1 year later showed no pathogenic microbiota in the blind loop and there has been no recurrence of symptoms for five years (fig. 3).

The diagnosis of *Giardia* infection prompted us to hypothesize that an atypical assemblage of microorganisms may have infected the blind loop. To test this hypothesis, PCR-RFLP at the glutamate dehydrogenase (*gdh*) gene locus was performed using fluid collected from the blind loop, as described previously [3]. In brief, a semi-nested PCR was developed using internal forward, external forward and reverse primers to yield a fragment of approximately 432 base pairs of *gdh* after extraction of DNA from fluid samples. The PCR product was profiled with DNA electrophoresis after digestion with specific restriction enzymes, *NlaIV* and *RsaI*. The results showed persistent infection by genotype A-II of *Giardia duodenalis* (fig. 2b).

Discussion

Giardiasis is typically characterized by watery diarrhea, vomiting, nausea and body weight loss; however, the main symptoms in this case were edema and loose stools. There are only a few reports on malabsorption syndrome caused by *Giardia* infection in the intestine. Tandon et al. [4] proposed that an interaction between bile salt deconjugation in the upper jejunum and bacterial overgrowth might contribute to the mechanism of malabsorption in giardiasis, and Castro et al. [5] reported three cases of malabsorption syndrome due to giardiasis after a Billroth operation II. PCR-RFLP at the *gdh* locus can discriminate among *Giardia* genotypes [3].

At the start of genotyping, we hypothesized that this case was infected by an atypical genotype of *Giardia* or by a mixed assemblage because the main symptom was malabsorption and neither cysts nor trophozoites were detected in a fecal culture test. Homan and Mank [6] proposed that the severity of diarrhea is related to the presence of assemblage A or B, with patients with giardiasis with stool samples containing assemblage B having severer symptoms than those with assemblage A. An outbreak of a mixed assemblage infection has also been described, and assemblage D passed from dogs may be a novel zoonosis based on an investigation of German travelers who visited an endemic area [7]. However, our analysis using fluid collected from the blind loop demonstrated persistent infection by genotype A-II of *G. duodenalis*.

This case suggests that giardiasis should be considered as a microbe in overgrowth in the blind loop of the intestine in a non-endemic area of *Giardia*. Infection with *Giardia* in a non-endemic area has also been associated with a high prevalence of irritable bowel syndrome and chronic fatigue after acute illness [8]. There is likely to be an increasing number of patients with a blind loop in the intestine after operations such as subtotal gastrectomy and bariatric surgery for obesity [9]. Patients with inflammatory bowel disease may also have a blind loop in the intestine as a complication of disease or after surgery. However, there is sometimes a significant delay in the diagnosis of bacterial overgrowth in a blind loop due to the difficulty of assessment of the environment inside the loop, and it is often difficult to select an appropriate antibiotic to treat the condition in a blind fashion [1, 10, 11]. The present case suggests that sampling of fluid in the blind loop using double balloon enteroscopy and insertion of an indwelling ileus tube for continuous monitoring inside the loop for a few days, accompanied by analysis of the microbiota in the loop, facilitates correct diagnosis and appropriate treatment for patients with malnutrition who have a blind loop in the digestive tract.

Author Contributions

T. Nakagawa, T. Katsuno, M. Saito and O. Yokosuka looked after the patient. T. Nakagawa and T. Katsuno wrote the report. K. Saito, D. Maruoka, T. Matsumura and M. Arai edited the report. Written consent to publish was obtained from the patient.

Disclosure Statement

The authors state that they have no conflict of interest directly relevant to the content of this article.

References

- 1 Elphick DA, Chew TS, Higham SE, Bird N, Ahmad A, Sanders DS: Small bowel bacterial overgrowth in symptomatic older people: can it be diagnosed earlier? *Gerontology* 2005;51:396–401.
- 2 Iivonen MK, Ahola TO, Matikainen MJ: Bacterial overgrowth, intestinal transit, and nutrition after total gastrectomy. Comparison of a jejunal pouch with Roux-en-Y reconstruction in a prospective random study. *Scand J Gastroenterol* 1998;33:63–70.
- 3 Read CM, Monis PT, Thompson RC: Discrimination of all genotypes of *Giardia duodenalis* at the glutamate dehydrogenase locus using PCR-RFLP. *Infect Genet Evol* 2004;4:125–130.
- 4 Tandon BN, Tandon RK, Satpathy BK, Shriniwas: Mechanism of malabsorption in giardiasis: a study of bacterial flora and bile salt deconjugation in upper jejunum. *Gut* 1977;18:176–181.
- 5 Castro M, Sánchez Porto A, Guillén P, Martín E, Guerrero P, Vargas J: Malabsorption syndrome caused by *Giardia lamblia* in gastrectomized patients (in Spanish). *Enferm Infecc Microbiol Clin* 1989;7:100–102.
- 6 Homan WL, Mank TG: Human giardiasis: genotype linked differences in clinical symptomatology. *Int J Parasitol* 2001;31:822–826.
- 7 Broglia A, Weitzel T, Harms G, Caccio SM, Nockler K: Molecular typing of *Giardia duodenalis* isolates from German travellers. *Parasitol Res* 2013;112:3449–3456.
- 8 Wensaas KA, Langeland N, Hanevik K, Morch K, Eide GE, Rortveit G: Irritable bowel syndrome and chronic fatigue 3 years after acute giardiasis: historic cohort study. *Gut* 2012;61:214–219.
- 9 Quigley S, Colledge J, Mukherjee S, Patel K: Bariatric surgery: a review of normal postoperative anatomy and complications. *Clin Radiol* 2011;66:903–914.
- 10 Elphick HL, Elphick DA, Sanders DS: Small bowel bacterial overgrowth. An underrecognized cause of malnutrition in older adults. *Geriatrics* 2006;61:21–26.
- 11 Di Stefano M, Miceli E, Missanelli A, Mazzocchi S, Corazza GR: Absorbable versus non-absorbable antibiotics in the treatment of small intestine bacterial overgrowth in patients with blind-loop syndrome. *Aliment Pharmacol Ther* 2005;21:985–992.

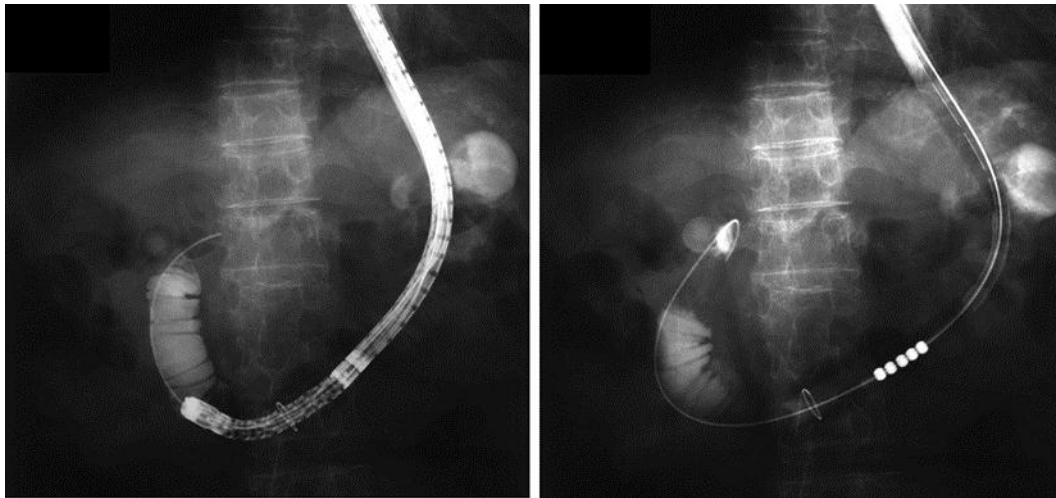


Fig. 1. An ileus tube was inserted into the blind loop using double balloon enteroscopy to collect fluid samples and to wash this region and administer drugs into the blind loop for a few days.

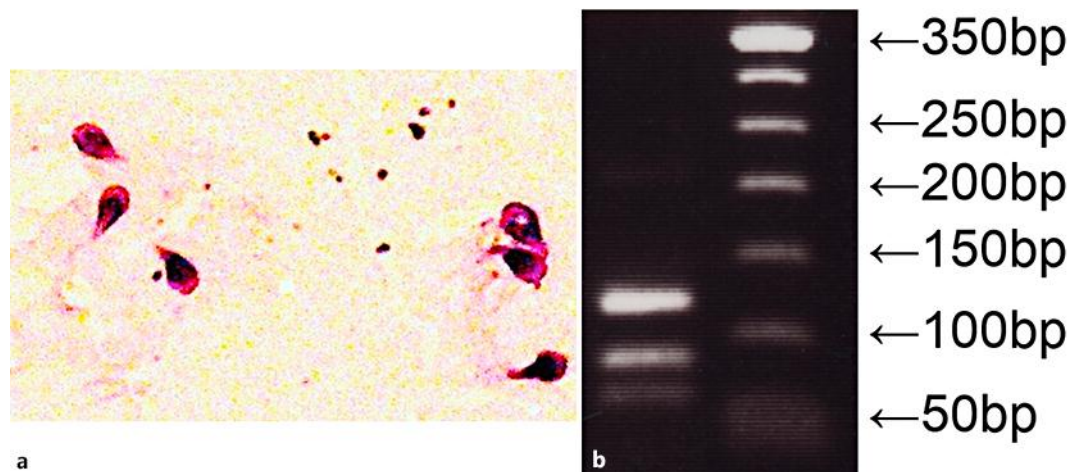


Fig. 2. **a** Immediate microscopic examination with Gram staining revealed teardrop-shaped microorganisms in fluid samples collected from the blind loop formed in partial gastrectomy with the Billroth II procedure. **b** An assemblage of A-II *G. duodenalis* was identified by PCR-RFLP genotyping. The PCR product from genomic DNA of fluid samples was digested with restriction enzymes and subjected to electrophoresis. The left lane indicates specific bands for A-II, the right lane shows DNA markers.

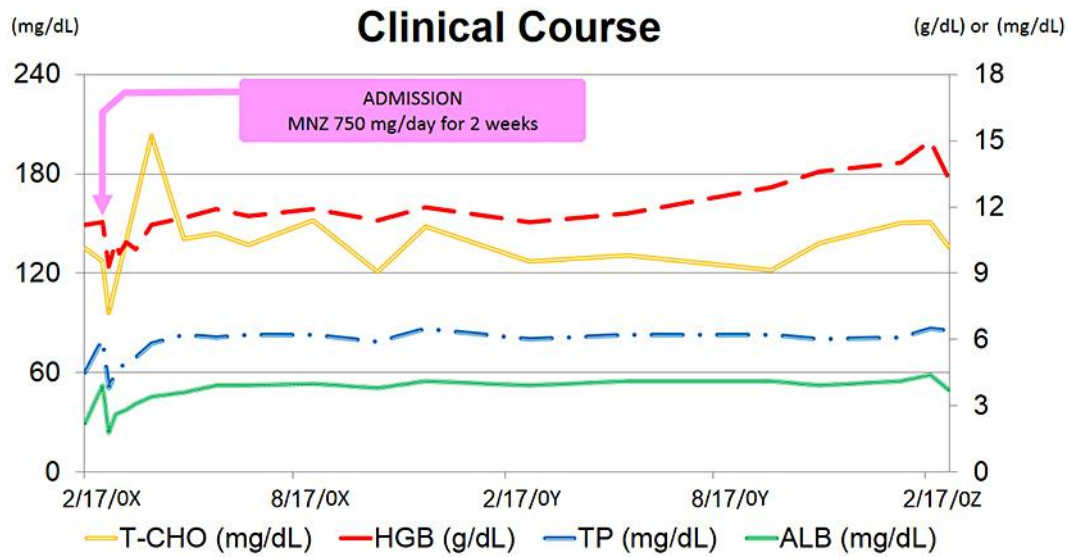


Fig. 3. Clinical course for 2 years after admission. Treatment with 750 mg metronidazole (MNZ) for 2 weeks produced rapid improvement of nutrition levels and there was no recurrence of malabsorption and anemia. T-CHO = Total cholesterol; HGB = hemoglobin; TP = total protein; ALB = albumin. The T-CHO scale is shown on the left axis and all other parameter scales are shown on the right axis.