

Diagnostic Accuracy of Magnetic Resonance Images and Weight-Bearing Radiographs in Patients With Arthroscopic-Proven Medial Osteoarthritis of the Knee

Clinical Medicine Insights: Arthritis and Musculoskeletal Disorders
Volume 13: 1–9
© The Author(s) 2020
Article reuse guidelines:
sagepub.com/journals-permissions
DOI: 10.1177/1179544120938369



Nuria Muñoz-García¹ , José Cordero-Ampuero² and Rosario Madero-Jarabo³

¹Department of Orthopaedic Surgery, Santa Cristina University Hospital, Madrid, Spain. ²Department of Orthopaedic Surgery, La Princesa University Hospital, Autonoma University, Madrid, Spain. ³Department of Statistics, La Paz University Hospital, Madrid, Spain.

ABSTRACT

AIMS: The aim of this study is to analyze the diagnostic value of weight-bearing radiographs, magnetic resonance images (MRI), and the combination of both in osteoarthritic knees when using arthroscopic findings as the “gold standard” to compare with.

METHODS: A total of 59 patients were studied because of chronic pain in 1 of their knees. Radiographs were classified according to Kellgren-Lawrence scale. Magnetic resonance images were classified according to Vallo-ton, and arthroscopic findings according to Outer-bridge criteria.

RESULTS: Sensitivity, specificity, positive predictive value, negative predictive value, and accuracy were, respectively, 75.0%, 60.0%, 56.2%, 77.8%, and 66.1% for weight-bearing radiographs, and 70.8%, 88.6%, 81.0%, 81.6%, and 81.4% for MRI. Logistic regression analysis showed that a weight-bearing radiograph added to MRI offered no additional diagnostic value compared with MRI alone ($P < .001$).

CONCLUSIONS: Magnetic resonance images presented higher specificity, positive and negative predictive values, and accuracy than weight-bearing radiographs for knee osteoarthritis. The combination of radiographs and MRI did not improve the diagnostic accuracy, compared with MRI alone.

KEYWORDS: Knee, osteoarthritis, radiographs, magnetic resonance, arthroscopy

RECEIVED: May 10, 2020. **ACCEPTED:** May 11, 2020.

TYPE: Original Research

FUNDING: The author(s) received no financial support for the research, authorship, and/or publication of this article.

DECLARATION OF CONFLICTING INTEREST: The author(s) declared no potential conflicts of interest with respect to the research, authorship, and/or publication of this article.

CORRESPONDING AUTHOR: Nuria Muñoz-García, Department of Orthopaedic Surgery, Santa Cristina University Hospital, c/ Maestro Amadeo Vives, 3, 28009 Madrid, Spain. Email: nuri.mun5@gmail.com

Introduction

Weight-bearing radiographs are very useful for the diagnosis of osteoarthritis of the tibiofemoral joint,¹⁻³ showing multiple signs as osteophytes, subchondral sclerosis, and, overall, narrowing of the joint space.^{2,4,5} These signs are used in Ahlbäck and Kellgren-Lawrence classifications.^{2,6,7} Some studies evaluated positively the usefulness of weight-bearing radiographs for knee osteoarthritis.⁸ The sensitivity of the posteroanterior standing radiograph to detect significant medial compartment osteoarthritis ranged from 3.0% to 95.0%, and the specificity ranged from 60.0% to 98.0%.^{2,9-11} The most used parameter was joint space narrowing.^{7,8,12} Sensitivity and specificity of each parameter in weight-bearing radiographs for tibiofemoral osteoarthritis were also studied. Focusing on the medial compartment, marginal osteophytes were the most sensitive feature for the detection of osteoarthritis of the tibiofemoral joint (67.2%), but it was also the least specific finding (72.9%). Joint space narrowing was less sensitive (46.0%), but its specificity was higher (94.6%). It was suggested that osteoarthritis in the tibiofemoral joint should be diagnosed on the basis of marginal osteophytes and that joint space narrowing should be used to

assess the severity of the disease.² In addition, a recent study by Duncan et al found that the Kellgren-Lawrence system was more sensitive for severe osteoarthritis in the medial compartment, with 95.0% sensitivity versus 83.0% for the joint space narrowing classification (but this was not statistically significant). The joint space narrowing classification was more specific for the medial compartment, showing a specificity of 96.0% versus 59.0% for the Kellgren-Lawrence system ($P < .01$).⁹ Nevertheless, knee joint space depends on knee flexion and X-ray beam position.^{13,14}

Magnetic resonance imaging (MRI) is also a valuable diagnostic tool for knee osteoarthritis. The degree of degenerative chondral lesions may be measured with the Vallo-ton classification system.^{15,16} Sensitivity reached only 60% for tibial plateau degenerative changes, especially in mild degrees of the disease, in some studies, whereas specificity was more than 90%.^{15,17} But it was also reported a sensitivity of 0% to 86% for identifying early grades and up to 98% in advanced grades, and a specificity of 48% to 95% in early grades and up to 100% in advanced grades in a recent systematic review.¹⁸ Magnetic resonance imaging is also considered a better tool for measuring



Creative Commons Non Commercial CC BY-NC: This article is distributed under the terms of the Creative Commons Attribution-NonCommercial 4.0 License (<https://creativecommons.org/licenses/by-nc/4.0/>) which permits non-commercial use, reproduction and distribution of the work without further permission provided the original work is attributed as specified on the SAGE and Open Access pages (<https://us.sagepub.com/en-us/nam/open-access-at-sage>).

disease progression.⁵ Magnetic resonance imaging findings for degenerative disease are dependent on the power of the magnetic field used, and 3.0-T MRI diagnostic results were better compared with the 1.5-T ones.^{19,20}

A study of the relationship between the progression of joint space narrowing on radiographic images and cartilage loss on MRI concluded that radiography was not a sensitive measure, and, if used alone, a substantial proportion of knees with cartilage loss would be missed.⁵ Nevertheless, both weight-bearing radiographs and MRI could describe only partially an osteoarthritic knee and underestimate (underdiagnose) mild degrees of the disease,²¹ so additional studies to evaluate the relative importance of both diagnostic tools and methods to include the whole joint have been proposed.²¹ Galea et al¹⁵ studied the accuracy of MRI in patients with previous diagnosis based on clinical and radiographic examination. The usefulness of each tool (weight-bearing radiographs and MRI) to identify degenerative joint disease was described in the study, but the accuracy of the combination of both compared with each technique separately was not studied. To the best of our knowledge, no previous study has evaluated the diagnostic value of the combination of weight-bearing radiographs and MRI.

Methods

Study design

This is a diagnostic, prospective study on a consecutive cohort of patients comparing diagnostic signs in weight-bearing (standing) radiographs and in MRI with arthroscopic findings.

Inclusion criteria

The inclusion criteria are as follows:

- Chronic pain in 1 knee for more than 6 months that limits walking in different grades. Radiologic criteria are used for diagnosing osteoarthritis patients;
- No description of previous traumatic episode;
- Painful knee is the main limiting factor for the global functional disability of the patient.

Exclusion criteria

The exclusion criteria are as follows:

- Inflammatory and autoimmune arthritis;
- Pseudogout, hyperuricemia, and other microcrystalline arthritis;
- Local acute and/or chronic infection in the knee and/or its sequelae;
- Previous surgery in the knee;
- Polyarticular disease of any cause;
- Osteochondritis dissecans;

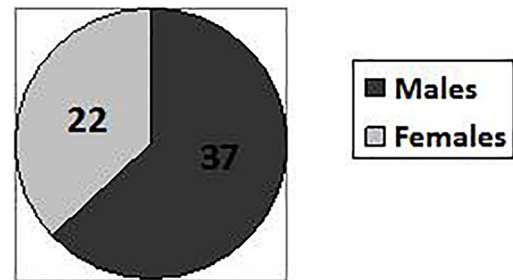


Figure 1. Sex distribution.

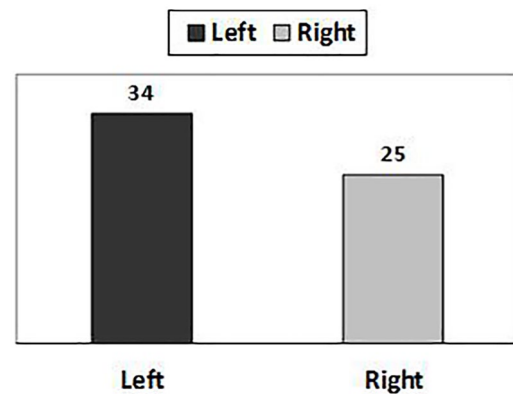


Figure 2. Knee involved.

- Osteonecrosis;
- Dysplasia of the knee of any cause;
- Although the study is about degenerative changes in the medial compartment, degenerative disease in the lateral and/or patellofemoral compartment is not an exclusion criterion.

Epidemiology

Patients with different diagnoses (meniscal tear, anterior cruciate ligament tear, refractory knee pain) were operated because of chronic pain in their knee in a General Hospital between May 2010 and February 2013. The group was formed by 59 patients with an average age of 49.6 (21-82) years. There were 37 men (62.7%) (average: 44.2%) and 22 women (37.3%) (average: 58.7%) (Figure 1). The left knee was studied in 34 patients and the right knee was studied in 25 (Figure 2). Pain had remained an average of 14.2 (6-60) months before the diagnostic process. Heavy labor activity was performed by 45% of patients, and another 37% of patients practiced a moderate level of sports/leisure activity. Prior to the beginning of the study, between 60 and 65 patients were expected to enroll in this study, which was a statistical estimation of the number of patients fulfilling the inclusion criteria during a period of 3 years. The accuracy was estimated by the width of the confidence intervals. Although numbers could appear small, the sample of patients with osteoarthritis changes was enough to reach significant differences with the employed statistical tests.

Informed consent and ethical aspects

All patients gave specifically their consent for the clinical interview, physical examination, standing radiograph, MRI, and arthroscopy. All personal data from the patients have been eliminated for research purposes, and confidentiality has been maintained. The local ethical committee has considered the informed consent for the patient ethically acceptable and it has also qualified the work conducted as methodologically appropriate, so the study has been approved by the committee (institutional review board [IRB]).

Weight-bearing radiographs

A standing, semi-flexed posteroanterior radiograph was obtained from all patients with the same protocol: knees flexed 7° to 10° to achieve a parallel alignment of the medial tibial plateau and the central x-ray beam (also parallel to the floor), so the anterior and posterior borders of the medial tibial plateau are not separated more than 1 mm. This measure is the most important item to reach accuracy, and a flexion of 7° to 10° is considered enough. Both feet should rotate until tibial spines are in line with the intercondylar notch of the femur. A parallel radioanatomic alignment of the medial tibial plateau is the only element of positioning that is consistently related to sensitivity in the detection of joint space narrowing in knee osteoarthritis,^{22,23} and it has been used in several clinical trials.^{24,25} We found this flexion weight-bearing position appropriate for the reproducibility and sensitivity of joint space narrowing. Conventional extension radiographs will underestimate the degree of degenerative disease. We used a manual method of joint space width measurement, which was less susceptible to be altered by technical factors.²³

These radiographs were the first study made in all cases, and they were analyzed and measured by 1 blinded observer, the main researcher, who did not know any medical information about the patients. We considered that the experience of an orthopedic surgeon was enough to analyze weight-bearing radiographs, as it is commonplace for daily study.

The following signs were investigated: osteophytes in the medial compartment, sclerosis in the subchondral bone of the medial compartment, subchondral cysts, and joint space narrowing according to Spahn criteria (patients with 4 or more of the following factors: a history of osteoarthritis for more than 2 years, obesity, smoking, tibial osteophytes, and joint space narrowing of less 5 mm are associated with a poor outcome of arthroscopy).²⁶ The Kellgren-Lawrence degree of knee osteoarthritis was determined with all these signs: osteophytes, joint space narrowing, sclerosis, and subchondral cysts (Table 1).

Magnetic resonance imaging

All knees were studied with a Siemens 1.5-T MRI scanner. The knee coil was used in all the patients. We acquired proton density (DS), T1, T2, and spin-echo sequences. The MRI scans

Table 1. Kellgren-Lawrence classification.

KELLGREN-LAWRENCE GRADE	KELLGREN-LAWRENCE DEFINITION
Grade 1—"doubtful"	Minute osteophyte, doubtful significance
Grade 2—"minimal"	Definite osteophyte, unimpaired joint space
Grade 3—"moderate"	Moderate diminution of joint space
Grade 4—"severe"	Joint space greatly impaired with sclerosis of the subchondral bone

were performed and analyzed after the weight-bearing radiographs and before arthroscopy in all cases, with an average time of 3.03 (0-12) months between weight-bearing radiographs and MRI. Only 1 patient suffered a long delay. We considered that the time delay would not affect the results. Signal intensity and changes in the medial compartment cartilage were analyzed independently by 2 blinded observers, the main researcher and a radiologist specialized in the musculoskeletal system, who had a previous calibration session. This analysis was considered blind because neither of them knew weight-bearing radiograph results. The degree of osteoarthritis was assigned to each knee according to the Vailotton score¹⁶: grade 0 (normal), I (cartilage surface intact, hyposignal or hypersignal), II (minor surface irregularities and/or focal reduction of thickness < 50%), III (noticeable surface irregularities, focal reduction of thickness > 50%), and IV (100% focal loss of thickness with or without bone reaction). The main researcher's Vailotton grade was finally used for the study because we could see in the results that the radiologist classification involved a description of a lower grade and less accuracy.

Other pathologies such as meniscal tear and anterior cruciate ligament injury were also described.

Arthroscopy

Arthroscopy was the "gold standard" diagnostic test for all patients. It was performed as an ambulatory process under spinal anesthesia and limb ischemia after an average time of 5.4 (0.5-14) months from the weight-bearing radiographs. Time delay between each diagnostic test could not be reduced because of the high demand from patients in waiting lists. We considered it was an adequate time between tests and assumed that degenerative arthritis does not undergo a relevant progression in that period as to affect the results of the study. To be able to prepare the operation correctly, arthroscopies were consecutively performed by different surgeons who knew about the preoperative tests, but they were revised intraoperatively with a blind method by an orthopedic surgeon who was the main researcher of this study. Several arthroscopic operators were involved to improve patient recruitment.

A 30° direction-of-view arthroscope with a 4 mm diameter was used. The images were recorded in video, using digital format and high definition. The diagnostic part of the procedure

was performed in a standard manner, and the main researcher probed the articular cartilage lesions and assessed the degree of the cartilage degeneration in the medial compartment intraoperatively, according to the Outerbridge classification²⁷: grade 0 (normal), I (cartilage surface intact, noticeable softening, loss of elasticity), II (cartilage surface damaged, lesion thickness < 50%), III (cartilage surface damaged, lesion thickness > 50%), and IV (exposed subchondral bone). Femoropatellar and lateral compartment diseases were described during the surgery, but this information was not included in the study. In some cases, details of surgical procedures were included in the recording.

Statistical analysis

The descriptive analysis included arithmetic mean, median, range, and standard deviation for quantitative variables, as well as absolute frequency and percentage for qualitative variables. Weight-bearing radiographs were analyzed in 2 different days, and the intra-rater correlation of Kellgren-Lawrence grade was calculated using the kappa statistic. Inter-rater correlation for MRI degrees was calculated with the kappa statistic as well, and a McNemar symmetry test analysis was added to study random influence. A total of 60 patients were involved in the inter-rater/intra-rater study, with 10 to 12 years of experience of raters. Kappa index, statistical ratio, and Wilcoxon test were used to calculate the accuracy of radiographs compared with the arthroscopic degree and accuracy of MRI compared as well with the arthroscopic degree.

In a second stage of statistical analysis, the cases were grouped and classified as “normal” (grades 0 and I of Kellgren-Lawrence, Valloton, and Outerbridge) and “pathologic” (grades II-IV of Kellgren-Lawrence, Valloton, and Outerbridge).¹⁵ These groups allowed us to calculate the sensitivity, specificity, positive and negative predictive values, and accuracy of radiographs and MRI. The analysis was repeated after an alternative mode of grouping (“normal” for grades 0-II and “pathologic” for grades III and IV) to study if it could be better. Finally, we found the first alternative more useful for the purpose of the study. It was also based in previous studies.¹⁵

Logistic regression analysis was applied to evaluate the diagnostic accuracy of isolated radiographs, isolated MRI, and the combination of both.

A receiver operating characteristic (ROC) curve is a graphical plot that illustrates the diagnostic ability of a test. The ROC curve is created by plotting the true-positive rate (also known as sensitivity) against the false-positive rate (also known as the fall-out or probability of false alarm). The ROC analysis provides tools to select possible optimal models and to discard suboptimal ones, and it is related in a direct way to the cost/benefit analysis of the diagnostic decision making. The area under the ROC curve is a measure of the usefulness of a test, where a great area means a more useful test. The area under the ROC curve was also calculated for both diagnostic techniques (radiographs and MRI) in our study.

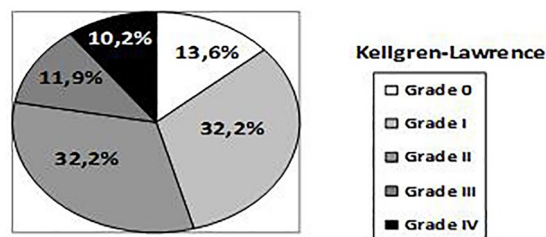


Figure 3. Distribution in grades according to Kellgren-Lawrence score (weight-bearing radiographs).

Nonparametric Spearman test was used to assess the relation between joint space width and the osteoarthritis degree in weight-bearing radiographs. In addition, cases were grouped according to articular space width (wider or narrower than 5 mm). We found it better to use an absolute value based on Spahn criteria, instead of a relative value, because the first one is related with the poor outcome of degenerative knee disease.²⁶ The Mann-Whitney *U* test was used to analyze the relation of narrowing joint space with each osteoarthritis degree according to the Kellgren-Lawrence, Valloton and Outerbridge classifications. We described Spahn criteria to study joint space narrowing as a secondary aim.

Differences were considered statistically significant when *P* values were <.05. All statistical calculations were made with the SAS 9.3 software package (SAS Institute, Cary, NC, USA).

Results

Weight-bearing radiographs

Intraobserver correlation reached a 0.95 kappa index. According to the Kellgren-Lawrence score, out of 59 studied knees, 8 (13.6%) were classified as grade 0, 19 (32.2%) as grade I, 19 (32.2%) as grade II, 7 (11.9%) as grade III, and 6 (10.2%) as grade IV (Figure 3).

Magnetic resonance imaging

The interobserver correlation leads to a 0.37 kappa index (*P* < .001). Analysis by the McNemar symmetry test established that these differences could not be explained only by random, observing a lower degree (milder classification) for the radiologist classification.

According to the Valloton classification, out of 59 studied knees, 22 (37.3%) were considered grade 0, 16 (27.1%) grade I, 11 (18.6%) grade II, and 10 (16.9%) grade III. No case was classified as grade IV (Figure 4).

Arthroscopic findings

No degenerative changes in articular cartilage were visualized in 10 knees. Out of 59 patients, 10 (16.9%) presented an Outerbridge grade 0, 25 (42.4%) grade I, 7 (11.9%) grade II, 13 (22.0%) grade III, and 4 (6.8%) grade IV (Figure 5).

No severe or important complication or secondary effect was registered after arthroscopy in the whole series.

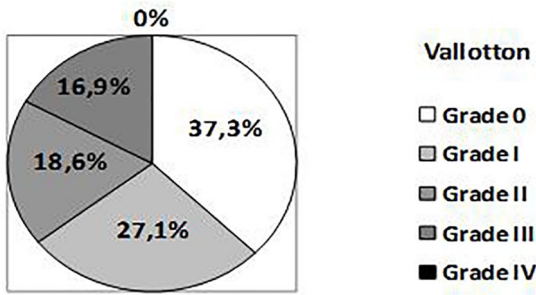


Figure 4. Distribution in grades according to Vallotton score (MRI). MRI indicates magnetic resonance imaging.

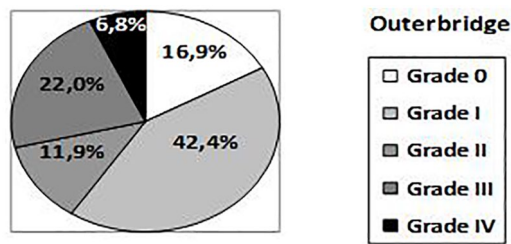


Figure 5. Distribution in grades according to the Outerbridge classification (arthroscopy).

Correlation of weight-bearing radiographs or MRI with arthroscopic findings

Establishing arthroscopy as the gold standard, the diagnostic accuracy of standing radiograph was calculated as 0.42 and that of MRI as 0.49. Wilcoxon signed rank test showed a tendency toward overdiagnosis with radiographs ($P=.25$) and significant underdiagnosis with MRI ($P=.001$). The computed kappa index was 0.25 for radiographs (0.17-0.49) and 0.33 for MRI (0.08-0.41), and this overlapping of confidence intervals made this way of comparison of both diagnostic tests difficult.

Diagnostic accuracy of weight-bearing radiographs or MRI

The sensitivity, specificity, positive and negative predictive values, and accuracy of weight-bearing radiographs and MRI for each degree of knee osteoarthritis are shown in Tables 2 and 3.

After grouping knees in “normal” (grades 0 and I) and “pathologic” (grades II-IV), a sensitivity of 75% (55%-88%) and a specificity of 60% (44%-74%) were calculated for weight-bearing radiographs, whereas the positive predictive value was 56.2% (39%-72%) and the negative predictive value was 77.8% (59%-89%); accuracy was estimated to be 66.1% (53%-80%). When alternative grouping was established (“normal” for grades 0 to II and “pathologic” for grades III and IV of Kellgren-Lawrence), the sensitivity lowered to 45.8%, the specificity increased to 94.3%, the positive predictive value also increased to 84.6%, whereas the negative predictive value lowered to 71.7%; accuracy was estimated to be 74.5% (62%-84%). These results confirm that accuracy is better when the severity of the disease increases (Table 4).

Table 2. Sensitivity, specificity, positive/negative predictive value, and accuracy of weight-bearing radiographs for each degree of knee osteoarthritis.

KELLGREN-LAWRENCE DEGREE	S (%)	E (%)	PPV (%)	NPV (%)	A (%)
I	40.0	73.5	52.6	62.5	59.3
II	28.6	67.3	10.5	87.5	62.7
III	38.5	95.7	71.4	84.6	83.1
IV	50.0	92.7	33.3	96.2	89.8

Abbreviations: A, accuracy; E, specificity; NPV, negative predictive value; PPV, positive predictive value; S, sensitivity.

Table 3. Sensitivity, specificity, positive/negative predictive value, and accuracy of MRI for each degree of knee osteoarthritis.

VALLOTTON DEGREE	S (%)	E (%)	PPV (%)	NPV (%)	A (%)
I	36.0	79.4	56.3	62.8	61.0
II	57.1	86.5	36.4	93.8	83.1
III	53.8	93.5	70.0	87.8	84.7

Abbreviations: A, accuracy; E, specificity; MRI, magnetic resonance imaging; NPV, negative predictive value; PPV, positive predictive value; S, sensitivity.

With the same methodology, a sensitivity of 70.8% (51%-85%) and a specificity of 88.6% (74%-95%) were calculated for MRI, whereas the positive predictive value was 81.0% (60%-92%) and the negative predictive value was 81.6% (67%-91%); accuracy was estimated to be 81.4% (70%-89%).

The ROC curve was 0.89 (0.81-0.97) for MRI and 0.77 (0.65-0.89) for weight-bearing radiographs ($P<.001$). A higher number of the area under the ROC curve means a more useful test, so MRI was more useful than weight-bearing radiographs with a statistically significant result in our study.

Diagnostic value of weight-bearing radiographs plus MRI

Table 4 also offers the diagnostic value when combining the findings in radiographs plus those in MRI. The sensitivity was 62.5%, the specificity was 91.4%, and the positive and negative predictive values were 83.3% and 78.0%, respectively. Accuracy was finally calculated as 79.7%. Moreover, the logistic regression analysis showed that a standing radiograph ($P=.520$) (0.38-6.72) after an MRI offered no additional diagnostic value compared with MRI alone ($P<.001$) (3.51-66.93) (Table 5).

The logistic regression analysis using the alternative grouping showed that a standing radiograph ($P=.115$) (0.69-30.31) after an MRI offered no additional diagnostic value compared with MRI alone ($P=.001$) (2.64-48.78). Confidence intervals were so wide in this case that we consider this grouping inadequate to center the study on it (Table 6).

Table 4. Sensitivity, specificity, positive/negative predictive value, and accuracy of isolated weight-bearing radiographs (alternative grouping included), isolated MRI, and radiographs plus MRI, for the diagnosis of knee osteoarthritis.

	S (%)	E (%)	PPV (%)	NPV (%)	A (%)
Weight-bearing radiographs	75.0	60.0	56.2	77.8	66.1
Weight-bearing radiographs (alternative grouping)	45.8	94.3	84.6	71.7	74.5
MRI	70.8	88.6	81.0	81.6	81.4
Weight-bearing radiograph plus MRI	62.5	91.4	83.3	78.0	79.7

Abbreviations: A, accuracy; E, specificity; MRI, magnetic resonance imaging; NPV, negative predictive value; PPV, positive predictive value; S, sensitivity.

Table 5. Logistic regression analysis of weight-bearing radiographs plus MRI, versus arthroscopy.

Dependent variable encoding.

ORIGINAL VALUE	INTERNAL VALUE
0-1	0
2-3-4	1

Categorical variable encoding.

		FREQUENCY	PARAMETER CODING
MRI Vallotton grouping	0-1	38	0.000
	2-3-4	21	1.000
Kellgren-Lawrence grouping	0-1	27	0.000
	2-3-4	32	1.000

	B	SE	WALD	DF	SIG.	EXP.	95% CI	
							LOWER	UPPER
rKELL	0.471	0.732	0.414	1	.520	1.602	0.382	6.722
rVALL	2.730	0.752	13.173	1	.000	15.327	3.510	66.933
Constant	-1.678	0.529	10.079	1	.002	0.187		

Abbreviations: CI, confidence interval; MRI, magnetic resonance imaging.

Table 6. Logistic regression analysis of weight-bearing radiographs (alternative grouping) plus MRI, versus arthroscopy.

Categorical variable encoding.

		FREQUENCY	PARAMETER CODING
MRI Vallotton grouping	0-1	38	0.000
	2-3-4	21	1.000
Kellgren-Lawrence grouping	0-1-2	46	0.000
	3-4	13	1.000

	B	SE	WALD	DF	SIG.	EXP.	95% CI	
							LOWER	UPPER
rKELL	1.520	0.965	2.480	1	.115	4.573	0.690	30.319
rVALL	2.429	0.744	10.666	1	.001	11.352	2.642	48.781
Constant	-1.601	0.434	13.600	1	.000	0.202		

Abbreviations: CI, confidence interval; MRI, magnetic resonance imaging.

Table 7. Comparison of published figures and data from this study on the diagnostic value of weight-bearing radiographs for knee osteoarthritis.

	N	S (%)	S (%) DEGREES II-IV	E (%)	E (%) DEGREES II-IV	PPV (%)	PPV (%) DEGREES II-IV	NPV (%)	A (%) DEGREES II-IV
Kijowski et al ²	125	69	–	68	–	–	–	–	–
Weidow et al ¹²	48	67-95	–	11-67	–	–	–	–	–
Fife et al ¹⁰	161	67	71	–	60	42	36	87	62.7
Duncan et al ⁹	Systematic review of 6 studies	3-95	3-71	–	60-98	–	36-57	59-87	58-63
This study	59	–	75	60	–	–	56.3	77.8	66.1

Abbreviations: A, accuracy; E, specificity; N, number of patients in series; NPV, negative predictive value; PPV, positive predictive value; S, sensitivity.

Importance of joint space narrowing

Medial joint space in weight-bearing radiographs was on average 1.82 mm narrower than lateral joint space (the mean value of medial joint line was 4.33 mm and the mean value of lateral joint space was 6.15 mm, with a difference of 1.82 mm). These results applied to only those patients who showed some medial joint space narrowing (51 patients).

Joint space width was inversely correlated with the osteoarthritis degree in weight-bearing radiographs (correlation coefficient: -0.69) ($P < .0001$), MRI (correlation coefficient: -0.47) ($P < .0001$), and arthroscopy (correlation coefficient: -0.50) ($P < .0001$).

When cases were grouped according to joint space wider or narrower than 5 mm,⁷ the Mann-Whitney U test discovered a strong statistical relation among weight-bearing radiographs ($P < .001$), MRI ($P < .005$), and arthroscopy ($P = .001$).

Discussion

Because the results after arthroscopy versus medical therapy for symptomatic knee osteoarthritis have shown no additional benefit for arthroscopic surgery,²⁸ the ability to detect chondromalacia is becoming more important.

We could summarize our most important findings as follows:

In our study, weight-bearing radiographs did not increase the diagnostic accuracy for knee osteoarthritis compared with MRI alone. As it was previously said, no results can be found in the literature about the diagnostic value of the combination of both tools compared with each technique separately.

Another important result was that weight-bearing radiographs and MRI offered better accuracy when the severity of the disease increased, as it had been described in the literature.¹⁵

Weight-bearing radiographs

Weight-bearing radiographs graded according to Kellgren-Lawrence or Ahlbäck classification continue to be the most employed procedure, but there are some discrepancies about

the usefulness of joint space width for osteoarthritis diagnosis and grading,^{7,29,30} whereas an author proposed tibial osteophytes as better indicators.² These recent studies convinced us to use the Kellgren-Lawrence instead of the Ahlbäck classification, as recommended by other authors.^{6,7} Most authors were in agreement regarding the use of radiological changes in the medial compartment,^{2,5,31} as we did.

The published sensitivity varies from 3% to 95%, and the specificity ranged from 60% to 98%^{2,9-11} (Table 7).

Our results were similar to those reported in the literature. According to all these figures, including those obtained in this study, we could conclude that weight-bearing radiographs had limited sensitivity and specificity.

Magnetic resonance imaging

When compared with arthroscopic findings, the sensitivity of MRI for diagnosing knee osteoarthritis varied from 58% to 97%, whereas the specificity was calculated to be in the range from 85% to 100%.^{15,17,32} Our figures were similar (Table 8). Accuracy was estimated as 47% to 69%,^{17,32} whereas we obtained a value of 81%. According to our data, some patients of Outerbridge grade II were underdiagnosed as grade I by MRI, as it had also been described previously.¹⁵ Other authors communicated low figures for sensitivity in milder degrees (from 20% to 94% for degrees I-III) and higher (from 77% to 100%) in the most severe degree IV,^{15,17} but improved in all cases with the 3-T equipment (instead the usual 1.5-T one used in our study). Nevertheless, the economic cost of an MRI was more than 10 times that of a standing radiograph (based on the costs in a university hospital), and this should also be taken into consideration when choosing a diagnostic tool.

Weight-bearing radiographs and MRI

We could not find any study that analyzes the diagnostic value of combining standing radiograph and MRI findings. Our results are shown in Table 3. It is clear that MRI was statistically significant ($P < .001$), but standing radiograph did not

Table 8. Comparison of published figures and data from this study on the diagnostic value of MRI for knee osteoarthritis.

	N	S (%)	E (%)	PPV (%)	NPV (%)	A (%)
Galea et al ¹⁵	100	58.8	95.3	–	–	–
Menashe ³²	Methanalysis	69	93	85	57	69
Engelhardt ¹⁷	36	–	–	–	–	47 and 57
Figuroa ³⁴	190	45	100	–	–	–
Kijowski ²	200	70.5	86	–	–	–
Quatman ¹⁸	Methanalysis	0-86	48-95	–	–	5-94
This study	59	70.8	88.6	81	81.6	81.4

Abbreviations: A, accuracy; E, specificity; N, number of patients in series; NPV, negative predictive value; PPV, positive predictive value; S, sensitivity.

increase the diagnostic value of MRI (standing radiograph represented $P = .520$, which means that the results did not add information to MRI).

Some studies^{5,33} analyzed the diagnostic value of radiographs using MRI as the “gold standard,” without arthroscopy. It could be assured that the results obtained were of less statistical and clinical value than those obtained by comparison with direct arthroscopic visualization, as relevant studies indicated that arthroscopy is the most suitable technique to value cartilage degeneration in osteoarthritis.^{17,34}

Joint space width

Usually, medial joint space is narrower than the lateral one in most osteoarthritic knees. This was measured in our patients and in other published papers.²¹

It is generally accepted that articular joint width is the best individual measure of the osteoarthritis degree^{26,30,31,35} in weight-bearing radiographs. In our study, it was also a good measure of osteoarthritis with a high clinical and radiologic correlation.

In a clinical context, we can say that weight-bearing radiographs were useful to exclude severe osteoarthritis prior to arthroscopic surgery. But MRI could diagnose the osteoarthritis degree more accurately, so it could be the only diagnostic tool used if we were just studying the osteoarthritis grade, especially for mild degrees. Weight-bearing radiographs could be added to rule out other diseases or to study some items for prosthetic surgery, for example.

Conclusions

Magnetic resonance imaging presented higher specificity, positive and negative predictive values, and accuracy than standing radiograph for knee osteoarthritis. Only sensitivity was slightly higher for weight-bearing radiographs when classes were grouped. Both diagnostic tools offered better results when the severity of the disease increased. The combination of radiographs and MRI did not increase the diagnostic accuracy for knee osteoarthritis, compared with MRI alone.

In a clinical context, it can be said that, when radiographic findings are already given, an MRI should be useful, especially to better study cases of mild osteoarthritis before arthroscopic surgery. Furthermore, if MRI has been already made, weight-bearing radiographs might not be necessary in the cases of mild osteoarthritis.

Author Contributions

Conception and design of the study: N.M.G., J.C.A. and R.M.J. Acquisition of data: N.M.G. Analysis and interpretation data: N.M.G., J.C.A. and R.M.J. Writing and editing: N.M.G. and J.C.A.

Ethical Approval and Informed Consent

The local ethical committee has considered the work submitted ethically acceptable. Written informed consent was obtained from all patients. The local ethical committee has also qualified it as methodologically appropriate. Because of all these positive evaluations, the study has been approved by the local ethical committee (IRB).

Location

This work was performed in the Orthopedic Surgery Department, La Princesa University Hospital, Autonoma University, Madrid, Spain.

ORCID iD

Nuria Muñoz-García  <https://orcid.org/0000-0002-8191-639X>

REFERENCES

- Blackburn WD, Chivers S, Bernreuter W. Cartilage imaging in osteoarthritis. *Semin Arthritis Rheum.* 1996;25:273-281.
- Kijowski R, Blankenbaker DG, Stanton PT, Fine JP, De Smet AA. Radiographic findings of osteoarthritis versus arthroscopic findings of articular cartilage degeneration in the tibiofemoral joint. *Radiology.* 2006;239:818-824.
- Koplas M, Schils J, Sundaram M. The painful knee: choosing the right imaging test. *Cleve Clin J Med.* 2008;75:377-384.
- Altman R, Asch E, Bloch D, et al. Development of criteria for the classification and reporting of osteoarthritis. Classification of osteoarthritis of the knee. Diagnostic and Therapeutic Criteria Committee of the American Rheumatism Association. *Arthritis Rheum.* 1986;29:1039-1049.

5. Amin S, LaValley MP, Guerzazi A, et al. The relationship between cartilage loss on magnetic resonance imaging and radiographic progression in men and women with knee osteoarthritis. *Arthritis Rheum.* 2005;52:3152-3159.
6. Kellgren JH, Lawrence JS. Radiological assessment of osteo-arthrosis. *Ann Rheum Dis.* 1957;16:494-502.
7. Petersson IF, Jacobsson LT. Osteoarthritis of the peripheral joints. *Best Pract Res Clin Rheumatol.* 2002;16:741-760.
8. Duryea J, Neumann G, Niu J, et al. Comparison of radiographic joint space width to MRI cartilage morphometry: analysis of longitudinal data from the Osteoarthritis Initiative. *Arthritis Care Res.* 2010;62:932-937.
9. Duncan ST, Khazzam MS, Burnham JM, Spindler KP, Dunn WR, Wright RW. Sensitivity of standing radiographs to detect knee arthritis: a systematic review of level I studies. *Arthroscopy.* 2015;31:321-328.
10. Fife RS, Brandt KD, Braunstein EM, Katz BP, Shelbourne KD, Kalasinski LA. Relationship between arthroscopic evidence of cartilage damage and radiographic evidence of joint space narrowing in early osteoarthritis of the knee. *Arthritis Rheum.* 1991;34:377-382.
11. Lysholm J, Hamberg P, Gillquist J. The correlation between osteoarthritis as seen on radiographs and on arthroscopy. *Arthroscopy.* 1987;3:161-165.
12. Weidow J, Cederlund CG, Ranstam J, Kärrholm J, Ahlbäck grading of osteoarthritis of the knee: poor reproducibility and validity based on visual inspection of the joint. *Acta Orthop.* 2006;77:262-266.
13. Hellio Le, Graverand MP, Mazzuca S, Duryea J, Brett A. Radiographic-based grading methods and radiographic measurement of joint space width in osteoarthritis. *Radiol Clin North Am.* 2009;47:567-579.
14. Vignon E, Piperno M, Hellio Le, Graverand MP, et al. Measurement of radiographic joint space width in the tibiofemoral compartment of the osteoarthritic knee: comparison of standing anteroposterior and Lyon schuss views. *Arthritis Rheum.* 2003;48:378-384.
15. Galea A, Giuffre B, Dimmick S, Coolican M, Parker D. The accuracy of magnetic resonance imaging scanning and its influence on management decisions in knee surgery. *Arthroscopy.* 2009;25:473-480.
16. Vallotton JA, Meuli RA, Leyvraz PF, Landry M. Comparison between magnetic resonance imaging and arthroscopy in the diagnosis of patellar cartilage lesions: a prospective study. *Knee Surg Sports Traumatol Arthrosc.* 1995;3:157-162.
17. Von Engelhardt LV, Lahner M, Klusmann A, et al. Arthroscopy vs. MRI for a detailed assessment of cartilage disease in osteoarthritis: diagnostic value of MRI in clinical practice. *BMC Musculoskelet Disord.* 2010;11:75.
18. Quatman CE, Hettrich CM, Schmitt LC, Spindler KP. The clinical utility and diagnostic performance of magnetic resonance imaging for identification of early and advanced knee osteoarthritis: a systematic review. *Am J Sports Med.* 2011;39:1557-1568.
19. Kijowski R, Blankenbaker DG, Davis KW, Shinki K, Kaplan LD, De Smet AA. Comparison of 1.5- and 3.0-T MR imaging for evaluating the articular cartilage of the knee joint. *Radiology.* 2009;250:839-848.
20. Wong S, Steinbach L, Zhao J, Stehling C, Ma CB, Link TM. Comparative study of imaging at 3.0 T versus 1.5 T of the knee. *Skeletal Radiol.* 2009;38:761-769.
21. Agnesi F, Amrami KK, Frigo CA, Kaufman KR. Comparison of cartilage thickness with radiologic grade of knee osteoarthritis. *Skeletal Radiol.* 2008;37:639-643.
22. Mazzuca SA, Brandt KD, Buckwalter KA, Lequesne M. Pitfalls in the accurate measurement of joint space narrowing in semiflexed, anteroposterior radiographic imaging of the knee. *Arthritis Rheum.* 2004;50:2508-2515.
23. Mazzuca SA, Brandt KD, Dieppe PA, Doherty M, Katz BP, Lane KA. Effect of alignment of the medial tibial plateau and x-ray beam on apparent progression of osteoarthritis in the standing anteroposterior knee radiograph. *Arthritis Rheum.* 2001;44:1786-1794.
24. Buckland-Wright JC. Protocols for precise radio-anatomical positioning of the tibiofemoral and patellofemoral compartments of the knee. *Osteoarthritis Cartilage.* 1995;3:71-80.
25. Buckland-Wright JC, Macfarlane DG, Williams SA, Ward RJ. Accuracy and precision of joint space width measurements in standard and macroradiographs of osteoarthritic knees. *Ann Rheum Dis.* 1995;54:872-880.
26. Spahn G, Mückley T, Kahl E, Hofmann GO. Factors affecting the outcome of arthroscopy in medial-compartment osteoarthritis of the knee. *Arthroscopy.* 2006;22:1233-1240.
27. Outerbridge RE. The etiology of chondromalacia patellae. *J Bone Joint Surg Br.* 1961;43-B:752-757.
28. Kirkley A, Birmingham TB, Litchfield RB, et al. A randomized trial of arthroscopic surgery for osteoarthritis of the knee. *N Engl J Med.* 2008;359:1097-1107.
29. Brandt KD, Fife RS, Braunstein EM, Katz B. Radiographic grading of the severity of knee osteoarthritis: relation of the Kellgren and Lawrence grade to a grade based on joint space narrowing, and correlation with arthroscopic evidence of articular cartilage degeneration. *Arthritis Rheum.* 1991;34:1381-1386.
30. Buckland-Wright JC, Bird CF, Ritter-Hrncirik CA, et al. X-ray technologists' reproducibility from automated measurements of the medial tibiofemoral joint space width in knee osteoarthritis for a multicenter, multinational clinical trial. *J Rheumatol.* 2003;30:329-338.
31. Raynauld JP, Martel-Pelletier J, Berthiaume MJ, et al. Quantitative magnetic resonance imaging evaluation of knee osteoarthritis progression over two years and correlation with clinical symptoms and radiologic changes. *Arthritis Rheum.* 2004;50:476-487.
32. Menashe L, Hirko K, Losina E, et al. The diagnostic performance of MRI in osteoarthritis: a systematic review and meta-analysis. *Osteoarthritis Cartilage.* 2012;20:13-21.
33. Reichenbach S, Guerzazi A, Niu J, et al. Prevalence of bone attrition on knee radiographs and MRI in a community-based cohort. *Osteoarthritis Cartilage.* 2008;16:1005-1010.
34. Figueroa D, Calvo R, Vaisman A, Carrasco MA, Moraga C, Delgado I. Knee chondral lesions: incidence and correlation between arthroscopic and magnetic resonance findings. *Arthroscopy.* 2007;23:312-315.
35. Bruyere O, Genant H, Kothari M, et al. Longitudinal study of magnetic resonance imaging and standard X-rays to assess disease progression in osteoarthritis. *Osteoarthritis Cartilage.* 2007;15:98-103.