



Revision Achilles Tendon Repair Using Posterior Tibial Tendon Allograft and Flexor Hallucis Longus Transfer

Joseph Meter, D.O., Randa Bascharon, D.O., Ajit Amesur, D.O., Shivali Gupta, D.O., Daniel Arias, D.O., Taylor Anthony, B.S., and Victor Hoang, D.O.

Abstract: Achilles tendon ruptures are common injuries seen by orthopaedic surgeons. A myriad of surgical options have been used in the management of Achilles tendon ruptures, but currently no gold standard exists. Re-rupture of Achilles tendon injuries occurs 1.7% to 5.6% of the time, and there has been no direct relationship demonstrated between complications and repair techniques used. The aim of this technique is to provide a method of fixation for the patient with an Achilles tendon re-rupture that provides a stable repair construct and mitigates the potential sequela of re-rupture. We describe the treatment of an Achilles tendon re-rupture with the use of a flexor hallucis longus tendon transfer and posterior tibial tendon allograft for repair of an 8.5 cm tendon gap.

Achilles tendon ruptures are one of the most common orthopaedic injuries, with recent studies indicating a rate of 7 to 40 per 100,000 patient-person years.¹ There is currently no gold standard for repair of these injuries, and treatment is largely dictated by the individual surgeon's preference. The 2 most common techniques include open repair and percutaneous repair. In addition, postoperative complications play a role in treatment selection, with open repair techniques having a higher risk of superficial and deep tissue infection and percutaneous repair reporting higher rates of sural nerve injury.² Re-rupture of Achilles tendon injuries occurs

1.7% to 5.6% of the time, and there has been no direct relationship demonstrated between complications and repair techniques used.^{1,2} It has been noted in the literature that patients with Achilles tendon re-rupture have worse patient-reported outcomes and may have long-term functional deficits when compared to patients with primary rupture.² Therefore these patients pose a unique and important challenge for the orthopaedic surgeon with regard to treatment. The aim of this technique is to provide a method of fixation for the patient with an Achilles tendon re-rupture that provides a stable repair construct and mitigates the potential sequela of re-rupture.

For this technique article, we describe the treatment of an Achilles re-rupture with the use of a flexor hallucis longus (FHL) tendon transfer and posterior tibial tendon (PTT) allograft for repair of an 8.5 cm tendon gap.

Surgical Technique

Indications

This technique is indicated for Achilles tendon revisions including re-ruptures with a large tendon gap or poor quality tendon edges that may not be amenable to standard repair.

Materials

The technique uses the following items: 3.2 mm and 7 mm drill bits, Stryker power drill, two 7.5 mm SwiveLock suture anchors (Arthrex, Naples, FL), Endobutton (Arthrex), no. 2 FiberTape (Arthrex), FHL autograft harvested from patient, PTT allograft, suture

From Valley Hospital Medical Center (J.M., R.B., A.A., S.G., D.A., V.H.), Las Vegas, Nevada; the Orthopedic & Sports Medicine Institute of Las Vegas (R.B.), Las Vegas, Nevada; the Touro University Nevada College of Osteopathic Medicine (T.A.), Henderson, Nevada; and Mass General Brigham Sports Medicine—Brigham and Women's Hospital (V.H.), Boston, Massachusetts, U.S.A.

The authors report that they have no conflicts of interest in the authorship and publication of this article. Full ICMJE author disclosure forms are available for this article online, as [supplementary material](#).

Received October 20, 2021; accepted November 8, 2021.

Address correspondence to Victor Hoang, D.O., Valley Hospital Medical Center, 620 Shadow Lane, Las Vegas, NV 89106, U.S.A. E-mail: Hoangorthopedics@gmail.com

© 2021 THE AUTHORS. Published by Elsevier Inc. on behalf of the Arthroscopy Association of North America. This is an open access article under the CC BY-NC-ND license (<http://creativecommons.org/licenses/by-nc-nd/4.0/>).

2212-6287/211501

<https://doi.org/10.1016/j.eats.2021.11.001>

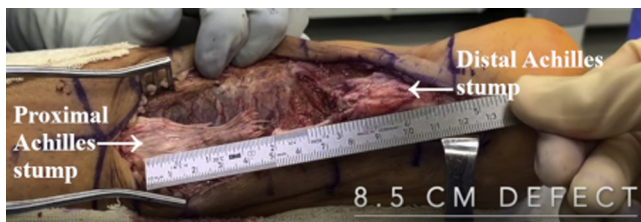

Fig 1. Intraoperative image of the right foot and ankle from a posteromedial viewpoint. After debridement, the final tendon gap is measured between proximal and distal Achilles stumps.

passer, straight needle, needle driver, and suture scissors.

Patient Positioning

The patient is placed in the prone position with bony prominences padded. A well-padded thigh tourniquet is placed on the operative side and inflated to 300 mm Hg. The operative lower extremity is prepped and draped in the usual sterile fashion.

Surgical Approach

Because this is a revision technique, the patient's previous incision is used, which in our patient was located slightly medial to the midline (Video 1). The incision is extended proximally and distally to the level of the calcaneal tuberosity. Full-thickness flaps including skin and subcutaneous tissue are then carefully elevated for full exposure of the tendon. Care is taken to protect the sural nerve during the approach, which crosses from proximal and medial to distal and lateral.

Tendon Inspection and Debridement

The previous repair site is evaluated to assess the extent of injury the patient sustained. On inspection, it was discovered in our patient that the prior lateral suture anchor had become displaced from the bone. The medial and lateral suture anchors were then removed to facilitate complete evaluation of the native tendon's integrity. Poor tissue quality at the tendon edges with

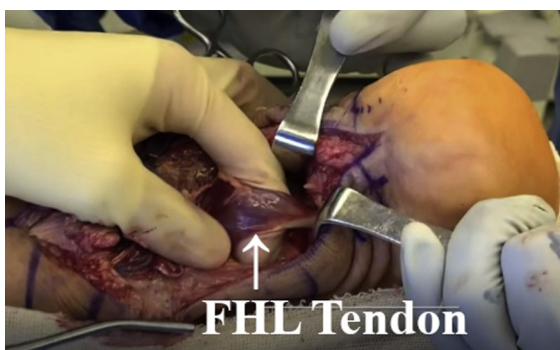


Fig 2. Intraoperative image of the right foot and ankle from a posteromedial viewpoint. After incision of the Achilles tendon sheath floor, the flexor hallucis longus tendon is identified.

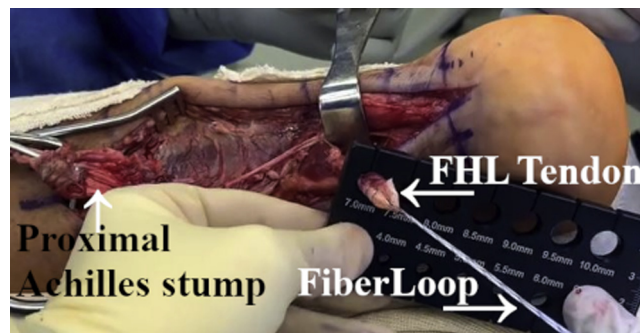


Fig 3. Intraoperative image of the right foot and ankle from a posteromedial viewpoint. After flexor hallucis longus tenotomy, the tendon is whipstitched and prepared using the Arthrex FiberLoop system (Arthrex, Naples, FL).

tendon gapping was noted. The tendon is then debrided, and the final gap is measured. In our patient, the gap was 8.5 cm in the Achilles tendon (Fig 1). Given the significant defect, the decision was made to augment with an FHL tenodesis and the PTT allograft.

FHL Harvest and Preparation

The floor of the Achilles tendon sheath is sharply incised to expose the FHL using the same incision. The FHL is then identified and the sheath is incised opening the tendon sheath (Fig 2). Tension is then placed on the FHL to achieve adequate length of the graft and complete tenotomy is performed in a decisive fashion distally at the level of the ankle joint. This is then prepared using the Arthrex FiberLoop system in a locking fashion (Fig 3).

FHL Tunnel Preparation

The Arthrex Endobutton system is used for FHL autograft augmentation of the Achilles tendon. A 3.2 mm bicortical tunnel is drilled under fluoroscopic guidance from the superior aspect of the calcaneal

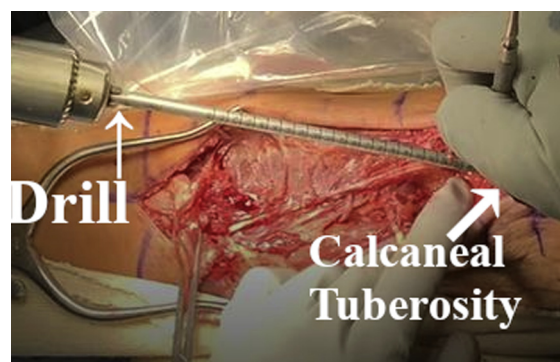

Fig 4. Intraoperative image of the right foot and ankle from a posteromedial viewpoint. The Arthrex Endobutton system (Arthrex, Naples, FL) is prepared by drilling a 3.2 mm bicortical tunnel from the superior aspect of the calcaneal tuberosity extending distally into the non-weightbearing surface of the calcaneus inferiorly. Overdrilling to create a 7 mm unicortical tunnel is then performed.

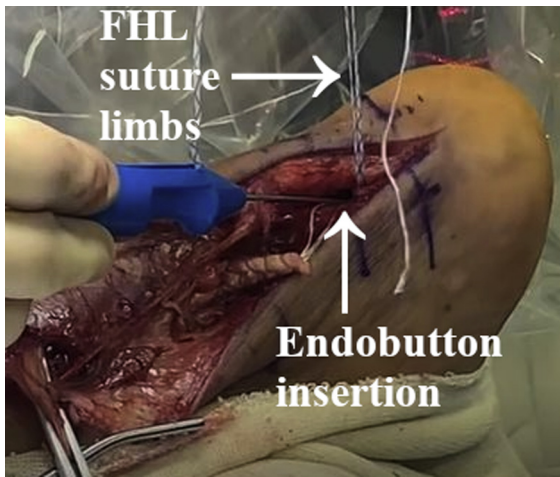


Fig 5. Intraoperative image of the right foot and ankle from a posteromedial viewpoint. The Endobutton (Arthrex, Naples, FL) is inserted into the previously drilled calcaneus hole while tension is applied to the suture limbs.

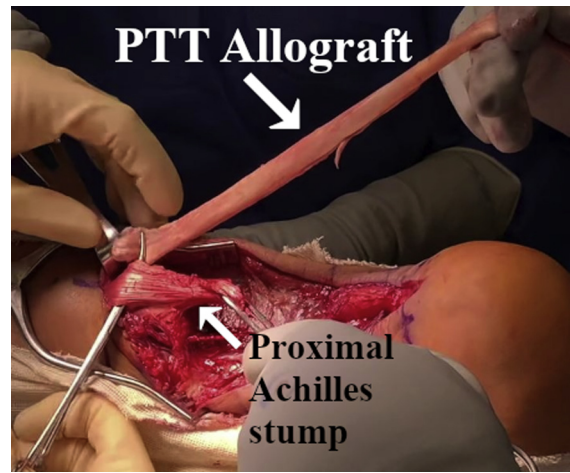


Fig 6. Intraoperative image of the right foot and ankle from a posteromedial viewpoint. The posterior tibial tendon allograft is passed through the proximal Achilles stump in a transverse lateral to medial direction.

tuberosity extending distally into the non-weightbearing surface of the calcaneus inferiorly. This track is then overdrilled using a 7 mm unicortical tunnel measuring 25 mm in length over the guide pin to facilitate tendon docking (Fig 4). The tunnel is then copiously irrigated along with the wound to remove bone dust and fragments.

FHL Tendon Tenodesis

Tension is held on all suture limbs of the FHL while the tip of the Endobutton is inserted into the previously drilled hole in the calcaneus (Fig 5). The ankle is dorsiflexed 10° to 15° to maintain tension on the FHL tenodesis during insertion (Table 1). The free suture limbs are pulled gently in a rocking fashion to set the Endobutton. Fluoroscopic guidance is used to confirm

that the Endobutton is deployed. The suture limbs are then grasped and the FHL tendon is tensioned inside the tunnel.

PTT Allograft Augmentation

Attention is now turned to the proximal and distal stumps of the gap site in the Achilles tendon. A posterior tibial tendon allograft is then shuttled through the proximal stump in a transverse lateral to medial direction and shuttled again through the distal stump from lateral to medial (Fig 6 and 7). The allograft is used to create a loop using the graft edges on the medial side of the repair site (Fig 8). The loop is secured using a Bunnell running suture technique using no. 2 Arthrex FiberTape (Fig 9). The suture is then continued distally and proximally, securing the looped allograft tendon

Table 1. Pearls and Pitfalls

Step	Pearl	Pitfall
Adequately debride the tendon edges to expose healthy tissue	Provides durable tissue for repair with good blood supply	Failure to adequately debride may result in failure of repair and increases risk of postoperative infection.
Harvest the FHL tendon through the same incision	Harvesting under tension yields a longer, more suitable autograft to be used. Using the same incision decreases potential for morbidity from multiple incisions.	Failure to maintain tension may result in an autograft that is inadequate to address large gaps, further complicating the procedure.
Drill the calcaneal tunnel such that the drill exits on the non-weightbearing portion of the calcaneus	Template with the drill on fluoroscopy before drilling to ensure the drill will exit on the non-weightbearing portion.	May lead to symptomatic hardware with weight bearing and possible skin breakdown and wound complications, resulting in failure of revision.
Docking of the FHL tendon	Maintain dorsiflexion of the foot when tensioning the graft.	Inadequate tensioning can result in overtightening of the tendon and altered foot mechanics after surgery.
Augmentation of the repair with PTT allograft	Alternate sides when suturing the tendon to ensure even tension on both sides of the graft and repair site and avoid tendon bunching.	Mismatched tension can predispose to altered gait mechanics and potential for repair failure. Tendon bunching increases risk for adhesions.

FHL, flexor hallucis longus; PTT, posterior tibial tendon.

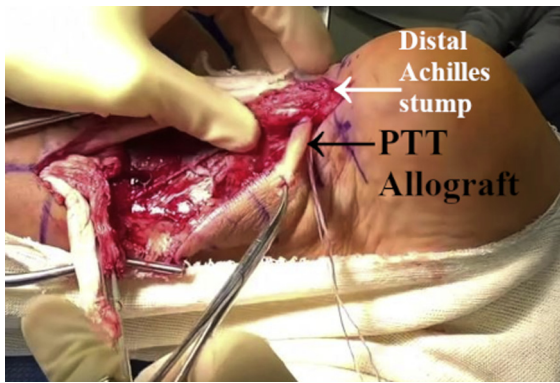


Fig 7. Intraoperative image of the right foot and ankle from a posteromedial viewpoint. After passing through the proximal Achilles stump, the posterior tibial tendon allograft is passed through the distal Achilles stump in a transverse lateral to medial direction.

with the native proximal and distal Achilles tendon stumps (Fig 10). Additional sutures from the FHL tenodesis Endobutton are then used to provide additional security, as well as aid in biologic integration to the PTT allograft using a Bunnell technique (Fig 11). These are then tied proximally.

Wound Closure

The tourniquet is released before closure and the wound irrigated with 500 mL of chlorhexidine saline solution. The wound is then closed in a multiple lateral fashion using 2-0 Vicryl and 2-0 Prolene. A sterile dressing and well-padded posterior splint in approximately 15° of plantarflexion are then applied.

Postoperative Protocol

During the immediate postoperative period, the patient is kept non-weightbearing to the operative extremity. At 4 weeks, the patient is transitioned into a controlled ankle movement walker boot with a heel insert.

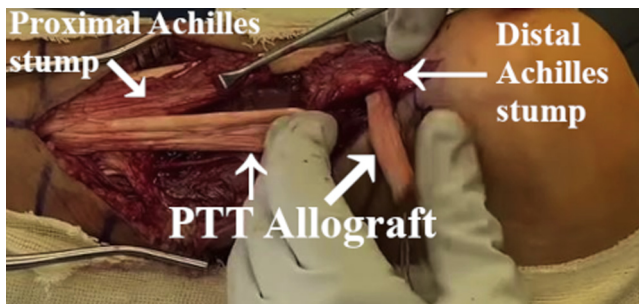


Fig 8. Intraoperative image of the right foot and ankle from a posteromedial viewpoint. On the medial aspect of the repair site, the edges of the posterior tibial tendon allograft are used to create a loop.

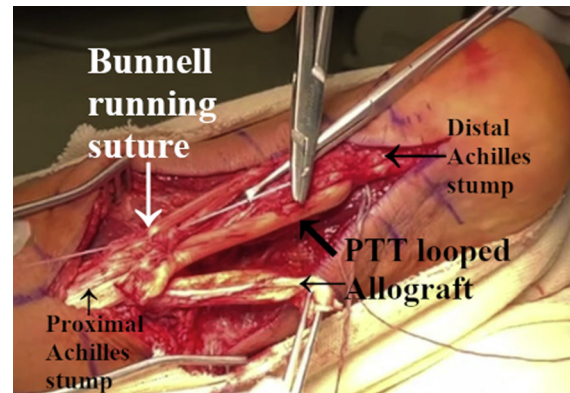


Fig 9. Intraoperative image of the right foot and ankle from a posterior viewpoint. The posterior tibial tendon allograft loop is secured by using no. 2 Arthrex FiberTape (Arthrex, Naples, FL) in a Bunnell running suture technique.

Discussion

Achilles tendon ruptures are common injuries seen by orthopaedic surgeons. A myriad of surgical options have been used in the management of Achilles tendon ruptures, but currently no gold standard exists.¹ Historically, nonoperative treatment was thought to be associated with higher rates of rerupture.³ However, newer data have shown that there is no difference in re-rupture rates in patients managed with functional rehabilitation.³ Still, treatment many times is based on patient and surgeon preference. Currently in difficult cases with poor-quality tendon edges and tendon gapping, autograft or allograft augmentation is often necessary to improve vascularity for healing in an already hypovascular tendon environment. A myriad of various tendon transfers have been used for augmentation with the FHL tendon autograft being preferred by most surgeons.⁴ Revision repair of a re-ruptured tendon presents a complicated situation for the orthopaedic surgeon and to date no gold standard treatment has been developed.^{5,6}

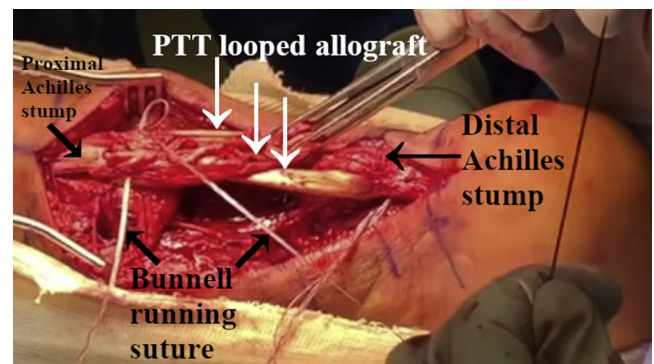


Fig 10. Intraoperative image of the right foot and ankle from a posteromedial viewpoint. The Bunnell running suture is advanced proximally and distally to secure the posterior tibial tendon looped allograft with the proximal and distal Achilles stumps.

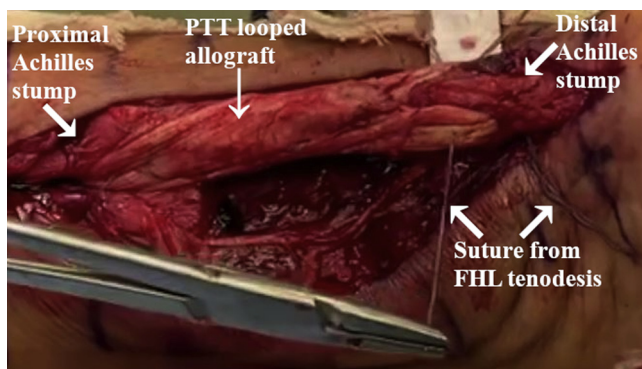


Fig 11. Intraoperative image of the right foot and ankle from a posteromedial viewpoint. To aid in further integration of the posterior tibial tendon allograft, sutures from the flexor hallucis longus tenodesis Endobutton (Arthrex, Naples, FL) are used using a Bunnell technique.

Given the history of success in orthopaedic literature with FHL transfer in primary rupture cases with extensive tendon gapping, we hypothesized that additional augmentation with an allograft would present a reasonable option to mitigate difficulties associated with this injury, such as tendon gapping, poor quality tissue, and a hypovascular environment. The main advantage of the use of a PTT allograft is that native anatomy is preserved through use of a tendon that in situ works in concert with the Achilles tendon and experiences similar loads. Possible disadvantages include loose improper tensioning that could lead to altered propulsion mechanics. There is also potential for over-tightening the allograft, which could lead to an unwanted varus deformity (Table 2). To our knowledge, there are no biomechanical studies evaluating the PTT in comparison to the Achilles. However, PTT allografts have been successfully used in cases of flatfoot deformity reconstruction, enabling patients to tolerate loading during gait, albeit with slightly altered mechanics.^{7,8} Although many techniques exist for primary repair of Achilles tendon ruptures, literature is lacking in cases of revision Achilles repair or reconstruction. Therefore the goal of our technique was to present surgeons with a technique that mitigates the difficulties of revision Achilles tendon surgery while enabling patients to avoid long-term functional sequela of re-rupture.

Table 2. Advantages and Disadvantages

Advantages

1. Repair option for large tendon gaps not amenable to VY tendon plasty
2. Preserves native anatomy that would otherwise be disturbed if augmentation needed in addition to FHL harvest
3. Endobutton allows postoperative radiographic assessment of fixation construct where anchors would not
4. PTT allograft acts as a checkrein in the event of FHL tendon failure and vice versa
5. No cosmetic difference compared to other revision techniques
6. Tension in tendons can be adjusted as desired

Disadvantages

1. Potential for immunologic reaction from allograft
2. Potential for loose improper tensioning leading to altered propulsion mechanics
3. Potential for over tightening leading to varus deformity
4. Inexperienced surgeons may need additional time to learn new technique, which initially lengthens surgical time
5. Healing time increased with allograft
6. Technically demanding procedure

FHL, flexor hallucis longus; PTT, posterior tibial tendon.

References

1. Lemme NJ, Li NY, DeFroda SF, Kleiner J, Owens BD. Epidemiology of Achilles tendon ruptures in the United States: athletic and nonathletic injuries from 2012 to 2016. *Orthop J Sports Med* 2018;6:2325967118808238.
2. Park S-H, Lee HS, Young KW, Seo SG. Treatment of acute Achilles tendon rupture. *Clin Orthop Surg* 2020;12:1-8.
3. Soroceanu A, Sidhwa F, Aarabi S, Kaufman A, Glazebrook M. Surgical versus nonsurgical treatment of acute Achilles tendon rupture. *J Bone Joint Surg Am* 2012;94:2136-2143.
4. Karnovsky SC, Drakos MC. Revision Achilles reconstruction with hamstring autograft and FHL tendon transfer in an athlete. *HSS J* 2017;13:302-306.
5. Rahm S, Spross C, Gerber F, Farshad M, Buck FM, Espinosa N. Operative treatment of chronic irreparable Achilles tendon ruptures with large flexor hallucis longus tendon transfers. *Foot Ankle Int* 2013;34:1100-1110.
6. Mahajan RH, Dalal RB. Flexor hallucis longus tendon transfer for reconstruction of chronically ruptured Achilles tendons. *J Orthop Surg Hong Kong* 2009;17:194-198.
7. Dominick DR, Catanzariti AR. Posterior tibial tendon allograft reconstruction for stage II adult acquired flatfoot: a case series. *J Foot Ankle Surg* 2020;59:821-825.
8. Sung I-H, Lee S, Otis JC, Deland JT. Posterior tibial tendon force requirement in early heel rise after calcaneal osteotomies. *Foot Ankle Int* 2002;23:842-849.