

Received: 2020.10.26

Accepted: 2020.12.29

Available online: 2021.01.12

Published: 2021.03.10

# High-Resolution Magnetic Resonance Imaging (HR-MRI) Imaging Characteristics of Vertebral Artery Dissection with Negative MR Routine Scan and Hypoperfusion in Arterial Spin Labeling

**Authors' Contribution:**

Study Design A  
Data Collection B  
Statistical Analysis C  
Data Interpretation D  
Manuscript Preparation E  
Literature Search F  
Funds Collection G

BCDEG **Yonggang Zhang\***  
CDEG **Chongchang Miao\***  
ACDF **Yan Gu**  
BD **Shunbin Jiang**  
ABC **Jian Xu**

Department of Radiology, The First People's Hospital of Lianyungang, Xuzhou Medical University, Lianyungang, Jiangsu, P.R. China

\* Yonggang Zhang and Chongchang Miao contributed equally to this work and should be considered co-first authors

Yan Gu, e-mail: 13815617997@139.com

**Corresponding Author:**

**Source of support:**

This study received funding from the General Scientific Research Project of Lianyungang Municipal Health Commission (201901)

**Background:** Unruptured vertebral artery dissection (VAD) that causes ischemic infarction may require anticoagulant therapy or other treatments. However, anticoagulation therapy is not recommended for patients without ischemic infarction. To date, there has been no research on the imaging characteristics of patients with ischemic hypoperfusion that have a negative routine MRI scan.


**Material/Methods:** Patients with suspected VAD were recruited between June 2015 and June 2020 in order to perform high-resolution magnetic resonance imaging (HR-MRI). In total, 26 patients with negative MRI routine scans that underwent arterial spin labeling (ASL) examination were included in the study. The patients were divided into the hypoperfusion group and normal group based on whether hypoperfusion was found in ASL. The clinical features and HR-MRI features between these 2 groups were analyzed.

**Results:** There were no statistical differences between the hypoperfusion group and normal group based on the patient's clinical characteristics ( $P > 0.05$ ). According to imaging characteristics between the 2 groups, the effective lumen index and the vertebrobasilar artery minimum angle were statistically significant ( $P < 0.001$ ). Therefore, a vertebrobasilar artery minimum angle  $< 90^\circ$  was negatively correlated to the posterior circulation ischemia hypoperfusion, with a correlation coefficient of  $-0.686$ . The effective lumen index was also negatively correlated to the posterior circulation ischemia hypoperfusion, with a correlation coefficient of  $-0.671$ . However, the location of the dissection and other HR-MRI characteristics were not statistically significant between these 2 groups ( $P > 0.05$ ).

**Conclusions:** The hypoperfusion of posterior circulation ischemia caused by VAD is related to the effective lumen index, as well as the vertebrobasilar artery minimum angle.

**Keywords:** Ischemia • Magnetic Resonance Imaging • Vertebral Artery Dissection

Full-text PDF: <https://www.medscimonit.com/abstract/index/idArt/929445>

 3418

 2

 3

 26



## Background

Arterial dissection refers to the intramural hematoma caused by a tear of the vascular intima or a rupture of the nourishing blood vessel, which is located either under the intima or adventitia. The former can lead to a secondary onset of vascular stenosis and occlusion, while the latter can easily cause lumen dilation [1]. Cervicocerebral artery dissection (CAD) is an important cause of ischemic stroke among young and middle-aged people in Asia [2]. Owing to a lack of specificity of clinical manifestations, a diagnosis of arterial dissection largely depends on imaging examination. Despite the fact that digital subtraction angiography (DSA) is regarded as the criterion standard for diagnosing intracranial vascular disease, the condition of the vessel wall itself cannot be observed. Hence, its diagnostic value for artery dissection with a normal lumen or non-specific stenosis or occlusion is limited [3]. Based on this, researchers recommend the application of arterial wall combined with luminal imaging technology to diagnose arterial dissection, and have pointed out that the diagnosis of dissection disease requires evidence of intramural hematoma or characteristics of dynamic imaging changes [4,5]. As a multi-parameter imaging sequence with ideal tissue contrast and spatial resolution, high-resolution magnetic resonance imaging (HR-MRI) is not only able to obtain luminal morphology information, but more importantly, the characteristic intramural hematoma, intimal flap, and double-lumen sign caused by arterial dissection can be directly visualized through wall imaging [6,7]. Therefore, HR-MRI is recommended as the first choice for diagnosing arterial dissection [4,8].

The specific etiology of CAD is currently unknown. The susceptibility factors based on epidemiology include hypertension, migraine, history of trauma, and recent infection [9]. In recent years, an increasing number of studies have concluded that most dissections tend to have a benign course. It has been recommended that patients with milder symptoms of unruptured dissection should be treated conservatively first and then followed up with imaging on a regular basis. Conservative treatment includes observation of mild symptoms or symptomatic treatment, treatment of acute stroke, and preventive treatment of recurrent ischemic stroke. According to the literature, for patients with ischemic symptoms without evidence of intracranial ischemia, the use of antiplatelet drugs or anticoagulants is controversial. Although these drugs can effectively prevent thrombotic occlusion or distal emboli, they can promote progression of dissection, which exacerbates ischemic symptoms and can cause rupture of aneurysm [10]. In some patients, despite the fact that MRI routine scans show normal manifestations, it does not necessarily mean that there is no intracranial ischemia focus in the brain. Arterial spin labeling (ASL) is a perfusion technique that does not require a contrast agent. It uses its own intravascular water molecules

as an endogenous tracer, which can non-invasively and safely assess brain tissue blood perfusion, and can more objectively display intracranial ischemia than conventional MRI scans. At present, this technology has been widely used to assess blood perfusion in cerebrovascular and tumor diseases. Some patients have ischemia hypoperfusion but MRI plain scan can still be normal and there has not been a research report on how to treat these patients. Among CAD, vertebral artery dissection (VAD) is the most common. This study attempted to analyze the clinical and vascular wall morphological characteristics of patients with VAD who were negative on MRI routine scan but may show ischemic hypoperfusion in order to explore meaningful indicators that can guide the clinical treatments in a correct and individualized manner.

## Material and Methods

### Research Subjects

This study protocol was approved by the Ethics Committee of our hospital (201506002). All patients included in the study signed informed consent prior to undergoing HR-MRI examination. From June 2015 to June 2020, patients ages 18-50 years old with suspected CAD were consecutively recruited from the Department of Neurosurgery at our hospital. The baseline clinical data of patients, including sex, age, hypertension, smoking history, clinical manifestations, and time of onset, were recorded. After diagnosis, all patients underwent anticoagulation therapy or symptomatic conservative treatment based on imaging manifestations and clinical symptoms. The follow-up visit for recovery was carried out 1 month after treatment.

Specific inclusion criteria included:

1. The patient was age 18-50 years old.
2. The patient presented with headache, neck tear-like pain, and other clinical symptoms of suspected VAD.
3. MRI routine scan was negative.
4. Completed HR-MRI and ASL.

Exclusion criteria included:

1. HR-MRI found vertebral basilar artery plaque or vasculitis, vasospasm and other arterial stenosis diseases.
2. Treated VAD, bilateral dissection, or dissection with other arteries.
3. Patients who had undergone HR-MRI for more than 7 days.
4. Patients with blurred image which cannot meet the diagnosis requirements.

### Image Inspection

The all-digital magnetic resonance scanner (Philips Ingenia 3.0T) was used for scanning. Patients were required to keep their

head still during the scan. All patients underwent head MRI plain scan and three-dimensional time-of-flight (3D-TOF) MRA first. Patients who were negative on the MRI plain scan underwent 3D-ASL. Two phases (PLD 1.5s and PLD 2.5s) of 3D-ASL were acquired. According to the original axial image of 3D-TOF-MRA, the location was conducted along the long axis of the blood vessel, and the coronal scan of HR-MRI was carried out at a thickness of 1 mm. The scanning sequence and parameters of HR-MRI included: (1) T1WI VISTA, TR/TE 800 ms/70 ms, FOV 160 mm×160 mm, thickness 1 mm, matrix 272×271; (2) T2WI VISTA, TR/TE 1800 ms/236 ms, FOV 160 mm×160mm, thickness 1 mm, matrix 276×271. T1WI VISTA coronal scanning was adopted for enhanced sequences, with an intravenous injection of 10% Gd.DTPA. A dose of 0.2 ml/kg body weight was used, and the flow rate of manual injection into the median cubital vein was approximately 1.5-3 ml/s. At 5 min after injection, the enhanced scanning was carried out and the catheter was flushed using 50 ml of normal saline.

### Diagnostic Criteria for VAD

HR-MRI showed indications of intra-vertebral artery hematoma (high signal of the crescent around the artery on T1WI), intimal flap, or double-lumen signs, all of which suggest VAD [11-13].

HR-MRI images of each patient were analyzed and diagnosed by 2 independent neuroradiologists with substantial experience in analysis. Both neuroradiologists were blinded to patient clinical information. When encountering divergent diagnoses for the same patient, the final decision was made after consultation with the entire imaging department.

The Likert scale [14] was used to classify image quality, and the image was scored from 1 to 5 points. Images with a score  $\leq 3$  points were discarded. The scoring standards included:

- 5 points. The image was very clear without the presence of any artifacts. The boundary of the lumen and vessel wall, as well as the periphery of the vessel wall, was clearly distinguishable.
- 4 points. The image was clear with few image artifacts. The boundaries of the lumen and the vessel wall, and periphery of the vessel wall were clearly distinguishable.
- 3 points. The image was generally clear with artifacts and boundary of the lumen and vessel wall. The periphery of the vessel wall was not clearly displayed.
- 2 points. The image quality was poor with too many artifacts. The boundary between lumen and vessel wall was still distinguishable, while outer circumference of the vessel wall was blurred.
- 1 point. The image quality was very poor. The lumen and the vessel wall boundary, and the vessel wall periphery were all blurred.

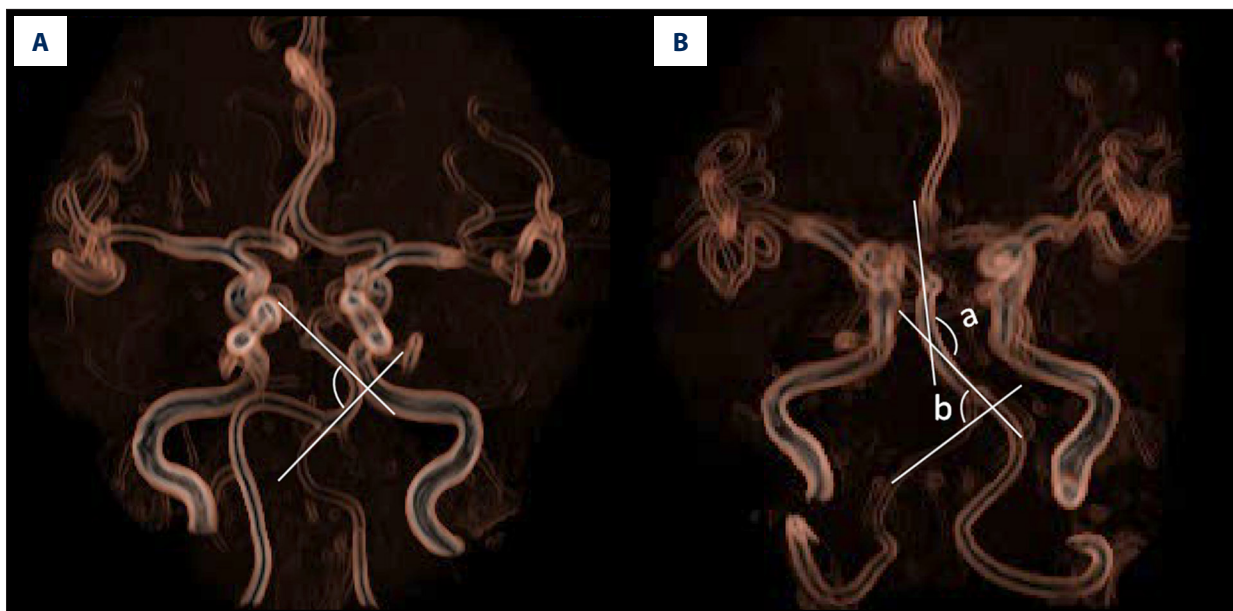
### Relevant Clinical Risk Factors and Research Index Definitions

The demographic characteristics, vascular-related risk factors, and clinical manifestations of enrolled patients were collected. The risk factors include:

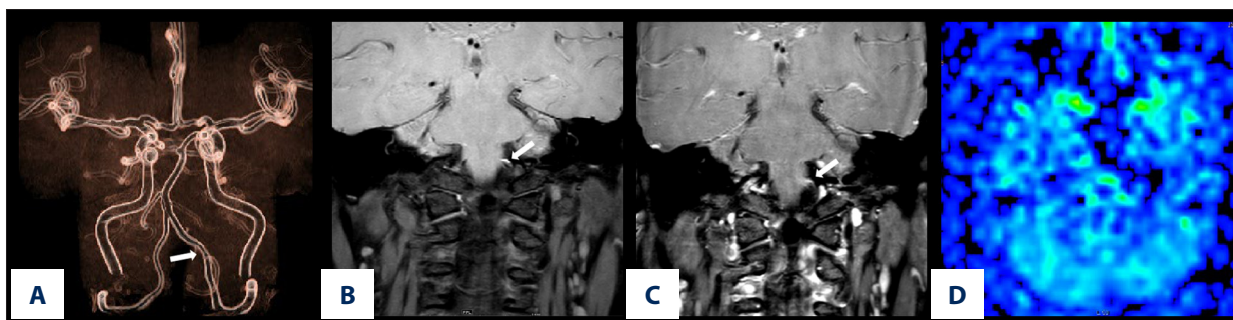
- Essential hypertension, which is defined as systolic blood pressure  $\geq 140$  mmHg and/or diastolic blood pressure  $\geq 90$  mmHg, or taking antihypertensive drugs.
- Diabetes, which is defined as fasting blood glucose  $\geq 7.0$  mmol/L, blood glucose 2 h after meal  $\geq 11.1$  mmol/L, or receiving hypoglycemic therapy.
- Hypercholesterolemia, which is defined as total cholesterol value  $\geq 5.20$  mmol/L or taking cholesterol-lowering drugs.
- Smoking history, including smoking  $\geq 1$  cigarette per day for a duration of  $\geq 3$  months, unless smoking was stopped for  $\geq 2$  years.
- Drinking history, defines as consumption of alcohol  $\geq 100$  grams per day for more than 2 years.
- Recent history of infection, including any infections that occurred within 1 month prior to enrollment, including infections of respiratory tract and digestive system.
- History of minor trauma, including neck massage, ball games, sports, roller coasters, childbirth, coughing, and sneezing.
- Angle of basilar arterial curvature (**Figure 1A**), designed as the angle formed by the 2 sides of the basilar arterial curvature toward the midline.
- The minimum bending angle of the distal intracranial segment of the vertebral basilar artery of the dissection lesion (hereinafter referred to as vertebrobasilar artery minimum angle). We took the minimum angle of the distal basilar artery or the V4 segment of the vertebral artery in the dissection lesion (**Figure 1B**). The bending angle of the basilar artery is the same as above, while the bending angle of the vertebral artery V4 segment is the minimum angle that could be formed using 2 sides of the vertebral artery V4 segment of the distal segment of the dissection disease.
- The effective lumen index is calculated by the inner diameter of the lumen at the narrowest part of the dissection/ the inner diameter of the normal lumen at the proximal end of the heart.
- ASL hypoperfusion, including when PLD=1.5s, compared to the contralateral side, the perfusion signal in the posterior circulation area on the affected side was reduced, which was diagnosed as hypoperfusion.

### Statistical Analysis

Data analysis was performed using the SPSS16.0 software. Depending on whether hypoperfusion occurred in ASL, VAD was divided into either the ASL hypoperfusion or the normal group. Measurement data presented normal distribution, which



**Figure 1.** (A) is a schematic diagram to measure the bending angle of the basilar artery. The arrow indicates the angle formed by 2 sides of the basilar artery curvature toward the midline. (B) is a schematic diagram to measure the vertebrobasilar artery minimum angle. Take the smallest angle of the distal base artery or the V4 segment of the vertebral artery in the dissection lesion. The vertebral-basilar artery at the distal end of the dissection lesion formed 2 angles, which were the basilar artery bending angle and the vertebral artery bending angle. The vertebral artery angle was 85°, while the basilar artery bending angle was 135°. Therefore, the vertebrobasilar artery minimum angle was 85°.



**Figure 2.** The left vertebral artery V4 proximal dissection images of a 45-year-old male patient with dizziness for 3 days. (A) Is an MRA image. It can be seen that the vertebrobasilar artery minimum angle in this case is the basilar artery bending angle, which was measured to be approximately 135°. (B) Is a T1 VISTA scan image, which shows an eccentric crescent-shaped high signal at the proximal end of the left vertebral artery. (C) Is a punctate enhancement of the vessel wall after T1VISTA-enhancement. (D) Is an ASL image, and the manifestation of hypoperfusion in posterior circulation area on both sides is invisible.

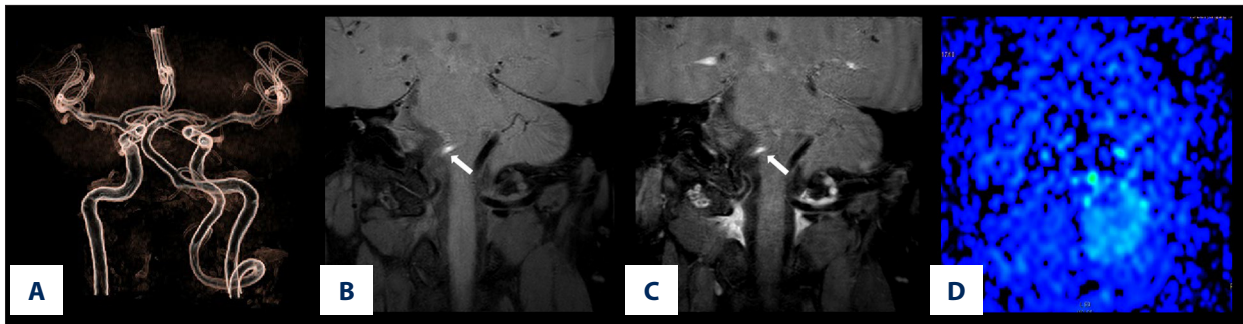
was expressed as mean±SD. The independent-samples *t* test was used to compare 2 groups. The description of count data was expressed using number of cases, and comparison of indicators, such as history of hypertension and smoking history, between 2 groups was performed using  $\chi^2$  test or Fisher exact test. Pearson analysis was employed when correlation of quantitative data indicated normal distribution, while Spearman analysis was used when non-normal distribution occurred. The Spearman correlation analysis was adopted for rank variables use. We used  $\alpha=0.05$  as the test level, and  $P<0.05$  was considered as statistical significance.

## Results

### Baseline Data Analysis of Patients with Dissection

In total, 97 patients with suspected head and neck dissection due to clinical symptoms underwent HR-MRI imaging. Among them, 68 patients were diagnosed as VAD by HR-MRI, while 58 confirmed patients were unilateral VAD. Additionally, 31 patients were examined within 7 days of onset, among which 27 were negative on MRI routine scan. One patient had poor coordination during examination, and showed movement artifacts.





**Figure 3.** The right vertebral artery V4 proximal dissection images of a 40-year-old female patient with dizziness and instable walking for 6 hours. (A) Is an MRA image. It can be seen that the vertebrobasilar artery minimum angle in this case is the basilar artery bending angle, which is measured to be approximately 75°. (B) Is a T1 VISTA scan image, showing eccentric crescent-shaped high signal at the proximal end of the right vertebral artery. (C) Shows no enhancement of vessel wall after T1 VISTA-enhancement. (D) Is an ASL image, and the right cerebellar hemisphere shows hypoperfusion.

Since their Likert scale score was 3, they did not meet the diagnostic requirements. Therefore, a total of 26 patients were included in the study.

Among these 26 patients (14 females, 12 males), 17 patients had normal ASL (Figure 2), while 9 patients had hypoperfusion with ASL (Figure 3). The baseline data of 26 patients with VAD are shown in Table 1. There was no statistically significant difference between the hypoperfusion and normal group with regards to sex, age, BMI, hypertension, and drinking history.

#### Analysis of HR-MRI Imaging Indexes of Patients with Dissection

The differences in HR-MRI imaging characteristics of 26 patients with VAD between the 2 groups are shown in Table 2. We found that the vertebrobasilar artery minimum angle was significantly smaller in the hypoperfusion group compared to the normal group ( $P < 0.001$ ). The differences between the 2 groups were statistically significant, which indicated a negative correlation and a correlation coefficient  $r = -0.686$ . The vertebrobasilar artery minimum angle less than 90° was more likely to cause posterior circulation hypoperfusion. The effective lumen index in the hypoperfusion group was lower compared to the normal group, and differences between the 2 groups were statistically significant ( $P < 0.001$ ), but with a negative correlation. The correlation coefficient was  $r = -0.671$ . However, there were no significant differences with regards to location of dissection, basilar artery curvature, hematoma distribution, enhancement, and other characteristics among the 2 groups.

#### Treatment and Follow-up of Patients with Dissection

Overall, there were 9 cases of hypoperfusion in 26 patients with ASL. Additionally, 2 patients progressed to cerebral infarction due to a worsening of symptoms within 3 days after the examination, and were treated using antiplatelet and

statins therapy. The other 7 cases were treated with antiplatelet therapy alone. Finally, 17 patients who showed negative signs of perfusion were treated conservatively and symptomatically, and their symptoms were significantly relieved at 1 month of follow-up.

#### Discussion

In this study, we discuss the characteristics of young and middle-aged patients with VAD who only show low perfusion but have negative MRI routine scan. We found no differences in clinical baseline data of patients in the hypoperfusion group and the normal group. In addition, with regards to the imaging characteristics of the lesion, we found that the bending angle of the basilar artery between the 2 groups was not significantly different. However, the vertebrobasilar artery minimum angle was statistically different among the 2 groups. Furthermore, when the bending angle was less than 90°, it was negatively correlated with the hypoperfusion group, with a correlation coefficient of  $-0.686$ . The smaller the angle, the greater the chance of ischemia.

There are few studies on the bending angle of the vertebrobasilar artery in VAD patients. Previous researchers [15-18] have found that vertebrobasilar dysplasia was related to VAD and posterior circulation ischemia according to research on vertebrobasilar dysplasia. The reason included that the bending of blood vessels can easily cause blood retention, slow flow rate, and cause insufficient blood supply to the distal end, and the curved blood vessels can also cause high blood flow resistance, which easily results in hypoperfusion infarction when the blood pressure fluctuates or blood volume is insufficient. Under physiological state, due to the existence of the compensatory mechanism of human blood supply, the changes can cause occurrence of non-obvious subjective symptoms. Nonetheless, with increasing age, the occurrence of vascular diseases and

**Table 1.** Clinical characteristics of VAD with negative MRI routine scan categorized into 2 groups.

Characteristics	Hypoperfusion group (n=9)	Normal group (n=17)	Total (n=26)	P value
Age, y, mean±SD	39±4	38±7	38±6	0.285
Sex, Male, n (%)	5 (55.6)	7 (41.2)	12 (46.2)	0.683
Body mass index, n (%)				0.692
≤25 kg/m <sup>2</sup>	4 (44.4)	6 (35.3)	10 (38.5)	
>25 kg/m <sup>2</sup>	5 (55.6)	11 (64.7)	16 (61.5)	
Hypertension, n (%)	5 (55.6)	6 (35.3)	11 (42.3)	0.419
Hyperlipidemia, n (%)	2 (22.2)	11 (64.7)	13 (50.0)	0.097
Diabetes, n (%)	3 (33.3)	4 (23.5)	7 (26.9)	0.661
Smoking, n (%)	4 (44.4)	12 (70.6)	16 (61.5)	0.234
Drinking, n (%)	5 (55.6)	12 (70.6)	17 (65.4)	0.667
Migraine, n (%)	3 (33.3)	3 (17.6)	6 (23.1)	0.628
Minor trauma, n (%)	5 (55.6)	5 (29.4)	10 (38.5)	0.234
Infection within 1 month of onset, n (%)	2 (22.2)	2 (11.8)	4 (15.4)	0.591
Clinical symptoms, n (%)				0.357
Dizziness, n (%)	8 (88.9)	11 (64.7)	19 (73.1)	
Headache and neck pain, n (%)	1 (11.1)	6 (35.3)	7 (26.9)	

degenerative diseases, and coupled with a decline of the body's compensatory ability, different degrees of cerebral ischemia symptoms can occur [19]. Kim et al [20] studied the influence of the morphological characteristics of the vertebrobasilar artery on the prognosis of VAD and concluded that patients with unruptured VADs who possess less BA (basilar artery) bending, a smaller VUBA (vertebral-union-basilar angle) and VUVA (vertebral-union-vertebral angle) could have a better prognosis compared with those without such features. They speculate that enlargement of the VUBA, VUVA, proximity of the dissection to the BA, and BA bending could cause changes in blood inflow and VA shear stress. These changes could heighten the vulnerability of the VA, thus affecting vascular healing. Although the definitions of the specific vertebrobasilar artery bending angles they studied are different and the purpose of the research is also different, their research principles are similar to this research. However, these studies include elderly patients over the age of 50 years. The selected population in this study included young and middle-aged people between 18 and 50 years old. Compared to the patients in the other studies, the relative vascular condition in this study is better, with a lower incidence of vascular disease and degeneration. In this study, the average bending angle of the basilar artery is 133°, with the conclusion that the curvature of VAD is related to the basilar artery, which is consistent with results of many researchers.

However, no statistically significant difference was found between the 2 groups. The primary reason may be that the basilar artery curvature is a predisposing factor of dissection, and is not necessarily a cause for ischemia, although ischemia is also correlated to the angle of basilar artery curvatures. Among the 26 cases analyzed in this study, the basilar artery curvature grade was small, with a few cases showing a basilar artery curvature angle of less than 90°. However, in this study, the vertebrobasilar artery minimum angle was related to hypoperfusion ischemia. Our analysis indicates 2 reasons for this. First, if the dissection is located in the proximal segment of V1-3 or V4, the vertebrobasilar artery minimum angle is selected according to the minimum angle of the bending angle between basilar artery and the V4 segment of the vertebral artery. Therefore, the angle is more likely to be lower than 90°. Second, in this ischemic hypoperfusion group, the proportion of vertebrobasilar artery minimum angle less than 90° was 8/9. Obviously, the proportion of bending angles lower than 90° was greater. The greater the bending angle, the easier the change of blood flow form, which can eventually form a vortex and cause a decrease in blood flow speed. Since the curved inner wall has low wall shear stress and high blood flow resistance, when blood pressure fluctuates or blood volume is insufficient, the blood supply disorder occurred in the posterior circulatory system to form hypoperfusion or even infarction [21].

**Table 2.** Comparison of HR-MR characteristics of the 2 groups with VAD.

Characteristics	Hypoperfusion group (n=9)	Normal group (n=17)	Total (n=26)	P value
Dissected side, n (%)				0.586
Intracranial	3 (33.3)	9 (52.9)	12 (46.2)	
Extracranial	5 (55.6)	6 (35.3)	11 (42.3)	
Intracranial and extracranial	1 (11.1)	2 (11.8)	3 (11.5)	
Vertebrobasilar artery minimum angle (°), mean±SD	86±10	132±28	115±33	<0.001
Vertebrobasilar artery minimum angle <90°, n (%)	8 (88.9)	3 (17.6)	11 (42.3)	0.001
Basilar artery bending angle (°), mean±SD	131±23	135±29	133±27	0.061
Basilar artery bending angle <90°, n (%)	3 (33.3)	1 (5.9)	4 (15.4)	0.192
Intra-vertebral artery hematoma side, n (%)				0.755
Outside	2 (22.2)	6 (35.3)	8 (30.8)	
Inside	4 (44.4)	7 (41.2)	11 (42.3)	
Both (spiral)	3 (33.3)	4 (23.5)	7 (26.9)	
Effective lumen index, mean±SD	0.19±0.07	0.31±0.06	0.27±0.09	<0.001
Lumen morphology, n (%)				0.937
Stenosis	3 (33.3)	10 (58.8)	13 (50.0)	
Stenosis with dilation	5 (55.6)	5 (29.4)	10 (38.5)	
Dilation	1 (11.1)	2 (11.8)	3 (11.5)	
Enhancement type, n (%)				0.258
No enhancement	1 (11.1)	0 (0)	1 (3.8)	
Punctate enhancement	5 (55.6)	13 (76.5)	18 (69.2)	
Diffuse enhancement	3 (33.3)	4 (23.5)	7 (26.9)	

Studies have indicated that the blood flow velocity is proportional to the 4th power of the vessel radius [22], indicating that blood flow velocity is slow when the vessel lumen is narrow. As the dissection mostly occurs in the endothelium, blood enters between the intima and the medium, and then coagulates rapidly [23], leading to different degrees of stenosis of the lumen. In this study, we found that the difference in effective lumen index was statistically significant between the hypoperfusion and the normal group. The effective lumen index was smaller in the ischemia hypoperfusion group, which was negatively correlated. We found that because the effective inner diameter of the lumen was smaller, the blood flow of the affected vertebral artery was lower, and the lower blood flow into the posterior circulation tissue was dominated by the patient's vertebral artery per unit time, leading to hypoperfusion in ASL. Even in extreme cases, when the effective lumen index of the blood vessel was as small as almost 0, it causes the vertebral artery

on the affected side to collapse, leading to obstruction of the ipsilateral blood vessel, and ultimately leading to appearance of large-scale infarction on the same side of the dissection.

In addition, we found in this study that the occurrence of ischemia caused by dissection was not related to location or morphology. Furthermore, among the 26 patients that underwent enhanced vascular wall imaging, 25 had vascular wall enhancement. Studies have shown that enhancement of the vascular wall may be related to inflammation or repair response after occurrence of arterial dissection [24,25]. Finally, studies have suggested that enhancement of the dissected vascular wall may originate from slow blood flow of the false lumen or arterial nourishment blood vessels [26]. We did not do a final pathological study, and so we also agree with their speculation. However, between the 2 groups, punctate enhancement and diffuse enhancement were not significantly different between the 2 groups,

which indicates that enhancement and the enhancement type of the dissection wall were not practically significant in distinguishing whether dissection had ischemic changes.

This study had some limitations. First, data from this study are based on a single research center, which cannot represent all ischemic manifestations of VAD, leading to bias. Secondly, few cases were included in the study, and risk factor prediction studies could not be conducted; only simple correlation analysis could be conducted. Hence, future multi-center and large-sample studies are needed. Third, as DSA is an invasive examination, none of the patients underwent the criterion standard DSA examination.

Although this study has certain limitations, it still imparts important information. In patients with VAD, we need to pay particular attention to those patients with infarcts on MRI routine scans, as they might actually have ischemia. Therefore, we believe that for those dissection patients with negative MRI routine scans, ASL should be carried out to determine whether it is an actual ischemic disease. This is particularly true for patients with dissection lesions where the vertebrobasilar artery minimum angle is less than 90° and the effective lumen index

is small. Thus, it should be highly suspected that there is ischemic lesion in the cranium, which needs to be taken seriously in order to optimize stroke prevention and perform treatment through early management.

## Conclusions

Posterior circulation ischemia in patients with VAD is related to the vertebrobasilar artery minimum angle and effective lumen index. For patients with a vertebrobasilar artery minimum angle less than 90° and a small effective lumen index, the incidence of ischemia is higher. It has been recommended that antiplatelet therapy should be actively performed for strict control of risk factors, and patients with worsening symptoms need further antiplatelet and statins therapy or endovascular therapy. However, patients without these manifestations and a negative ASL should be treated conservatively and symptomatically.

## Conflicts of interest

None.

## References:

- Schievink WI. Spontaneous dissection of the carotid and vertebral arteries. *N Engl J Med*, 2001;344:898-906
- Debette S, Compter A, Labeyrie MA, et al. Epidemiology, pathophysiology, diagnosis, and management of intracranial artery dissection. *Lancet Neurol*, 2015;14:640-54
- Lee SH, Jung JM, Kim KY, et al. Intramural hematoma shape and acute cerebral infarction in intracranial artery dissection: A high-resolution magnetic resonance imaging study. *Cerebrovasc Dis*, 2020;49:269-76
- Debette S, Compter A, Labeyrie MA, et al. Epidemiology, pathophysiology, diagnosis, and management of intracranial artery dissection. *Lancet Neurol*, 2015;14:640-54
- Mandell DM, Mossa-Basha M, Qiao Y, et al. Intracranial vessel wall MRI: principles and expert consensus recommendations of the American society of neuroradiology. *Am J Neuroradiol*, 2017;38:218-29
- Choi JW, Han M, Hong JM, et al. Feasibility of improved motion-sensitized driven-equilibrium (IMSDE) prepared 3D T1-weighted imaging in the diagnosis of vertebrobasilar artery dissection. *J Neuroradiol*, 2018;45:186-91
- Yun SY, Heo YJ, Jeong HW, et al. Spontaneous intracranial vertebral artery dissection with acute ischemic stroke: High-resolution magnetic resonance imaging findings. *Neuroradiol J*, 2018;1:262-69
- Yuan X, Cui X, Gu H, et al. Evaluating cervical artery dissections in young adults: A comparison study between high-resolution MRI and CT angiography. *Int J Cardiovasc Imaging*, 2020;36:1113-19
- Ro A, Kageyama N. Pathomorphological differentiation between traumatic rupture and nontraumatic arterial dissection of the intracranial vertebral artery. *Leg Med (Tokyo)*, 2014;16:121-27
- Vineetha VS, Sreedharan SE, Sarma PS, et al. Antiplatelets versus anticoagulants in the treatment of extracranial carotid and vertebral artery dissection. *Neurol India*, 2019;67:1056-59
- Park KJ, Jung SC, Kim HS, et al. Multi-contrast high-resolution magnetic resonance findings of spontaneous and unruptured intracranial vertebral artery dissection: Qualitative and quantitative analysis according to stages. *Cerebrovasc Dis*, 2016;42:23-31
- Zhang FL, Liu Y, Xing YQ, et al. Diagnosis of cervical artery dissection using 3-T magnetic resonance imaging. *JAMA Neurol*, 2015;72:600-1
- Atsina KB, Rothstein A, Messé SR, et al. Intracranial vessel wall MR imaging of an intradural vertebral artery dissection. *Clin Imaging*, 2020;68:108-10
- Woo S, Kim SY, Cho JY, et al. Apparent diffusion coefficient for prediction of parametrial invasion in cervical cancer: A critical evaluation based on stratification to a Likert scale using T2-weighted imaging. *Radiol Med*, 2018;123:209-16
- Zhou M, Zheng H, Gong S, et al. Vertebral artery hypoplasia and vertebral artery dissection. A hospital-based cohort study. *Neurology*, 2015;84:818-24
- Hori S, Hori E, Umemura K, et al. Anatomical variations of vertebrobasilar artery are closely related to the occurrence of vertebral artery dissection – an MR angiography study. *J Stroke Cerebrovasc Dis*, 2020;29:104636
- Park M, Shin NY, Yoo J, et al. Association between morphologic subtypes of vertebral artery dissection and vertebral artery hypoplastic appearance. *Eur J Radiol*, 2019;116:84-89
- Hwang J, Chung JW, Cha J, et al. Selective application of high-resolution 3 T MRI in the evaluation of intracranial vertebral artery dissection. *J Neuroimaging*, 2017;27:71-77
- Cosar M, Yaman M, Eser O, et al. Basilar artery angulation and vertigo due to the hemodynamic effect of dominant vertebral artery. *Med Hypotheses*, 2008;70:941-43
- Kim MK, Lim YC. Conservative management of unruptured spontaneous intracranial vertebral artery dissection. *World Neurosurg*, 2019;126:e402-9
- Lee SH, Hur N, Jeong SK. Geometric analysis and blood flow simulation of basilar artery. *J Atheroscler Thromb*, 2012;19:397-405
- Nakamura Y, Hirayama T, Ikeda K. Clinicoradiologic features of vertebrobasilar dolichoectasia in stroke patients. *J Stroke Cerebrovasc Dis*, 2012;21:5-10
- Tiu C, Terecoasa E, Grecu N, et al. Vertebral artery dissection: A contemporary perspective. *Maedica (Buchar)*, 2016;11:144-49
- Saito A, Fujimura M, Endo H, et al. Diagnostic value of contrast-enhanced magnetic resonance vessel wall imaging on the onset type of vertebral artery dissection. *Cerebrovasc Dis*, 2019;48:124-31
- Arai D, Satow T, Komuro T, et al. Evaluation of the arterial wall in vertebrobasilar artery dissection using high-resolution magnetic resonance vessel wall imaging. *J Stroke Cerebrovasc Dis*, 2016;25:1444-50
- Sakurai K, Miura T, Sagisaka T, et al. Evaluation of luminal and vessel wall abnormalities in subacute and other stages of intracranial vertebrobasilar artery dissections using the volume isotropic turbo-spin-echo acquisition (VISTA) sequence: A preliminary study. *J Neuroradiol*, 2013;40:19-28