

Effectiveness of low-level laser therapy after surgical removal of impacted mandibular third molars: A randomized clinical trial

ABSTRACT

Introduction: The low-level laser therapy has been accepted globally as cell bio-modulator, used to reach ideal therapeutic effects, acting in the reduction of the pain response, with anti-inflammatory effects, stimulating local micro-circulation and wounds repair, promoting a rapid recovery, which brings a better quality of life to the patient. In this study, we aim to determine the effectiveness of low-level laser therapy on reducing the pain and swelling after removal of impacted third molars.

Materials and Methods: In this present prospective randomized clinical study, third molar surgeries were performed in thirty patients who were divided into two equal groups (placebo group and study group) a placebo group with routine treatment and a study group with low-level laser therapy which was applied both intraorally and extraorally after the surgical extraction of mandibular third molar.

Results: The parameters such as postoperative pain, edema, and trismus were assessed on 1st and 7th day. All these parameters showed statistically significant results in patients with low-level laser therapy.

Conclusions: Low-level laser therapy was effective in reducing the postoperative pain, edema, and trismus in the third molar surgeries.

Keywords: Low-level laser, postoperative pain, surgical removal, third molar

INTRODUCTION

The most common minor surgical procedure performed by oral and maxillofacial surgeons is surgical extraction of impacted third molars. The major problems faced by surgeons are postoperative pain, swelling, and loss of jaw function. Postoperative pain and swelling are the major concern to the surgeons. Pain attains its peak after 3–5 h and continues till 2–3 days, which gradually decreases over the period of 4–5 days. The swelling usually appears after 12–48 h that will lead to facial disfigurement and major social concern.^[1,2]

The commonly used measures in reducing these complications by most of the surgeons are the use of analgesics, nonsteroidal anti-inflammatory drugs, and steroids. The use of these medications can have adverse effects like gastro-intestinal irritation, bleeding tendency, and allergic reactions. These limitations have led to the discovery of other treatment

modalities having less or no adverse reactions. As per the recent literature, the use of low-level laser therapy in the management of postoperative pain and swelling have shown promising results with no adverse reactions.^[2]

The laser has got the anti-inflammatory effect due to its increased phagocytic activity, increased lymphatic vessels, normalization

ARUP RATAN DAS, K. C. VIDYA, M. V. SRIKAR, JUGAJYOTI PATHI, ARYAN JAISWAL¹

Department of Oral and Maxillofacial Surgery, Kalinga Institute of Dental Sciences, KIIT University, ¹Program Associate, Bioinnovation, KIIT TBI, KIIT DU, Bhubaneswar, Odisha, India


Address for correspondence: Dr. K. C. Vidya, Department of Oral and Maxillofacial Surgery, Kalinga Institute of Dental Sciences, KIIT University, Bhubaneswar, Odisha, India. E-mail: drvidya1984@gmail.com

Received: 13 January 2021, **Revised:** 04 July 2021, **Accepted:** 05 October 2021, **Published:** 20 April 2022

This is an open access journal, and articles are distributed under the terms of the Creative Commons Attribution-NonCommercial-ShareAlike 4.0 License, which allows others to remix, tweak, and build upon the work non-commercially, as long as appropriate credit is given and the new creations are licensed under the identical terms.

For reprints contact: WKHLRPMedknow_reprints@wolterskluwer.com

How to cite this article: Das AR, Vidya KC, Srikar MV, Pathi J, Jaiswal A. Effectiveness of low-level laser therapy after surgical removal of impacted mandibular third molars: A randomized clinical trial. Natl J Maxillofac Surg 2022;13:60-6.

Access this article online	
Website: www.njms.in	Quick Response Code 
DOI: 10.4103/njms.njms_297_21	

of blood circulation, and vessel permeability. Low-level laser therapy produces its analgesic effect by producing endogenous endorphins and reducing inflammatory cytokines. Although its effects have shown significant reduction pain, inflammation, and swelling in many fields, its effect on postoperative pain management after third molar surgery is still controversial.^[3]

Thus, the present study was conducted to evaluate the effectiveness of low-level laser therapy after the surgical removal of impacted mandibular third molars.

MATERIALS AND METHODS

The purpose of this randomized clinical trial was to evaluate the effectiveness of low-level laser therapy in surgical extraction of mandibular third molars.

Sample size selection and source

The present study was carried out in the Department of Oral and Maxillofacial Surgery, Kalinga Institute of Dental Sciences, KIIT Deemed to be University, Bhubaneswar, after obtaining the Ethics Committee clearance (KIMS/KIIT/IEC/199/2018). For the estimation of sample size, we used test software (G Power). Taking in to these valuations we got a sample size of 20. Accounting for the loss to follow-ups, we increased the sample size to 25%. The final sample size taken was 30, from which two groups were done (control and study group) with 15 each in both groups.

Inclusion criteria

1. Patients with impacted mandibular third molars indicated for both prophylactic and symptomatic removal
2. Patients with impacted mandibular third molars which falls under Pederson's score criteria of 5–6 (Moderate index).

Exclusion criteria

1. Patients with the past history of hypersensitive or allergic episodes, cardiovascular compromise, or any other systemic disease which falls under the American Society of Anesthesiologists (ASA) III and ASA IV category
2. Pregnant or lactating women
3. Immunocompromised patients or patients taking central nervous system depressants or any other analgesics preoperatively
4. Patients presenting with acute infections (pericoronitis) and trismus
5. Patients unwilling to participate in the study.

Method of collection of data

All 30 patients were selected with Pederson's score criteria of 5–6 (Moderate index) and were grouped using random allocation software.

Preoperative investigations

All 30 patients are advised to get the following routine hematological and radiographic investigations.

1. Complete blood count
2. Bleeding time
3. Clotting time
4. Fasting blood sugar level
5. Postprandial blood sugar level
6. Radiovisiography.

Surgical technique

All the surgical procedure for 30 patients was done by the same operator. Facial skin preparation was done with savlon and betadine scrub. A standard draping procedure was carried out. Intraoral irrigation was done using normal saline and chlorhexidine solution. The inferior alveolar nerve, lingual nerve, and long buccal nerve were blocked using 2% lignocaine hydrochloride with 1:100,000 epinephrine.

Standard Terrence Ward's incision was placed with 15 number Bard Parker's blade. A full-thickness mucoperiosteal flap was reflected with Molt's periosteal elevator and retracted by the Austin's retractor. After that buccal and distobuccal bone guttering was done with rotary cutting instruments under copious saline irrigation. The tooth was split longitudinally using rotary cutting instruments and elevated with Coupland's elevator. The tooth fragments were separately retrieved.

The wound toilet was done using betadine solution and normal saline. Wound closure was achieved with 3-0 black braided silk. Postoperatively the following procedure was followed for both the groups.

Control group

Postoperatively, the control group were advised with routine medications for 7 days which included antibiotics (Amoxicillin 500 mg + Clavulanic acid 125 mg) 8th hourly, analgesics (Aceclofenac 100 mg + Paracetamol 325 mg + Serratiopeptidase 15 mg) 12th hourly, and Antiemetics (Pantoprazole 40 mg + Domperidone 30 mg) before food.

Study group

Postoperatively, the study group was subjected to low-level laser therapy (Photobiomodulation). A Diode laser (Novolase) with 660 nm in continuous mode.

Dosage of Laser– Power: 0.1 watt, Dose: 6J/cm², time: 60 s, frequency one time. This dose was used for the following sites.

Intraorally– Buccal, lingual, mesial, and distal side of extraction site in the vestibular area [Figure 1].

Extraorally- (A) Angle of the mandible, (B) Lower border of the mandible along with the surgical site, (C) A point 1.5 cm below the point (B) for lymph nodes [Figure 2].

The procedure was repeated on the first postoperative day.

Follow up design

All the patients were recalled on 1st postoperative day after 24 h and 7th postoperative day to measure the parameters (Pain, Edema, Interincisal Opening).

*Pain assessment-*done using visual analog scale. The patients were asked to mark the degree of perceived pain on a 10 cm horizontal line with zero (left side) indicating no pain and 10 (right side) indicating the severe pain.

*Edema-*measured by the two planes using thread and measuring scale. The distance between the tragus and the lip commissure and the distance between the gonion and the external canthus of the eye were measured both preoperatively and postoperatively. The edema coefficient was calculated using the following formula:-

Edema coefficient = (Distance after surgery – distance before surgery)/(distance before surgery) × 100.

*Inter-incisal mouth opening-*measured by using a divider and measuring scale both preoperatively and postoperatively.

Patients of the study group were asked to document the total no of rescue analgesics consumed per day up to the 7th postoperative day.

Suture removal was done on the 7th postoperative day after ensuring the satisfactory healing. Routine follow-up

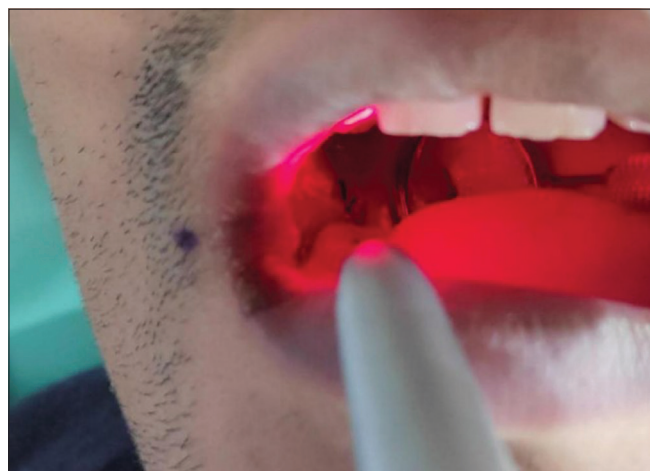


Figure 1: Laser exposure for intra-oral sites after the surgery

examination also included evaluation of the potential complications associated with the surgical procedure.

Statistical analysis

Data in relation to postoperative pain, postoperative swelling, trismus, and total no of analgesics consumed was analyzed

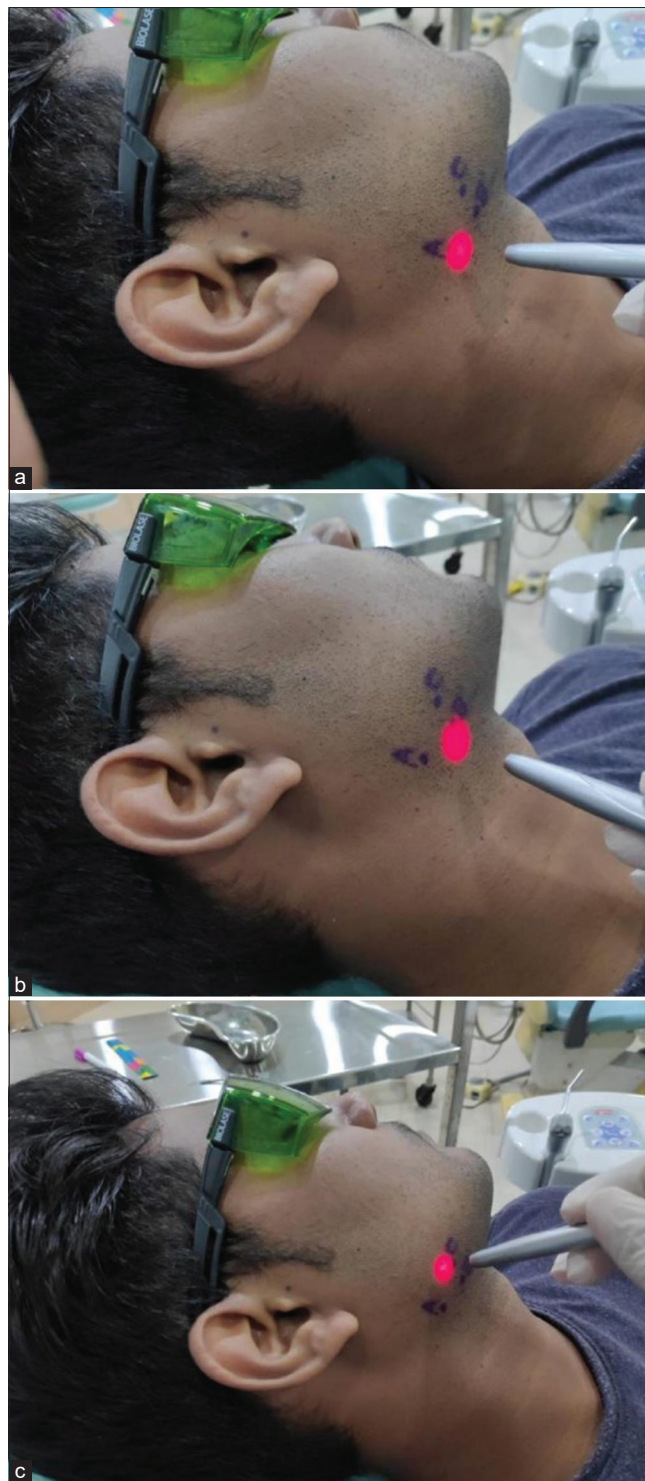


Figure 2: Laser exposure for extra oral sites after the surgery. (a) Point A (b) Point B (c) Point C

by a various statistical test. A $P < 0.05$ was considered highly significant, $P < 0.01$ highly significant, $P < 0.001$ very highly significant while $P > 0.05$ was considered to be statistically insignificant.

RESULTS

The present randomized clinical trial was conducted to assess the effectiveness of low-level laser therapy in terms of postoperative pain, edema, and trismus.

Pain assessment

Comparison of pain status between the groups on 1st and 7th day was done by Wilcoxon matched-pair test [Table 1].

The comparison of pain status on 1st postoperative day in control groups were zero patients with mild pain, 7 with moderate pain and 8 with severe pain, whereas in the study group, it was 9 patients with mild pain, 6 with moderate pain and zero patients with severe pain. The results were statistically highly significant ($P = 0.0001$).

The comparison of pain status on 7th postoperative day in control groups were zero patients with no pain, 11 with mild pain and 4 with moderate pain, whereas in the study, group 12 patients had no pain, and 3 patients had mild pain. The results were statistically highly significant ($P = 0.0001$) [Table 2].

The percentage of decrease in pain from first postoperative day to 7th postoperative in the control group was 50%,

Table 1: Comparison of 1st and 7th day time points with pain status in control group and study group by Wilcoxon matched pairs test

Groups	Changes from	Percentage of change	Z	P
Control group	1 st day to 7 th day	50.00	3.2958	0.0010*
Study group	1 st day to 7 th day	85.71	3.1798	0.0015*

* $P < 0.05$

Table 2: Comparison of control group and study group with pain status at 1st and 7th day time points by Mann-Whitney U-test

Pain at	Control group (%)	Study group (%)	Total (%)	Z	P
1 st day					
Mild pain	0	9 (60.00)	9 (30.00)	-3.7952	0.0001*
Moderate pain	7 (46.67)	6 (40.00)	13 (43.33)		
Severe pain	8 (53.33)	0	8 (26.67)		
Total	15 (100.00)	15 (100.00)	30 (100.00)		
7 th day					
No pain	0	12 (80.00)	12 (40.00)	-3.9818	0.0001*
Mild pain	11 (73.33)	3 (20.00)	14 (46.67)		
Moderate pain	4 (26.67)	0	4 (13.33)		
Total	15 (100.00)	15 (100.00)	30 (100.00)		

*P value < 0.05 is significant

and in study group, it was 85.7% which was statistically significant ($P = 0.001$).

Edema assessment

A dependent *t*-test was used to compare the edema co-efficient.

Supero-inferiorly

The mean value of superoinferior edema coefficient between 1st and 7th postoperative day in the control group were 12.63 and 6.67 respectively and in the study group, they were 10.30 and 5.91 respectively. The percentage of change between 1st and 7th day in the Control Group was 47.20% and in the study group, it was 42.65% [Table 3]. The results were statistically highly significant ($P = 0.0001$).

Antero-posteriorly

The mean value of anteroposterior edema coefficient between 1st and 7th postoperative day in study group were 7.54 and 2.98 respectively and in the control group, they were 8.83 and 4.07 respectively. The percentage of change between the 1st and 7th day in the control group was 60.48% and in the study group, it was 53.85 percentage [Table 3]. The results were statistically highly significant ($P = 0.0001$).

Mouth opening

Dependent *t*-test was used to compare the mouth opening on 1st and 7th postoperative day.

The average mouth opening after the first postoperative day in the control group was 32.8 mm and in study group, it was 32.5 mm. The mouth opening after 7th postoperative day in the control group was 2 reduced to 26.6 mm, whereas in study group mouth opening was increased to 38.6 mm. The results were significant statistically ($P = 0.001$).

DISCUSSION

Impacted third molars can lead to problems such as pericoronitis, external root resorption of the second molar's

Table 3: Comparison of 1st and 7th day time points with supero-inferior edema coefficient, antero-posterior edema coefficient and mouth opening (mm) in control group and study group by dependent t-test

Groups	Time	Mean	SD	Mean difference	SD difference	Percentage of change	Paired t	P
Supero-inferior edema coefficient								
Control group	1 st day	12.63	6.88	5.96	3.13	47.20	7.3857	0.0001*
	7 th day	6.67	5.39					
Study group	1 st day	10.30	6.45	4.39	6.50	42.65	2.6179	0.0203*
	7 th day	5.91	3.85					
Antero-posterior edema coefficient								
Control group	1 st day	8.83	4.73	4.56	3.02	60.48	5.8574	0.0001*
	7 th day	4.07	2.21					
Study group	1 st day	7.54	4.19	4.75	4.22	53.85	4.3584	0.0007*
	7 th day	2.98	2.45					
Mouth opening (mm)								
Control group	1 st day	32.80	12.19	+6.13	4.07	+23.00	+5.838	0.0001*
	7 th day	26.67	88					
Study group	1 st day	32.53	1.88	+6.07	2.49	+18.65	+9.429	0.0001*
	7 th day	38.60	2.06					

*P<0.05. SD: Standard deviation

root, tooth decay, odontogenic cysts, and tumors. The extraction can lead to postoperative complications such as pain, swelling, trismus, and ecchymosis, all caused by tissue trauma and inflammation.^[4]

Analgesics, antibiotics, cold, and warm packs have been commonly used to counter such complications, but the therapeutic effects of low-level laser therapy are used with positive effects. The irradiation effects of low-level laser therapy in live tissue are caused by a phenomenon called photobiomodulation, which is the application of nonionized light produced by low-level laser therapy to trigger positive physiological effects.^[5]

The present randomized clinical trial assessed the effectiveness of low-level laser therapy in mandibular third molar surgery.

The study conducted on 32 female patients by Santos *et al.*^[6] showed that there was a significant reduction of pain after 48 h and above. In a similar study conducted on 80 patients by Mohajerani *et al.*^[5] showed a significant reduction in pain after 3 days postoperatively in laser group as compared to the control group. Another study conducted by Petrini *et al.*^[7] showed reduction in pain. In another study conducted by Landucci *et al.*^[8] showed reduction in pain after 48 h with a single dose of low-level laser therapy. The other study which showed a significant reduction in pain after low-level laser therapy was conducted by Shenawy *et al.*^[9]

The present randomized clinical trial also showed significant reduction in pain after low level laser therapy. On first postoperative day, 9 of our patients had only mild pain in

comparison with control group and no pain was after 7 days was seen in 12 out of 15 patients in study group.

Fernando *et al.*^[4] conducted a study in 64 patients and did a split-mouth technique in which one side was study and other side was a placebo, he found out that there was no difference in reduction of pain among both the sites. A randomized control trial conducted by Farhadi *et al.*^[10] on 24 patients with low-level laser therapy showed no significant reduction in pain.

However, the difference in their results as compared to our results could be due to the dose, mode, or frequency used in our study. In the current study, low-level laser therapy was given by using Diode laser (Novolase) with 660 nm in a continuous mode both intraorally and extraorally in contact mode. The procedure was repeated on the first postoperative day.

Amarillas-Escobar *et al.*^[11] conducted a randomized control trial on 30 patients with study and control group and showed reduction in swelling postoperatively. In another study conducted by Batinjan *et al.*^[12] on 150 patients with three groups of 50 each and compared photodynamic therapy, low-level laser therapy and control group, results of their study showed a significant reduction in postoperative swelling in both groups treated with laser as compared to control group. Alan H conducted a study on 15 patients with bilateral impaction, one side was control and the other side was study group, they found reduction in postoperative swelling.

In the present study, the mean value of superoinferior edema coefficient on 1st day in the control group was more (12.63) than in the low-level laser therapy group (10.30), also in the

7th day it was 6.67 and 5.91 in the control and study group respectively.

The mean value of anteroposterior edema coefficient on 1st day in the control group was more (8.83) than in the low-level laser therapy group (7.54), also in the 7th day, it was 4.07 and 2.98 in the control and study group respectively.

In our study, both superoinferior and anteroposterior edema coefficient shown statistically highly significant results in the low-level laser therapy Group.

Fernando *et al.*^[4] conducted a study in 64 patients and did a split-mouth technique in which one side was study and other side was a placebo, he found out that there was no difference in reduction of swelling among both the sites. Raouaa *et al.*^[13] conducted a study on 60 patients with two groups, one group received laser and the other group received steroids, the results showed that corticosteroid was more effective in reducing swelling than the laser group. Another study conducted by Raesian *et al.*^[14] in 44 patients with no significant difference in swelling between both study and control groups.

Farhadi *et al.*^[10] and Koparal *et al.*^[15] also conducted studies on laser after third molar surgery and showed no significant reduction in swelling postoperatively.

The inconsistent results associated with low-level laser therapy from our study and others may be explained by different irradiation parameters and application.

The mean value of maximal mouth opening in control group on postoperative day one and day seven was less (32.80), (26.67) as compared to the study group (32.53) and (38.60) respectively.

A similar study was conducted by Ferrante *et al.*^[11] on 30 patients with control and study group found an acceptable reduction in trismus postoperatively in comparison to control group. Landucci *et al.*^[8] in their study on 22 patients showed a significant reduction in trismus postoperatively. Petrini *et al.*^[7] also found a significant reduction in trismus postoperatively in both groups of laser therapy.

Raesian *et al.*^[14] in their study on 44 patients found no significant reduction in trismus compared to the drug group. Raouaa *et al.*^[13] in their study showed a significant reduction in trismus in the corticosteroid group compared to laser group. A randomized control trial conducted by Farhadi *et al.*^[10] found no significant results in terms of reduction in

trismus. Koparal *et al.*^[15] found reduction in trismus only after 7th postoperative day.

This variation may be due to the difficulties in the measurement of variables associated with postoperative sequelae, differences in the type of laser machine used.

CONCLUSIONS

Low-level laser therapy intervention is noninvasive, simple to perform and carries a negligible to nonexistent risk of harm.

Considering the methods used and results obtained in the present study, we conclude that low-level laser therapy was effective in reducing the postoperative pain, edema, and trismus in the third molar surgeries.

The laser therapy needs to be evaluated in future studies along with the larger sample size and longer follow-up period.

Declaration of patient consent

The authors declare that they have obtained consent from patients. Patients have given their consent for their images and other clinical information to be reported in the journal. Patients understand that their names will not be published and due efforts will be made to conceal their identity but anonymity cannot be guaranteed.

Financial support and sponsorship

Nil.

Conflicts of interest

There are no conflicts of interest.

REFERENCES

1. Ferrante M, Petrini M, Trentini P, Perfetti G, Spoto G. Effect of low-level laser therapy after extraction of impacted lower third molars. *Lasers Med Sci* 2013;28:845-9.
2. Eshghpour M, Ahrari F, Takallu M. Is low-level laser therapy effective in the management of pain and swelling after mandibular third molar surgery? *J Oral Maxillofac Surg* 2016;74:8.e1-8.
3. Momeni E, Barati H, Arbabi MR, Jalali B, Moosavi MS. Low-level laser therapy using laser diode 940 nm in the mandibular impacted third molar surgery: Double-blind randomized clinical trial. *BMC Oral Health* 2021;21:77.
4. Fernando S, Hill CM, Walker R. A randomised double blind comparative study of low level laser therapy following surgical extraction of lower third molar teeth. *Br J Oral Maxillofac Surg* 1993;31:170-2.
5. Mohajerani H, Tabeie F, Alirezaei A, Keyvani G, Bemanali M. Does combined low-level laser and light-emitting diode light irradiation reduce pain, swelling, and trismus after surgical extraction of mandibular third molars? A randomized double-blinded crossover study. *J Oral Maxillofac Surg* 2021;79:1621-8.
6. Santos PL, Marotto AP, Zatta da Silva T, Bottura MP, Valencise M, Marques DO, *et al.* Is low-level laser therapy effective for pain control

- after the surgical removal of unerupted third molars? A randomized trial. *J Oral Maxillofac Surg* 2020;78:184-9.
7. Petrini M, Ferrante M, Trentini P, Perfetti G, Spoto G. Effect of pre-operative low-level laser therapy on pain, swelling, and trismus associated with third-molar surgery. *Med Oral Patol Oral Cir Bucal* 2017;22:e467-72.
 8. Landucci A, Wosny AC, Uetanabaro LC, Moro A, Araujo MR. Efficacy of a single dose of low-level laser therapy in reducing pain, swelling, and trismus following third molar extraction surgery. *Int J Oral Maxillofac Surg* 2016;45:392-8.
 9. Shenawy H, Aboelsoud N, Zaki A, Zawahry M, Shaibeta A. Postoperative pain control in patients after lower third molar extraction. *J Am Sci* 2010;6:1068-72.
 10. Farhadi F, Eslami H, Majidi A, Fakhrzadeh V, Ghanizadeh M, KhademNeghad S. Evaluation of adjunctive effect of low-level laser therapy on pain, swelling and trismus after surgical removal of impacted lower third molar: A double blind randomized clinical trial. *Laser Ther* 2017;26:181-7.
 11. Amarillas-Escobar ED, Toranzo-Fernández JM, Martínez-Rider R, Noyola-Frías MA, Hidalgo-Hurtado JA, Serna VM, *et al.* Use of therapeutic laser after surgical removal of impacted lower third molars. *J Oral Maxillofac Surg* 2010;68:319-24.
 12. Batinjan G, Filipović Zore I, Rupić I, Bago Jurić I, Zore Z, Gabrić Pandurić D. Assessing health-related quality of life with antimicrobial photodynamic therapy (APDT) and low level laser therapy (LLLT) after third molar removal. *J Lasers Med Sci* 2013;4:120-6.
 13. Raouaa B, Sameh S, Nour B, Abdellatif C, Jamil S. Effects of low-level-laser therapy versus corticotherapy on pain, trismus and edema after surgical removal of third mandibular molars: A comparative study. *Family Med Medical Sci Res* 2013;2:1-4.
 14. Raiesian S, Khani M, Khiabani K, Hemmati E, Pouretezad M. Assessment of low-level laser therapy effects after extraction of impacted lower third molar surgery. *J Lasers Med Sci* 2017;8:42-5.
 15. Koparal M, Kucuk AO, Alan H, Asutay F, Avci M. Effects of low-level laser therapy following surgical extraction of the lower third molar with objective measurement of swelling using a three-dimensional system. *Exp Ther Med* 2018;15:3820-6.