



Optimizing Treatment of Breast Cancer Related Lymphedema Using Combined DIEP Flap and Lymphedema Surgery

Edward I. Chang, MD, FACS¹

¹Department of Plastic Surgery, University of Texas MD Anderson Cancer Center, Houston, Texas

Arch Plast Surg 2022;49:150–157.

Address for correspondence Edward I. Chang, MD, FACS, Department of Plastic Reconstructive Surgery, MD Anderson Cancer Center, 1400 Pressler Drive, 19.500, Houston, TX 77030 (e-mail: eichang@mdanderson.org).

Abstract

Patients undergoing treatment for breast cancer who undergo an axillary dissection and require adjuvant therapies such as radiation and chemotherapy are at high risk of developing lymphedema of the associated extremity. Historically, patients with lymphedema were treated with ablative procedures aimed simply to remove excess fluid and adiposity; however, the field of lymphatic surgery employing super-microsurgery techniques has witnessed tremendous advances in a relatively short period of time. Advancements in surgical instruments, microscope magnification and optics, imaging technology, and surgeon experience have ushered in a new era of hope to treat patients suffering from breast cancer-related lymphedema (BCRL). Here we aim to present the available options for patients suffering from BCRL, and the pinnacle in reconstruction and restoration for these patients.

Keywords

- ▶ breast cancer lymphedema
- ▶ lymphedema surgery
- ▶ breast reconstruction

Breast reconstruction has long been an integral part of the field of reconstructive plastic surgery and has documented benefits in improving the psychological health of patients and their quality of life.^{1,2} In the modern era, breast reconstruction has become a standard component in the multidisciplinary care for patients with breast cancer, and at national accredited cancer institutions, the aim is to afford all patients undergoing surgery for breast cancer an opportunity for reconstruction. Despite the known advantages to breast reconstruction, the benefits to reconstruction for lymphedema are not as well accepted, and insurance companies in the United States continue to deny coverage for what is considered experimental surgery.³ However, there is growing body of literature demonstrating long-term efficacy in lymphatic microsurgery in improving symptoms and quality of life of patients suffering from breast cancer-related lymphedema (BCRL).^{4–6}

Two recent physiologic options have now become the mainstay of surgical treatment for lymphedema, both of which have proven to be effective and reproducible when performed by skilled, trained microsurgeons at centers of excellence. The lymphovenous bypass (LVB) or lymphaticovenular anastomosis (LVA) creates a shunt between obstructed lymphatic vessels and the system circulation (▶ Fig. 1). The lymphatic channels are identified with the use of the fluorescent dye, indocyanine green (ICG), which is absorbed into the lymphatic system and then detected using specialized infrared imaging. Once a lymphatic vessel and a recipient venule are identified, an anastomosis is performed.^{7,8} The second approach is a vascularized lymph node transfer (VLNT), which is based on transferring lymph nodes from one location into the affected extremity to replace the lymph nodes removed during the node dissection. Although the precise underlying mechanism of action

DOI <https://doi.org/10.1055/s-0042-1744414>.
ISSN 2234-6163.

© 2022. The Korean Society of Plastic and Reconstructive Surgeons. All rights reserved.

This is an open access article published by Thieme under the terms of the Creative Commons Attribution-NonDerivative-NonCommercial-License, permitting copying and reproduction so long as the original work is given appropriate credit. Contents may not be used for commercial purposes, or adapted, remixed, transformed or built upon. (<https://creativecommons.org/licenses/by-nc-nd/4.0/>)

Thieme Medical Publishers, Inc., 333 Seventh Avenue, 18th Floor, New York, NY 10001, USA

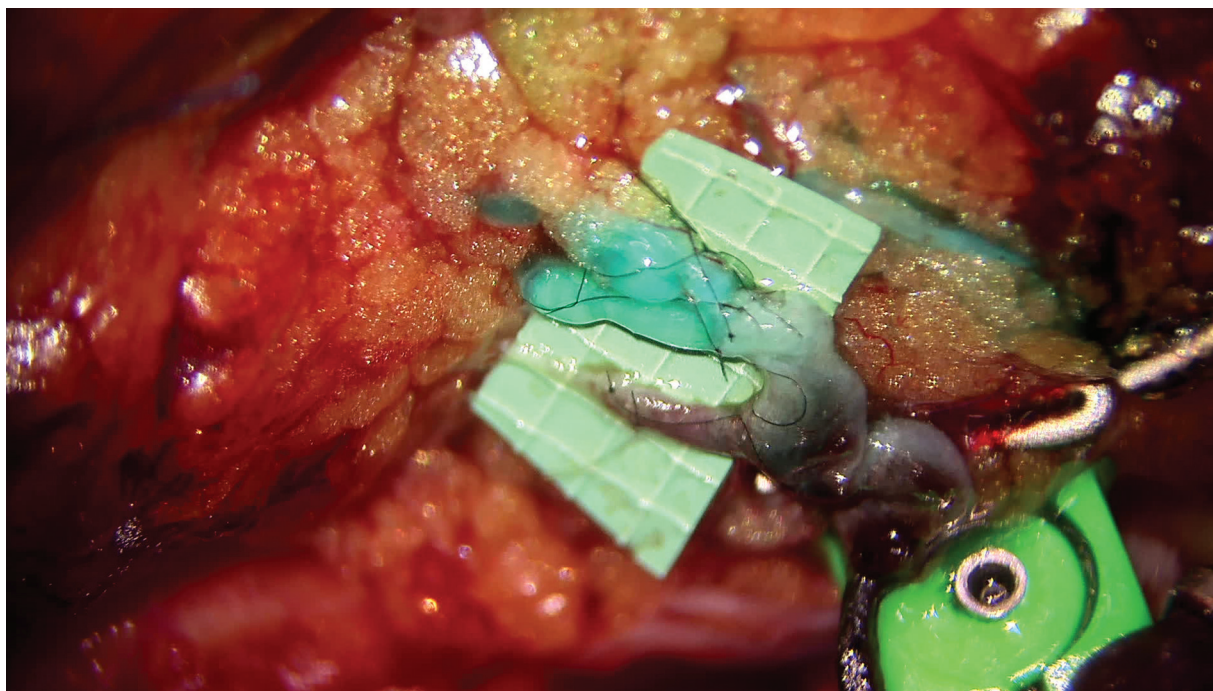


Fig. 1 Lymphovenous anastomosis (LVA) demonstrating patency of the anastomosis with drainage of lymphatic fluid and lymphazurin into the recipient venule.

remains an area of active investigation, the transferred lymph nodes have also proven remarkably effective in improving lymphedema.⁹ Several different donor sites have been described, all of which have generally demonstrated equivalent outcomes with comparable improvements and complications.^{10–12}

As the experience and popularity with lymphedema surgery have increased over time, so have the techniques evolved to provide patients with the most optimal outcomes. Not surprisingly, the treatment of BCRL has also witnessed dramatic advancements, but BCRL presents a unique circumstance for modifications in the available techniques for treatment. The present review aims to describe the currently available strategies and authors' approach for treating BCRL.

Preoperative Evaluation

Patients with advanced disease who have often had neoadjuvant chemotherapy with a subsequent axillary node dissection and postoperative radiation are at high risk of developing lymphedema.^{13–15} Patients with the trifecta of risk factors should be monitored closely for symptoms of lymphedema and should be referred proactively to certified lymphedema therapists for prevention and education. For those who develop lymphedema, all patients should be evaluated by certified lymphedema therapists to maximize complete decongestive therapy (CDT). A thorough physical examination documenting the consistency of the soft tissue, Stemmer's sign, presence of pitting edema and fibrosis, and peripheral pulses should be performed along with a complete history, particularly documenting adjuvant therapies and prior surgeries, any prior episodes of infection and cellulitis, and compliance with CDT and compression garments.

Patients should have objective metrics obtained. Although there is considerable debate regarding the most optimal means of measuring lymphedema, some objective measure should be obtained. Circumferential measurements are the simplest and also notoriously inaccurate with tremendous variability in measurements obtained. A perometer that obtains a volumetric measurement of the affected arm, the L-Dex that provides an objective ratio of fluid to fat distribution in the arm, and bioimpedance are all useful measurements that can aid in following the progression of the lymphedema and response to treatment.

Preoperative imaging studies such as magnetic resonance imaging (MRI) can also be used to delineate the ratio of fluid to fat in the arm. For those with a high fat distribution, some would argue a reductive procedure such as liposuction will suffice, whereas those with a higher fluid component will respond better to a physiologic procedure such as an LVB or VLNT. Others have demonstrated the ability of MR to predict outcomes following LVB in addition to surgical planning in localizing potential lymphatic channels for LVB. Many practitioners also rely on MR studies not only for surgical planning, but also to assess postoperative outcomes.¹⁶ However, the routine use of MRI preoperatively and postoperatively can be prohibitively difficult and costly and is therefore not performed at the authors' institution. On the other hand, lymphoscintigraphy is considered the gold standard for diagnosing lymphedema and is also critically important in the preoperative planning for VLNT. Some practitioners have also demonstrated the efficacy and accuracy of lymphoscintigraphy in predicting postoperative outcomes following LVB.¹⁷ In the affected arm, the lymphoscintigraphy will confirm lack of drainage of technetium proximally; however, other etiologies for unilateral arm swelling should be

excluded such as a deep vein thrombosis. However, for patients who present with a classic history of breast cancer, prior axillary dissection, along with chemotherapy and radiation, the authors do not routinely obtain lymphoscintigraphy as it is a relatively painful study and can add additional unnecessary costs. For patients undergoing a lymph node transfer from the inguinal region, lateral thoracic, or supraclavicular donor sites, preoperative lymphoscintigraphy should be performed to identify the sentinel nodes draining the extremity to avoid precipitating iatrogenic lymphedema following harvest of the lymph nodes.

Lymphovenous Bypass or Vascularized Lymph Node Transfer

Both physiologic approaches have demonstrated high success rates in improving lymphedema. The decision for which option to use was historically based on the severity of the lymphedema. Several different classification systems have been described; however, the authors prefer to employ the ICG classification system described at our institution. For patients with early stage lymphedema (stages 1 and 2), the LVB technique was historically the option offered, whereas those with more severe lymphedema where lymphatic channels could no longer be identified using ICG (stages 3 and 4) were offered a VLNT.¹⁸ This original algorithm remains the standard approach, particularly in patients who have undergone breast conservation, although this philosophy is also continuing to evolve.

Given the reproducible outcomes achieved with the LVB and VLNT, we hypothesized that combining both modalities would have a synergistic benefit with a more dramatic improvement compared with either modality alone. With this novel notion, an attempt is often made to perform an LVB even in the setting of advanced lymphedema where a distinct channel is not visualized using ICG. With increasing experience and knowledge of the anatomic architecture of the lymphatic system as well as dynamic ultrasound, successful bypasses can be performed irrespective of the limitations of ICG lymphangiography. The use of ultra-high-frequency ultrasound may revolutionize the field of lymphedema surgery and make ICG lymphatic mapping obsolete. Early experience with this technology has demonstrated promising outcomes where both the lymphatic channels and a recipient vein can be readily identified. Further, the ultrasound allows for visualization of lymphatics and venules that cannot be identified using ICG allowing the ability to perform an LVB even in more advanced stage lymphedema.^{19–21}

For patients who have undergone breast conservation and develop BCRL, the combined LVB/VLNT approach is now our recommended approach. However, the decision for which donor site to select for a lymph node transfer is dependent on surgeon comfort and experience, patient preference and prior surgeries, and risk of donor site lymphedema. Given the equivalent efficacy of all donor sites, the authors offer all options.^{12,22} The supraclavicular and submental donor sites leave scars that are potentially quite visible, whereas the scars from the lateral thoracic or inguinal nodes are well concealed. The authors prefer harvest of the omentum and

gastroepiploic nodes via a minimally invasive laparoscopic approach, which again leaves scars that are well tolerated (→ Fig. 2). However, there is always the potential risk of a need to convert to an open procedure, inadvertent injury to the bowel or other structures, adhesions, or an incisional hernia.²³ As previously noted, preoperative lymphoscintigraphy is always obtained when using the supraclavicular, lateral thoracic, or inguinal donor sites to minimize the risk of donor site lymphedema (→ Fig. 3).

Combined Breast Reconstruction and Lymph Node Transfer

For patients who present with BCRL who are interested in breast reconstruction, the authors recommend a combined approach where an autologous breast reconstruction is performed using a free abdominal flap in combination with a chimeric inguinal lymph node flap that has been previously described by others as well.^{24–26} This combined approach provides the most optimal means for reconstruction as the overwhelming majority of patients have had radiation, and the use of implants is fraught with higher complication rates. Although this does represent a bias of the authors to favor autologous tissue reconstruction in this setting, a combined DIEP flap with an inguinal lymph node transfer will provide a durable, aesthetic reconstruction and improve the patient's lymphedema in a single operation without increasing the operative time, hospital stay, or recovery time (→ Fig. 4).

The decision to obtain a preoperative computed tomography (CT) angiogram to evaluate the vascular anatomy and perforator distribution to facilitate the dissection of the DIEP flap is at the discretion of the operating surgeon; however, all patients should undergo preoperative lymphoscintigraphy of both lower extremities to identify the sentinel nodes in the inguinal region to avoid injury to these nodes during the inguinal node harvest, which can cause lymphedema of the leg. Reverse lymphatic mapping can also be performed to further preserve the drainage from the legs, again to minimize the risks of iatrogenic lymphedema. At the start of the case, lymphazurin dye is injected into the webspaces of the foot to allow identification of the drainage of the lower extremity, although the use of ICG has also demonstrated excellent results.²⁷ Combined with the preoperative lymphoscintigraphy, understanding of the anatomic boundaries of the critical lower extremity nodes, and the reverse lymphatic mapping, we have never precipitated donor site lymphedema following harvest of the inguinal nodes.

The inguinal nodes are perfused based on a wide adipofascial pedicle centered over the superficial inferior epigastric or the superficial circumflex iliac vessels. Whether or not an additional arterial or venous anastomosis is needed is based on ICG angiography, which will confirm perfusion of the lymph nodes. We typically perform ICG angiography following dissection and elevation of the DIEP flap and repeat the ICG angiography after revascularization to confirm adequate perfusion of the flap and also clearance of the fluorescent dye. If the nodes continue to enhance from the first ICG

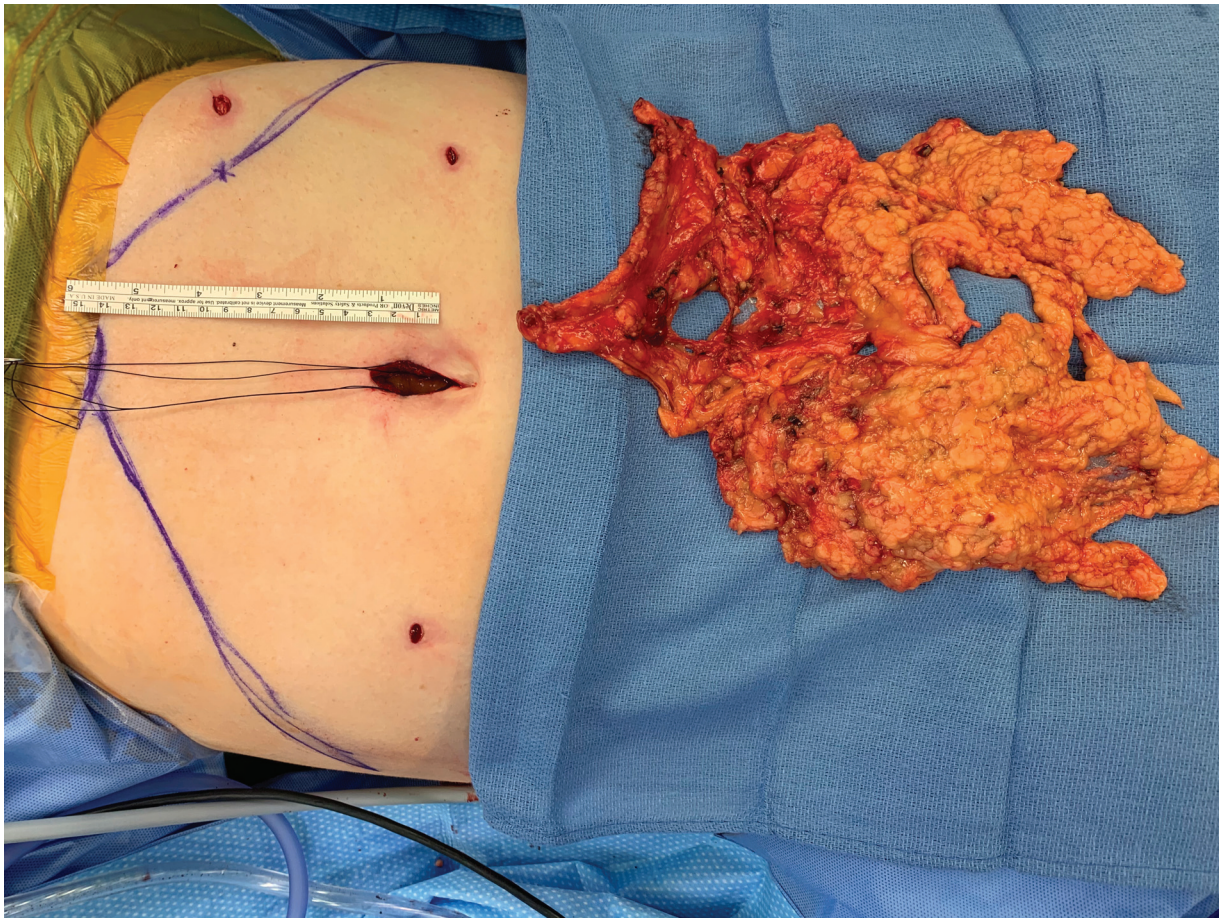


Fig. 2 Laparoscopic omental harvest. Harvest of the gastroepiploic lymph nodes and free omental flap using a minimally invasive laparoscopic approach.

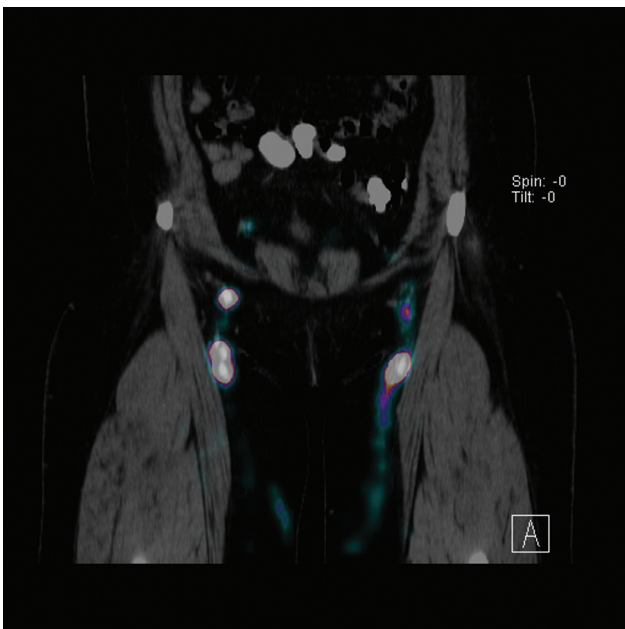


Fig. 3 Lower extremity lymphoscintigraphy. Preoperative lymphoscintigraphy for mapping of the sentinel nodes draining the leg in preparation for harvest of the inguinal lymph nodes as a vascularized lymph node transfer (VLNT). Preoperative imaging is critical to

injection, this indicates the need for an additional venous anastomosis. In the setting that an additional arterial or venous anastomosis is needed, the lateral thoracic vessels or the serratus branch of the thoracodorsal vessels is recommended. The dissection of additional recipient vessels can be tedious and risky in the previously operated and radiated axilla; however, a thorough scar release is critical. The scar release will facilitate drainage from the arm, create a space for the lymph nodes to avoid a lateral bulge, improve the range of motion of the arm, and also permit for dissection of recipient vessels. The authors typically preserve the main thoracodorsal vessels in the setting of a total flap loss, which still allows for a pedicle latissimus dorsi myocutaneous flap to salvage the reconstruction. However, others propose using the thoracodorsal vessels as the primary recipient vessels for the DIEP flap, which is reasonable as well, although this may compromise the aesthetics of the breast reconstruction placing the flap more laterally and also preclude the use of a latissimus dorsi flap for salvage breast reconstruction. The authors favor using the internal mammary vessels as the recipients for the DIEP flap, which is often sufficient to perfuse the inguinal nodes. Whether an additional arterial and venous anastomosis is necessary or has an impact on outcomes remains to be determined.

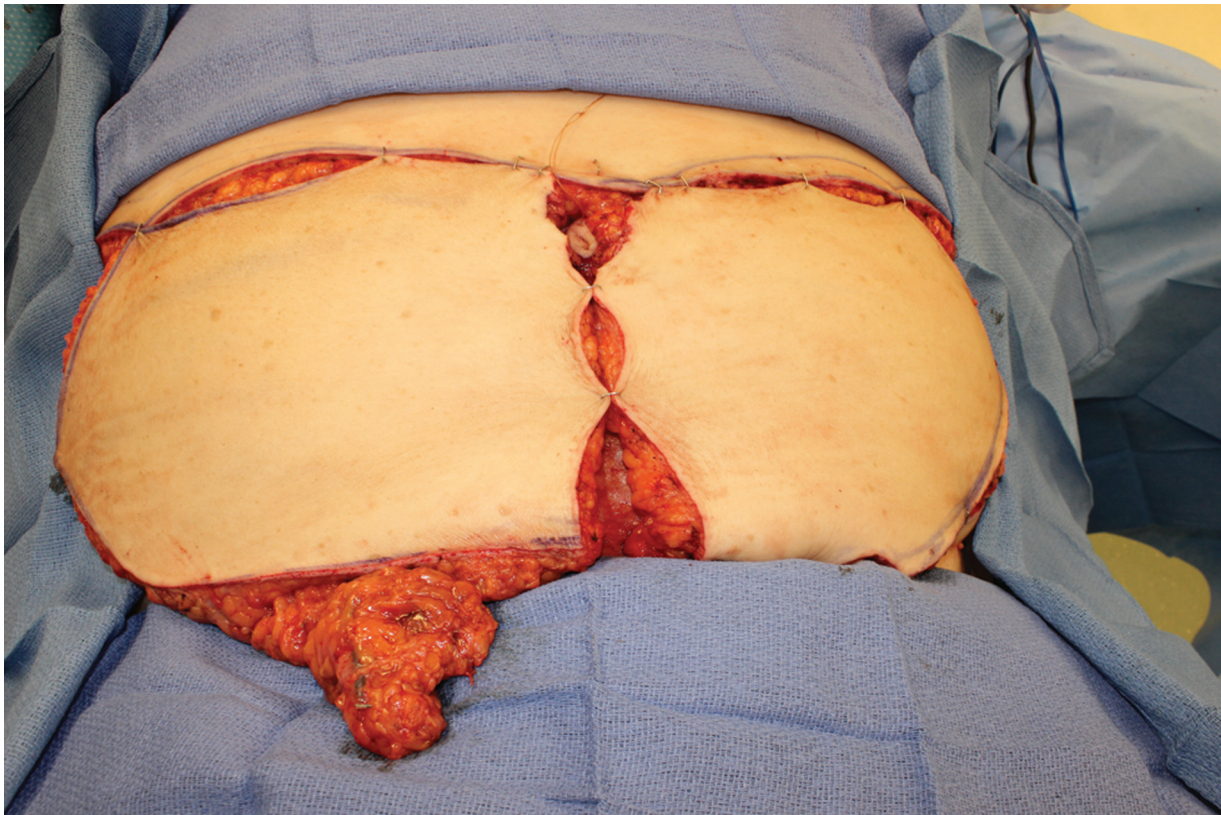


Fig. 4 Deep inferior epigastric perforator (DIEP) flap with inguinal node transfer. Combined chimeric inguinal lymph nodes with a free DIEP flap to reconstruct the mastectomy defect as well as improve the drainage from the affected extremity.

Breast Reconstruction Including LVB and Inguinal to Axillary Node Transfer

Historically, patients suffering from BCRL and presenting for reconstruction were treated using a combined DIEP and lymph node transfer; however, our algorithm has evolved over time to combine both physiologic techniques to maximize the drainage from the arm, similar to the treatment of BCRL in patients who had breast conservation (► **Fig. 5**). The Breast Reconstruction Including LVB and Inguinal to Axillary Node Transfer (BRILIANT) technique not only couples the DIEP flap breast reconstruction with the inguinal lymph node transfer but also includes the LVB in a single operation.^{28–30} The operation does not increase the patient's hospital stay or recovery and has the potential to provide an immediate benefit.

The LVB creates an immediate shunt allowing the lymphatic fluid to drain from the extremity and is most commonly performed in the hand or forearm, which leads to immediate improvement in the distal upper extremity. We typically favor performing a true anastomosis rather than using another technique and also prefer an end-to-end orientation that has proven to have superior long-term patency rates, although there are studies supporting other orientations such as an end-to-side or a side-to-end orientation.^{31,32} The vascularized inguinal nodes are placed into the axilla, which mandates a thorough scar release in the axilla that has also been found to improve drainage as well as patients' quality of life as limitations in range of motion are common complaints. The release also creates a pocket for the

lymph node transfer, so the authors favor placing the VLNT proximally rather than in the forearm. However, most agree that the lymph node transfer requires a minimum of 6 to 12 months before adequate lymphangiogenesis has occurred to improve the drainage from the arm.^{9,33} By coupling the two techniques, patients have the maximal benefit with immediate improvement following the operation, and then will have a further improvement as the lymph nodes become functional. In the authors' opinion, this provides the most optimal outcomes for patients suffering from BCRL.

Discussion

BCRL is an underappreciated problem in patients undergoing treatment for breast cancer. The incidence can be nearly half of patients who have had multimodality treatment including an axillary dissection, taxane-based chemotherapy, and radiation therapy.^{13–15} Unfortunately, there is currently no cure for lymphedema; however, tremendous advancements have been made in surgical management with high success rates demonstrated in numerous large volume studies.^{34,35} When performed by trained, skilled, experienced microsurgeons, the physiologic procedures including LVB and VLNT are remarkably reliable and effective. Currently, there is no clear algorithm or definitive studies dictating whether one approach is superior to the other; however, there is no question that experience and training are vital to achieve the most optimal outcomes. High-volume lymphedema

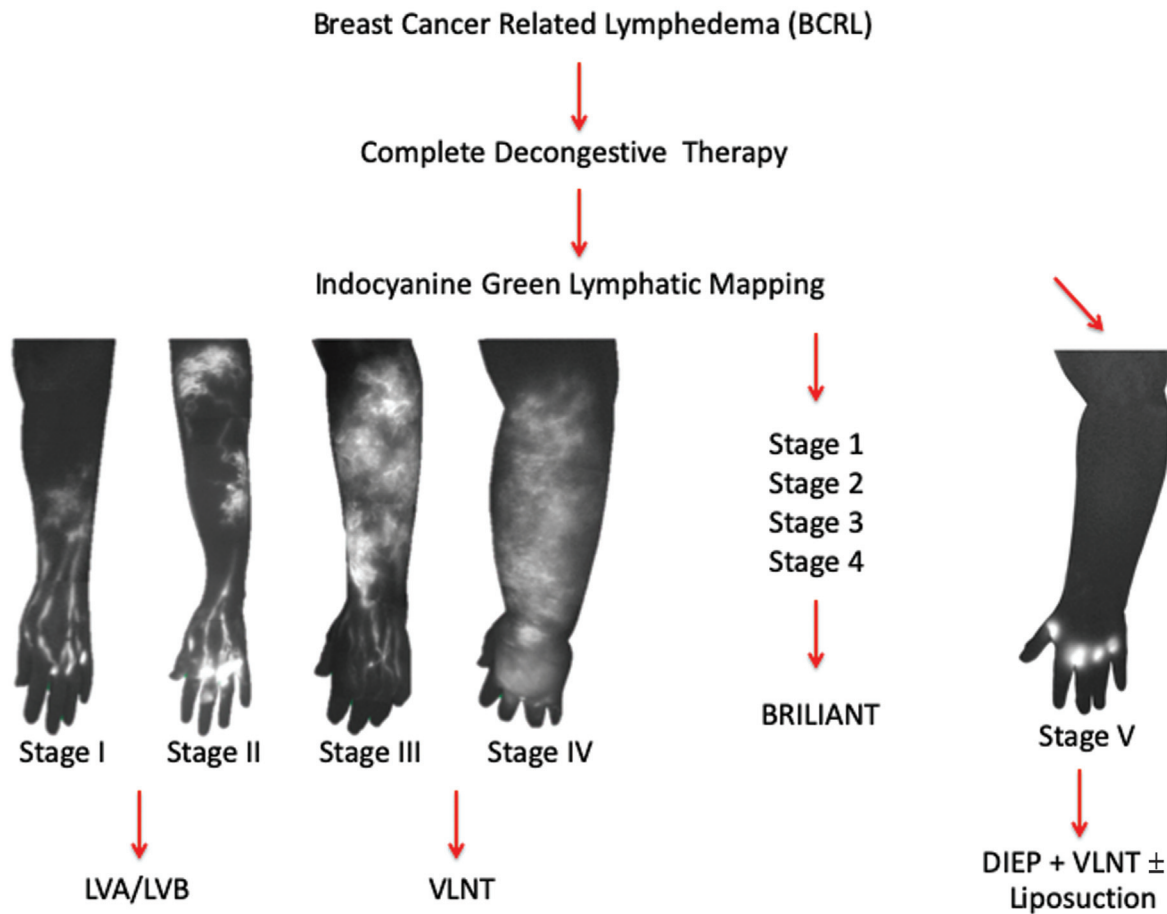


Fig. 5 Algorithm for breast cancer-related lymphedema (BCRL). Evolved algorithm for treating patients with BCRL who are also interested in breast reconstruction. The current approach combines both lymphovenous anastomosis (LVA) and vascularized lymph node transfer (VLNT) with autologous free flap breast reconstruction, termed Breast Reconstruction Including LVA and Inguinal to Axillary Node Transfer (BRILIANT).

microsurgeons may favor one technique over another, or may favor one lymph node donor site over another, but each have demonstrated high success rates and reproducible outcomes. The authors believe the selected approach should be tailored to each individual patient, but in general, we believe combining both LVB and VLNT offers patients the best possible outcome. For patients seeking breast reconstruction, the BRILIANT technique has become the standard of care. Early results have demonstrated the combined approach is superior to a DIEP and VLNT alone. Certainly, larger studies are warranted. For patients who have undergone breast conservation and develop lymphedema, the authors also favor a combined approach, and the VLNT donor site is based on a thorough discussion with the patient regarding the risks and benefits of each donor site.

Although the current techniques are highly effective in experienced centers of excellence, the next step in the evolution for lymphedema treatment is prevention. In patients who are undergoing an axillary dissection for treatment of advanced breast cancer or for staging, the immediate repair of ligated lymphatic vessels has also been found to be very effective in reducing the risks of lymphedema. The Lymphatic Microsurgical Prevention Healing Approach (LYMPHA) has demonstrated significant de-

creased incidence of lymphedema compared with patients who did not undergo microsurgical repair of lymphatic vessels.³⁶⁻³⁸ The authors refer to this as the prophylactic repair of vessels in the axilla with immediate LVB (PREVAIL) and favor identification of lymphatic vessels using axillary reverse mapping (ARM) and performing a lymphovenous anastomosis with the use of a high-magnification, high-resolution operative microscope. In our opinion, there is no cure for lymphedema although surgical treatment has proven effective, so prevention may represent the most optimal strategy for the future. The use of ICG lymphangiography has proven to be less effective in our hands compared with ARM, but if performed appropriately, both approaches achieve the same objective in the identification and localization of lymphatic vessels draining the ipsilateral upper extremity following an axillary dissection.³⁹ Once the lymphatic channels are identified, an anastomosis is performed using the super-microsurgical technique, which is challenging and should be performed by skilled microsurgeons in the authors' opinion. The authors again favor performing a true anastomosis in an end-to-end orientation if possible rather than using an intussusception technique. A modified or simplified approach has also been proposed and whether this demonstrates equivalent outcomes

compared with true super-microsurgical LVBs remains to be elucidated.⁴⁰

Overall, the field of lymphedema surgery and the treatment for BCRL is continuously evolving with novel modifications and advancements. The overwhelming body of the literature has demonstrated high success rates and significant benefit in terms of both patients' quality of life and the economic burden on the health care system. Although there is still considerable debate as to whether the LVB technique or the VLNT approach is superior, there is no question that both are effective. However, combining both LVB and VLNT may prove to be even more efficacious and is now offered to all patients seeking treatment for lymphedema. Even for patients with advanced-stage lymphedema where lymphatic channels cannot be visualized using ICG, an attempt is made to perform a bypass.⁴¹ Others have employed dynamic ultrasound and MR lymphography for identification of deeper lymphatics that are not detectable using currently available imaging devices. Consequently, for patients who have undergone a mastectomy, suffer from lymphedema, and are interested in breast reconstruction, the chimeric DIEP flap with vascularized lymph nodes addresses both concerns in a single operation, and performing a bypass at the same time can potentially be the best modality to achieve the most optimal results.

Conclusion

Super-microsurgery for lymphedema has proven to be an effective means of improving the quality of life of patients suffering from BCRL. The LVB and VLNT techniques are the main treatments for lymphedema, and combining both approaches can have a synergistic benefit, providing patients with the most optimal outcomes.

Prior Presentation

This study was presented at the 77th Congress of the Korean Society of Plastic and Reconstructive Surgeons PRS Korea 2019.

Patient consent

The patients provided written informed consent for the publication and the use of their images.

Conflict of Interest

E.I.C. is an editorial board member of the journal but was not involved in the peer reviewer selection, evaluation, or decision process of this article. No other potential conflicts of interest relevant to this article were reported.

References

- Cordova LZ, Hunter-Smith DJ, Rozen WM. Patient reported outcome measures (PROMs) following mastectomy with breast reconstruction or without reconstruction: a systematic review. *Gland Surg* 2019;8(04):441–451
- Nelson JA, Allen RJ Jr, Polanco T, et al. Long-term patient-reported outcomes following postmastectomy breast reconstruction: an 8-year examination of 3268 patients. *Ann Surg* 2019;270(03):473–483
- Rockson SG. Lymphedema after breast cancer treatment. *N Engl J Med* 2018;379(20):1937–1944
- Salgarello M, Mangialardi ML, Pino V, Gentileschi S, Visconti G. A prospective evaluation of health-related quality of life following lymphaticovenular anastomosis for upper and lower extremities lymphedema. *J Reconstr Microsurg* 2018;34(09):701–707
- Ciudad P, Agko M, Perez Coca JJ, et al. Comparison of long-term clinical outcomes among different vascularized lymph node transfers: 6-year experience of a single center's approach to the treatment of lymphedema. *J Surg Oncol* 2017;116(06):671–682
- Engel H, Lin CY, Huang JJ, Cheng MH. Outcomes of lymphedema microsurgery for breast cancer-related lymphedema with or without microvascular breast reconstruction. *Ann Surg* 2018;268(06):1076–1083
- Garza RM, Chang DW. Lymphovenous bypass for the treatment of lymphedema. *J Surg Oncol* 2018;118(05):743–749
- Chang EI, Skoracki RJ, Chang DW. Lymphovenous anastomosis bypass surgery. *Semin Plast Surg* 2018;32(01):22–27
- Patel KM, Lin CY, Cheng MH. From theory to evidence: long-term evaluation of the mechanism of action and flap integration of distal vascularized lymph node transfers. *J Reconstr Microsurg* 2015;31(01):26–30
- Gould DJ, Mehrara BJ, Neligan P, Cheng MH, Patel KM. Lymph node transplantation for the treatment of lymphedema. *J Surg Oncol* 2018;118(05):736–742
- Silva AK, Chang DW. Vascularized lymph node transfer and lymphovenous bypass: Novel treatment strategies for symptomatic lymphedema. *J Surg Oncol* 2016;113(08):932–939
- Scaglioni MF, Arvanitakis M, Chen YC, Giovanoli P, Chia-Shen Yang J, Chang EI. Comprehensive review of vascularized lymph node transfers for lymphedema: outcomes and complications. *Microsurgery* 2018;38(02):222–229
- Byun HK, Chang JS, Im SH, et al. Risk of lymphedema following contemporary treatment for breast cancer: an analysis of 7617 consecutive patients from a multidisciplinary perspective. *Ann Surg* 2021;274(01):170–178
- DiSipio T, Rye S, Newman B, Hayes S. Incidence of unilateral arm lymphoedema after breast cancer: a systematic review and meta-analysis. *Lancet Oncol* 2013;14(06):500–515
- Armer JM, Ballman KV, McCall L, et al. Factors associated with lymphedema in women with node-positive breast cancer treated with neoadjuvant chemotherapy and axillary dissection. *JAMA Surg* 2019;154(09):800–809
- Forte AJ, Boczar D, Huayllani MT, et al. Use of magnetic resonance imaging lymphangiography for preoperative planning in lymphedema surgery: a systematic review. *Microsurgery* 2021;41(04):384–390
- Kim HO, Woo KJ, Kim BS, Kang SY, Moon BS, Yoon HJ. Lymphoscintigraphic findings as indicators of lymphaticovenous anastomosis outcome in patients with extremity lymphedema: a retrospective cohort study. *Clin Nucl Med* 2021;46(07):549–555
- Chang DW, Suami H, Skoracki R. A prospective analysis of 100 consecutive lymphovenous bypass cases for treatment of extremity lymphedema. *Plast Reconstr Surg* 2013;132(05):1305–1314
- Cha HG, Oh TM, Cho MJ, et al. Changing the paradigm: lymphovenous anastomosis in advanced stage lower extremity lymphedema. *Plast Reconstr Surg* 2021;147(01):199–207
- Hara H, Mihara M. Lymphaticovenous anastomosis for advanced-stage lower limb lymphedema. *Microsurgery* 2021;41(02):140–145
- Yang JC, Wu SC, Lin WC, Chiang MH, Chiang PL, Hsieh CH. Super-microsurgical lymphaticovenous anastomosis as alternative treatment option for moderate-to-severe lower limb lymphedema. *J Am Coll Surg* 2020;230(02):216–227
- Chang EI, Chu CK, Hanson SE, Selber JC, Hanasono MM, Schaverien MV. Comprehensive overview of available donor sites for vascularized lymph node transfer. *Plast Reconstr Surg Glob Open* 2020;8(03):e2675

- 23 Nguyen AT, Suami H, Hanasono MM, Womack VA, Wong FC, Chang EI. Long-term outcomes of the minimally invasive free vascularized omental lymphatic flap for the treatment of lymphedema. *J Surg Oncol* 2017;115(01):84–89
- 24 Nguyen AT, Chang EI, Suami H, Chang DW. An algorithmic approach to simultaneous vascularized lymph node transfer with microvascular breast reconstruction. *Ann Surg Oncol* 2015;22(09):2919–2924
- 25 Chang EI, Masià J, Smith ML. Combining autologous breast reconstruction and vascularized lymph node transfer. *Semin Plast Surg* 2018;32(01):36–41
- 26 Saaristo AM, Niemi TS, Viitanen TP, Tervala TV, Hartiala P, Suominen EA. Microvascular breast reconstruction and lymph node transfer for postmastectomy lymphedema patients. *Ann Surg* 2012;255(03):468–473
- 27 Pons G, Abdelfattah U, Sarria J, Duch J, Masia J. Reverse lymph node mapping using indocyanine green lymphography: a step forward in minimizing donor-site morbidity in vascularized lymph node transfer. *Plast Reconstr Surg* 2021;147(02):207e–212e
- 28 Chang EI, Ibrahim A, Liu J, et al. Optimizing quality of life for patients with breast cancer-related lymphedema: a prospective study combining DIEP flap breast reconstruction and lymphedema surgery. *Plast Reconstr Surg* 2020;145(04):676e–685e
- 29 Chang EI, Schaverien MV, Hanson SE, Chu CK, Hanasono MM. Evolution in surgical management of breast cancer-related lymphedema: the MD Anderson Cancer Center experience. *Plast Reconstr Surg Glob Open* 2020;8(03):e2674
- 30 Schaverien MV, Chang EI. Combined deep inferior epigastric artery perforator flap with vascularized groin lymph node transplant for treatment of breast cancer-related lymphedema. *Gland Surg* 2021;10(01):460–468
- 31 Chung JH, Baek SO, Park HJ, Lee BI, Park SH, Yoon ES. Efficacy and patient satisfaction regarding lymphovenous bypass with sleeve-in anastomosis for extremity lymphedema. *Arch Plast Surg* 2019;46(01):46–56
- 32 Aljindan FK, Lin CY, Cheng MH. Comparison of outcomes between side-to-end and end-to-end lymphovenous anastomoses for early-grade extremity lymphedema. *Plast Reconstr Surg* 2019;144(02):486–496
- 33 Manrique OJ, Bustos SS, Kapoor T, et al. Gastroepiploic vascularized lymph node transfer for the treatment of extremity lymphedema: comparison between middle and distal inset. *Gland Surg* 2020;9(02):528–538
- 34 Basta MN, Gao LL, Wu LC. Operative treatment of peripheral lymphedema: a systematic meta-analysis of the efficacy and safety of lymphovenous microsurgery and tissue transplantation. *Plast Reconstr Surg* 2014;133(04):905–913
- 35 Ciudad P, Manrique OJ, Bustos SS, et al. Comparisons in long-term clinical outcomes among patients with upper or lower extremity lymphedema treated with diverse vascularized lymph node transfer. *Microsurgery* 2020;40(02):130–136
- 36 Boccardo FM, Casabona F, Friedman D, et al. Surgical prevention of arm lymphedema after breast cancer treatment. *Ann Surg Oncol* 2011;18(09):2500–2505
- 37 Ozmen T, Lazaro M, Zhou Y, Vinyard A, Avisar E. Evaluation of simplified lymphatic microsurgical preventing healing approach (S-LYMPHA) for the prevention of breast cancer-related clinical lymphedema after axillary lymph node dissection. *Ann Surg* 2019;270(06):1156–1160
- 38 Feldman S, Bansil H, Ascherman J, et al. Single institution experience with lymphatic microsurgical preventive healing approach (LYMPHA) for the primary prevention of lymphedema. *Ann Surg Oncol* 2015;22(10):3296–3301
- 39 Johnson AR, Fleishman A, Granoff MD, et al. Evaluating the impact of immediate lymphatic reconstruction for the surgical prevention of lymphedema. *Plast Reconstr Surg* 2021;147(03):373e–381e
- 40 Boccardo F, Casabona F, De Cian F, et al. Lymphatic microsurgical preventing healing approach (LYMPHA) for primary surgical prevention of breast cancer-related lymphedema: over 4 years follow-up. *Microsurgery* 2014;34(06):421–424
- 41 Pereira N, Lee YH, Suh Y, et al. Cumulative experience in lymphovenous anastomosis for lymphedema treatment: the learning curve effect on the overall outcome. *J Reconstr Microsurg* 2018;34(09):735–741