

CASE REPORT

An atypical case of atypical pneumonia

Koshi Ota MD, MPH | Ryo Iida MD | Kanna Ota MD | Masahide Sakaue MD |
 Kohei Taniguchi MD, PhD | Masao Tomioka MD | Masahiko Nitta MD, PhD |
 Akira Takasu MD, PhD

Department of Emergency Medicine, Osaka Medical College, Takatsuki, Japan

Correspondence

Koshi Ota, Department of Emergency Medicine, Osaka Medical College, Takatsuki City, Osaka, Japan.
 Email: emm006@osaka-med.ac.jp

Abstract

Atypical pneumonia has been thought to account for 7%-20% of community-acquired pneumonia (CAP). The treatment for the pathogens that cause atypical pneumonia is different from that of other bacterial pneumonia. Therefore, identification of the causative pathogen in a primary care situation is crucial for adequate treatment of CAP. *Mycoplasma pneumoniae* infection is prevalent in the general population, but *Mycoplasma pneumoniae* with extrapulmonary symptoms is relatively rare. Herein, we report a case of CAP because of *M. pneumoniae* that presented with a wide variety of extrapulmonary diseases. Delayed administration of appropriate antibiotics may contribute to development of extrapulmonary manifestations.

KEYWORDS

community-acquired pneumonia, family medicine, infection, respiratory disease

1 | INTRODUCTION

Atypical pneumonia, which is caused by *Mycoplasma pneumoniae*, *Legionella* spp., *Chlamydia pneumoniae*, *Chlamydia psittaci*, and viruses, has been thought to account for 7%-20% of community-acquired pneumonia (CAP).¹ The treatment for the pathogens that cause atypical pneumonia is different from that of other bacterial pneumonia. Therefore, identification of the causative pathogen in an emergency situation is crucial for adequate treatment of CAP. *Mycoplasma pneumoniae* is one of the most common causes of atypical pneumonia that can occur at any age and most frequently during the fall and winter seasons, but may develop year-round. *Mycoplasma pneumoniae* infection is prevalent in the general population, but *M. pneumoniae* with extrapulmonary symptoms is relatively rare.² Herein, we report a case of CAP because of *M. pneumoniae* that presented with a wide variety of extrapulmonary diseases.

2 | CASE PRESENTATION

A 28-year-old healthy woman who had fever and dry cough was referred to our emergency department for evaluation of left-sided pneumonia.

Notation of prior abstract publication/presentation: None.

Six days prior to admission, she started to have flulike symptoms and persistent fever, for which she took loxoprofen and acetaminophen. Two days prior to admission, she consulted a clinic, where chest radiograph did not reveal any sign of infection. The day of admission, she went to another clinic for further workup and chest computed tomography (CT) showed left lung consolidation (Figure 1A); thereafter, she was referred to our emergency department. She worked as a nurse at our facility without occupational exposure to chemicals or toxins. She had no prior medical problems or surgeries and denied cigarette smoking, alcohol abuse, and illicit drug use.

Physical examination showed a young woman of average built, with clear mental status, temperature of 36.6°C, pulse rate of 114 beats per minute, respiratory rate of 24 breaths per minute, blood pressure of 120/70 mm Hg, and oxygen saturation of 96% on ambient air. Air entry was distant on the left lung; there were no rales on the bilateral lungs. Heart sounds were normal, and there was no abdominal tenderness or organomegaly. The initial laboratory examination showed mild leukocytopenia (white blood cell count of 3200/mm³ with 77.8% neutrophils) and elevated C-reactive protein (12.36 mg/dL). She had no anemia (hemoglobin, 13.2 g/dL), thrombocytopenia (202 000/ μ L), and renal failure (creatinine, 0.6 mg/dL). Serum aspartate aminotransferase (AST) was mildly elevated at

This is an open access article under the terms of the Creative Commons Attribution-NonCommercial License, which permits use, distribution and reproduction in any medium, provided the original work is properly cited and is not used for commercial purposes.

© 2018 The Authors. *Journal of General and Family Medicine* published by John Wiley & Sons Australia, Ltd on behalf of Japan Primary Care Association.

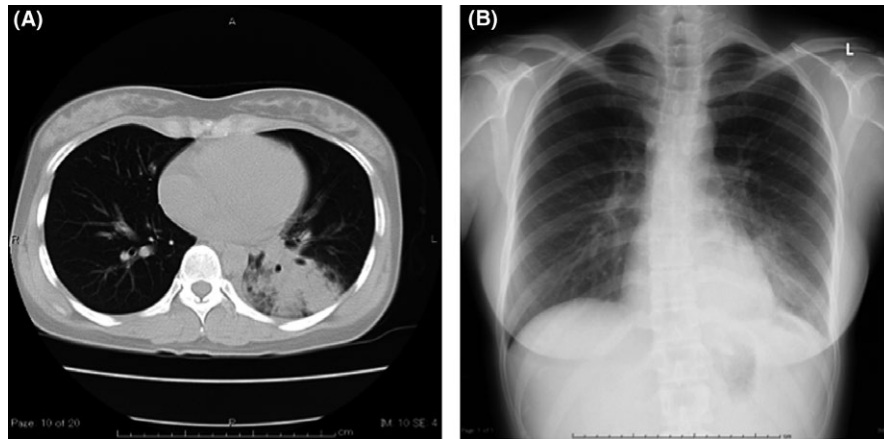


FIGURE 1 A, Computed tomography on the day of admission shows consolidation with air bronchogram. B, Chest radiograph on the day of admission shows left lower lobe consolidation without silhouette sign

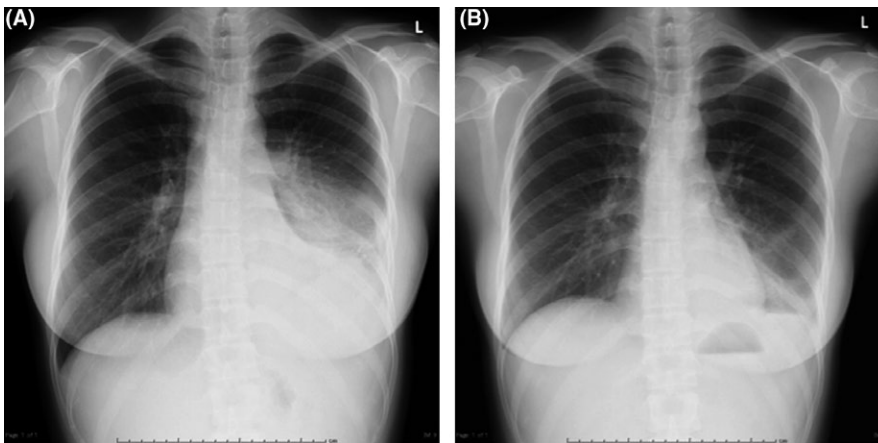


FIGURE 2 A, Chest radiograph on the 4th day of admission shows left lower lobe consolidation with silhouette sign. B, Chest radiograph on the day of discharge shows improvement of left lower lobe consolidation

49 IU/L, but serum alanine aminotransferase (ALT) level was normal at 21 IU/L. Test for *M. pneumoniae* ribosomal protein using a rapid antigen kit (Ribotest Mycoplasma®; Asahi Kasei Pharma Co., Tokyo, Japan) was negative. Her initial chest radiograph showed left lower lobe consolidation without silhouette sign (Figure 1B).

She was admitted and was started on ampicillin-sulbactam. Her symptoms and chest CT were compatible with Gram-positive bacterial pneumonia, but unlikely to associate with *M. pneumoniae* as a result of negative Ribotest. Thus, ampicillin-sulbactam, which was effective on the bacterial pneumonia, was selected as the empirical antibiotic therapy. However, on the 4th day of admission, her symptoms got worse with a temperature of 40.6°C and oxygen saturation of 94%. Therefore, antibiotic treatment was changed to meropenem to cover a broad range of pathogens including Gram-negative bacteria such as extended spectrum beta-lactamase producing organisms and low-flow oxygen at 2 L/min was started. Her fever persisted and repeat chest radiograph revealed left lower lobe consolidation with silhouette sign (Figure 2A). *Mycoplasma pneumoniae* IgM antibody titer was 1:160. On the 6th day of admission, there was no symptomatic improvement with meropenem; there was persistence of tachycardia at 120 beats per

minute, creatine kinase was at 632 IU/L, and the *M. pneumoniae* IgM antibody titer increased to 1:320 and acid fast-stained smears of *Mycobacterium tuberculosis* were negative. Therefore, oral levofloxacin was started. On the 8th day of admission, there was gradual improvement of symptoms; however, the liver enzymes increased to a maximum of AST 632 IU/L and ALT 720 IU/L. A drug-induced lymphocyte stimulation test (DLST) did not show any abnormal results for the administered agents, except oral acetaminophen and loxoprofen. Nevertheless, she was discharged after confirming that the IgM antibody titer was 1:2560 and that the chest radiograph consolidation has resolved (Figure 2B). Five days after discharge, her follow-up laboratory examination was normal, except for the mildly elevated serum liver enzymes at AST of 48 (normal 10-35) IU/L and ALT of 77 (5-35) IU/L.

3 | DISCUSSION

Mycoplasma pneumoniae infection has been reported to be most common among patients younger than 50 years of age and without significant comorbid conditions.³ However, the diagnosis of CAP

because of *M. pneumoniae* is sometimes delayed in the emergency situation because the clinical laboratory findings are of limited value in making the diagnosis. In this case, detection of *M. pneumoniae* was performed using rapid antigen kit, albeit the lower diagnostic sensitivity compared with the genetic method.⁴ We calculated the negative likelihood ratio of Ribotest of 0.315, which might be proper value to deny the infection because of low pretest probability of *M. pneumoniae* infection at that time. Her initial chest radiograph and CT showed left lower lobe consolidation, which was diagnosed as bacterial CAP.

Delayed treatment with appropriate antibiotics might be one of the reasons for the occurrence of extrapulmonary manifestations of *M. pneumoniae* infection; in fact, cardiac, dermatologic, gastrointestinal, hematologic, musculoskeletal, neurologic, and urogenital complications reportedly occurred in up to 25% of patients.^{2,5} Hepatic and cardiac damage caused by *M. pneumoniae* infection was reportedly induced by a combination of autoimmunity response and inflammatory cytokines.⁶ The incidence of hepatitis because of *M. pneumoniae* infection has been thought to be rare,² although it was reported to be 7.7% in Korea.⁷ In this case, drug-induced hepatitis was unlikely because the hepatic enzyme levels were elevated before initiation of treatment and dropped after treatment. However, the DLST results were positive for oral acetaminophen and loxoprofen, which should be considered as a cause of hepatitis. However, these medicines had already been administered before hospitalization, while the liver enzymes peaked on the 8th hospital day and the onset time did not appear to match the regimen of these medicines. Therefore, we believed that the hepatitis was more likely caused by the delayed treatment. Cardiac involvement of *M. pneumoniae* infection is also relatively rare, with an incidence ranging between 1% and 8.5%.² In this case, the tachycardia and increased cardiac enzyme, which were probably associated with *M. pneumoniae*, gradually resolved with improvement of the respiratory symptoms.

Although our case did not meet the Infectious Diseases Society of America/American Thoracic Society criteria for severe CAP,³ the patient might have been in a severe condition despite the fact that no pathogen was identified. Appropriate initial treatment is the key for a favorable outcome of *M. pneumoniae* CAP and prompt administration of appropriate antibiotics with steroids is required for severe cases.^{8,9} Although her symptoms got better with levofloxacin, we should have administered corticosteroid as a cellular immune suppressor with antibiotic treatment. We did not use macrolide first because the prevalence of macrolide-resistant *M. pneumoniae* remains high in Japan.¹⁰ One study reported the prevalence of macrolide-resistant *M. pneumoniae* in adult patients with CAP was 100%. The prevalence of azithromycin-resistant *M. pneumoniae* was reported 72%, and tuberculosis test was negative in this patient; thus, we

chose levofloxacin instead of macrolide antibiotics. Because the patient worked at our medical facility as a nurse, we did not choose fluoroquinolone initially because *M. tuberculosis* was a possible etiology, and fluoroquinolone treatment might render the culture results negative and delay the diagnosis.

In conclusion, based on this experience on a case of CAP because of *M. pneumoniae*, delayed administration of appropriate antibiotics may contribute to development of extrapulmonary manifestations.

CONFLICT OF INTEREST

The authors have stated explicitly that there are no conflicts of interest in connection with this article.

REFERENCES

1. Klement E, Talkington DF, Wasserzug O, et al. Identification of risk factors for infection in an outbreak of *Mycoplasma pneumoniae* respiratory tract disease. *Clin Infect Dis*. 2006;43:1239–45.
2. Waites KB, Talkington DF. *Mycoplasma pneumoniae* and its role as a human pathogen. *Clin Microbiol Rev*. 2004;17:697–728, table of contents.
3. Mandell LA, Wunderink RG, Anzueto A, et al. Infectious Diseases Society of America/American Thoracic Society Consensus Guidelines on the Management of Community-Acquired Pneumonia in Adults. *Clin Infect Dis*. 2007;44(suppl 2):S27–72.
4. Miyashita N, Kawai Y, Kato T, et al. Rapid diagnostic method for the identification of *Mycoplasma pneumoniae* respiratory tract infection. *J Infect Chemother*. 2016;22:327–30.
5. Narita M. Classification of extrapulmonary manifestations due to *Mycoplasma pneumoniae* infection on the basis of possible pathogenesis. *Front Microbiol*. 2016;7:1–9.
6. Fan Q, Meng J, Li P, Liu Z, Sun Y, Yan P. Pathogenesis and association of *Mycoplasma pneumoniae* infection with cardiac and hepatic damage. *Microbiol Immunol*. 2015;59:375–80.
7. Kim KW, Sung JJ, Tchah H, et al. Hepatitis associated with *Mycoplasma pneumoniae* infection in Korean children: a prospective study. *Korean J Pediatr*. 2015;58:211–7.
8. Izumikawa K, Izumikawa K, Takazono T, et al. Clinical features, risk factors and treatment of fulminant *Mycoplasma pneumoniae* pneumonia: a review of the Japanese literature. *J Infect Chemother*. 2014;20:181–5.
9. Miyashita N, Obase Y, Ouchi K, et al. Clinical features of severe *Mycoplasma pneumoniae* pneumonia in adults admitted to an intensive care unit. *J Med Microbiol*. 2007;56:1625–9.
10. Tanaka T, Oishi T, Miyata I, et al. Macrolide-resistant *Mycoplasma pneumoniae* infection, Japan, 2008–2015. *Emerg Infect Dis*. 2017;23:1703–6.

How to cite this article: Ota K, Iida R, Ota K, et al. An atypical case of atypical pneumonia. *J Gen Fam Med*. 2018;19:133–135. <https://doi.org/10.1002/jgf2.179>