

## Mycobacterium avium intracellulare complex causing olecranon bursitis and prosthetic joint infection in an immunocompromised host



Eugene M. Tan<sup>a,\*</sup>, Jasmine R. Marcelin<sup>b,1</sup>, Erin Mason<sup>b,2</sup>, Abinash Virk<sup>b,3</sup>

<sup>a</sup> Department of Medicine, Mayo Clinic, 200 First Street SW Rochester, MN 55905, USA

<sup>b</sup> Division of Infectious Diseases, Mayo Clinic, 200 First Street, SW Rochester, MN 55905, USA

### ARTICLE INFO

#### Article history:

Received 30 June 2015

Revised 10 November 2015

Accepted 25 November 2015

### ABSTRACT

**Case:** A 73-year-old immunocompromised male presented with recurrent left elbow swelling due to *Mycobacterium avium intracellulare* complex (MAC) olecranon bursitis. 3 years after completing MAC treatment, he underwent right total knee arthroplasty (TKA). 1 year later, he developed TKA pain and swelling and was diagnosed with MAC prosthetic joint infection (PJI). He underwent TKA resection, reimplantation, and 12 months of anti-MAC therapy. This patient is the seventh case report of MAC olecranon bursitis and the third case report of MAC PJI. He is the only report of both MAC olecranon bursitis and PJI occurring in the same patient.

**Informed consent:** This patient was informed and agreed to the publication of this material.

© 2015 Published by Elsevier Ltd.

This is an open access article under the CC BY-NC-ND license (<http://creativecommons.org/licenses/by-nc-nd/4.0/>).

### Introduction

Nontuberculous mycobacteria (NTM) comprise over 125 species and are ubiquitous in soil, water, and animals. *Mycobacterium avium intracellulare* complex (MAC) is the most common pathogenic NTM species and consists of *M. avium* and *M. intracellulare*, which are indistinguishable based on traditional laboratory testing. MAC usually causes pulmonary disease but may also cause lymphatic, skin/soft tissue, skeletal, or disseminated disease. Water sources, such as recirculating hot-water systems, are the reservoir for most MAC infections.[1] We illustrate a rare case of MAC causing both olecranon bursitis and prosthetic joint infection (PJI) in an immunocompromised host.

### Case report

A 73-year-old male with history of multiple myeloma (in remission for 3 years after thalidomide and dexamethasone treatment) and chronic cough, presented to the Emergency Department with 3 days of left elbow swelling, which was diagnosed as olecranon bursitis

based on clinical presentation and X-ray (Fig. 1). There was no history of elbow trauma. His bursitis improved with a steroid injection but recurred 2 months later and was treated with a repeat steroid injection. Unfortunately, his bursitis recurred again 2 months later, and bursa aspirate yielded a white blood cell (WBC) count of 45,708 with 98% neutrophils, suspicious for septic bursitis. Bacterial cultures were negative, and he had not been on antibiotics previously. He received a 14-day course of cephalexin.

Because the elbow was still edematous after 8 days of cephalexin, he underwent elbow debridement, which revealed purulent fluid with erythematous grayish-brown tissue. Histology showed acutely inflamed synovium consistent with infection. 2 out of 3 samples were smear-positive for acid-fast bacilli. All 3 operative mycobacterial cultures and the initial aspiration grew MAC.

On review of systems, he mentioned a chronic productive cough. The patient smoked a pipe for 10 years but quit 65 years ago. He had no formal diagnosis of COPD. Sputum cultures grew MAC. A chest X-ray showed basal atelectasis and multiple bilateral calcified pleural plaques, consistent with prior asbestos exposure (Fig. 2). There was no significant change compared to a chest X-ray done 3 years prior to presentation, and tuberculosis skin testing was negative. Other exposures included gardening, hot-tub use, and a pet dog.

The MAC isolate was susceptible to rifabutin, ethambutol, and clarithromycin; intermediate to rifampin, streptomycin, and moxifloxacin; and resistant to ciprofloxacin, kanamycin, cycloserine, ethionamide, and amikacin. His initial treatment regimen included clarithromycin 500 mg PO BID, ethambutol 1600 mg PO daily, and

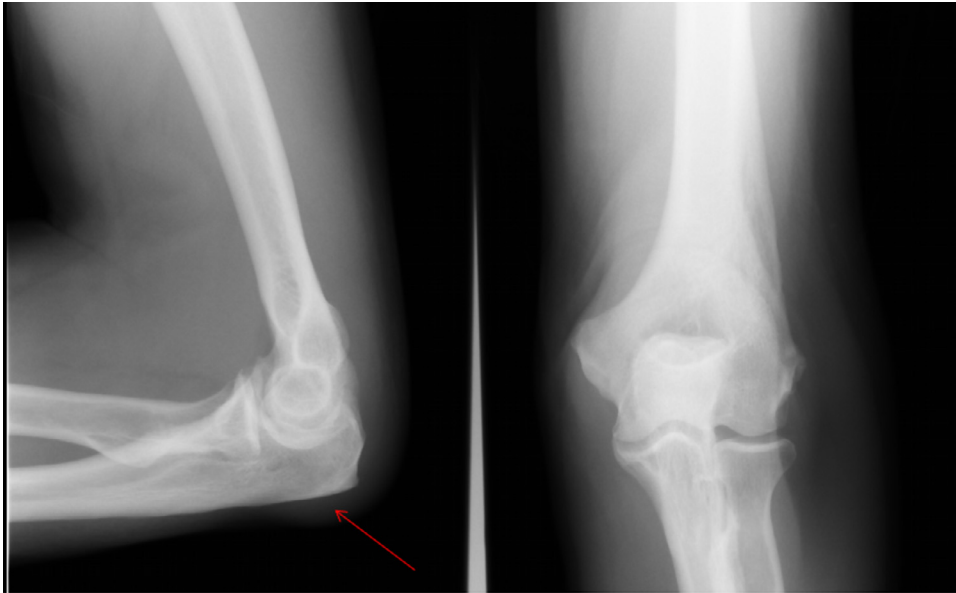
\* Corresponding author. Tel.: +1 507 284 9456.

E-mail addresses: [Tan.Eugene@mayo.edu](mailto:Tan.Eugene@mayo.edu) (E.M. Tan), [Marcelin.Jasmine@mayo.edu](mailto:Marcelin.Jasmine@mayo.edu) (J.R. Marcelin), [Mason.Erin@mayo.edu](mailto:Mason.Erin@mayo.edu) (E. Mason), [virka@mayo.edu](mailto:virka@mayo.edu) (A. Virk).

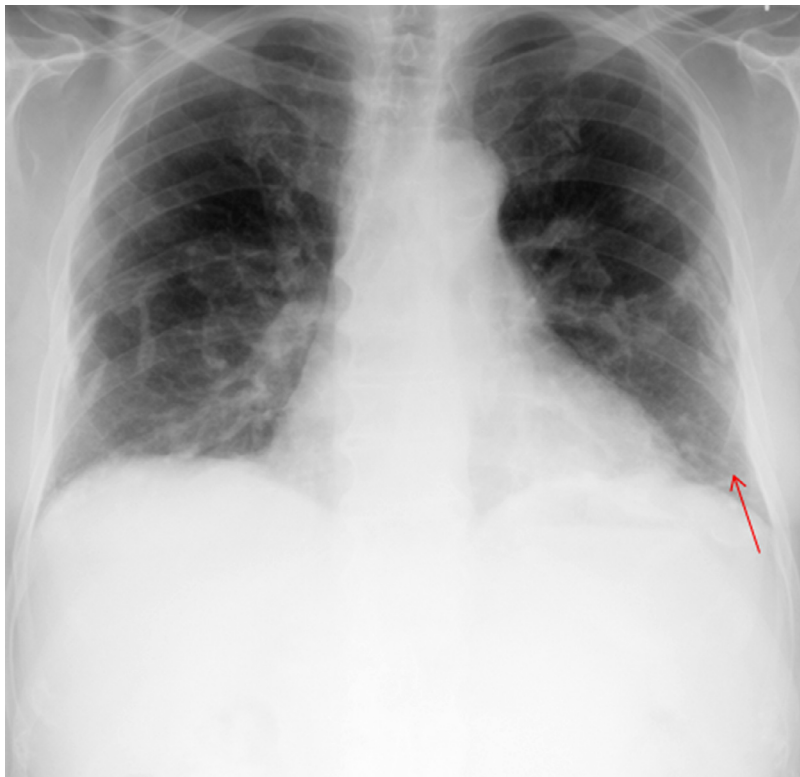<sup>1</sup> Tel.: +1 507 284 3309.

<sup>2</sup> Tel.: +1 507 284 3309.

<sup>3</sup> Tel.: +1 507 538 0030.



**Fig. 1.** Left elbow X-ray (left panel: lateral view, right panel: anteroposterior view) shows soft tissue swelling (red arrow) overlying the extensor surface of the olecranon, consistent with olecranon bursitis. There is also a tiny olecranon spur and minimal bone spurring at both humeral epicondyles. (For interpretation of the references to color in this figure legend, the reader is referred to the web version of this article).

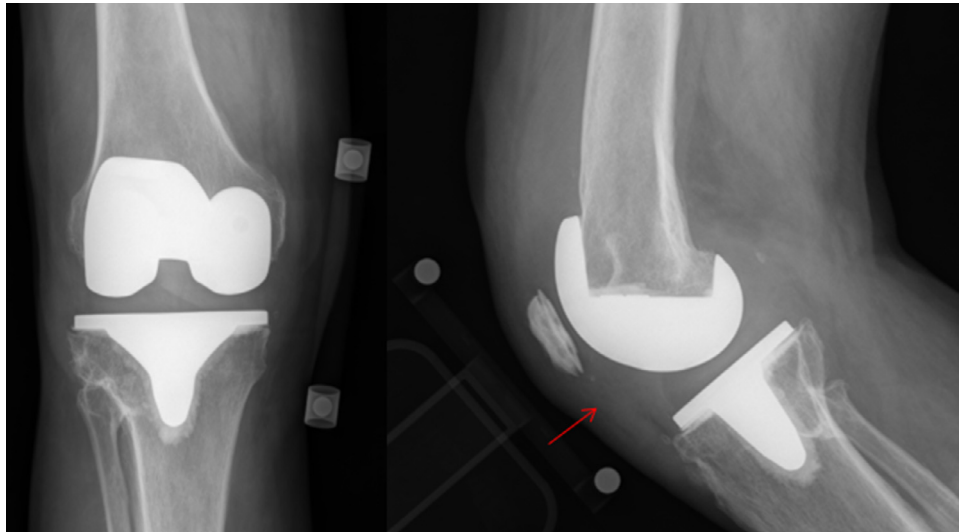


**Fig. 2.** Anteroposterior view of chest X-ray shows basal atelectasis and multiple bilateral calcified pleural plaques (red arrow) consistent with prior asbestos exposure. (For interpretation of the references to color in this figure legend, the reader is referred to the web version of this article).

rifabutin 300 mg once daily. The rifabutin was discontinued 3 weeks into therapy due to neutropenia and transaminitis. His bursitis resolved after a 12-month course of ethambutol and clarithromycin. Repeat sputum cultures were not obtained after completion of therapy.

One year later, his multiple myeloma recurred, and he was started on lenalidomide and dexamethasone. Around this time, he was also diagnosed with seronegative rheumatoid arthritis (RA) and initiated methotrexate. 3 years after completing his MAC treatment, he un-

derwent an elective right total knee arthroplasty (TKA) for degenerative joint disease. This procedure was performed at an outside facility with presumed peri-operative prophylaxis. One year later, he developed right TKA pain, instability, and swelling. X-ray showed a well-seated right TKA with a large effusion (Fig. 3). C-reactive protein (CRP) was elevated at 13.5 mg/L (reference range < 8 mg/L), and erythrocyte sedimentation rate (ESR) was elevated at 65 mm/h. Synovial fluid aspiration yielded 4524 total nucleated cells; 57% neutrophils,



**Fig. 3.** Right knee X-ray shows a well-seated TKA with large effusion or synovitis (red arrow). Left panel shows an anteroposterior view of the standing knee. Right panel shows a lateral view of the knee in flexion. (For interpretation of the references to color in this figure legend, the reader is referred to the web version of this article).

and 39% monocytes. The synovial fluid aspirate grew MAC. He underwent TKA resection with placement of a vancomycin/tobramycin impregnated spacer. Histology was negative for acute inflammation or granulomas. All 4 surgical tissue samples grew MAC. His multiple myeloma chemotherapy and methotrexate for RA were held.

His TKA MAC isolate was still susceptible to ethambutol and clarithromycin. Although it was previously susceptible to rifabutin, it now demonstrated intermediate susceptibility. He was initially started on clarithromycin, ethambutol and rifabutin, but due to recurrent transaminitis and neutropenia, he was continued on dual therapy with ethambutol and clarithromycin for 6 months prior to consideration for reimplantation. Pre-reimplantation CRP was normal at 4.8 mg/L, and ESR was 49 mm/h. Although still on therapy, the right knee synovial fluid was aspirated prior to reimplantation and found to be negative for mycobacterial growth.

Six weeks later, he underwent reimplantation. All 4 surgical tissue samples from reimplantation remained negative for MAC. One of 4 cultures grew coagulase-negative staphylococci, which was considered a contaminant. Pathology was negative for acute inflammation. He continued ethambutol and clarithromycin for another 6 months, to complete a total of 12 months. Then, he was placed on chronic suppression with azithromycin 1200 mg orally once a week. Fifteen months later, he successfully underwent an elective contralateral TKA, again for degenerative joint disease. His multiple myeloma went into remission, precluding further chemotherapy. His methotrexate for RA was switched to hydroxychloroquine. He continues to do well at 7 years of follow-up after the 2-stage exchange of his MAC-infected right TKA.

## Discussion

Nontuberculous mycobacteria (NTM) olecranon bursitis is very rare, with only 21 reported cases, 6 of which were due to MAC (Table 1). 38% of cases occurred in immunocompromised patients. Minor elbow trauma or bursa injection can provide a portal of entry for NTM if contaminated with soil [2,3]. Most patients with NTM olecranon bursitis typically present with mild pain that improves with multiple corticosteroid injections, but bursal swelling may worsen. Diagnosis is delayed more than 6 months in most cases. 13 out of the 21 reported cases required surgical intervention followed by prolonged anti-mycobacterial therapy [2].

This patient's subsequent MAC infection of the TKA was also interesting. In general, the microorganisms causing PJI are *S. aureus* (31.0%), coagulase-negative *Staphylococcus* (20.2%), culture-negative (15.8%), polymicrobial (7.4%), *Streptococcus* (5.8%), *Enterococcus* (3.9%), fungi (2.3%), anaerobes (0.9%), and lastly mycobacteria (0.6%) [4]. Mycobacterial species previously reported to cause PJI include *M. tuberculosis*, *M. bovis*, and the rapidly growing mycobacteria: *M. abscessus*, *M. chelonae*, *M. fortuitum*, *M. kansasii*, *M. smegmatis*, and *M. wolinskyi*. However, MAC PJI is relatively rare [5]. The pathogenesis of his infection is unclear – whether it was contamination at surgery or subsequent hematogenous spread. He had chronic respiratory tract colonization, but there is no clear mechanism to explain how MAC respiratory colonization could potentially lead to joint infection in his case. Currently, there are 2 known case reports of MAC PJI (Table 2) [5,6]. Because of the rarity of MAC PJI, optimal management is undefined. A 3-drug regimen of a macrolide, ethambutol, and a rifamycin is recommended for 6–12 months, but accepted treatment guidelines have not been established [1]. Regarding reimplantation, treatment decisions must be extrapolated from the available literature on other mycobacterial PJI's. In a 1998 case series, only 2 out of 7 patients with *M. tuberculosis* PJI underwent reimplantation, one at 20 months and other at 30 months post-resection [7]. In a 2007 case series of PJI due to rapidly growing mycobacteria (RGM), 2 patients underwent reimplantation (one at 3.5 months and one at 7.5 months post-resection) and required chronic antibiotic suppression [8].

ESR and CRP are helpful to assess clearance of bacterial infections prior to reimplantation but may be unreliable in determining timing of second-stage reimplantation in NTM PJI [9]. Our patient's ESR of 49 mm/h done one day prior to reimplantation may have been confounded by his multiple myeloma and RA; however CRP had normalized. In a 2007 case series of RGM PJI, the median ESR at diagnosis was 70.5 mm/h, and the median CRP was 6 mg/dL. In the two patients who underwent reimplantation, ESR and CRP had normalized [8]. Synovial fluid WBC count less than 1102.5 cells/uL may be an adjunctive perioperative test but only has a sensitivity of 75% and specificity of 61% and has not been studied in NTM PJI [9].

Suppressive therapy is another important question. One patient with *M. chelonae* PJI underwent resection, reimplantation, and suppressive therapy with clarithromycin and moxifloxacin. Two patients with *M. fortuitum* PJI were able to retain their prosthesis and remained asymptomatic on suppressive regimens of

**Table 1**  
6 prior case reports of olecranon bursitis due to MAC, adapted with permission from Garrigues et al. 2009.

Age (years)/sex	Symptoms	Medical history	Steroid use	Time from symptom onset to diagnosis (months)	Antibiotics	Treatment duration (months)	Number of surgeries	Outcome
58/male	Drainage	Colon carcinoma	None	6	Rifampin	1	2	Resolved
49/female	Drainage, ulcer	Mixed connective tissue disease	Oral	14	Rifampin, ethambutol, isoniazid	36	1	Recurrence
57/male	Mild pain	Psoriasis	None	>9	Ciprofloxacin, rifampin, clarithromycin	Not noted	1	Resolved
53/male	Swelling	None	Oral	7	Rifampin, ethambutol, azithromycin	8	1	Resolved
61/male	Swelling, pain	Diabetes mellitus, atrial fibrillation	Intrabursal	1	Ethambutol, clarithromycin	Not noted	1	Resolved
54/female	Swelling, pain	End-stage renal disease on hemodialysis, congestive heart failure, atrial fibrillation	Intrabursal	4	Not noted	Not noted	1	Resolved

**Table 2**  
2 prior case reports of prosthetic joint infection due to MAC.

Age/sex	Symptoms	Medical history	Steroid use	Time from symptom onset to diagnosis (months)	Antibiotics	Treatment duration (months)	Number of surgeries	Outcome
67/female	Warmth, pain, decreased mobility	Left total hip arthroplasty, systemic lupus, end-stage renal disease, kidney transplant, anal cancer	Oral	Not specified	Ethambutol, rifabutin, azithromycin	12	2 incisions & drainages, 1 explant of prosthesis, 1 reimplantation	Resolved
20/male	Pain	Bilateral hip replacements, osteoarthritis, Perthes disease, AIDS	None	<1 month	Ciprofloxacin, clarithromycin, rifampicin, clofazimine	5 (died during treatment)	1 hip aspiration, 1 resection arthroplasty	Expired

moxifloxacin, trimethoprim-sulfamethoxazole and azithromycin and levofloxacin/trimethoprim-sulfamethoxazole, respectively. However, suppressive therapy may not be feasible with other species such as *M. abscessus*, which are often resistant to most oral antibiotics [8].

This patient's MAC olecranon bursitis and PJI were separated by approximately 4 years, suggesting long-term colonization. MAC has been known to colonize the respiratory and gastrointestinal tract of patients especially those with immune compromise such as AIDS or those with structural lung disease, such as COPD or bronchiectasis. Our patient was immunocompromised with his multiple myeloma and treatment of seronegative RA [10–12]. Other risk factors for pulmonary NTM colonization include white race, age greater than or equal to 60 years, female sex, birth and residency in Canada for at least 10 years. Our patient possesses the risk factors of white race and age greater than 60 years and immune suppression for his long-term colonization with MAC [12]. This patient's MAC olecranon bursitis, followed by a MAC PJI 4 years later, is a rare phenomenon and likely related to chronic relatively asymptomatic respiratory MAC colonization.

In summary, mycobacterial PJIs are very rare, and patients often experience a delay in diagnosis. Mycobacterial cultures should be obtained in immunocompromised patients with persistent symptoms and negative bacterial cultures [2]. This is the seventh case report of MAC olecranon bursitis and the third case report of a MAC PJI. This patient is unique, as he is the only known case of both MAC olecranon bursitis and PJI occurring in the same patient. This case also highlights the rare risk of MAC PJI in immunocompromised patients who may be colonized with MAC.

#### Learning points for clinicians

1. Obtain mycobacterial cultures for persistent joint pain or swelling despite empiric antibiotics, especially if the patient is immunocompromised.

2. ESR, CRP, and synovial WBC count may be helpful to determine timing of reimplantation for patients with PJI's.
3. Discuss the option of long-term antibiotic suppression for patients with MAC PJI.

#### References

- [1] Griffith DE, et al. An official ATS/IDSA statement: diagnosis, treatment, and prevention of nontuberculous mycobacterial diseases. *Am J Respir Crit Care Med* 2007;175(4):367–416.
- [2] Garrigues GE, et al. Nontuberculous mycobacterial olecranon bursitis: case reports and literature review. *J Shoulder Elbow Surg / Am Shoulder and Elbow Surg* 2009(2):e1–5.
- [3] Zhibang Y, et al. Large-scale outbreak of infection with *Mycobacterium chelonae* subsp. *abscessus* after penicillin injection. *J Clin Microbiol* 2002(7):2626–8.
- [4] Aggarwal VK, et al. Organism profile in periprosthetic joint infection: pathogens differ at two arthroplasty infection referral centers in Europe and in the United States. *J Knee Surg* 2014;27(5):399–406.
- [5] Gupta A, Clauss H. Prosthetic joint infection with *Mycobacterium avium* complex in a solid organ transplant recipient. *Transpl Infect Dis : Off J Transpl Soc* 2009;11(6):537–40.
- [6] McLaughlin JR, Tierney M, Harris WH. *Mycobacterium avium* intracellular infection of hip arthroplasties in an AIDS patient. *J Bone Joint Surg. Br vol* 1994;76(3):498–9.
- [7] Berbari EF, et al. Prosthetic joint infection due to *Mycobacterium tuberculosis*: a case series and review of the literature. *Am J Orthop* 1998;27(3):219–27.
- [8] Eid AJ, et al. Prosthetic joint infection due to rapidly growing mycobacteria: report of 8 cases and review of the literature. *Clin Infect Dis : Off Publ Infect Dis Soc Am* 2007;45(6):687–94.
- [9] Kusuma SK, et al. What is the role of serological testing between stages of two-stage reconstruction of the infected prosthetic knee? *Clin Orthop Relat Res* 2011;469(4):1002–8.
- [10] Weinstock DM, et al. High rates of infection and colonization by nontuberculous mycobacteria after allogeneic hematopoietic stem cell transplantation. *Bone Marrow Transpl* 2003;31(11):1015–21.
- [11] Bermudez LE, et al. An animal model of *Mycobacterium avium* complex disseminated infection after colonization of the intestinal tract. *J Infect Dis* 1992;165(1):75–9.
- [12] Hernandez-Garduno E, Elwood RK. Demographic risk factors of pulmonary colonization by non-tuberculous mycobacteria. *Int J Tuberc Lung Dis : Off J Int Union Against Tuberc Lung Dis* 2010;14(1):106–12.