

## ORIGINAL RESEARCH

# Platelet-rich plasma in treatment of scar, atrophy, and sulcus: Short- and long-term results

Peak Woo MD, FACS 

Department of Otolaryngology, Head and Neck Surgery, Icahn School of Medicine at Mount Sinai, New York, NY, USA

**Correspondence**

Peak Woo, MD FACS, 300 Central Park West 1-H, New York, NY 10024, USA.  
Email: [peakwoo@peakwoo.com](mailto:peakwoo@peakwoo.com)

**Abstract**

**Objective:** Platelet-rich plasma (PRP) is rich in growth factors and is easily obtained from blood samples. Long-term data after PRP injection into the larynx should be improved. This study reports the short-term (3 months) and long-term (12 months) voice results after PRP injection.

**Materials and Methods:** Sixty-three patients with scars ( $n = 34$ ), sulcus vocalis ( $n = 17$ ), recalcitrant nodules ( $n = 5$ ), atrophy ( $n = 4$ ), or a combination of these ( $n = 3$ ) were included (158 injections; median follow-up = 12.3 months). Stroboscopy, voice handicap index (VHI-10), and cepstral spectral index of dysphonia (CSID) before and after treatment (3 months) and at 12 months were tabulated.

**Results:** VHI-10 changed from 19.5 to 14 at 3 months and 21 to 15 in the long term. The CSID scores improved from 31 to 21 in the short term and 31 to 26 in the long term ( $p < 0.001$ , paired  $t$ -test). Patients reported improved vocal effort and stamina with slight VHI or CSID score changes. Stroboscopy revealed improved closure and mucosal waves. Patients with severe dysphonia were less likely to improve compared to those with mild to moderate dysphonia. Some patients showed short-term improvements and then deteriorated back to baseline CSID over time ( $p < .05$ , paired  $t$ -test).

**Conclusion:** Both short- and long-term improvements in voice following PRP injection have been reported. Patients with mild-to-moderate dysphonia had better outcomes. PRP injection is an alternative treatment for patients with mild-to-moderate dysphonia due to vocal fold scarring, sulcus, and atrophy.

**Level of evidence:** II Prospective case series treatment.

**KEYWORDS**

dysphonia, growth factor, injection laryngoplasty, platelet-rich plasma, sulcus vocalis, vocal fold atrophy, vocal fold scar

Presented at: The American Laryngological Association Annual Meeting, Boston, MA, May 4–5, 2023.

This is an open access article under the terms of the [Creative Commons Attribution-NonCommercial-NoDerivs](https://creativecommons.org/licenses/by-nc-nd/4.0/) License, which permits use and distribution in any medium, provided the original work is properly cited, the use is non-commercial and no modifications or adaptations are made.

© 2023 The Author. *Laryngoscope Investigative Otolaryngology* published by Wiley Periodicals LLC on behalf of The Triological Society.

## 1 | INTRODUCTION

Vocal-fold scarring, atrophy, and sulcus vocalis continue to pose challenges to laryngologists.<sup>1</sup> Multiple treatments are currently available for this condition, including augmentation laryngoplasty,<sup>2</sup> tissue implantation,<sup>3,4</sup> mucosal freeing,<sup>5</sup> steroid injection,<sup>6</sup> and laser surgery.<sup>7</sup> Despite the common use of these techniques, the results are not consistent.<sup>8</sup> Tissue regenerative procedures have gained interest because basic scientific studies have shown promise.<sup>9,10</sup> Stem cells,<sup>11,12</sup> growth factors,<sup>13</sup> and extracellular matrix<sup>14,15</sup> or a combination of these have been used in animal models and humans. The first such report was published by Hirano in 2009.<sup>16</sup> The first case of human vocal-fold injection of stem cells was reported in 2018.<sup>17</sup> In 2016, Ohno et al. reported six patients with vocal-fold atrophy who were treated with basic fibroblast growth factor (b-FGF) and showed improved vocal function.<sup>18</sup> In 2021, Hirano reported on 100 patients with scarring, atrophy, and sulcus treated with b-FGF and reported positive effects of intracordal injection of b-FGF, resulting in an improved voice with no severe adverse events.<sup>19</sup>

Platelet-rich blood (PRP) represents a cocktail of autologous growth factors. Thus, PRP could be used as an alternative to commercial growth factors for cell therapy. PRP can potentiate stem cell proliferation, migration, and differentiation. Blood-derived products are effective for human tissue repair.<sup>20</sup> PRP is widely used in cosmetic, dental, orthopedic, dermatological, and wound healing.<sup>21</sup> It has an appeal over pure growth factors owing to its ready availability and fewer regulatory hurdles.

Bhatt et al. first described the use of PRP for the treatment of vocal scars and reported improvement.<sup>22</sup> Woo and Murry showed short-term improvements in voice quality.<sup>23</sup> In a safety and efficacy study, Johns et al. showed that PRP is safe, with minor reported morbidity.<sup>24</sup> Since then, other authors have used PRP during phonosurgery,<sup>25</sup> acute vocal injury,<sup>26</sup> and in combination with fat grafting.<sup>27</sup> However, long-term PRP results are unavailable.

This study reports a prospective case series of patients treated with office PRP injections in the larynx. We report short-term (3 months) and long-term (1 year) voice results after PRP injections into the vocal folds of 63 patients. PRP is a ready and renewable source of growth factors that may be used for the same indications as in a study using growth factor therapy proposed by Hirano in 2021.<sup>19</sup> Thus, volume and pliability issues of the vocal folds resulting from scarring, sulcus, and atrophy, with the involvement of both the lamina propria and vocal ligament and muscle, may benefit from using PRP. This study also aimed to evaluate the acoustic parameters reported by patients using the voice handicap index short form (VHI-10) and objective analysis of voice in both the short and long term after PRP treatment.

## 2 | MATERIALS AND METHODS

### 2.1 | Patient selection

Between February 2019 and December 2022, a total of 158 PRP injections were administered to 63 patients. Thirty-four patients had

unilateral or bilateral vocal fold scars, 17 had unilateral or bilateral sulcus vergeture or sulcus vocalis, five had mature vocal-fold nodules, four had bilateral vocal atrophy, and three had combinations of the above. All patients had previously failed standard therapies or surgery. All patients had received prior voice or behavioral therapy. For all patients, it had been longer than 6 months after the last intervention and all had stabilized from any initial treatment effects. These treatments included voice therapy, steroid injection, laser surgery, augmentation laryngoplasty, and micro-flap techniques. All participants requested additional interventions.

All patients were recommended three monthly injections of PRP. The injection technique was trans-oral for 27 injections and trans-cervical for 131. Twenty-six injections were administered on one side, and 132 injections were administered bilaterally. All procedures were performed with laryngoscopy monitoring either during the procedure (trans-oral) or during or after the procedure (trans-cervical) to verify the placement of PRP. Institutional review board (IRB) approval was obtained for the review of voice outcomes after treatment from the Icahn School of Medicine (IRB Study 19-01251).

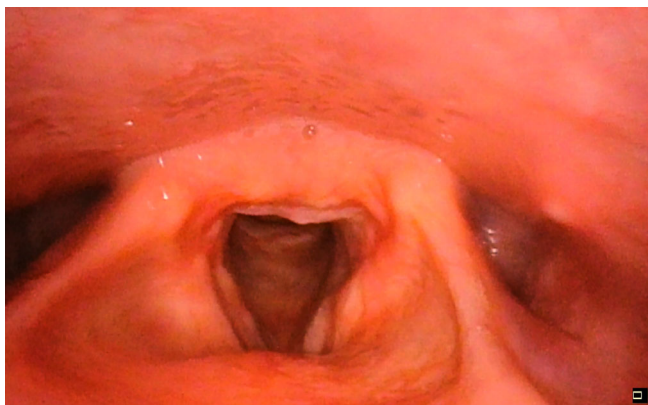
Consent for the use of PRP was obtained separately. This consent included a discussion that this study involved an off-label use of a product that is not specifically approved for application in the patient's laryngeal condition. It also included the risks and benefits of blood draw and the risks and benefits of PRP use from the known literature. Patients with a prior history of blood disorders or the use of platelet inhibitors or anticoagulants were excluded.

### 2.2 | Preparation of PRP

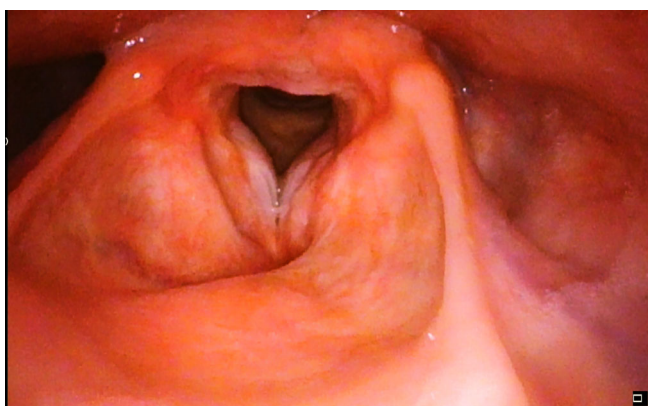
PRP was prepared in the physician's office. A phlebotomist drew blood, and the physician prepared the PRP.

Seventeen milliliters of blood were drawn non-traumatically and placed into two blood collection tubes containing ACD anticoagulant (citrate-dextrose solution = ACD solution; Vacutainer tubes, Becton-Dickinson, Franklin Lakes, NJ). The collected material underwent a double-centrifugation process.<sup>28,29</sup> A sterile technique was used. The concentration of platelets was at a minimum of 10:1 compared to that in blood plasma. The first centrifugation was 100×g for 10 min. After the first centrifugation, the plasma was transferred to a sterile tube and centrifuged at 200×g for 15 min to optimize platelet concentration. After a second centrifugation, the top 80% of the plasma was removed and discarded. The remaining 20% corresponded to the PRP. This material includes the buffy coat along with mononuclear cells, leukocytes, macrophages, hematopoietic stem cells, and platelets. The buffy coat portion contained leukocyte-rich PRP. Approximately 1.0 ml of PRP was derived from 17 ml blood. The PRP was resuspended for injection through a 1-mL syringe. The injection was performed through a standard 1.5-inch 25-G needle via the trans-cervical route or through a 23-G needle via indirect trans-oral injection (27200T; Karl Storz, Tuttlingen, Germany).

The PRP preparation method is a double-spin harvest technique outlined by Lana.<sup>28</sup>



**FIGURE 1** A patient with bilateral vocal fold scar before PRP injection.



**FIGURE 2** Same patient as Figure 1 post-injection of 0.5 cc PRP into each vocal fold using the trans-cervical technique.

### 2.3 | Administration of PRP

PRP injections were performed in one of two ways. Indirect vocal-fold injections were performed using a trans-oral indirect needle, whereas the injection was carried out trans-cervically in patients who could not tolerate the trans-oral approach.

PRP was injected trans-orally by drawing 1.0 cc of PRP into a sterile 1-cc syringe. A 23-G indirect needle was used for indirect injections (2700T, Karl Storz). The injection site was the mid-membranous vocal fold.

For trans-cervical injection, PRP was drawn into a sterile 1-cc syringe and a 25-G, 1.5-inch needle was used for injection through the cricothyroid membrane. Injection of PRP into the vocal folds was verified via fiberoptic laryngoscopy.

Unilateral injections were performed in patients with unilateral scars, whereas the other patients received bilateral injections. Video laryngoscopy was performed to verify the size and placement of the injections. Figure 1 shows a photograph of the larynx before PRP administration, and Figure 2 shows the same patient after bilateral injection of 0.5 cc of PRP (see S1–S5).

Guidance of the needle position for both procedures was done by a navigator endoscopist using a fiberoptic laryngoscope to check the position of the needle (ENF-VH scope, VISERA Elite OTV-S190; Olympus, Tokyo, Japan). PRP was injected when the mid-membranous fold was reached. Approximately 0.5 cc was placed into each fold. Repeated injections of the same PRP volume were administered. Validation of adequate injection after PRP injection revealed bulging of the paraglottic space (Figures 1 and 2).

### 2.4 | Voice evaluation

Video stroboscopy, voice recordings, and clinical examinations were performed before treatment, 3 months after the first injection (short-term results), and 6 months to 1 year after the completion of the first injection (long-term results).

The VHI-10 was administered before and after each injection and during short- and long-term evaluations.

Acoustic analysis was performed using laboratory recordings. Patients were recorded saying the Consensus Auditory-Perceptual Evaluation of Voice (CAPE-V) sentence “How hard did he hit him” five times in 10 s. The microphone-to-mouth distance was 6 inches. The ambient noise in the room was less than 55 dB. Sentences recorded over 10 s were analyzed using cepstral peak prominence (ADSV software analysis of dysphonia speech and voice, version J3.42; Pentax Medical Computer Speech Laboratory, Montvale, NJ). The Cepstral Spectral Index of Dysphonia (CSID) was also calculated. We collected the CSID scores for the CAPE-V sentences in each session. The CSID index was used as an objective treatment outcome measure.<sup>30–32</sup>

### 2.5 | Analysis and statistics

Stroboscopic recordings were performed before and after treatment. Based on a review of stroboscopy, we compared closure and mucosal waves. The stroboscopy rating is a subjective rating by the author.

The CSID scores for CAPE-V sentences and VHI-10 before treatment, short-term post-treatment, and long-term post-treatment were analyzed using two-tailed paired t-tests. A similar analysis was performed on the CSID and VHI-10 scores between the short- and long-term results. Short-term and long-term data were compared to pretreatment data. For short-term versus long-term comparisons, a paired t-test was performed only for those with short- and long-term data.

## 3 | RESULTS

The senior author administered 158 injections in 63 patients. These injections were done over 5 years. Patients who are still undergoing treatment were excluded. The inclusion criterion for the study was a minimum follow-up period of 3 months. Short-term follow-up was defined as an evaluation 3 months after the first injection.

**TABLE 1** Pre and post-treatment VHI and CSID values.

	Pre-treatment number	Pre-treatment value	Short-term treatment number	Short-term treatment value	Long-term treatment number	Long-term treatment value
VHI median	64	19.5	62	14.0 <sup>a</sup>	56	14.0 <sup>a</sup>
VHI SD	64	9.6	62	9.2	56	10.1
CSID median	64	31	60	21 <sup>a</sup>	52	26 <sup>a</sup>
CSID SD	64	21	60	26	52	23

<sup>a</sup>Paired t-test (two tail)  $p < .01$  compared to the pre-treatment value.

**TABLE 2** Short versus long-term result comparison.

	Long term treatment Number	Short term treatment Value	Long term treatment Value
VHI median	56	14.0	14.0 (N.S.)
VHI SD	56	9.5	10.0
CSID median	52	21	26 <sup>a</sup>
CSID SD	52	26	23

<sup>a</sup>Paired t test (two tail)  $p < .01$  long term compared to short term value.

Data collected more than 6 months after the first PRP injection were classified as long-term follow-up data.

There were 34 patients with scars (short- and long-term), 17 patients with sulcus vocalis, five with recalcitrant nodules, and four with vocal atrophy. The remaining 17 patients had combinations of the above.

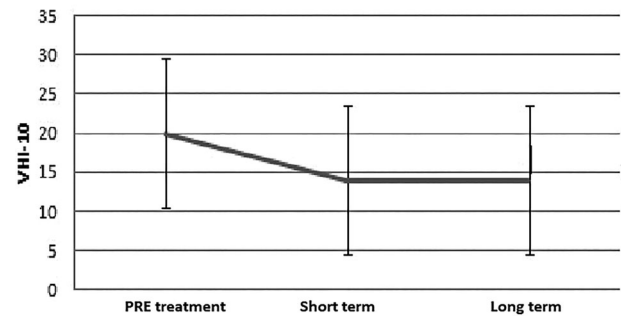
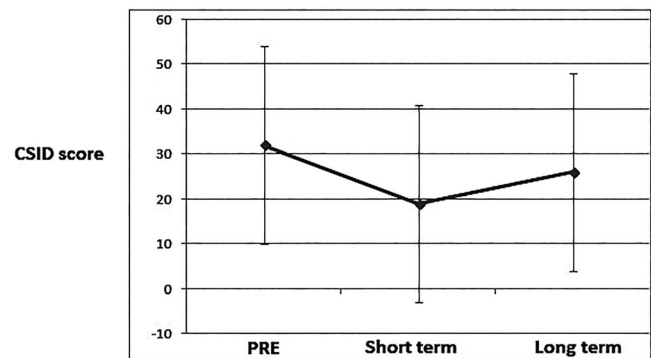
The study included 20 females and 43 males, with a median age of 43 years (standard deviation, 17 years). The youngest patient was 20 years old, and the oldest was 90 years old. There were 27 trans-oral injections and 131 trans-cervical injections administered.

All patients tolerated the injections. Three near-syncope events occurred. Most patients reported transient pain due to the injection. All patients were discharged from the clinic. Excessive cough and throat clearing were reported during the first 24 h.

The median duration of clinical follow-up was  $12.3 \pm 8$  months since the first PRP injection.

Table 1 tabulates the short- and long-term VHI and CSID scores of all patients. We obtained 62 short-term VHI data points and 56 paired short- and long-term VHI data points. In-person recordings were available for 60 short-term and 52 long-term CSID recordings. The median pretreatment, short-term, and long-term VHI values were 19.5, 14, and 14, respectively. The median CSID scores before and after treatment were both 31. The short- and long-term CSID scores were 21 and 26, respectively.

There were significant improvements in both the VHI and CSID scores compared with pretreatment in both the short- and long-term recordings (paired two-tailed t-test). No significant differences were observed between the short- and long-term results. The CSID scores also showed significant differences between pre- and post-treatment in both the short- and long-term recordings. Table 2 presents the short- and long-term VHI and CSID scores. There were no significant

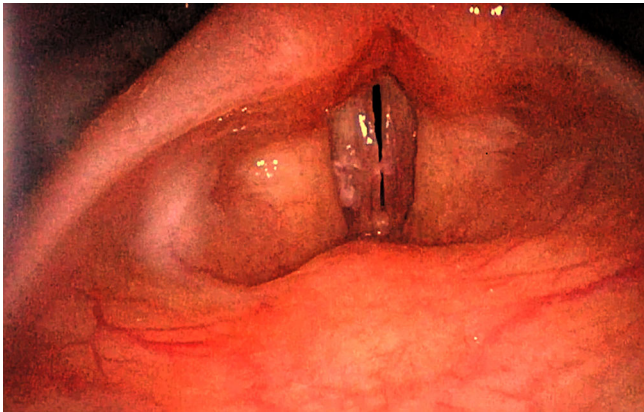
**VHI pre, post PRP short, and post PRP long****FIGURE 3** Line plot and SD of VHI values pre-treatment, short-term, and long-term after-treatment.**CSID Score before treatment, short term and long term after treatment****FIGURE 4** Line plot and standard deviation of CSID values pre-treatment, short-term, and long-term after treatment.

changes in the VHI between the short-term recordings and long-term VHI scores. However, there were significant differences in CSID scores between the short- and long-term recordings. Long-term CSID scores were worse than the short-term CSID scores.

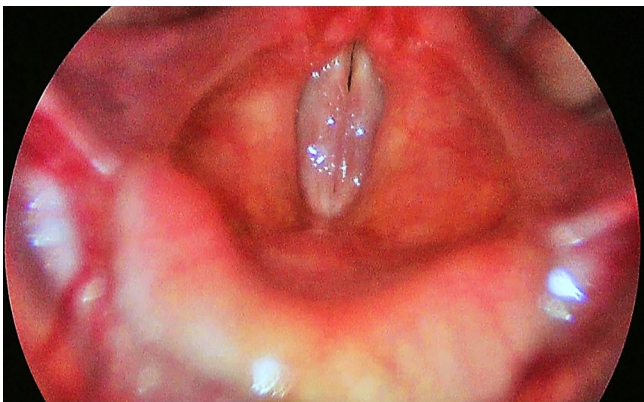
Although both the CSID score and VHI at short- and long-term recordings showed significant improvements compared to the pre-injection status, there was a significant deterioration in CSID scores between the short- and long-term CSID recordings. The VHI did not change significantly between the short- and long-term recordings.

The changes in the VHI scores are shown in Figure 3. Figure 4 shows the CSID scores at pre-, short-, and long-term post-treatment.

Subjective evaluation using videostroboscopy viewed before and after injection showed better closure and amplitude in patients with reported improvements. In contrast, those with minimal improvement showed no improvement in vocal-fold vibratory function. Although we did not systematically rate the stroboscopy findings before and after injection, we noted improved vocal-fold vibration in patients who reported a better voice. Figure 5 shows a stroboscopic photograph of a patient with persistent vocal-fold nodules before PRP treatment, and Figure 6 shows the same patient 5 months after PRP treatment. It showed better closure, with an improved mucosal wave.



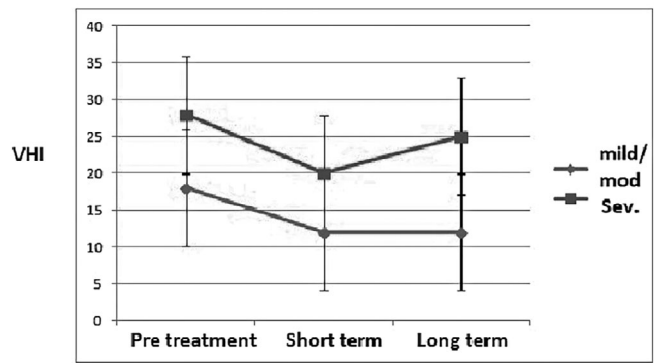
**FIGURE 5** Video frame from stroboscopy of best closure in a patient with bilateral vocal fold nodules previously treated by therapy.



**FIGURE 6** The same patient as in Figure 5 5 months post PRP treatment. There is better closure and more pliable mucosal waves.

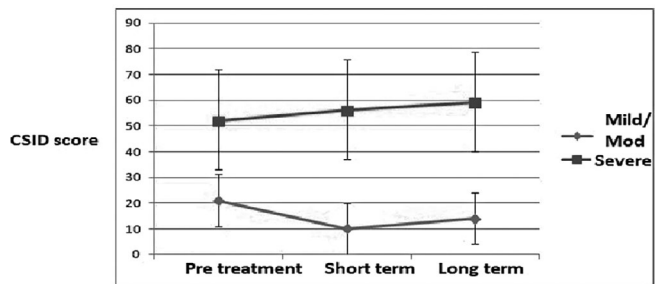
Patients with severe dysphonia had worse outcomes than those with mild-to-moderate dysphonia. Subgroup analysis was used to compare the outcomes between patients with mild and moderate dysphonia and those with severe dysphonia. The mild-to-moderate group showed better and more durable results. The results are summarized in Table 3. Table 3 tabulates the severity of dysphonia using the VHI and CSID scores. There were significant VHI and CSID scores for the severe group in the short-term follow-up, but not in the long-term follow-up. Patients with mild-to-moderate dysphonia had short- and long-term sustained improvements in the VHI and CSID scores. Figures 7 and 8 shows the changes in VHI and CSID scores according to each group. There were fewer durable changes in the CSID and VHI scores in the severe group than in the mild-to-moderate group.

**VHI-results of mild to moderate dysphonia vs. severe dysphonia**



**FIGURE 7** Line plot and standard deviation of VHI values pre-treatment, short-term, and long-term after-treatment. A mild to moderate dysphonia group versus a severe dysphonia group is shown.

**CSID score of mild to moderate and severe dysphonia patients with treatment**



**FIGURE 8** Line plot and standard deviation of CSID values pre-treatment, short-term, and long-term after treatment. A mild to moderate dysphonia group versus a severe dysphonia group is shown.

	VHI short	VHI long	CSID short	CSID long	Number
Mild to moderate	<sup>a</sup>	<sup>a</sup>	<sup>a</sup>	<sup>a</sup>	38
Severe	<sup>a</sup>	NS	<sup>a</sup>	NS	14

**TABLE 3** Analysis of mild to moderate dysphonia vs. severe dysphonia in voice outcome.

Abbreviation: NS, not significant.

<sup>a</sup>Paired t-test (two tails).

Subgroup analysis was performed to determine any differences between sulci and scarring. In both groups, there were durable improvements in VHI in both the short and long terms. We noted no significant differences between sulci and scars in their responses to PRP treatment.

## 4 | DISCUSSION

PRP is a new treatment for the management of vocal-fold scars, sulcus atrophy, recalcitrant vocal nodules, and atrophy. Many patients received prior treatment, including extensive voice therapy, steroid injection, KTP laser treatment, and operative scar lysis. Voice disabilities in this group varied from near-normal speaking function to severe dysphonia. All patients expressed a desire to seek additional treatment.

Many interventions can be considered for sulcus, scarring, atrophy, and recalcitrant nodules. These procedures have usually been reported in small clinical case studies and have yet to show uniform success. What is expected in all these disorders is the loss of mucosal pliability (scarring, sulcus, and mature nodules) and the need for volume (type I sulcus, atrophic scarring, and vocal atrophy). Thus, regenerative medicine approaches that mobilize the intrinsic healing capabilities of the body are attractive. Although there have been studies on stem cells and matrices, it is possible to use growth factors in the larynx, which have received the most recent interest. This is because of the relative ease of purifying growth factors and the relative lack of possible harm from their use.

In an important study, Hirano<sup>19</sup> showed that the injection of basic fibroblast growth factors was essentially free of adverse side effects, and many patients reported improved function. Hirano noted that patients with mild-to-moderate dysphonia often performed better than those with moderate-to-severe dysphonia. This finding may be due to the short-acting nature of growth factors injected or the lack of stem cells that are activated by stem cells. Nevertheless, many patients reported sustained improvements in voice outcomes. To replicate these results, we used PRP as a growth factor source.

The use of PRP is well accepted in facial plastic and orthopedic literature. Many patients receive PRP injections for hair rejuvenation, facial rejuvenation, and treatment of orthopedic injuries. It is an autologous source of growth factors that, if processed on-site and not subjected to manipulation, is subject to fewer regulatory hurdles than other materials.

Offering an office-based minimally invasive procedure is an attractive alternative to other more invasive procedures. PRP is procedure is readily tolerated. As reported by Johns et al.,<sup>24</sup> the use of PRP is understood to be an adjunct to help vocal-fold healing.

Although many techniques have been reported to improve vocal-fold function, regenerative medicine is an exciting new adjunct. There is growing recognition that stem cell therapy can be applied to the larynx.<sup>33-35</sup> Patient-derived PRP is a low-morbidity, low-cost, and

practical approach to cell therapy. Animal studies support the use of PRP for vocal-fold healing.<sup>36</sup> Previous studies have also noted short-term improvements with PRP use.<sup>22,24</sup>

Over the last 18 years, ample literature has been published on the use of growth factors and stem cells in laryngology.<sup>13,37-39</sup> In a report on b-FGF in 100 cases, Hirano also noted better improvements in mild-to-moderate dysphonia than in severe cases.<sup>19</sup>

The durable effects of PRP and other growth factors remain unclear.

Our observation was that while patients reported better voice outcomes, their vocal folds did not return to normal. In patients with sulcus atrophy, we still observed vocal-fold depression from the sulcus despite improved vocal-fold oscillation. Patients frequently report that they still struggle with phonation despite improved vocal function.

The improvements in both VHI and CSID were partial. There was some deterioration in the CSID scores over time. This gradual loss of functional improvement may be due to the temporary effects of the PRP, or it may be due to ongoing phono-trauma. This study also showed that, in patients with severe dysphonia, short-term improvements were short-lasting. This finding is similar to that reported by Hirano on basic human growth factor injections.<sup>19</sup>

In this study, we asked the following two questions: First, are the reported voice outcomes sustained over the next year, and second, is there a difference in the longitudinal outcome of the voice as reported by the patient and as analyzed by a computer? The data reported in this study support the use of PRP for the treatment of mild-to-moderate dysphonia. Furthermore, voice improvements were expected to last 12 months.

For patients with mild-to-moderate dysphonia, PRP injections offer an attractive office-based intervention over operative scar lysis, steroid injections, or fat injections. Surprisingly, a durable improvement was reported in VHI despite mild deterioration in CSID scores. Other measures such as vocal effort scales may be better surrogates for explaining these results.

The limitations of this study include the small sample size and the challenges of obtaining all treated patients for in-person follow-up. Despite these limitations, the improvements reported by the patients are encouraging. The safety profile of office PRP injections was established. We believe that PRP injections should be limited to patients with mild-to-moderate dysphonia. We can further refine the role of PRP in the management of scars, sulci, and atrophy.

## 5 | CONCLUSION

PRP injections into the larynx are associated with few adverse effects. PRP showed both short- and long-term improvements in the VHI and objective voice recording analysis after 1-3 injections at monthly intervals. Short- and long-term improvements appear to be more pronounced in patients with mild-to-moderate dysphonia

than in those with severe dysphonia. PRP can play an important role in patients with voice disturbances caused by vocal-fold scarring, atrophy, and sulcus vocalis. However, the use of PRP requires further investigation.

## FUNDING INFORMATION

I have no financial support for this paper or its contents.

## CONFLICT OF INTEREST STATEMENT

I have no conflict of interest related to this paper or its contents.

## ORCID

Peak Woo  <https://orcid.org/0000-0003-0144-5178>

## REFERENCES

1. Welham NV, Choi SH, Dailey SH, Ford CN, Jiang JJ, Bless DM. Prospective multi-arm evaluation of surgical treatments for vocal fold scar and pathologic sulcus vocalis. *Laryngoscope*. 2011;121:1252-1260.
2. Isshiki N, Shoji K, Kojima H, Hirano S. Vocal fold atrophy and its surgical treatment. *Ann Otol Rhinol Laryngol*. 1996;105:182-188.
3. Pitman MJ, Rubino SM, Cooper AL. Temporalis fascia transplant for vocal fold scar and sulcus vocalis. *Laryngoscope*. 2014;124:1653-1658.
4. Paniello RC, Sulica L, Khosla SM, Smith ME. Clinical experience with Gray's minithyrotomy procedure. *Ann Otol Rhinol Laryngol*. 2008;117:437-442.
5. Pontes P, Behlau M. Sulcus mucosal slicing technique. *Curr Opin Otolaryngol Head Neck Surg*. 2010;18:512-520.
6. Mortensen M. Laryngeal steroid injection for vocal fold scar. *Curr Opin Otolaryngol Head Neck Surg*. 2010;18:487-491.
7. Shoffel-Havakuk H, Sadoughi B, Sulica L, Johns MM 3rd. In-office procedures for the treatment of benign vocal fold lesions in the awake patient: a contemporary review. *Laryngoscope*. 2019;129:2131-2138.
8. Dailey SH, Ford CN. Surgical management of sulcus vocalis and vocal fold scarring. *Otolaryngol Clin North Am*. 2006;39:23-42.
9. Hirano S, Thibeault S, Bless DM, Ford CN, Kanemaru S. Hepatocyte growth factor and its receptor c-met in rat and rabbit vocal folds. *Ann Otol Rhinol Laryngol*. 2002;111:661-666.
10. Ohno S, Hirano S, Kanemaru S, et al. Transforming growth factor  $\beta$ 3 for the prevention of vocal fold scarring. *Laryngoscope*. 2012;122:583-589.
11. Hertegård S, Nagubothu SR, Malmström E, LeBlanc K. Treatment of vocal fold scarring with autologous bone marrow-derived human mesenchymal stromal cells: first phase I/II human clinical study. *Stem Cell Res Ther*. 2020;11:128.
12. Svensson B, Nagubothu SR, Cedervall J, et al. Injection of human mesenchymal stem cells improves healing of vocal folds after scar excision: a xenograft analysis. *Laryngoscope*. 2011;121:2185-2190.
13. Suzuki R, Kawai Y, Tsuji T, et al. Prevention of vocal fold scarring by local application of basic fibroblast growth factor in a rat vocal fold injury model. *Laryngoscope*. 2017;127:E67-e74.
14. Walimbe T, Panitch A, Sivasankar PM. A review of hyaluronic acid and hyaluronic acid-based hydrogels for vocal fold tissue engineering. *J Voice*. 2017;31:416-423.
15. Kobayashi T, Mizuta M, Hiwatashi N, et al. Drug delivery system of basic fibroblast growth factor using gelatin hydrogel for restoration of acute vocal fold scar. *Auris Nasus Larynx*. 2017;44:86-92.
16. Hirano S, Kishimoto Y, Suehiro A, Kanemaru S, Ito J. Regeneration of aged vocal fold: first human case treated with fibroblast growth factor. *Laryngoscope*. 2009;119:197-202.
17. Mattei A, Magalon J, Bertrand B, et al. Autologous adipose-derived stromal vascular fraction and scarred vocal folds: first clinical case report. *Stem Cell Res Ther*. 2018;9:202.
18. Ohno S, Hirano S, Yasumoto A, Ikeda H, Takebayashi S, Miura M. Outcome of regenerative therapy for age-related vocal fold atrophy with basic fibroblast growth factor. *Laryngoscope*. 2016;126:1844-1848.
19. Hirano S, Sugiyama Y, Kaneko M, Mukudai S, Fuse S, Hashimoto K. Intracordal injection of basic fibroblast growth factor in 100 cases of vocal fold atrophy and scar. *Laryngoscope*. 2021;131:2059-2064.
20. Andia I, Maffulli N. Blood-derived products for tissue repair/regeneration. *Int J Mol Sci*. 2019;20:45-81.
21. Masoudi E, Ribas J, Kaushik G, Leijten J, Khademhosseini A. Platelet-rich blood derivatives for stem cell-based tissue engineering and regeneration. *Curr Stem Cell Rep*. 2016;2:33-42.
22. Bhatt NK, Gao WZ, Timmons Sund L, Castro ME, O'Dell K, Johns MM 3rd. Platelet-rich plasma for vocal fold scar: a preliminary report of concept. *J Voice*. 2023;37(2):302.e17-302.e20.
23. Woo P, Murry T. Short-term voice improvement after repeated office-based platelet-rich plasma PRP injection in patients with vocal fold scar, sulcus, and atrophy. *J Voice*. 2023;37(4):621-628.
24. van der Woerd B, O'Dell K, Castellanos CX, et al. Safety of platelet-rich plasma subepithelial infusion for vocal fold scar, sulcus, and atrophy. *Laryngoscope*. 2023;133:647-653.
25. Gaafar A, Eldeghiedy A, ElMaghraby R, Nouh I, Donia M. The role of platelet-rich plasma in micro laryngeal surgery: a randomized, controlled trial. *J Laryngol Otol*. 2022;136:737-741.
26. Cobden SB, Oztürk K, Duman S, et al. Treatment of acute vocal fold injury with platelet-rich plasma. *J Voice*. 2016;30:731-735.
27. Tsou YA, Tien VH, Chen SH, et al. Autologous fat plus platelet-rich plasma versus autologous fat alone on sulcus vocalis. *J Clin Med*. 2022;11:725.
28. Lana JF, Vicente EF, Lana ABSD, et al. PRP experience in MOR Institute: Brazil (iMOR-research Institute for Sports Medicine, orthopedics, and regeneration). In: Duarte Lana JFS, Andrade Santana MH, Dias Belangero W, Malheiros Luzo AC, eds. *Platelet-Rich Plasma Regenerative Medicine: Sports Medicine, Orthopedic, and Recovery of Musculoskeletal Injuries*. New York Springer-Verlag; 2014:360.
29. Dhurat R, Sukesh M. Principles and methods of preparation of platelet-rich plasma: a review and author's perspective. *J Cutan Aesth Surg*. 2014;7:189-197.
30. Dejonckere PH. Cepstral voice analysis: link with perception and stroboscopy. *Rev Laryngol Otol Rhinol (Bord)*. 1998;119:245-246.
31. Awan SN, Roy N, Dromey C. Estimating dysphonia severity in continuous speech: application of a multi-parameter spectral/cepstral model. *Clin Linguist Phon*. 2009;23:825-841.
32. Peterson EA, Roy N, Awan SN, Merrill RM, Banks R, Tanner K. Toward validation of the cepstral spectral index of dysphonia (CSID) as an objective treatment outcomes measure. *J Voice*. 2013;27:401-410.
33. Sato K, Umeno H, Nakashima T. Vocal fold stem cells and their niche in the human vocal fold. *Ann Otol Rhinol Laryngol*. 2012;121:798-803.
34. Long JL. Tissue engineering for the treatment of vocal fold scar. *Curr Opin Otolaryngol Head Neck Surg*. 2010;18:521-525.
35. Morisaki T, Kishimoto Y, Tateya I, et al. Adipose-derived mesenchymal stromal cells prevented rat vocal fold scarring. *Laryngoscope*. 2018;128:E33-e40.

36. Woo SH, Jeong HS, Kim J, et al. Favorable vocal fold wound healing induced by platelet-rich plasma injection. *Clin Exp Otorhinolaryngol*. 2014;7:47-52.
37. Hirano S, Bless DM, Heisey D, Ford CN. Effect of growth factors on hyaluronan production by canine vocal fold fibroblasts. *Ann Otol Rhinol Laryngol*. 2003;112:617-624.
38. Hirano S, Nagai H, Tateya I, Tateya T, Ford CN, Bless DM. Regeneration of aged vocal folds with basic fibroblast growth factor in a rat model: a preliminary report. *Ann Otol Rhinol Laryngol*. 2005;114:304-308.
39. Gugatschka M, Ohno S, Saxena A, Hirano S. Regenerative medicine of the larynx. Where are we today? A review. *J Voice*. 2012;26(670): e677-e613.

#### SUPPORTING INFORMATION

Additional supporting information can be found online in the Supporting Information section at the end of this article.

**How to cite this article:** Woo P. Platelet-rich plasma in treatment of scar, atrophy, and sulcus: Short- and long-term results. *Laryngoscope Investigative Otolaryngology*. 2023;8(5): 1304-1311. doi:[10.1002/lio2.1143](https://doi.org/10.1002/lio2.1143)