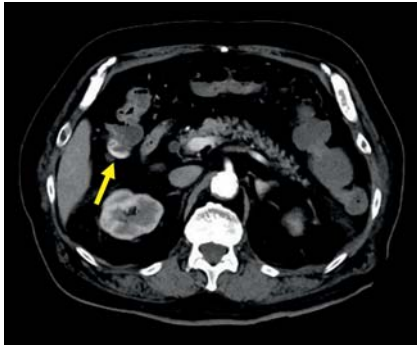
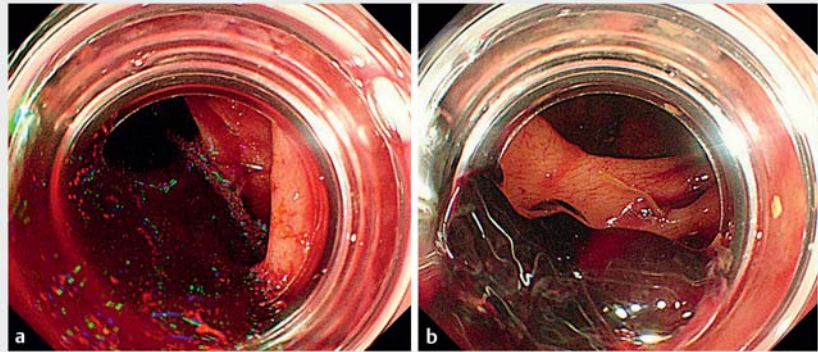


## Usefulness of gel immersion endoscopy to identify a colonic diverticulum with active bleeding

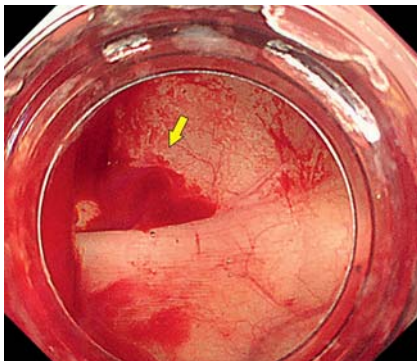
OPEN  
ACCESS



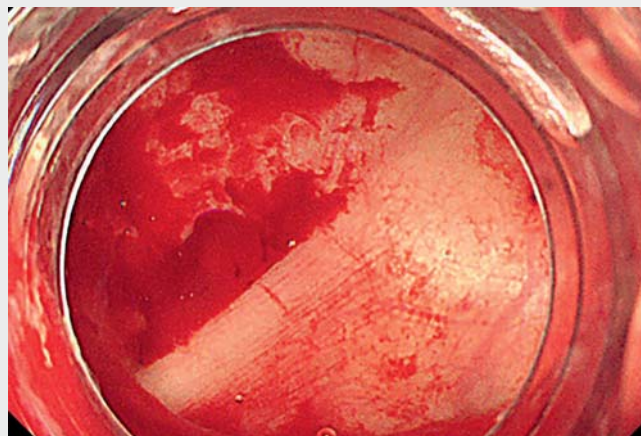
► **Fig. 1** Contrast-enhanced computed tomography revealed extravasation in the ascending colon (arrow).



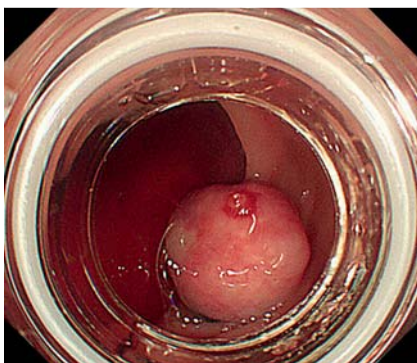
► **Fig. 2** Fresh blood and clotting were observed in the ascending colon.



► **Fig. 3** Gel immersion endoscopy showed a diverticulum with pulsatile bleeding (arrow).



► **Video 1** Gel immersion endoscopy for colonic diverticular bleeding with active bleeding.



► **Fig. 4** A vessel was visualized on the ligated diverticulum.

Management of colonic diverticular bleeding is clinically important because severe cases require transarterial embolization or surgical intervention; colonic diverticular bleeding can cause death in elderly patients with multiple comorbidities [1]. Colonoscopy enables the diagnosis and treatment of the bleeding site; however, identifying the diverticulum with active bleeding is challenging. Gel immersion endoscopy has been reported to be useful for securing the visual field

during endoscopy for gastrointestinal bleeding [2,3]. We report a case in which gel immersion endoscopy was effective in allowing the colonic diverticulum with active bleeding to be identified.

An 87-year-old man taking aspirin and apixaban for ischemic heart disease presented to our hospital with massive hematochezia from that morning. On admission, his hemoglobin level was 8.0 g/dL and he exhibited vital signs of shock. Contrast-enhanced computed tomog-

raphy revealed extravasation in the ascending colon (► **Fig. 1**). We performed emergency colonoscopy with blood transfusion. Fresh blood and clotting were observed in the ascending colon (► **Fig. 2**). However, we were unable to identify the bleeding point because of active bleeding and poor visual field. After injecting Viscoclear gel (Otsuka Pharmaceutical Factory, Tokushima, Japan) [4], the visual field improved and a diverticulum with pulsatile bleeding was identified (► **Fig. 3**, ► **Video 1**). An endoclip was placed as a marker close to this diverticulum, and endoscopic band ligation was then carried out (► **Fig. 4**). Bleeding did not recur after the treatment.

In summary, we found gel immersion endoscopy to be useful for identifying a colonic diverticulum with active bleeding.

Endoscopy\_UCTN\_Code\_TTT\_1AQ\_2AZ

### Competing interests

The authors declare that they have no conflict of interest.

### The authors

**Takaaki Kishino, Yoko Kitamura**  
Department of Gastroenterology and Hepatology, Center for Digestive and Liver Diseases, Nara City Hospital, Nara, Japan

### Corresponding author

**Takaaki Kishino, MD**  
Department of Gastroenterology and Hepatology, Center for Digestive and Liver Diseases, Nara City Hospital, 1-50-1 Higashikideracho, Nara 6308305, Japan  
t-kishino@nara-jadecom.jp

### References

- [1] Kaise M, Nagata N, Ishii N et al. Epidemiology of colonic diverticula and recent advances in the management of colonic diverticular bleeding. *Dig Endosc* 2020; 32: 240–250
- [2] Yano T, Nemoto D, Ono K et al. Gel immersion endoscopy: a novel method to secure the visual field during endoscopy in bleeding patients (with videos). *Gastrointest Endosc* 2016; 83: 809–811
- [3] Yano T, Takezawa T, Hashimoto K et al. Gel immersion endoscopy: innovation in securing the visual field – clinical experience with 265 consecutive procedures. *Endosc Int Open* 2021; 9: E1123–E1127
- [4] Yano T, Ohata A, Hiraki Y et al. Development of a gel dedicated to gel immersion endoscopy. *Endosc Int Open* 2021; 9: E918–E924

### Bibliography

*Endoscopy* 2022; 54: E794–E795  
DOI 10.1055/a-1810-6843  
ISSN 0013-726X  
published online 25.4.2022  
© 2022. The Author(s).

This is an open access article published by Thieme under the terms of the Creative Commons Attribution-NonDerivative-NonCommercial License, permitting copying and reproduction so long as the original work is given appropriate credit. Contents may not be used for commercial purposes, or adapted, remixed, transformed or built upon. (<https://creativecommons.org/licenses/by-nc-nd/4.0/>)

Georg Thieme Verlag KG, Rüdigerstraße 14, 70469 Stuttgart, Germany



### ENDOSCOPY E-VIDEOS

<https://eref.thieme.de/e-videos>



*Endoscopy E-Videos* is an open access online section, reporting on interesting cases

and new techniques in gastroenterological endoscopy. All papers include a high quality video and all contributions are freely accessible online. Processing charges apply (currently EUR 375), discounts and wavers acc. to HINARI are available.

This section has its own submission website at <https://mc.manuscriptcentral.com/e-videos>