

Breast and Axillary Lymph Nodes Metastasis five years after Radical Nephrectomy for Renal Cell Carcinoma A Case Report and Review of the Literature

Hairulfaizi H¹, Rohaizak M¹, Naqiyah I¹, Yahya ML¹, Tan GC² and Zainuddin Z¹

¹ Department of Surgery and ² Department of Pathology, Faculty of Medicine
Universiti Kebangsaan Malaysia, Kuala Lumpur, Malaysia

Abstract; Breast is an uncommon and rare site for metastasis. Primary and secondary tumors of the breast need to be differentiated as management is different. We present a 67 year old female patient with two breast lumps and an axillary lymph node, 5 years after nephrectomy for Renal Cell Carcinoma (RCC). Mammogram report showed a dense spiculated mass at right upper outer quadrant and a retroareolar mass associated with clustered micro calcifications. Fine Needle Cytology and trucut biopsy were inconclusive. Computer Topography (CT) abdomen did not show evidence of RCC recurrence. After discussion with the patient, she underwent mastectomy with axillary clearance and the final histopathology report was consistent with metastasis from RCC. The management of this case is discussed.

Key words: *Extramammary breast metastasis, Renal cell carcinoma, Post radical nephrectomy.*

Introduction

Renal cell carcinoma, which accounts for approximately 3% of all adult cancers, has a tendency to metastasize, commonly to the lungs, bones, liver, adrenal glands and brain. Metastases to the breast from extramammary tumours are uncommon and metastatic renal cell carcinoma to the breast is extremely rare accounting for 3% of the cases [1]. We report metastases to the breast and the difficulty in diagnosis. Thus far, this is the first case reported as in most cases; the metastasis to the breast is part of systemic metastases.

Case report

The patient is a 67 year old lady, diagnosed with right renal cell carcinoma in 2002 for which she underwent right radical nephrectomy. Histological examination showed a clear cell type. The pathological stage was pT2 N0 M0. Regular follow-ups with computed tomography of the abdomen were negative for 5 years. In March 2007 she noted a lump in the right breast. Clinical examination revealed a 2 x 2cm right breast swelling and a vague retro-areolar mass 1 x 1cm with an enlarged ipsilateral axillary lymph node. There were no nipple discharge or skin changes. Fine needle aspiration cytology was consistent with poorly differentiated carcinoma. The possibilities include breast carcinoma and metastatic renal cell carcinoma. A true cut biopsy was unable to confirm the diagnosis due to insufficient tissue. Mammogram (Figure 1) revealed a dense spiculated mass at right upper outer quadrant and a retroareolar mass which is associated with clustered micro-calcifications suggestive of malignancy. Breast ultrasound (Figure 2) confirmed these finding. CT thorax and abdomen showed a speculated hyper-dense lesion in the right breast and there was no evidence of local recurrence of RCC or other organ metastasis.

In view of cytological findings, mammogram and absence of distant metastases which suggested a possibility of either multicentric breast carcinoma or metastatic renal cell carcinoma, we proceeded with right mastectomy and axillary clearance. The patient made an uneventful recovery. The final histopathology report was consistent with metastatic renal carcinoma. The patient was referred to the oncologist but unfortunately defaulted

further treatment. She is currently well and disease free 24 months after metastatectomy.

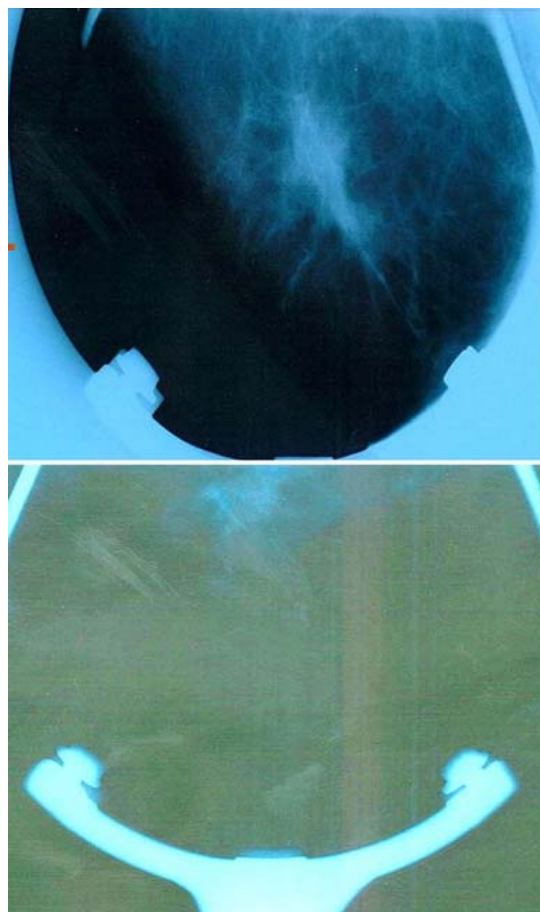


Figure 1 Mammogram: Dense speculated mass at the right upper outer quadrant and a retro-areolar mass with clustered microcalcification

Histological section (Figure 3 and 4) showed: -
Immunohistochemical studies: Positive cytokeratin(CK) , CD10 and CK7 while negative with CK20 . Only one out of 21 lymph nodes shows malignant cell infiltration. The diagnosis of metastatic renal cell carcinoma to the breast with one lymph node involvement was made.

Discussion

All malignancies have the capacity to metastasize. The incidence of secondary metastasis to the breast is uncommon and rarely reported. It is represented by nearly up to 2% of all breast swelling which account for nearly 400 cases that have been reported in the literature [2]. Malignant melanoma, leukaemia and lymphoma are the most common among all malignancies that have been described metastasizing to the breast [2].

15 cases of breast metastasis from renal cell carcinoma have been reported. 8 cases presented as the initial sign of metastasis from RCC while the rest occur after nephrectomy done for RCC. The cases presented are usually found 1 to 18 years following nephrectomy for RCC [3,4]. In the case presented, the metastasis occurred 5 years after nephrectomy. The survival rates for the patient with renal cell carcinoma, 5-year and 10-year post nephrectomies were 95% and 91% for pT1; 80% and 70% for pT2; 66% and 53% for pT3a; 52% and 43% for pT3b; and 43% and 42% for pT3c, respectively [5].

other signs that characterize the majority of primary carcinomas [6]. Micro calcifications are unusual and are mostly associated with metastatic carcinoma of the ovary, in which psammoma bodies may be abundant [7]. However, in our study, the case presented with microcalcifications as shown in the mammography study along with dense speculated mass at RUQ area. This produce suspicious of primary breast carcinoma with metastatic disease from RCC as a provisional diagnosis.

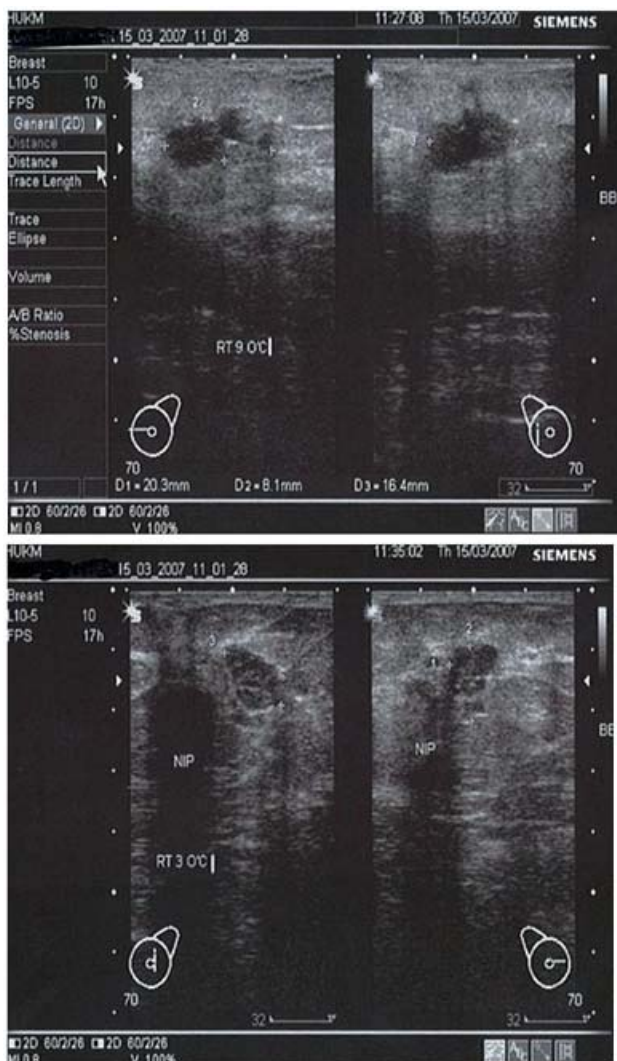


Figure 2 Ultrasound: Irregular mass with acoustic shadow at right 9 o'clock and another well-defined solid mass with irregular margin at 3 o'clock position.

The most common extra mammary metastasis in mammography finding was a well circumscribed mass with increased density but without speculation, calcifications or

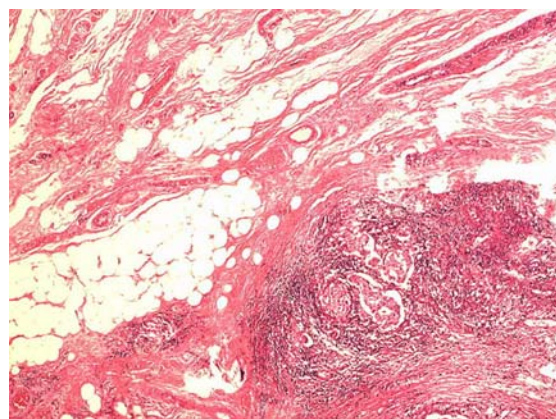


Figure 3 Tumour clusters with normal breast ducts. (2x10, HE)

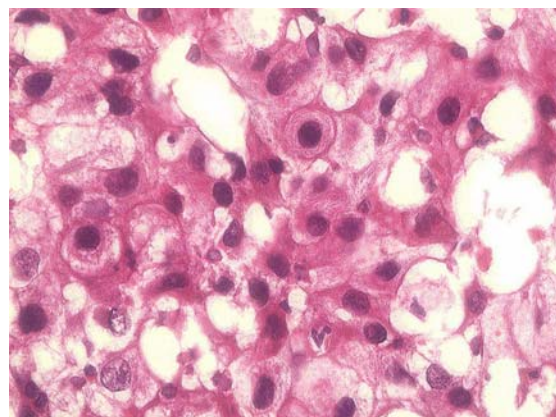


Figure 4 Malignant cells with clear to slightly eosinophilic cytoplasm. (40x10, HE)

Treatment for metastasis from RCC after a long-term cancer-free survival is removal of the tumour bloc in total followed with Immunotherapy, targetted therapy and chemotherapy. This is based on a clinical trial indicating that metastasectomy RCC (MRCC) whereby solitary and fully resectable lung metastasis, together with adequate performance status, then the treatment of choice should be metastasectomy [8]. (I do not understand this paragraph from the linguistic point of view) Best outcomes are seen with single site of RCC metastasis to lung where 50 % 5 years survival is seen compared with 19%, in patients who had more than one site of cancer removed [9].

Usually, RCC metastasis to other tissue is diagnosed after tissue biopsy and most of the time, cytological biopsy is enough to confirm the diagnosis [10]. However, this is not seen in all cases. As in our case, the Fine Needle Aspiration Cytology (FNAC) which was repeated twice suggests metastatic disease (the presence of malignant cells with predominant eosinophilic cytoplasm with

minority of them having cytoplasmic clearing cells) but cannot exclude primary breast carcinoma. Due to this limitation, tissue biopsy with Immunohistological staining (IHC) is mandatory for the definitive diagnosis.

Definitive diagnosis is important such as to prevent unnecessary mastectomy in extramammary tumour such as RCC metastasis. Treatment for metastasis from RCC after a long-term cancer-free survival is removal of the tumour bloc in total followed with Immunotherapy, Targetted therapy and chemotherapy. Alpha interferon and interleukin (IL)-2 are the two most frequently used types of immunotherapy in Metastatic Renal Cell Cancer. Unfortunately, long-term results of clinical trials indicate that only approximately 15% of patients with advanced renal cell carcinoma have an anticancer response when treated with high-dose interleukin 2 and interferon [11].

In the presented case, we have proceeded with mastectomy and axillary clearance after full discussion with the patient and the family as cytological and mammogram study were strongly suspicious of breast carcinoma with no evidence of recurrence of RCC and patient opted for mastectomy.

In summary

Primary and secondary breast carcinomas may mimic each other in clinical and radiological findings. Careful assessment and adequate tissue examination is paramount to confirm the diagnosis. Resection of isolated metastasis from RCC is feasible and can achieve long term relapse free survival.

References

1. Ahmed Alzaraa , Aleksandar Vodovnik , Hugh Montgomery , Mohammed Saeed, Narinder Sharma Et al. Breast metastasis from a renal cell cancer World Journal of Surgical Oncology 2007, 5:25
2. B. Vergier, M Trojani, and I.de Mascarel Et al. Metastases to the breast:differential diagnosis from primary breast carcinoma, J Surg Oncol. 1991; 48:112-6
3. Vassalli, V.D Ferrari, E Simoncini Et al. Solitary breast metastases from a renal cell carcinoma. Breast Cancer Res Treat. 2001; 68:29-1
4. Sarah A. McLaughlin, David D. Thiel, Stephen L. Smith, Michael J. Wehle and David M. Menke Et al. Solitary breast mass as initial presentation of clinically silent metastatic renal cell carcinoma The Breast. 2006; 3:426-8
5. Gettman MT, Blute ML, Spotts B, Bryant SC, Zincke H et al. Pathologic staging of renal cell carcinoma: significance of tumor classification with the 1997 TNM staging system. Cancer 2001; 91:354-1
6. Bartella L, Kaye J, Perry N M, Malhotra A, Evans D, Ryan D, Wells C, Vinnicombe S J Et al. Metastases to the breast revisited: radiological histopathological correlation. Clin Radiol 2003; 58:524-1.
7. Chaignaud B, Hall TJ, Powers C, Subramony C, Scott-Conner CE: Diagnosis and natural history of extramammary tumors metastatic to the breast. J Am Coll Surg. 1994; 179:49-3.
8. Mike F, Steve D Et al. Notes on the potential for metastasectomy in RCC. Br J Urology. April 2002
9. Friedel G, Hurtgen M, Penzenstadler M et al. Resection of pulmonary metastases from renal cell carcinoma. Anticancer Research. 1999;19(2C):1593-6.
10. D.C Chhieng, J.M Cohen and J. Waisman Et al. Fine Needle Aspiration Cytology of renal cell adenocarcinoma metastatic to the breast: A report of three cases. Diagn Cytopathol. 1999; 21:324-7
11. Fyfe G, Fisher RI, Rosenberg SA, et al. Results of treatment of 255 patients with metastatic renal cell carcinoma who received high-dose recombinant interleukin-2 therapy. Journal of Clinical Oncology. 1995; 13(3):688-6.