



Case Report

Intradural extramedullary tuberculoma of the thoracic spine – A rare case report of paraparesis

Boris Kangabam¹, Thokchom Amataleima¹, Mayanglambam Amitkumar², Takhelmayum Umesh³

Departments of ¹Surgery, ²Neurosurgery, ³Orthopaedics, Jawaharlal Nehru Institute of Medical Sciences, Imphal, Manipur, India.

E-mail: *Boris Kangabam - boriskangabamcha@gmail.com; Thokchom Amataleima - amataleima.th@gmail.com;

Mayanglambam Amitkumar - gmamitkumar@gmail.com; Takhelmayum Umesh - umeshTakhelmayum2014@gmail.com



***Corresponding author:**

Boris Kangabam,
Department of Surgery,
Jawaharlal Nehru Institute
of Medical Sciences, Imphal,
Manipur, India.

boriskangabamcha@gmail.com

Received : 25 February 2021

Accepted : 06 March 2021

Published : 08 April 2021

DOI

10.25259/SNI_197_2021

Quick Response Code:



ABSTRACT

Background: Intradural extramedullary tuberculoma of the spinal cord (IETSC) is an extremely rare form of spinal tuberculosis (TB) that is believed to be due to a host's immune reaction against the *Mycobacterium* protein derivatives.

Case Description: A 25-year-old male with human immunodeficiency virus, hepatitis C virus, and disseminated TB on antitubercular therapy for the past 8 months, presented with paraplegia of 2 months duration. When the MRI spine revealed multiple peripheral rim enhancing intradural extramedullary lesions from T6 to T8 and dorsally from T10 to T11, the patient was diagnosed with IETSC. At surgery, we countered cystic lesions adherent to the dura and the spinal cord, containing a whitish material. Postoperatively, the patient showed clinical improvement in motor power and sensation.

Conclusion: Intradural extramedullary spinal tuberculomas in patients with a history of TB and spinal cord compression, although rare, should be considered among the differential diagnoses.

Keywords: Intradural extramedullary, Spine, Tuberculosis

INTRODUCTION

Intradural spinal tuberculomas are extremely rare (i.e., 5% of cases) and intradural extramedullary tuberculoma of the spinal cord (IETSC) is even less frequently encountered.^[2] Here, we describe a 25-year-old male who presented with paraplegia due to thoracic intradural extramedullary tuberculoma of the spine despite 8 months of anti-tubercular therapy. Fortunately, surgical decompression resulted in gradual partial return of neurological function.

CASE REPORT

A 25-year-old male with known case of disseminated tuberculosis (TB), hepatitis C, and human immunodeficiency virus (HIV) presented with a progressive paraparesis and loss of sphincter control (T8 level) of 2 months duration. He had already been on antitubercular therapy for the prior 8 months and had been taking antiretroviral therapy medication for HIV since 2018, although on an irregular basis.

This is an open-access article distributed under the terms of the Creative Commons Attribution-Non Commercial-Share Alike 4.0 License, which allows others to remix, tweak, and build upon the work non-commercially, as long as the author is credited and the new creations are licensed under the identical terms.

©2021 Published by Scientific Scholar on behalf of Surgical Neurology International

MR study

The thoracic MRI revealed multiple peripheral rim enhancing contiguous intradural extramedullary lesions along the right side of the dura from T6 to T8 thoracic, and dorsally from T10 to T11. This was accompanied by diffuse pachymeningeal enhancement resulting in moderate/severe cord compression at T7-T8 and diffuse cord edema from T5-T11. Lesions were hyperintense on T2-weighted images and hypointense on T1-weighted images [Figures 1 and 2].

Lumbar cerebrospinal fluid (CSF) findings

The lumbar CSF puncture revealed colorless fluid with a protein of 58 mg%, glucose of 43 mg%, and cell count of 80 per cumm (all lymphocytes). The CSF Ziehl-Neelsen stain

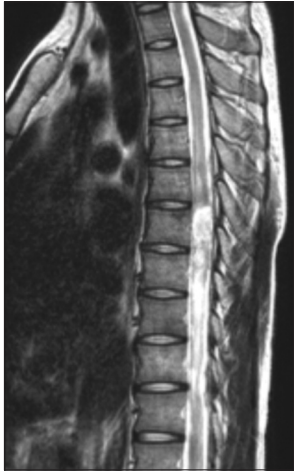

Figure 1: T2-weighted MRI sagittal spine image showing hyperintense intradural extramedullary lesion compressing spinal cord at T6-T8 and T10-T11 vertebrae levels.

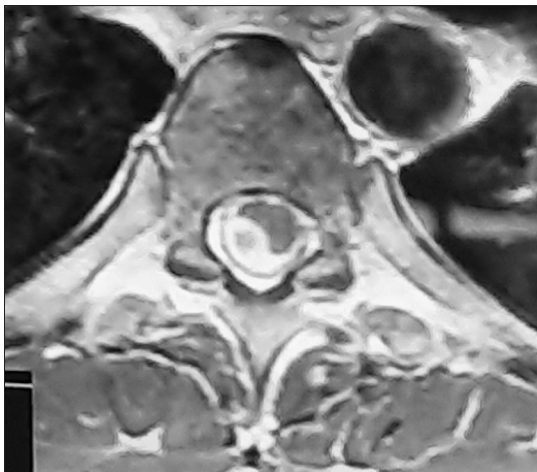


Figure 2: T2-weighted cross-sectional MRI spine showing hyperintense intradural extramedullary lesion compression at T6 vertebral level from the right side.

and cartridge-based nucleic acid amplification test yielded negative results.

Surgery, cultures, and pathology

The patient underwent a laminectomy from T5 to T8. At surgery, a cystic lesion measuring 3 cm×1.5 cm×1 cm was found adherent to the dura and spinal cord; the capsule contained 3 cc of a whitish material that was positive for acid-fast bacilli Ziehl-Neelsen staining [Figure 3]. *Mycobacterium tuberculosis* was detected on Xpert MTB/RIF assay with no resistance to rifamycin found. Histopathology examination of cystic tissue removed revealed a suppurative granulomatous lesion also consistent with TB [Figure 4].

Postoperative course

Postoperatively, there was gradual but only slight clinical improvement. Two weeks following surgery, motor power

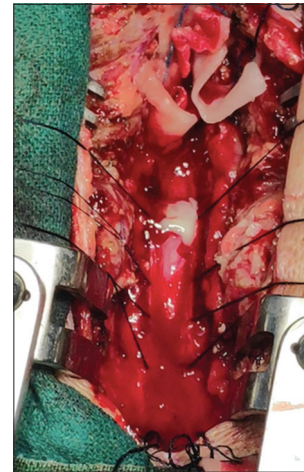


Figure 3: Intraoperative picture showing whitish material after marking and opening the dura. The discharge came positive for tubercle bacilli.

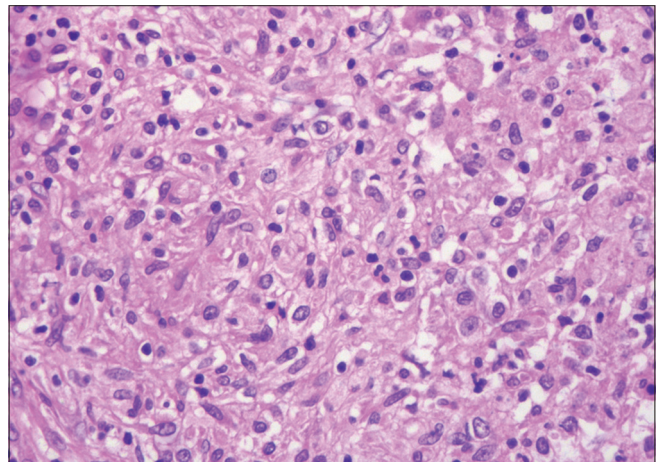


Figure 4: Histopathology slide picture of intradural extramedullary tissue removed during surgery.

was 3/5 in both lower extremities, while the prior sensory and sphincteric deficits fully resolved.

DISCUSSION

TB can present 10% of the time in the central nervous system.^[2] There are four typical presentations of spinal TB: Pott's spine, nonosseous spinal tuberculoma, tubercular arachnoiditis, and spinal meningitis. Dastur^[1] in 1983 reviewed 74 cases of spinal tuberculomas and found that 65% of tuberculomas were extradural, 8% intramedullary, 5% intradural extramedullary, and 20% arachnoidal.

IETSC is the rarest type of spinal TB seen only in 1 out of 50,000 cases, and is usually found in young individuals presenting with three variants; in healthy individuals with no primary TB history, in those with disseminated TB, and in those with recent TB history previously treated with antitubercular therapy successfully.^[3-5]

Although medical therapy is the mainstay of treatment, prompt surgical intervention may be warranted for those with significant neurological deficits attributed to cord compression.^[4]

CONCLUSION

Although IETSC is an extremely rare form of spinal TB, it must be considered among the differential diagnoses for those presenting with a known history of TB and spinal cord compression. Where patients present with significant deficits secondary to cord compression, prompt surgical intervention/decompression may be warranted.

Declaration of patient consent

The authors certify that they have obtained all appropriate patient consent.

Financial support and sponsorship

Nil.

Conflicts of interest

There are no conflicts of interest.

REFERENCES

1. Dastur HM. Diagnosis and neurosurgical treatment of tuberculous disease of the CNS. *Neurosurg Rev* 1983;6:111-7.
2. Jeong DK, Kwon YM. Intradural extramedullary tuberculoma of the spinal cord following tuberculous meningitis. *Korean J Spine* 2015;12:107-10.
3. Kaur H, Mittal GK, Singhdev J. Intradural extramedullary tuberculoma of the spinal cord in patient of tubercular meningitis-an uncommon scenario. *Indian J Tuberc* 2020;67:426-9.
4. Takahashi H, Ito S, Kojima S, Tanno T, Hattori T. Intradural extramedullary tuberculoma of the thoracic spine: Paradoxical response to antituberculous therapy. *Intern Med* 2008;47:797-8.
5. Verma K, Crothers T, Neuman B, Vaccaro A, Heller J. A case of intradural extramedullary spinal tuberculosis diagnosed 8 years after treatment of the primary infection. *JHN J* 2013;8:14-7.

How to cite this article: Kangabam B, Amataleima T, Amitkumar M, Umesh T. Intradural extramedullary tuberculoma of the thoracic spine – A rare case report of paraparesis. *Surg Neurol Int* 2021;12:136.