

Priapism after spinal cord injury – a case report and review of the literature

Jeff John , Noma Mngqi and Ken Kesner

Ther Adv Urol

2021, Vol. 13: 1–4

DOI: 10.1177/
17562872211039107

© The Author(s), 2021.
Article reuse guidelines:
sagepub.com/journals-
permissions

Abstract: Involuntary unwanted erections are extremely rare after spinal cord injury (SCI). A sudden loss of sympathetic tone to the pelvic vasculature following SCI causes an increase in the parasympathetic tone and uncontrolled arterial blood flow into the penile sinusoidal spaces. When occurring immediately after an acute SCI, it is generally self-limiting and settles within a few hours. In contrast, recurrent, unwanted erections in patients with chronic SCI are more unpredictable in frequency and duration and may require treatment. We present a case of recurrent involuntary unwanted erections in a patient with chronic SCI after a stab wound to his neck and review the pathophysiology and available management options.

Keywords: Priapism, spinal cord injury

Received: 24 February 2021; revised manuscript accepted: 27 July 2021.

Introduction

Involuntary unwanted erections are extremely rare after spinal cord injury (SCI), and the exact incidence is unknown.¹ The oldest known case dates back to the 17th century BC: The *Edwin Smith Surgical Papyrus*, thought to be the oldest discovered medical papyrus, describes a patient with a cervical spine fracture complicated by quadriplegia priapism, seminal emission, and urinary incontinence.² The Ancient Egyptian physician concerned with the case noted that the prognosis was guarded and dolefully declared that his patient had “an ailment not to be treated.”³ We present a case of recurrent involuntary unwanted erections in a patient with chronic SCI after a stab wound to his neck and review the pathophysiology and available management options.

Case presentation

A 34-year-old male patient was brought to our emergency department by his neighbor after sustaining a single stab wound to the neck and finding himself unable to walk. Physical examination found him fully conscious, hemodynamically stable and without any neck restraint. A single right-sided stab wound was noted in the lower anterior triangle of the neck (Figure 1), and air entry was

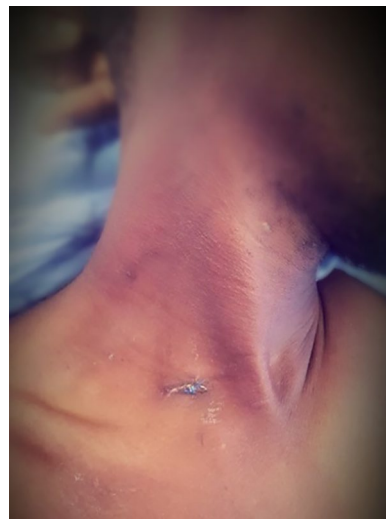

Figure 1. Clinical photograph depicting a single stab wound in zone 1 of the right anterior triangle.

reduced over the right hemithorax. He could not move his lower limbs or feel sensation below the waist, and his cervical spine was immobilized forthwith. A chest x-ray revealed a right-sided pneumothorax, and an intercostal drain was inserted. A multidetector helical computed tomography (CT) with angiography and contrast swallow ruled out vascular, laryngotracheal, and

Correspondence to:
Jeff John
Division of Urology,
Department of Surgery,
Frere Hospital and Walter
Sisulu University, East
London, 5200, South Africa
jeffveenajohn@gmail.com

Noma Mngqi
Ken Kesner
Division of Urology,
Department of Surgery,
Frere Hospital and Walter
Sisulu University, East
London, South Africa

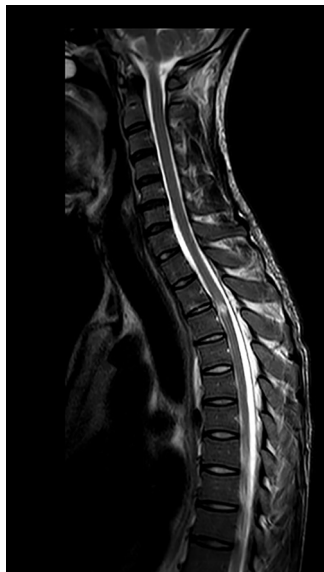

Figure 2. T2-weighted MRI a central intramedullary high signal lesion of the spinal cord at the level of T2–T3. MRI, magnetic resonance imaging.

pharyngo-oesophageal injuries. T2-weighted magnetic resonance imaging (MRI) of the spine revealed a central intramedullary high signal lesion of the spinal cord at the T2–T3 level as the cause of his acute paraplegia (Figure 2).

Our urology department was consulted 5 h after admission with a complaint of persistent erection of 4-h duration. He denied the use of antipsychotics, recreational drugs, or any oral medication or self-injection for erectile dysfunction. He gave no history of hematological diseases such as sickle cell anemia or leukemia. Further, examination revealed no evidence of trauma to the pelvis, perineal, or genital area. A full blood count, liver, renal and thyroid function tests and serum electrolytes were normal. No sickle cells were detected on the peripheral smear. A tox screen was negative. Penile corporal blood gas analysis demonstrated a high-flow, non-ischemic priapism with pH 7.42, pCO₂ 35.2 mmHg, and pO₂ 93.5 mmHg. Repeat penile corporal blood gas analysis reaffirmed the priapism to be non-ischemic in nature, and it was decided to manage the patient conservatively. The priapism resolved spontaneously 7 h after onset. The patient reported two further episodes of unwanted erections, each lasting 30 min over the next 24 h. He was transferred to a rehabilitation unit. He showed no demonstrable improvement in motor and sensory function at

follow-up 5 months later and no recurrence in priapism episodes.

Discussion

High-flow priapism is a persistent erection caused by unregulated cavernous arterial inflow. Although more commonly caused by blunt perineal or penile trauma, it is a rare complication of SCI. The proportion of male patients with priapism post-SCI is unclear because of the scarcity of reported cases in the literature.⁴ A sudden loss of sympathetic tone to the pelvic vasculature following SCI causes an increase in the parasympathetic tone and uncontrolled arterial blood flow into the penile sinusoidal spaces.⁵ Lesions and injuries of the cervical spinal cord are most frequently associated with priapism. However, since the sympathetic outflow to the penis arises from the most caudal aspect of the spinal cord, the conus, a lesion at any level of the spinal cord, can be associated with priapism.^{6,7}

Although SCI patients with priapism have been found to present with high-flow, non-ischemic priapism, this diagnosis should not be assumed ab initio. Causes of low-flow priapism should first be excluded routinely since delayed intervention for low-flow ischemic priapism may result in permanent corporal fibrosis, cellular damage, and permanent impotence. Therefore, the history should inquire for risk factors such as pharmacotherapy for erectile dysfunction (both oral and intracavernous), medications such as antipsychotics, illicit drug use, and a history of hematological diseases such as sickle cell anemia or leukemia. Penile blood gas analysis is critical to confirm the diagnosis of high-flow, non-ischemic priapism. A penile ultrasound may be helpful to further reaffirm the diagnosis of non-ischemic priapism by demonstrating normal bilateral penile artery Doppler velocities. Seeing that our patient had sequential penile blood gas analyses that were suggestive of non-ischemic priapism, we did not perform a penile Doppler ultrasound.

Priapism usually occurs immediately after an acute SCI, and, in this setting, the priapism is generally self-limiting and settles within a few hours (up to 30 h) after the injury – as was the case in our patient.^{6,7} In contrast, the clinical course of recurrent or refractory priapism in patients with chronic SCI is far more variable. Koyuncu *et al.* and Vaidyanathan *et al.* both

described patients with tetraplegia after a diving accident and another after a mountain bike accident.^{1,8} In both cases, the patients first experienced involuntary, unwanted erections many weeks after their acute SCI. The recurrent erections reduced significantly in both duration and frequency on oral baclofen, a γ -aminobutyric acid derivative, which is known to inhibit both erection and ejaculation by relaxing the ischiocavernosus and bulbospongiosus muscles.^{9–11} Oral baclofen may prove ineffective in many patients. Because the spinal cord represents only about 2% of the brain's mass and therefore receives a proportionately lower fraction of cardiac output,¹² cerebral side effects often occur before the therapeutic anti-spastic effects of oral baclofen are observed. Intrathecal baclofen (ITB) therapy injected directly into the subarachnoid space has proven beneficial in patients with chronic priapism after SCI. A pump is implanted surgically in the subcutaneous tissue of the anterior abdominal wall, and baclofen is delivered *via* a silicone rubber catheter into the lumbar subarachnoid space. The ITB pump delivers approximately 100–900 $\mu\text{g}/\text{day}$ of baclofen and is titrated for the desired clinical response.¹² When baclofen is introduced directly into the intrathecal space, sufficient CSF concentrations can be achieved with plasma concentrations 100 times less than those occurring with oral administration. D'Aleo *et al.* reported the case of a 41-year-old male with C3 tetraplegia after a motor vehicle accident who had priapismic episodes commencing a month after his injury.¹⁰ Oral baclofen (75 mg/day) had minimal benefit. After a successful test dose of ITB proved effective in controlling the priapism episodes, further ITB therapy was administered *via* an implanted pump system. Denys *et al.* studied nine men with SCI or multiple sclerosis and chronic priapismic episodes who received ITB *via* an implantable pump.¹³ After an average of 44.4 months follow-up, eight of the nine patients reported decreased erection rigidity and duration after ITB therapy. Prolonged ITB infusion causes a down-regulation of GABA_B receptors in the CNS and spinal cord. The baclofen itself causes increased inhibitory tone in the CNS and spinal cord.¹⁴ Abrupt ITB withdrawal results in the cessation of this inhibitory tone in the CNS and results in the predominance of excitatory effects with the reappearance of a baseline level of spasticity associated with mild symptoms such as pruritis, anxiety, and disorientation.¹² More severe consequences of ITB withdrawal syndrome are hyperthermia, exaggerated rebound spasticity

and muscle rigidity, seizures, rhabdomyolysis, multisystem organ failure, cardiac arrest, and coma.^{15–17} Prompt initiation of high-dose benzodiazepines, reinstatement of baclofen, and proper supportive intensive care management are the essential pillars for managing ITB withdrawal syndrome.¹²

Other suggested options for treating stuttering priapism include hormonal manipulation with gonadotropin-releasing hormone (GnRH) agonists or antagonists, anti-androgens, diethylstilbestrol, and ketoconazole, but their efficacy is unclear.¹ Pseudoephedrine, digoxin, and terbutaline have been used to reverse erections by increasing corpus cavernosal smooth muscle tone. Low-dose phosphodiesterase type 5 (PDE-5) inhibitors, gabapentin, hydralazine, and hydroxyurea are other alternatives.¹⁸ These drugs may be used in carefully selected patients where oral and ITB have failed. Digoxin or terbutaline may have detrimental cardiac side effects. Diethylstilbestrol increases the risk of deep-vein thrombosis in immobilized patients with severe SCI, and hormonal agents are contraindicated in children and in men who wish to remain fertile.¹⁸ The high incidence of androgen deficiency and hypogonadism in SCI patients also precludes anti-androgenic measures in these patients.^{19,20}

Conclusion

Priapism after SCI may be associated with injury to any part of the spinal cord and is extremely rare. When occurring immediately after an acute SCI, it is generally self-limiting and settles within a few hours. In contrast, recurrent, unwanted erections in patients with chronic SCI are more unpredictable in frequency and duration and may require treatment, with ITB being highly effective. Therefore, patients should first respond to a screening dose of ITB before considering long-term infusion *via* an implantable pump.

Author contributions

JJ reviewed the literature and drafted the manuscript with input and images from NM. KK reviewed and edited the manuscript. All authors issued final approval for the version to be submitted for publication.

Conflict of interest statement

The authors declare that there is no conflict of interest.


Funding

The authors received no financial support for the research, authorship, and/or publication of this article.

Informed consent

Written informed consent was obtained from the patient for the anonymised information and the accompanying images to be published in this article.

ORCID iD

Jeff John  <https://orcid.org/0000-0002-6139-810X>

References

1. Koyuncu E, Taşoğlu Ö, Orhan A, *et al.* Recurrent priapism in spinal cord injury: a case report. *J Spinal Cord Med* 2019; 44: 331–333.
2. Turliuc MD, Turliuc S, Cucu AI, *et al.* Through clinical observation: the history of priapism after spinal cord injuries. *World Neurosurg* 2018; 109: 365–371.
3. Maiti TK, Konar S, Bir SC, *et al.* Historical vignette of infamous gunshot injury to spine: “an ailment not to be treated”? *World Neurosurg* 2015; 84: 1441–1446.
4. Chang C, Lu C, Yang Y, *et al.* Man with trauma after a fall. *J Am Coll Emerg Physicians Open* 2020; 1: 296–297.
5. Keoghane SR, Sullivan ME and Miller MAW. The aetiology, pathogenesis and management of priapism. *BJU Int* 2002; 90: 149–154.
6. Gordon SA, Stage KH, Tansey KE, *et al.* Conservative management of priapism in acute spinal cord injury. *Urology* 2005; 65: 1195–1197.
7. Todd NV. Priapism in acute spinal cord injury. *Spinal Cord* 2011; 49: 1033–1035.
8. Vaidyanathan S, Watt J, Singh G, *et al.* Management of recurrent priapism in a cervical spinal cord injury patient with oral baclofen therapy. *Spinal Cord* 2004; 42: 134–135.
9. Kousournas G, Muneer A, Ralph D, *et al.* Contemporary best practice in the evaluation and management of stuttering priapism. *Ther Adv Urol* 2017; 9: 227–238.
10. D’Aleo G, Rifici C, Kofler M, *et al.* Favorable response to intrathecal, but not oral, baclofen of priapism in a patient with spinal cord injury. *Spine (Phila Pa 1976)* 2009; 34: E127–E129.
11. Levey HR, Segal RL and Bivalacqua TJ. Management of priapism: an update for clinicians. *Ther Adv Urol* 2014; 6: 230–244.
12. Mohammed I and Hussain A. Intrathecal baclofen withdrawal syndrome - a life-threatening complication of baclofen pump: a case report. *BMC Clin Pharmacol* 2005; 4: 1–5.
13. Denys P, Mane M, Azouvi P, *et al.* Side effects of chronic intrathecal baclofen on erection and ejaculation in patients with spinal cord lesions. *Arch Phys Med Rehabil* 1998; 79: 494–496.
14. Kroin JS, Bianchi GD and Penn RD. Intrathecal baclofen down-regulates GABA_B receptors in the rat substantia gelatinosa. *J Neurosurg* 1993; 79: 544–549.
15. Green LB and Nelson VS. Death after acute withdrawal of intrathecal baclofen: case report and literature review. *Arch Phys Med Rehabil* 1999; 80: 1600–1604.
16. Reeves RK, Stolp-Smith KA and Christopherson MW. Hyperthermia, rhabdomyolysis, and disseminated intravascular coagulation associated with baclofen pump catheter failure. *Arch Phys Med Rehabil* 1998; 79: 353–356.
17. Sampathkumar P, Scanlon PD and Plevak DJ. Baclofen withdrawal presenting as multiorgan system failure. *Anesth Analg* 1998; 87: 562–563.
18. Kheirandish P, Chingewundoh F and Kulkarni S. Treating stuttering priapism. *BJU Int* 2011; 108: 1068–1072.
19. Sullivan SD, Nash MS, Tefera E, *et al.* Prevalence and etiology of hypogonadism in young men with chronic spinal cord injury: a cross-sectional analysis from two university-based rehabilitation centers. *PM R* 2017; 9: 751–760.
20. Bauman WA, La Fontaine MF and Spungen AM. Age-related prevalence of low testosterone in men with spinal cord injury. *J Spinal Cord Med* 2014; 37: 32–39.