

Available online at www.sciencedirect.com

ScienceDirect

journal homepage: www.elsevier.com/locate/radcr

Case Report

Osteoid osteoma of the second metatarsal bone diagnosed on MRI: A case report and literature review ☆☆☆★

Mohammad Hossein Daghighi, MD^a, Masoud Mahmoudpour, MD^a, Ali Akhavi Milani, MD^{b,*}

^a Radiology Department, Imam Reza Hospital, Tabriz University of Medical Sciences, Tabriz, Iran

^b Student Research Committee, Tabriz University of Medical Sciences, Tabriz, Iran

ARTICLE INFO

Article history:

Received 16 October 2021

Revised 10 November 2021

Accepted 10 November 2021

Keywords:

Osteoid osteoma

Metatarsal bone

Magnetic resonance imaging

Plain radiography

ABSTRACT

Osteoid osteoma is a relatively common benign bone tumor that is most frequently seen on the appendicular skeleton in adolescents and young adults. Here we present the case of a 14-year-old boy presenting with a 10 month history of pain in his left foot which had been misdiagnosed as stress fracture due to its unusual clinical presentation. Magnetic resonance imaging of the left foot revealed a bone lesion with typical features of the osteoid osteoma on the distal part of the second metatarsal bone. The lesion was surgically removed and the diagnosis of osteoid osteoma was confirmed by post-surgical histopathologic examination of the resected section. The patient reported a substantial relief in his pain 4 weeks following the surgical operation.

© 2021 The Authors. Published by Elsevier Inc. on behalf of University of Washington.

This is an open access article under the CC BY-NC-ND license

(<http://creativecommons.org/licenses/by-nc-nd/4.0/>)

Introduction

Osteoid osteoma is a relatively common benign bone tumor accounting for approximately 2%-3% of all primary bone tumors and 10%-12% of benign bone tumors [1]. It most frequently affects adolescents and young adults (ages of 5 to 24 years) with a predilection for the male gender [1,2]. Osteoid osteoma can present anywhere in the skeleton; however, it is

most frequently seen on appendicular bones (about half of the cases involve either femur or tibia) [1,3,4]. Jordan et al. in a systematic review of 94 studies including 223 cases of foot and ankle osteoid osteomas have concluded that talus, calcaneus, phalanges, metatarsals, cuneiform, and cuboid, respectively, are the most commonly involved bones of the foot and ankle [4]. It is also reported that metatarsal osteoid osteomas comprise approximately 1.7% of the osteoid osteoma cases [4,5].

☆ Acknowledgments: Authors did not receive any funding for this research.

☆☆ Competing Interests: Authors declare that there was no conflict of interest.

★ Availability of data and material: All the raw data are available upon request from the corresponding author.

* Corresponding author.

E-mail address: ali.akhavi.milani@gmail.com (A. Akhavi Milani).

<https://doi.org/10.1016/j.radcr.2021.11.014>

1930-0433/© 2021 The Authors. Published by Elsevier Inc. on behalf of University of Washington. This is an open access article under the CC BY-NC-ND license (<http://creativecommons.org/licenses/by-nc-nd/4.0/>)

Osteoid osteomas are usually of a diameter of less than 2 cms [6]. They consist of a characteristic radiolucent central nidus which is the actual neoplastic tissue. This central nidus is covered by a layer of reactive sclerosis and adjacent periosteal reaction. Histologically, the central nidus of the osteoid osteoma is composed of woven bone trabeculae. These trabeculae are covered by a single layer of osteoblasts and the spaces in-between these trabeculae are filled with loose connective tissue containing many dilated capillaries and variable degrees of calcification [6,7].

Osteoid osteoma is histologically identical to osteoblastoma except for reactive sclerosis surrounding the nidus which is usually absent in osteoblastoma [6]. Osteoid osteoma and osteoblastoma are mainly differentiated based on their clinical features, size, and location.

Patients with osteoid osteoma usually present with pain. The pain caused by osteoid osteoma is typically localized, worsens at night (may also awaken the patient), and recedes with NSAIDs within 20-25 minutes [2]. Diagnosis is straightforward if the clinical presentation and the imaging findings are typical, but may be difficult otherwise. Herein, we report a case of osteoid osteoma of the second metatarsal bone which had been misdiagnosed for several months due to its atypical clinical presentation.

Case presentation

A 14-year-old Caucasian boy presented to the Orthopaedics outpatient clinic complaining of pain in his left foot and difficulty walking which had been started 10 months ago. The patient reported that the pain had been started since he had started to play football 10 months ago. He localized the pain to the dorsomedial aspect of the forefoot. The pain was of mild to moderate intensity, was intermittent, and was usually evoked by activity. He reported that his pain had been unresponsive to all the topical medications he had received during the past 10 months and subsided to some degree only when he used ibuprofen tablets. He did not report any other symptoms (eg, fever, malaise). His past medical history, past surgical history, and family history were unremarkable. On physical examination, while inspecting the foot in sitting and standing positions no deformity, swelling, erythema, ecchymosis, rashes, warts, blisters, or ulcers were identified and the foot arch was normal. When the patient was asked to walk in the room, limping was evident. In palpation of the foot, the site of maximal tenderness was identified to be the dorsal aspect of the 1st to 3rd metatarsal bones. Dorsalis pedis and posterior tibialis pulses and neurologic examinations of the foot were normal. The range of motion was normal on active and passive dorsiflexion and plantarflexion of the foot but the patient refused to perform eversion and inversion motions due to pain in his foot. A plain radiograph of the left foot was requested which was remarkable for a mild cortical thickening of the second metatarsal bone (Fig. 1). As the next step in the diagnostic workup, an MRI of the left foot was requested. As shown in Figure 2, MRI was remarkable for an intracortical oval-shaped lesion consisting of a central nidus and cortical thickening on the distal part of the second metatarsal bone. Edema was also evident in the adjacent bone marrow and nearby soft tissues. Based on the typical appearance of the

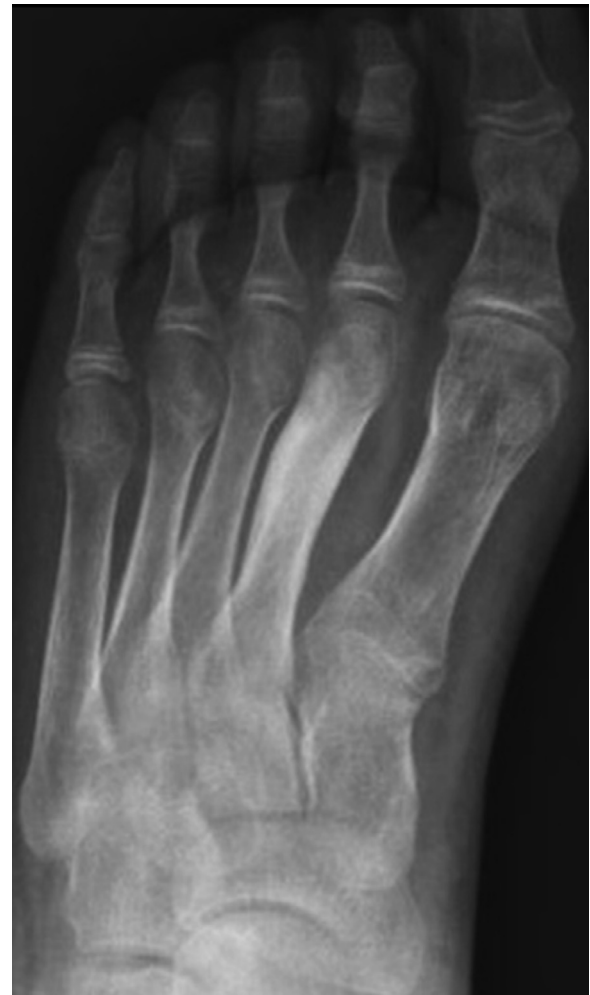

Fig. 1 – Plain radiograph of the left foot of a 14-year-old boy showing cortical thickening of the second metatarsal bone. The patient was finally diagnosed with osteoid osteoma of the distal part of the second metatarsal bone

lesion, osteoid osteoma was proposed as the most likely diagnosis. The bone lesion was surgically removed and sent for pathologic examination which confirmed the diagnosis of osteoid osteoma. Four weeks after the surgery the patient came for another visit and reported substantial relief of his pain.

Discussion

The typical picture of osteoid osteoma is an adolescent male patient complaining of pain in his lower limb which has been started several weeks to months ago, has not been induced by trauma, worsens at night, and recedes with NSAIDs and is not related to activity [2]. The presentation of our patient was unusual in several aspects. First, the patient reported that his pain had been started from the time he had started to play football 10 months ago and that his pain would worsen by activity. This was why the previous clinicians who had visited the patient in the acute phase of the disease had attributed the pain to overuse or mild traumatic injuries suffered during football play. Pain caused by osteoid osteoma is usually con-

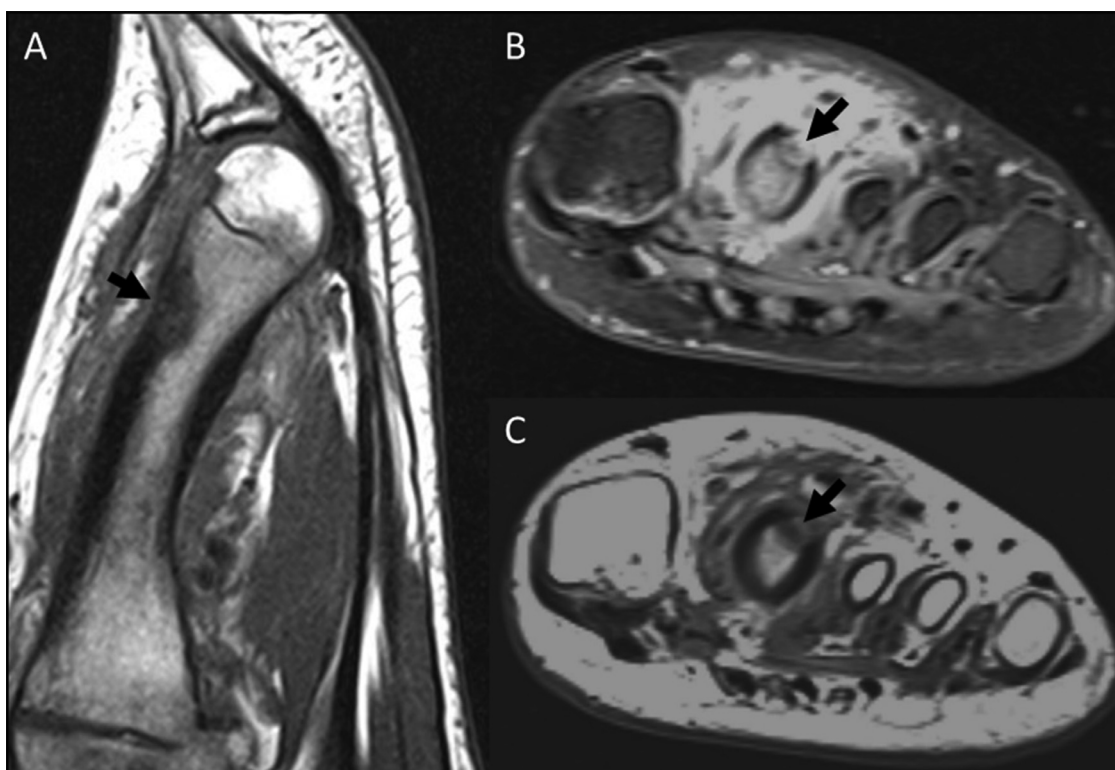


Fig. 2 – MRI of the left foot of a 14-year-old boy, sagittal T1-weighted (A), transverse proton density (B), and transverse T1-weighted (C) images demonstrating an intracortical oval-shaped lesion consisting of a central nidus and cortical thickening on the distal part of the second metatarsal bone (arrows). Edema is also evident in the adjacent bone marrow and nearby soft tissues

sidered to be alleviated by increased activity and worsened at night. It was interesting that there were also some other reports of apparent post-traumatic foot pains finally diagnosed to be caused by osteoid osteoma in literature [8]. Second, the osteoid osteoma in our patient was diagnosed on the second metatarsal bone which is not a common location for osteoid osteoma [2].

Based on radiographic findings, osteoid osteomas are traditionally classified as “medullary, cortical, or subperiosteal” [9]. However, a more precise classification system has been also described based on computed tomography (CT) or magnetic resonance imaging (MRI) findings, which classifies osteoid osteomas as “subperiosteal, intracortical, endosteal, or intramedullary” [7,10]. Cortical osteoid osteomas are generally considered the most common type.

The sensitivity of plain radiography for the detection of osteoid osteoma depends on the tumor’s location in the bone. Cortical osteoid osteomas are most likely to be detected on plain radiography as they present a radiolucent nidus which is usually surrounded by a layer of reactive sclerosis and periosteal reaction. Medullary osteoid osteomas are more difficult to be detected on plain radiography [1,2]. In our patient osteoid osteoma was best classified as intracortical; however, only the cortical thickening was notable on plain radiograph of the foot and the central nidus of the osteoid osteoma was not apparent.

CT is generally considered as the modality of choice for the diagnosis of osteoid osteoma [1,2]. Assoun et al. (1994) have

compared the diagnostic performance of CT and MRI on 19 patients with histologically confirmed osteoid osteomas and have concluded that CT has a better diagnostic performance in the detection of the nidus of the osteoid osteoma [11]. However, Liu et al. (2003) have compared the diagnostic performance of the dynamic gadolinium-enhanced T1-weighted images with nonenhanced T1- and T2-weighted images and thin-section CT images for detection of osteoid osteomas [12]. They have finally concluded that the diagnostic performance of dynamic gadolinium-enhanced MR images is better than nonenhanced MR images and equal to or better than thin-section CT images. The nidus of the osteoid osteoma is usually low signal on T1 weighted images and often enhances diffusely following gadolinium injection; however, its signal intensity on T2 weighted images can be variable, depending on the degree of mineralization inside the nidus. Edema in the adjacent bone marrow and soft tissues may also be evident [1,7,13]. Although the MRI findings were typical for osteoid osteoma in our patient, CT of the left foot was also obtained which confirmed the diagnosis of osteoid osteoma.

Patient Consent

Informed written consent was obtained from the patient to publish the case, MRI, and radiography images after de-identification of the personal information.

REFERENCES

- [1] Iyer RS, Chapman T, Chew FS. Pediatric bone imaging: diagnostic imaging of osteoid osteoma. *AJR Am J Roentgenol* 2012;198(5):1039–52.
- [2] Greenspan A. Benign bone-forming lesions: osteoma, osteoid osteoma, and osteoblastoma. Clinical, imaging, pathologic, and differential considerations. *Skeletal Radiol* 1993;22(7):485–500.
- [3] Noordin S, Allana S, Hilal K, Nadeem N, Lakdawala R, Sadruddin A, et al. Osteoid osteoma: Contemporary management. *Orthop Rev (Pavia)* 2018;10(3):7496.
- [4] Jordan RW, Koç T, Chapman AW, Taylor HP. Osteoid osteoma of the foot and ankle—A systematic review. *Foot and ankle surgery: official journal of the European Society of Foot and Ankle Surgeons* 2015;21(4):228–34.
- [5] Jackson RP, Reckling FW, Mants FA. Osteoid osteoma and osteoblastoma. Similar histologic lesions with different natural histories. *Clinical orthopaedics and related research* 1977(128):303–13.
- [6] Kumar Vinay, Abbas Abul K, Fausto N, Aster Jon C, A Perkins James. *Bones, Joints, and Soft Tissue Tumors. Robbins and Cotran pathologic basis of disease.* Philadelphia, PA: Saunders Elsevier; 2015.
- [7] Chai JW, Hong SH, Choi JY, Koh YH, Lee JW, Choi JA, et al. Radiologic diagnosis of osteoid osteoma: from simple to challenging findings. *Radiographics* 2010;30(3):737–49.
- [8] Ambrosia JM, Kernek CB. Osteoid osteoma of the foot: presentation following trauma. *Orthopedics* 1985;8(5):684–5.
- [9] Kransdorf MJ, Stull MA, Gilkey FW, Moser RP, osteoma Osteoid. *Radiographics* 1991;11(4):671–96.
- [10] Kayser F, Resnick D, Haghghi P, Pereira Edo R, Greenway G, Schweitzer M, et al. Evidence of the subperiosteal origin of osteoid osteomas in tubular bones: analysis by CT and MR imaging. *AJR Am J Roentgenol* 1998;170(3):609–14.
- [11] Assoun J, Richardi G, Railhac JJ, Baunin C, Fajadet P, Giron J, et al. Osteoid osteoma: MR imaging versus CT. *Radiology* 1994;191(1):217–23.
- [12] Liu PT, Chivers FS, Roberts CC, Schultz CJ, Beauchamp CP. Imaging of osteoid osteoma with dynamic gadolinium-enhanced MR imaging. *Radiology* 2003;227(3):691–700.
- [13] Spouge AR, Thain LM. Osteoid osteoma: MR imaging revisited. *Clin Imaging* 2000;24(1):19–27.