

Investigation of grape sap on wingless/integrated and β -catenin genes expression with histological factors on the hair follicle in rat

Mohammad Kazemi¹, Mohammad-Mohsen Taghavi¹, Ahmad Shabanizadeh¹, Zahra Taghipour¹, Ayat Kaeidi^{2,3}, and Mahdi Shariati-Kohbanani^{1,*}

¹Department of Anatomical Sciences, School of Medicine, Rafsanjan University of Medical Sciences, Rafsanjan, I.R. Iran.

²Physiology-Pharmacology Research Center, Research Institute of Basic Medical Sciences, Rafsanjan University of Medical Sciences, Rafsanjan, I.R. Iran.

³Department of Physiology and Pharmacology, School of Medicine, Rafsanjan University of Medical Sciences, Rafsanjan, I.R. Iran

Abstract

Background and purpose: Natural products are used to improve the damage caused by harmful reagents in various pathological situations. This study investigated the effect of grape sap as a natural product with antioxidant properties on follicle cell proliferation in bleomycin (as a chemotherapy agent with toxic effects on hair growth) treated rats skin.

Experimental approach: The bleomycin treated rats were administrated grape sap. Wingless/integrated (wnt) and β -catenin gene expression as follicle proliferative markers were evaluated using real-time polymerase chain reaction. Furthermore, histological factors and total antioxidant capacity were evaluated.

Findings / Results: The data showed that, grape sap increased the number of anagenic hair follicle in grape sap (100 mg/kg) group ($P < 0.001$), sebaceous glands ($P < 0.001$), blood vessel density ($P < 0.001$), and hair growth length ($P < 0.001$). Also, wnt and β -catenin gene expression was elevated. The data showed that wnt and β -catenin gene expression were elevated in grape sap treated animals versus bleomycin group ($P < 0.01$ and 0.001 , respectively).

Conclusion and implications: Our finding showed that grape sap can be effective in increasing hair growth a gains bleomycin toxic effects on skin hair growth.

Keywords: Antioxidant capacity; β -catenin; Grape sap, Hair follicle; wnt; Rat.

INTRODUCTION

The skin, as the largest organ, is responsible for protecting the body from chemical agents, bacteria, viruses, radiation, and trauma (1). The skin has a variety of attachments that can be used for sweat glands, fat glands (sebaceous), nails, and hair (2). Various factors contribute to the reduction of growth or hair loss, which can be attributed to poor hair nutrition, increased age, hormone imbalance, and stress (3). Studies have shown that oxidative stress and free radicals play an important role in hair loss and survival (4). These radicals are highly active molecules that can directly affect the membrane structure, lipids, proteins, and DNA (5,6).

Although the mechanism of hair growth is not completely clear, the core of the process is the interaction between the mesenchymal cell and epithelial cell population in the hair follicle (7,8). During hair growth, the hair follicle has three stages of anagen, catagen, and telogen (9,10). In the anagen stage, the follicular cells are constantly growing, divided, branching, and forming the hair's stem (growth stage) (11). In the transitional or catagen phase, hair growth is slowed down and the hair is wrinkled (12).

Access this article online



Website: <http://rps.mui.ac.ir>

DOI: 10.4103/1735-5362.293513

The final stage of the hair growth phase is hair loss or telogen phase. At this stage, hair growth is stopped, and the hair follicle is loose and the hair strain is shaken due to the pressure of new hair growing in (12). It has been shown that different genes are involved in hair growth, such as wingless/integrated (wnt) and β -catenin (13,14). The family of wnt proteins activates intracellular signaling through wnt/ β -catenin, wnt/polarity, wnt/ ca^{2+} pathways (15). During telogen bulge stem cells reside in a wnt-restricted environment. During the transition between hair cycle telogen and anagen phases, nuclear β -catenin and Lef1/ β -catenin reporter expression can be detected at the bulging base, where the new hair follicle begins to emerge. β -Catenin is involved in the differentiation of stem cells in the skin which has a critical role in wnt signaling (16,17). In the absence of β -catenin, skin stem cells are not able to differentiate into follicular keratinocytes, and instead differentiate to the epidermal fate (7). Currently, natural products are used to improve the damage caused by oxidative stress, apoptosis, and inflammation in various pathological situations (18,19). Grape in various forms (such as grape juice, wine, grape seed oil, and its extract) is used for the cure of several diseases in folk remedies (20). It has been shown that several polyphenol and antioxidant compounds are found in grape (21,22). The grape sap is a liquid that spills from freshly cut branches at the beginning of the spring. This watery compound contains glucose, fructose, calcium, potassium, iron, magnesium, phosphate, tartaric acid, citric acid, fumaric acid, malic acid, succinic acid, vitamin B1, vitamin B6, glutamic acid, glutamine, proline, and alanine (23). Due to the important compounds that are present in grape sap and as there is little study on this fluid, especially its effect on the hair follicles and skin, in this study we determined the effect of grape sap on the expression of wnt and β -Catenin (as hair follicular proliferative markers) mRNA, total antioxidant capacity, and some histological factors are studied in bleomycin treated rats.

MATERIALS AND METHODS

Plant material

First, the grape sap was harvested from the cut branches of the grape in late March and

early April 2018 (in Rafsanjan, I.R. Iran). In brief, we cut the grape branches with a clean and sharp stainless steel knife. Then the edge of the cut branches was kept in a clean nylon bag for 24 h. The harvested grape sap was kept clean in glass containers. We then placed the grape sap liquid in a freeze-drying unit for 48 h. The condensed matter was collected and then weighed.

Animals

Thirty male Wistar rats (200-250 g) were provided from the animal house of Rafsanjan University of Medical Sciences, Rafsanjan, I.R. Iran. The rats were kept under light/dark cycles (12/12-h light/dark). Attempts were made to minimize animal suffering during the whole experimental course. All experimental procedures in this investigation were approved by the Ethical Committee of Rafsanjan University of Medical Sciences (IR.RUMS.REC.1396.74) based on the United States NIH Guide for the Care and Use of Laboratory Animals (publication no. 85-23).

Experimental groups

The animals were randomly distributed to five experimental groups, 6 each. (1) Control group (intact group); (2) bleomycin + normal saline group, the animals in this group were treated with bleomycin (1.7 mg/kg, i.p, every 5 days for 20 days) then the rats were treated with normal saline (2 mL, daily, orally) for 21 days (from day 21 to 41), (3-5) bleomycin + grape sap groups, the animals in these groups were treated with bleomycin (1.7 mg/kg, i.p, every 5 days for 20 days) then the rats were administrated grape sap (1, 10, and 100 mg/kg, daily, orally) for 21 days (from day 21 to 41).

Hair loss induction

In order to induce hair loss, 1.7 mL/kg bleomycin (Sigma, USA) was injected intraperitoneally every 5 days for 21 days (24). The hair follicles, as well as the number of anagenic hair follicles, hair growth length, number of sebaceous glands, number of blood vessels, and the expression of wnt and β -catenin genes, were sampled from the rats back area on day 41.

Table 1. Primers and their sequences.

Genes	Sequences	Annealing temperature (°C)	Size (bp)
wnt	F:5'- GTGATGCAAATAGGCAGCCG -3' R:5'- ATAGTCGATGTTGTCCCCGC -3'	60	186
catenin-B	F:5'- ACCATCGAGAGGGCTTGTTG -3' R: 5'- CTGGCGACCCAAGCATTTTC -3'	60	75
Actin-B	F:5'- ATGGTGGGTATGGGTCAGAA -3' R: 5'- TGGCTGGGGTGTGAAGGTC -3'	60	265

Total antioxidant capacity measurement

Commercial biochemical kits (Zellbio, Germany) were used to measure serum levels of total antioxidant capacity (TAC) according to the company's guidelines.

Tissue sample collection

After the completion of the experimental period, animals were sacrificed under deep anesthesia using ketamine (50 mg/ kg, i.p.) and xylazine (5 mg/kg, i.p.). The blood serum and skin tissue were rapidly collected after killing the animals. Skin tissues were divided into two parts for histological and real-time polymerase chain reaction (RT-PCR).

Histopathological examination

Histological skin tissue samples were dehydrated and embedded in paraffin, then paraffin blocks were prepared and, cut into 5 µm-thick sections. One series of tissue sections were stained with hematoxylin and eosin (H&E), and the other sections were stained with periodic acid-Schiff (PAS) staining. H&E staining was done to evaluate the blood vessel and anagenic follicles count, hair follicles changes in the skin tissue, the mean number of blood vessels per unit area were counted in each experimental group. PAS staining was used to detect the thickness of the glass membrane of the hair follicle. The stained slides were seen using a light microscope equipped with a digital camera (Olympus CX31, Japan).

RT-PCR reaction

Total RNA extraction of cells was done on the tissue separated from skin tissue using RNA Kit (Pars Tous, I.R. Iran) according to its protocol. The RNA sample was dissolved in diethylpyrocarbonate-treated water and RNA contents were determined by a spectrophotometer (APEL PD-303UV, Japan).

The fidelity of extracted RNA was examined by electrophoresis 1% agarose and further staining with DNA Green Viewer™ and using Gel Doc three bands were seen from each RNA sample. cDNA was synthesized using a reverse transcriptase kit (Bioneer, Korea). The cDNA was stored at -20 °C or immediately used for quantitative RT-PCR. The cDNA was synthesized by a thermocycler device (Bio-Rad, USA). Subsequently, RNA was converted to cDNA by reverse transcriptase enzyme, which was used as a target in the RT-PCR technique. To do so, we used 10 µL of diethylpyrocarbonate, total RNA, oligo dT, and random hexamer primers. Then, they were incubated for 10 min at 70 °C. After this step, 10 µL of RT-mix was added to the micro-tube. The mixture was kept at 42 °C for 60 min for cDNA synthesis. Finally, to inactivate RT-enzymes, the mixture was incubated at 95 °C for 5 min. The primers (Table 1) were obtained from Takapouzist Co. (I.R. Iran).

Statistical analysis

The results were expressed as the mean ± standard deviation (SD). The results were evaluated by one-way ANOVA test. Tukey post hoc test was used to determine the differences between experimental groups. Data were considered significant at $P < 0.05$.

RESULTS

The effects of grape sap on histological parameters

The histological analysis in the hair follicles of rats displayed that anagenic follicles had a rounded and prominent nucleus, and a specific area and coherent tissue (Fig. 1A). For the determination of telogenic follicles, extremely dense, wrinkled nucleus, and unspecified nuclei were used (Fig. 1B).

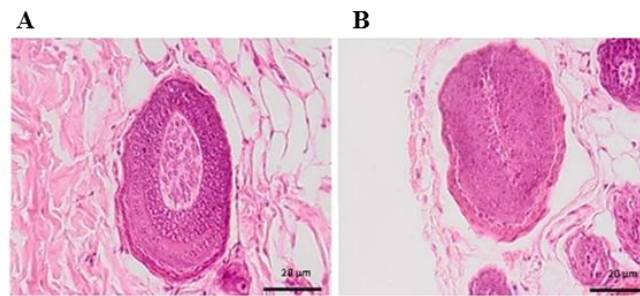


Fig. 1. The effects of grape sap on hair follicle morphological parameters in bleomycin treated rats. The H&E histologic staining show the different regions of the hair follicles in (A) anagen and (B) telogen phase. (Magnification: 40×).

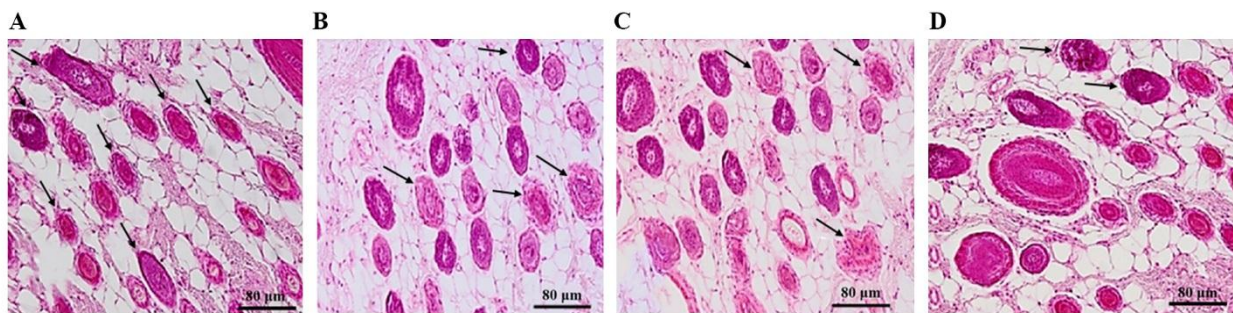


Fig. 2. The effects of grape sap on telegenic follicle density in bleomycin treated rats. The H&E histologic staining show sections of the skin hair follicles. The arrows show telegenic hair follicles in (A) bleomycin, in, (B) bleomycin + 1 mg/kg grape sap, (C) bleomycin + 10 mg/kg grape sap, and (D) bleomycin + 100 mg/kg grape sap. (Magnification: 10×).

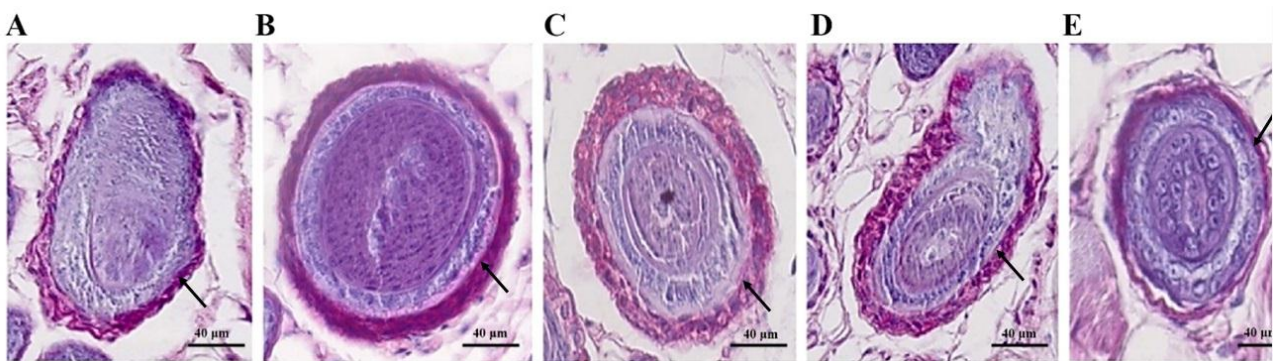


Fig. 3. Periodic acid-Schiff staining, a cross-section of the hair follicle in experimental groups. The arrows represent the glass membrane of the hair follicle (which is purplish-colored) (A) bleomycin, in (B) control, (C) bleomycin + 1 mg/kg grape sap, (D) bleomycin + 10 mg/kg grape sap, and (E) bleomycin + 100 mg/kg grape sap. (Magnification: 20×).

Also, the telegenic follicle was seen in the all experimental group which were treated with bleomycin. As shown in Fig 2, grape sap administration leads to decrease in the telegenic follicles (Fig. 2).

Glass membrane thickness did not have any significant change in the grape sap-treated

groups compared to other experimental groups (Fig. 3). The vessel density (Fig. 4A), the number of sebaceous glands (Fig. 4B), anagenic hair follicles (Fig. 4C), and hair growth lengths (Fig. 4D) were significantly increased in grape sap (10 and 100 mg/kg) treated rats compared to bleomycin group.

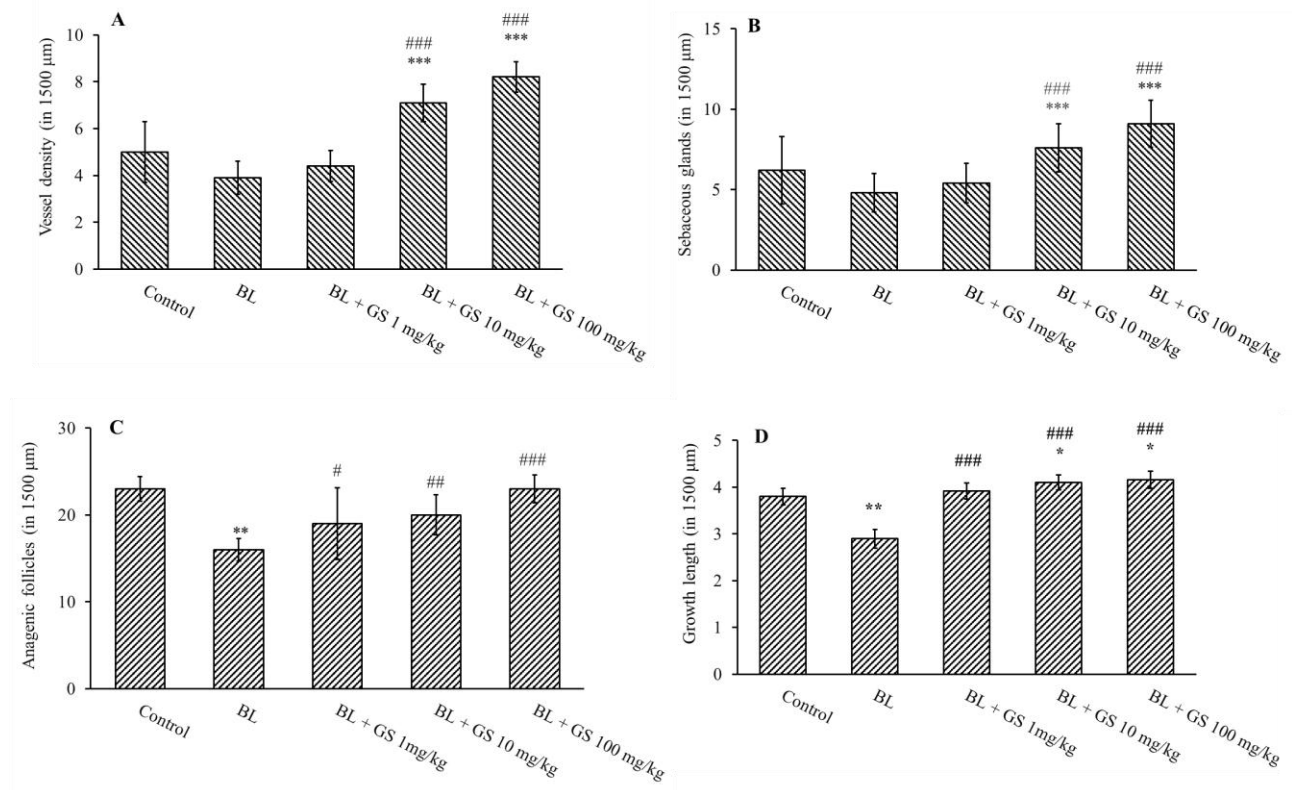


Fig. 4. (A) Blood vessel density, (B) the number of sebaceous glands, (C) anagenic hair follicles, and (D) hair growth length in all experimental groups. The data are expressed as the means \pm SD, $n = 5$ rat/group. $*P < 0.05$, $**P < 0.01$, and $***P < 0.001$ indicate significant differences in comparison with the control group; $\#P < 0.05$, $\#\#\#P < 0.01$, and $\#\#\#\#P < 0.001$ versus bleomycin group. BL, Bleomycin; GS, grape sap.

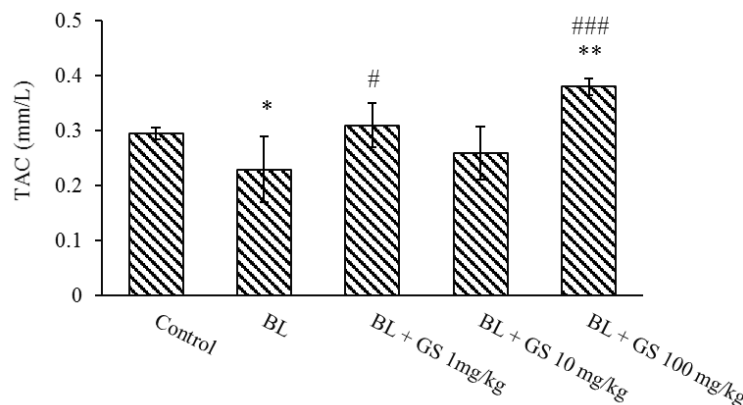


Fig. 5. TAC in serum of bleomycin treated rats. The data are expressed as the means \pm SD, $n = 5$ rat/group. $*P < 0.05$ and $**P < 0.01$ indicate significant differences in comparison with the control group; $\#P < 0.05$ and $\#\#\#P < 0.001$ versus bleomycin group. TAC, Total antioxidant capacity; BL, Bleomycin; GS, grape sap.

Total antioxidant capacity

The comparison of the mean antioxidant absorption coefficient in different experimental groups showed a significant increase in grape sap (1 and 100 mg/kg) treated rats compared to the bleomycin group (Fig. 5).

Evaluation of *wnt* and β -catenin genes expression

The results of the molecular test indicated an increase in the expression of the *wnt* gene in the treatment groups (Fig. 6A). The data showed that bleomycin treatment cannot change the *wnt* gene expression in rats.

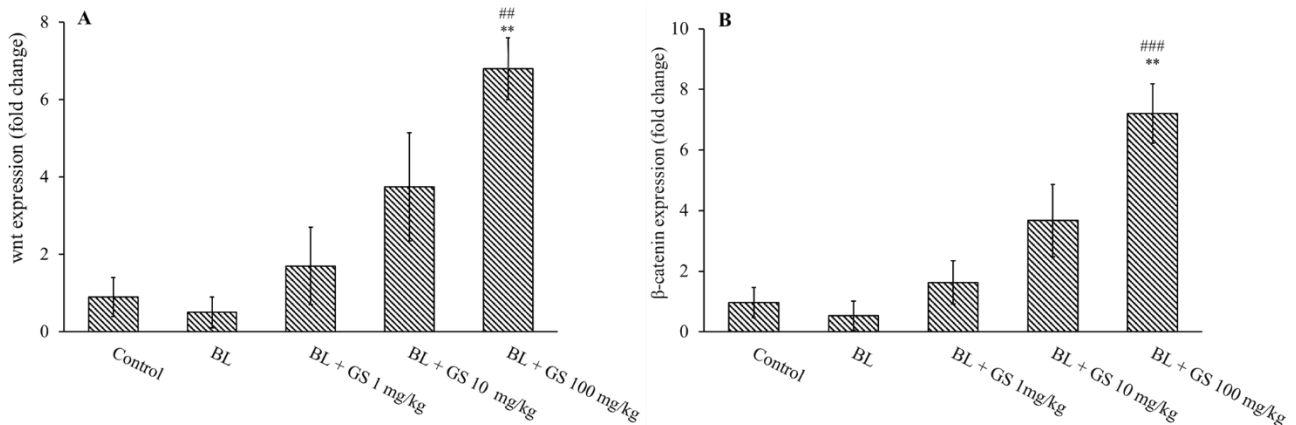


Fig. 6. (A) wnt and (B) β -catenin genes expression in skin of bleomycin treated rats. The data are expressed as the means \pm SD, n = 5 rat/group. ** $P < 0.01$ indicates significant differences in comparison with the control group; ### $P < 0.001$ and ### $P < 0.001$ versus bleomycin group. BL, Bleomycin; GS, grape sap.

However, wnt gene expression was significantly increased in bleomycin + 100 mg/kg grape sap compared to the control ($P < 0.01$) and bleomycin-treated rats ($P < 0.01$). The results of the RT-PCR test indicated an increase in the expression of the β -catenin gene in the treatment groups (Fig. 6B). The data showed that bleomycin treatment cannot change the β -catenin gene expression in rats. However, β -catenin gene expression was significantly increased in bleomycin + 100 mg/kg grape sap compared to the control ($P < 0.001$) and bleomycin-treated rats ($P < 0.001$).

DISCUSSION

We evaluated the effect of grape sap on the hair growth, and some histopathological and molecular factors in bleomycin treated rats. Our findings showed that the administration of grape sap can exert some beneficial effects on hair growth and skin health in bleomycin treated rats.

Many factors can slow or even disrupt hair growth such as high fever, thyroid disease, anemia, certain diets, consumption of some drugs, inflammatory or infectious skin diseases, chemical materials, chemotherapy, stress, etc. (24-27).

Today, the side effects of chemical drugs have been revealed. On the other hand, the use of herbal medicines to strengthen and increase hair growth is increasing. The normal cycle of hair growth and hair loss in all body hair includes active growth stage (anagen), transitional stage (catagen), and hair loss (telogen) (28).

Our findings showed that grape sap can increase total antioxidant capacity in the serum of bleomycin treated rats. In agreement with our findings, it has been shown the grape seeds extract has protective effects against cadmium toxicity in the lung of male Wistar rats by elevation of some antioxidant parameters such as TAC (29). Also, Züllü *et al.* showed that grape seed extract with tocopherol decreases oxidative stress and also increases hair growth in humans (30,31).

In a study conducted by Singha *et al.* the antioxidant effect of four different grapevine extracts on human lymphocyte cells was investigated. Their results showed that grapevine extract is a potential source of natural antioxidant that plays an important role in decreasing the oxidative stress induced by ionizing radiation and apoptosis inhibition (32). Also, Devi *et al.* showed the benefits of grape seed proanthocyanidin extract in treating the effects of age-related oxidative stress. That study results showed that grape seed proanthocyanidin decreases brain oxidative stress in middle-aged and adult rats (33). Our results showed that grape sap administration reduced the telogen and increased the anagen phase. Similar to our findings, it has been shown that grape seed extract proanthocyanidins have growth-promoting activity (34). Soref *et al.* showed that topical administration of resveratrol as one of the main grape polyphenols can be effective in prevention of the chemotherapy and radiotherapy-induced alopecia in the rat skin (35). Grape sap treatment can increase the expression of wnt

and β -catenin as well as blood vessel density in the present study.

We showed grape sap increased the β -catenin and wnt gene expression in the bleomycin-treated rats in the present study. Atitdhika *et al.* conducted a study to determine the role of β -catenin in the fate of dorsal dermal cells using immunocytochemistry and histology. In line with our study, they showed that when β -catenin is activated in an En1 cell (homeobox protein engrailed-1 expressed in the central dermomyotome), it expresses Dermol1 in all En1 cells and as a result stimulates hair growth by activating the wnt/ β -catenin and vascular endothelial growth factor receptor 2 (VEGF-R2) pathways in the mouse (36). Andl, *et al.* who evaluated the role of the wnt gene on the growth of hair follicles using Dickkopf 1 as an inhibitor of the wnt, concluded that wnt signaling is required to induce the hair follicle in mice skin (28).

CONCLUSION

Altogether, the molecular and histopathological data of this study indicate that grape sap as a natural product, due to its rich antioxidant property can be effective in boosting and enhancing hair growth in bleomycin-treated rats. The grape sap, at least in part, through the antioxidative property, increases the angiogenesis, and elevation in wnt and β -catenin gene expression increases the hair growth in rat skin.

ACKNOWLEDGMENTS

This work was supported by the Rafsanjan University of Medical Sciences via Grant No. 96048.

CONFLICT OF INTEREST STATEMENT

The authors declare no conflicts of interest in this study.

AUTHORS' CONTRIBUTIONS

M. Shariati-Kohbanani and M. M. Taghavi conceived and designed the experiments, M. Kazemi performed the experiments,

A. Kaeidi, A. Shabanizadeh, and Z. Taghipour analyzed the data, and M. Kazemi, M. Shariati-Kohbanani, and A. Kaeidi wrote the paper.

REFERENCES

1. Mescher AL. Junqueira's basic histology: text and atlas. 14th ed. New York; McGraw-hill Medical; 2013. pp. 193-208.
2. Hendriks FM, Brokken D, Oomens CW, Bader DL, Baaijens FP. The relative contributions of different skin layers to the mechanical behavior of human skin *in vivo* using suction experiments. *Med Eng Phys.* 2006;28(3):259-266. DOI: 10.1016/j.medengphy.2005.07.001.
3. Shapiro J, Wiseman M, Lui H. Practical management of hair loss. *Can Fam Physician.* 2000;46(7):1469-1477.
4. Shah AA, Sinha AA. Oxidative stress and autoimmune skin disease. *Eur J Dermatol.* 2013;23(1):5-13. DOI: 10.1684/ejd.2012.1884.
5. Ghobadi S, Dastan D, Soleimani M, Nili-Ahmadabadi A. Hepatoprotective potential and antioxidant activity of *Allium tripedale* in acetaminophen-induced oxidative damage. *Res Pharm Sci.* 2019;14(6):488-495. DOI: 10.4103/1735-5362.272535.
6. Arck PC, Overall R, Spatz K, Liezman C, Handjiski B, Klapp BF, *et al.* Towards a "free radical theory of graying": melanocyte apoptosis in the aging human hair follicle is an indicator of oxidative stress induced tissue damage. *FASEB J.* 2006;20(9):1567-1569. DOI: 10.1096/fj.05-4039fje.
7. Huelsken J, Vogel R, Erdmann B, Cotsarelis G, Birchmeier W. β -Catenin controls hair follicle morphogenesis and stem cell differentiation in the skin. *Cell.* 2001;105(4):533-545. DOI: 10.1016/s0092-8674(01)00336-1.
8. Sennett R, Rendl M. Mesenchymal-epithelial interactions during hair follicle morphogenesis and cycling. *Seminars in cell & developmental biology.* 2012;23(8):917-927. DOI: 10.1016/j.semcd.2012.08.011.
9. Enshell-Seijffers D, Lindon C, Kashiwagi M, Morgan BA. β -Catenin activity in the dermal papilla regulates morphogenesis and regeneration of hair. *Dev Cell.* 2010;18(4):633-642. DOI: 10.1016/j.devcel.2010.01.016.
10. Jain PK, Das D, Singhai AK. Alternative herbal drugs used for treating hair disease. *Asian J Pharm Clin Res.* 2016;9(1):75-77.
11. Mecklenburg L, Tobin DJ, Müller-Röver S, Handjiski B, Wendt G, Peters EM, *et al.* Active hair growth (anagen) is associated with angiogenesis. *J Investig Dermatol.* 2000;114(5):909-916. DOI: 10.1046/j.1523-1747.2000.00954.x.
12. Gizlenti S, Ekmekci TR. The changes in the hair cycle during gestation and the post-partum period. *J Eur Acad Dermatol Venereol.* 2014;28(7):878-881. DOI: 10.1111/jdv.12188.

13. Hemmati AA, Foroozan M, Houshmand G, Moosavi ZB, Bahadoram M, Maram NS. The topical effect of grape seed extract 2% cream on surgery wound healing. *Glob J Health Sci.* 2014;7(3):52-58. DOI: 10.5539/gjhs.v7n3p52.
14. Rishikaysh P, Dev K, Diaz D, Qureshi WMS, Filip S, Mokry J. Signaling involved in hair follicle morphogenesis and development. *Int J Mol Sci.* 2014;15(1):1647-1670. DOI: 10.3390/ijms15011647.
15. Miller JR. The wnts. *Genome Biol.* 2001;3(1):reviews3001-1. DOI: 10.1186/gb-2001-3-1-reviews3001.
16. Clevers H, Nusse R. Wnt/ β -catenin signaling and disease. *Cell.* 2012;149(6):1192-1205. DOI: 10.1016/j.cell.2012.05.012.
17. MacDonald BT, Tamai K, He X. Wnt/ β -catenin signaling: components, mechanisms, and diseases. *Dev Cell.* 2009;17(1):9-26. DOI: 10.1016/j.devcel.2009.06.016.
18. Konczak I, Roulle P. Nutritional properties of commercially grown native Australian fruits: lipophilic antioxidants and minerals. *Food Res Int.* 2011;44(7):2339-2344. DOI: 10.1016/j.foodres.2011.02.023.
19. Hofseth LJ, Wargovich MJ. Inflammation, cancer, and targets of ginseng. *J Nutr.* 2007;137(1 Suppl):183S-185S. DOI: 10.1093/jn/137.1.183S.
20. Schieber A, Stintzing FC, Carle R. By-products of plant food processing as a source of functional compounds-recent developments. *Trends Food Sci Technol.* 2001;12(11):401-413. DOI: 10.1016/S0924-2244(02)00012-2.
21. Cheung DY, Kim JI, Park SH, Kim JK. Proanthocyanidin from grape seed extracts protects indomethacin-induced small intestinal mucosal injury. *Gastroenterol Res Pract.* 2014;2014:618068,1-8. DOI: 10.1155/2014/618068.
22. Xia EQ, Deng GF, Guo YJ, Li HB. Biological activities of polyphenols from grapes. *Int J Mol Sci.* 2010;11(2):622-646. DOI: 10.3390/ijms11020622.
23. Nicolescu MP, Nicolescu R. Ocular sevtherapy with the help of crying sap from grape vine. *AMT.* 2012;2(1):165-168.
24. Batchelor D. Hair and cancer chemotherapy: consequences and nursing care-a literature study. *Eur J Cancer Care (Engl).* 2001;10(3):147-163. DOI: 10.1046/j.1365-2354.2001.00272.x.
25. Larki A, Hemmati AA, Arzi A, Borujerdnia MG, Esmailzadeh S, Karami MZ. Regulatory effect of caffeic acid phenethyl ester on type I collagen and interferon-gamma in bleomycin-induced pulmonary fibrosis in rat. *Res Pharm Sci.* 2013;8(4):243-252.
26. Trüeb RM. Systematic approach to hair loss in women. *J Dtsch Dermatol Ges.* 2010;8(4):284-297. DOI: 10.1111/j.1610-0387.2010.07261.x.
27. Trost LB, Bergfeld WF, Calogeras E. The diagnosis and treatment of iron deficiency and its potential relationship to hair loss. *J Am Acad Dermatol.* 2006;54(5):824-844. DOI: 10.1016/j.jaad.2005.11.1104.
28. Andl T, Reddy ST, Gaddapara T, Millar SE. WNT signals are required for the initiation of hair follicle development. *Dev Cell.* 2002;2(5):643-653. DOI: 10.1016/s1534-5807(02)00167-3.
29. Baiomy AA. Protective role of grape seeds extract against cadmium toxicity in the lung of male wistar rats. *J Cytol Histol.* 2016;S5:1-8. DOI: 10.4172/2157-7099.1000S5:004.
30. Züllli F, Belser E, Neuenschwander M, Muggli R. Antioxidants from grape seeds protect hair against reactive oxygen species. *PCare.* 2001;65-67.
31. Hajhashemi V, Vaseghi G, Pourfarzam M, Abdollahi A. Are antioxidants helpful for disease prevention? *Res Pharm Sci.* 2010;5(1):1-8.
32. Singha I, Das SK. Grapevine fruit extract protects against radiation-induced oxidative stress and apoptosis in human lymphocyte. *Indian J Exp Biol.* 2015;53(11):753-761.
33. Asha Devi S, Sagar Chandrasekar BK, Manjula KR, Ishii N. Grape seed proanthocyanidin lowers brain oxidative stress in adult and middle-aged rats. *Exp Gerontol.* 2011;46(11):958-964. DOI: 10.1016/j.exger.2011.08.006.
34. Begum S, Gu LJ, Lee MR, Li Z, Li JJ, Hossain MJ, *et al.* *In vivo* hair growth-stimulating effect of medicinal plant extract on BALB/c nude mice. *Pharm Biol.* 2015;53(8):1098-1103. DOI: 10.3109/13880209.2014.959614.
35. Soref CM, Fahl WE. A new strategy to prevent chemotherapy and radiotherapy-induced alopecia using topically applied vasoconstrictor. *Int J Cancer.* 2015;136(1):195-203. DOI: 10.1002/ijc.28961.
36. Atit R, Sgaier SK, Mohamed OA, Taketo MM, Dufort D, Joyner AL, *et al.* β -catenin activation is necessary and sufficient to specify the dorsal dermal fate in the mouse. *Dev Biol.* 2006;296(1):164-176. DOI: 10.1016/j.ydbio.2006.04.449.