

[LETTERS TO THE EDITOR]

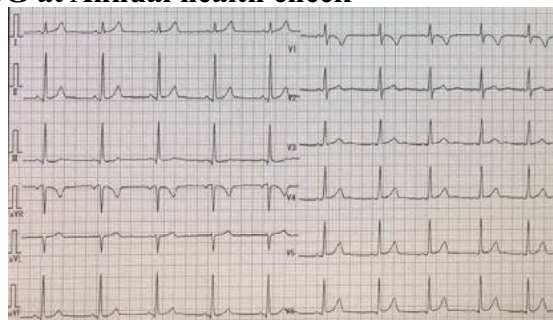
**Chest Pain with New Abnormal
Electrocardiogram Development after Injection of
COVID-19 Vaccine Manufactured by Moderna**

Key words: acute myocarditis, viral infection, side effect, vaccine

(Intern Med 61: 2089-2090, 2022)
(DOI: 10.2169/internalmedicine.8711-21)

To the Editor Kurihara et al. reported that 82.1% of patients with Coronavirus-2019 (COVID-19)-like symptoms were diagnosed with non-COVID-19, with potentially fatal diseases detected in 14.2% of them. In addition, they concluded that, “Several potentially fatal diseases remain masked among the wave of COVID-19 mimics” (1). We recently experienced a case of COVID-19 vaccine-related probable myocarditis that was masked at the first clinic visit. In this case, COVID-19 infection was suspected and treated because of chest symptoms with a fever. A cardiac examination was not performed. COVID-19 vaccine-caused myocarditis has been reported in young men (2-4). However, few reports on cases of COVID-19 vaccine-caused myocarditis exist in Japan, especially among young women. We herein report a young woman with chest pain and abnormal electrocardiogram (ECG) changes after receipt of a COVID-19 vaccine manufactured by Moderna. A 19-year-old woman (158 cm, 63 kg) visited our outpatient clinic because of recurrent chest pain with a low-grade fever (37.6°C) 26 days after receiving her second COVID-19 vaccination. The chest pain lasted for over six hours. She had first complained of a fever (37.6°C) with chest pain 1 week after receiving her second vaccination and visited another clinic. COVID-19 infection was suspected because of the fever, but aside from a polymerase chain reaction (PCR) test, which was negative, no detailed examination was performed. Acetaminophen was prescribed. Her pain temporarily subsided but then recurred. Her history was deemed non-contributory. She visited our outpatient clinic because of sustained chest pain. An ECG revealed sinus tachycardia and new ST-T segment abnormal changes compared with the ECG findings obtained at an annual health checkup. New ST segment depression in II, III and aVF and inverted T wave in III, aVF and V2-3 were observed, as shown in the Figure. Chest X-ray was normal. Laboratory data showed the following: negative troponin T; AST/ALT, 14/12 U/L; CPK/CPKMB, 57/2.1 U/L; BUN/Cr, 10.7/0.5 mg/dL; CRP, 0.10 mg/dL; and WBC, 10,500/ μ L (μ L; microliter). PCR testing for COVID-19 virus was nega-

ECG at Annual health check



ECG at symptoms

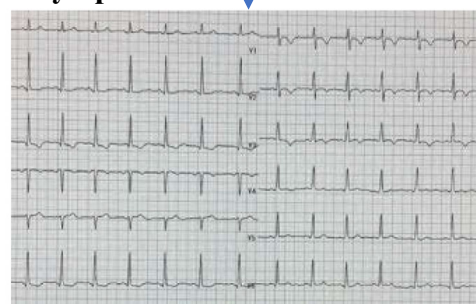

Figure. Electrocardiogram changes at the annual health checkup and symptoms. ECG: 12-lead electrocardiogram

tive. Loxoprofen 60 mg thrice daily was prescribed. Her chest pain was relieved one week later. One month later, her ECG findings returned to normal. According to the proposed Bozkurt’s criteria (5), probable acute myocarditis due to COVID-19 vaccination was diagnosed. Since myocarditis can be fatal and most reported COVID-19 vaccination-related myocarditis cases have been seen in men (2-4), myocarditis due to COVID-19 vaccination in women is likely to be overlooked. Chest symptoms after COVID-19 vaccination in women should therefore be carefully monitored. Further epidemiological research on the cardiac side effects of COVID-19 vaccination in women seems necessary.

The authors state that they have no Conflict of Interest (COI).

Bonpei Takase^{1,2}, Katsumi Hayashi², Tetsuya Hisada²,
Tyouji Tsuchiya³, Nobuyuki Masaki¹ and
Masayoshi Nagata²

References

1. Kurihara S, Nakajima M, Kaszynski RH, et al. Prevalence of COVID-19 mimics in the emergency department. *Intern Med* **60**: 3087-3092, 2021.

¹Department of Intensive Care Medicine, National Defense Medical College, Japan, ²Division of Cardiology, Iruma Heart Hospital, Japan and ³Department of General Medicine, Sakado Central Hospital, Japan
Received: September 21, 2021; Accepted: October 24, 2021; Advance Publication by J-STAGE: December 4, 2021
Correspondence to Dr. Bonpei Takase, dui1577@db3.so-net.ne.jp

2. Patel YR, Louis DW, Atalay M, Agarwal S, Shah NR. Cardiovascular magnetic resonance findings in young adult patients with acute myocarditis following mRNA COVID-19 vaccination: a case series. *J Cardiovasc Magn Reson* **23**: 101, 2021.
3. Kim HW, Jenista ER, Wendell DC, et al. Patients with acute myocarditis following mRNA COVID-19 vaccination. *JAMA Cardiol* **6**: 1196-1201, 2021.
4. Montgomery J, Ryan M, Engler R, et al. Myocarditis following immunization with mRNA COVID-19 vaccines in members of the US military. *JAMA Cardiol* **6**: 1202-1206, 2021.
5. Bozkurt B, Kamat I, Hotez PJ. Myocarditis with COVID-19 mRNA vaccines. *Circulation* **144**: 471-484, 2021.

The Internal Medicine is an Open Access journal distributed under the Creative Commons Attribution-NonCommercial-NoDerivatives 4.0 International License. To view the details of this license, please visit (<https://creativecommons.org/licenses/by-nc-nd/4.0/>).

© 2022 The Japanese Society of Internal Medicine
Intern Med 61: 2089-2090, 2022