



Open Access

LETTER TO THE EDITOR

Male Health

Right cryptorchid testicular metastasis from descending colon carcinoma: a case report of “Krukenberg tumor” in male

Qi Xu^{1,2}, Xiao-Lei Li¹, Ya-Wei Yu³, Lai-Rong Dong², Jian-Guo Shen¹, Lin-Bo Wang¹

Asian Journal of Andrology (2015) 17, 171–172; doi: 10.4103/1008-682X.142769; published online: 03 October 2014

Dear Editor,

We present here a case report of “Krukenberg tumor” in male. In 1896, Friedrich Krukenberg (1871–1946), a German gynecologist and pathologist, described what he presumed as a new type of primary ovarian neoplasm. The true metastatic nature of this lesion was established 6 years later and termed as “Krukenberg tumor”.¹ Now, the term “Krukenberg tumor” has been used either as a broad definition to indicate all metastatic tumors to the ovaries or to describe just metastatic tumors from the gastrointestinal tract containing the typical signet ring cell with intracellular mucin.^{2–6} Our case, as an analog in male, has criteria to be called “Krukenberg tumor” in male.

A 73-year-old male patient, who had a history of right inguinal testicle, was admitted to our department for right inguinal and left abdominal pain. Physical examination revealed a firm right testis that was located in the superficial inguinal pouch. On the other side, the left testis was normal. The physical examination also revealed that there was a palpable mass in the left lower abdomen. The whole abdominal computed tomography indicated a cryptorchid testis in the right groin (**Figure 1**) and a huge tumor at the descending colon (**Figure 2**). Colonoscopy was then performed showing a mass at the descending colon with intestinal stenosis. The biopsy of the colon mass indicated moderately differentiated adenocarcinoma. The laboratory tests of tumor markers such as carcinoembryonic antigen, CA 19-9, and alpha-fetoprotein were all in the standard range. Left hemicolectomy and right-sided orchiectomy were performed. During the operation, insufficient obliteration of the peritoneal gap in the abdominal inguinal ring with right cryptorchid testis was identified. There were no ascites, hepatic metastasis, or abdominal cavity metastasis, while the right cryptorchid testicular involvement was suspected. Histopathological examination confirmed moderately differentiated adenocarcinoma of the colon mass (**Figure 3**) and right cryptorchid testicular metastatic adenocarcinoma (**Figure 4**) which was histologically similar to the colonic origin. The colon tumor had extended through the serosa. The surface of the right cryptorchid testis was involved (**Figure 4**), while the internal organization was not involved (**Figure 5**). Metastasis to

three lymph nodes was also found in 14 examined mesenteric lymph nodes. The patient received postoperative chemotherapy that consisted of 12 cycles of mFOLFOX6. He was doing well during follow-ups and remained no recurrence at 20 months after surgery.

Reports on metastatic cancer of the testis, as analog Krukenberg tumor in male, are rare. Cryptorchid testicular metastasis, as a special type of testicular metastasis, scarcely has been reported. We searched the medical literature using the MEDLINE/PubMed database from 1950 to 2013. Our search yielded two cases of cryptorchid testicular metastasis, both from colon cancer. Rampa *et al.*⁷ reported a case of metastatic carcinoma from the sigmoid colon to the left cryptorchid testis. In another Spanish paper, Alvarez Pérez *et al.*⁸ reported a case of metastasis of carcinoma from the colon to cryptorchid testis. We described here for the first time, a metastasis of descending colon adenocarcinoma to the right cryptorchid testis.

Various pathways have been supposed as routes of cancer spread leading to the development of Krukenberg tumor. These include lymphatic spread, hematogenous spread, direct invasion, peritoneal seeding, etc. Al-Agha and Nicastrì¹ considered that retrograde lymphatic spread is the most likely route of metastasis. But Jun and Park⁹ reported the incidence of hematogenous recurrence was the highest. Other less common pathways of metastasis to the ovary occur via the peritoneum and vasculature.^{10,11} In male, the route for the spread of metastasis to the testes might be similar. Some possible pathways have been reported, including a retrograde lymphatic extension, direct invasion or extension from the original lesion, arterial and venous embolization from the tumor, and retrograde sperm duct extension.¹² Our case showed that the testicular maldescending led to an insufficient obliteration of the peritoneal gap in the abdominal inguinal ring and generated a patent processus vaginalis. This might provide a potential route for gastrointestinal tumors spread through the patent processus vaginalis to testis. Therefore, our case provided a new pathway for the development of “Krukenberg tumor” in male.

The incidence of “Krukenberg tumor” in male is lower than that in female. Yada-Hashimoto *et al.*⁶ found that metastatic tumors accounted for 21.1% (64/304) of malignant ovarian tumors. While metastatic carcinoma to the testes is extremely rare, the incidence rates vary from 0.02% to 2.5%.¹³ Such a big difference might be explained in two reasons at least. One reason is that the sufficient obliteration in the abdominal inguinal ring prevents tumor transperitoneal seeding on testis in most

¹Department of Surgical Oncology, Affiliated Sir Run Run Shaw Hospital, Zhejiang University School of Medicine, Hangzhou, China; ²Department of Surgical Oncology, The Second Hospital of Jiaxing City, Jiaxing, China; ³Department of Pathology, The Second Hospital of Jiaxing City, Jiaxing, China.
Correspondence: Dr. LB Wang (wanglinbo@medmail.com.cn)
Received: 22 May 2014; Accepted: 22 July 2014

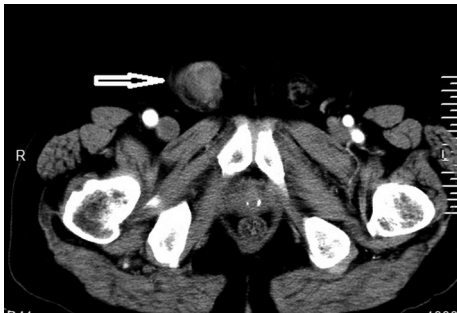

Figure 1: Computed tomography scan showing right cryptorchid testis in the right groin (marked by arrow).

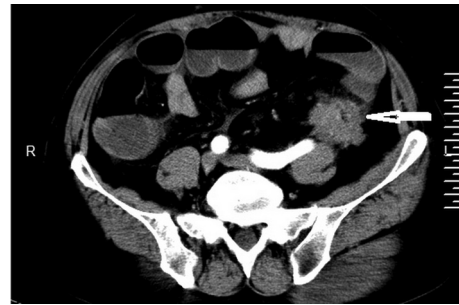


Figure 2: Computed tomography scan showing descending colon mass (marked by arrow).

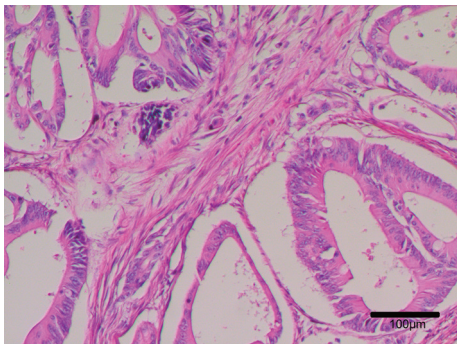


Figure 3: Histological examination of the descending colon mass showing moderately differentiated adenocarcinoma. Scale bar = 100 μ m.

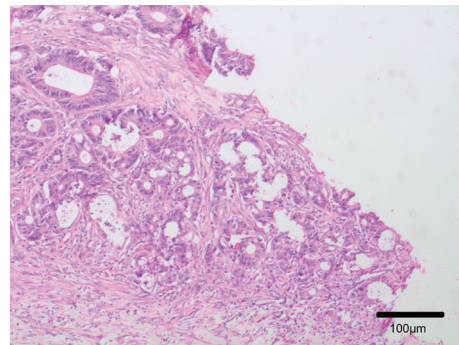


Figure 4: Histological examination of the surface of the right cryptorchid testis showing adenocarcinoma similar to the colonic origin. Scale bar = 100 μ m.

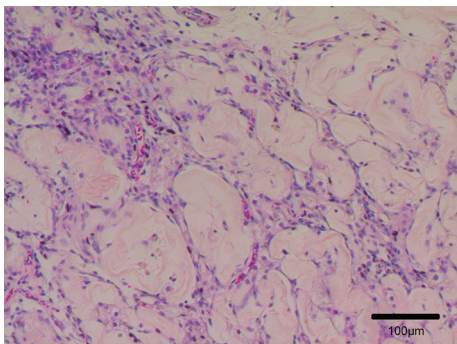


Figure 5: Histological examination showing the internal organization of the right cryptorchid testis was not involved. Scale bar = 100 μ m.

males. The other reason is that the lower temperature of the scrotum may be an unacceptable environment for growth of metastatic tumor cells, which was also supported by the study of Smallman and Odedra.¹⁴ In the present case, the male who had cryptorchid or maldescend testis, lost these advantages, therefore, having the same chance to develop “Krukenberg tumor” as female. Further studies are required to characterize this rare disease.

AUTHOR CONTRIBUTIONS

QX cared for the patients, collected the clinical information and drafted the manuscript. YWY helped to collect the pathological data. XXL, LRD, JGS, and LBW revised the manuscript and participated in critical discussion. All authors read and approved the final manuscript.

COMPETING INTERESTS

The authors declare no competing interests.

REFERENCES

- 1 Al-Agha OM, Nicastrì AD. An in-depth look at Krukenberg tumor: an overview. *Arch Pathol Lab Med* 2006; 130: 1725–30.
- 2 Woodruff JD, Novak ER. The Krukenberg tumor: study of 48 cases from the ovarian tumor registry. *Obstet Gynecol* 1960; 15: 351–60.
- 3 Mazur MT, Hsueh S, Gersell DJ. Metastases to the female genital tract. Analysis of 325 cases. *Cancer* 1984; 53: 1978–84.
- 4 Ulbright TM, Roth LM, Stehman FB. Secondary ovarian neoplasia. A clinicopathologic study of 35 cases. *Cancer* 1984; 53: 1164–74.
- 5 Russel P, Bannatyne P. *Surgical Pathology of the Ovaries*. Edinburgh: Churchill Livingstone; 1989. p. 474–501.
- 6 Yada-Hashimoto N, Yamamoto T, Kamiura S, Seino H, Ohira H, et al. Metastatic ovarian tumors: a review of 64 cases. *Gynecol Oncol* 2003; 89: 314–7.
- 7 Rampa M, Battaglia L, Caprotti A, Gazzano G, Prestianni P, et al. Metastasis of sigmoid colon cancer in cryptorchid testis: report of a case. *Tumori* 2012; 98: 63e–6e.
- 8 Alvarez Pérez JA, Vázquez Velasco L, González González JJ, Fresno Forcelledo MF. Metastasis of carcinoma of the colon to cryptorchid testis. An infrequent finding. *Rev Esp Enferm Apar Dig* 1989; 75: 213–4.
- 9 Jun SY, Park JK. Metachronous ovarian metastases following resection of the primary gastric cancer. *J Gastric Cancer* 2011; 11: 31–7.
- 10 Kakushima N, Kamoshida T, Hirai S, Hotta S, Hirayama T, et al. Early gastric cancer with Krukenberg tumor and review of cases of intramucosal gastric cancers with Krukenberg tumor. *J Gastroenterol* 2003; 38: 1176–80.
- 11 Kim NK, Kim HK, Park BJ, Kim MS, Kim YI, et al. Risk factors for ovarian metastasis following curative resection of gastric adenocarcinoma. *Cancer* 1999; 85: 1490–9.
- 12 Hatoum HA, Abi Saad GS, Otrock ZK, Barada KA, Shamseddine AI. Metastasis of colorectal carcinoma to the testes: clinical presentation and possible pathways. *Int J Clin Oncol* 2011; 16: 203–9.
- 13 Niesel T, Böhm J, Paul R, Breul J, Hartung R. Rare metastases of signet ring cell carcinomas to the scrotum: report of two cases. *Urology* 1996; 47: 769–71.
- 14 Smallman LA, Odedra JK. Primary carcinoma of sigmoid colon metastasizing to epididymis. *Urology* 1984; 23: 598–9.