

Case report

Post covid pneumonia pulmonary fibrosis and encephalitis in a term neonate with prenatal exposure to SARS CoV-2: A case report



Vaanathi Hementha Kumar^{a,*}, Chandrakumar Natarajan^a, M. Siddharth^a, S. Shivabalan^b, Gopinath^c, Dhanalakshmi^d, Shyam^a, Ahalya^a, Maria^a, Jean^a, Rajashree^a

^a Departments of Neonatology, Chennai, India

^b Pediatric Pulmonology, Chennai, India

^c Radiodiagnosis, Chennai, India

^d Pediatric Infectious disease Kanchi Kamakoti CHILDS Trust Hospital, Chennai, India

ARTICLE INFO

Article history:

Received 12 October 2021

Received in revised form 14 January 2022

Accepted 20 January 2022

Introduction

SARS CoV-2 infection is often asymptomatic or mild in neonates. Literature on clinical manifestations of the infection in neonates is limited. Recent systematic review on the clinical manifestations of COVID-19 in neonates found fever, non-specific respiratory and gastrointestinal symptoms as the most common presentation in neonates [1]. In a recent largest case series from India (n = 143) only 20% of the infants who tested positive by nasopharyngeal RT-PCR were found to be symptomatic [2]. While MIS-C in pediatric population as well as its neonatal entity MIS-N is well documented [3,4], pulmonary fibrosis is less well described in this age group. Although a common presentation in adults, with incidence as high as one-third of patients with advanced disease [5,6], the incidence in pediatric cohorts is varied from 0% [7] to 29% [8] across different cohorts. To our knowledge, pulmonary fibrosis has not been described in the neonates affected with SARS CoV-2. In this report we share our experience in managing a neonate with COVID19 who developed pulmonary fibrosis.

Case report

9 day old neonate born to primigravida mother with history of maternal covid 19 infection one week prior to delivery was referred to our center for further care. The neonate had respiratory distress

and hypoxia soon after birth. Mother had gestational diabetes since 20 weeks and was on insulin therapy. Antenatal growth scans were normal. Mother had fever with myalgia a week prior to delivery. Maternal COVID rapid antigen test done was positive and the baby was born by at 36+5 weeks by vaginal delivery at a government hospital in the neighboring state of Andhra Pradesh. APGARS were 6 and 8 at birth and 5 minutes and 10 minutes respectively. There was progressive respiratory distress soon after birth for which the baby was started on oxygen and referred to a another hospital. The baby tested positive for COVID 19 by rapid antigen test on post natal day 5, was transferred on oxygen by nasal prongs to our tertiary neonatal intensive care unit by day 9 of life for further care.

At admission, the baby had respiratory distress (SA score of 5) with preductal saturations of 87% in room air. She was hemodynamically stable with heart rate of 140/ min and noninvasive blood pressure of 68/38(44) mm Hg with normal first and second heart sounds. All peripheral pulses were well felt and capillary refill time was less than 3 s. She had an irritable cry, however head circumference, tone and activity were appropriate for age. There was no jaundice, hepatosplenomegaly, cutaneous rashes, petechiae or bleeds. The capillary blood gas at admission was suggestive of respiratory acidosis. Chest X ray was suggestive of bilateral hyperinflation with normal cardiothymic shadow. Nasopharyngeal Covid RT PCR for the neonate (day 9 of illness, at admission) and mother were both positive.

The baby was isolated in negative isolation as per infection control recommendations and started on non invasive positive pressure ventilation (NIPPV), intravenous fluids and empirical antibiotics (meropenem and amikacin) after sending routine laboratory

* Correspondence to. Department of Neonatology, Kanchi Kamakoti CHILDS Trust Hospital, 12-A, Nageswara Road, Nungambakkam, Chennai 600034 India.

E-mail address: vaanathihementha@gmail.com (V.H. Kumar).

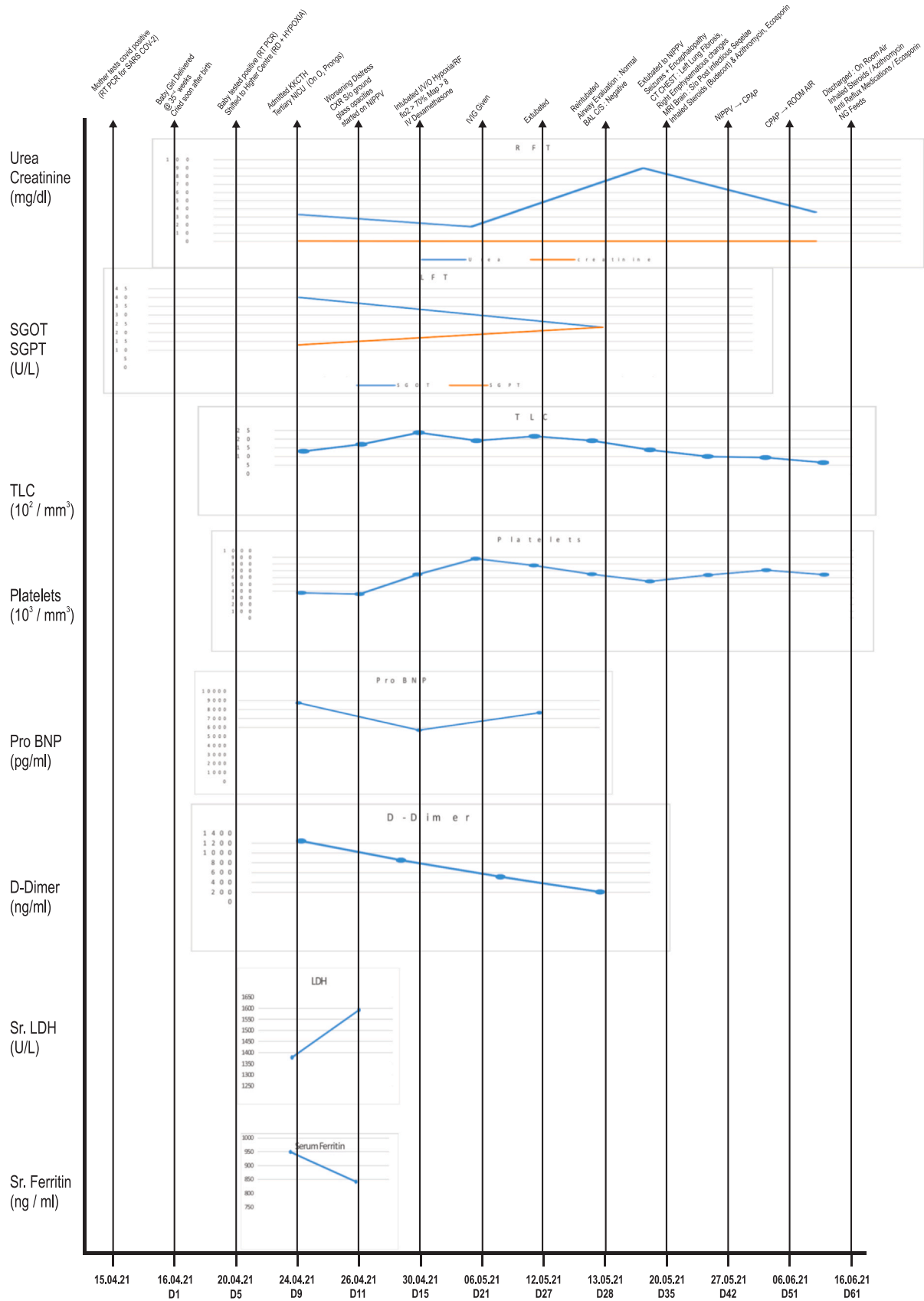


Fig. 1. Timeline of disease course along with laboratory markers.

investigations including blood cultures. Sepsis screen done at admission was negative. Renal and liver function tests were normal. Point of care ECHO done at admission revealed normal biventricular function with a small PDA/mild tricuspid regurgitation. By day 2 (day 11 of illness) of hospital stay, there was further deterioration with increase in fiO_2 requirement $> 60\%$ and capillary blood gas suggestive of worsening respiratory acidosis, hence she was intubated and started on invasive ventilation with MAP(Mean airway pressure) of 10 with fiO_2 of 70% on which targeted saturations were maintained above 92% (Oxygenation Index OI-18) She was started on inotropes (dobutamine 10 mcg/kg/min) in view of shock. CXR done revealed bilateral ground glass heterogenous opacities with involvement of left lung $>$ right lung. She was managed on pressure-control mode and prone ventilation, monitored with serial blood gases and chest x-ray. Repeat echo cardiogram showed normal left ventricular function with moderate pulmonary hypertension. There was no worsening of hemodynamics and inotropes were weaned by 72 h. In view of severe pneumonia with acute respiratory distress syndrome (ARDS) ground glass opacities in chest x-ray and need for invasive respiratory support, dexamethasone was started at a dose of

0.15 mg/kg/day for a period of 2 weeks and later tapered and stopped. Inflammatory parameters were serially monitored were always in the acceptable range with marginal elevation of pro BNP and negative troponin I. Fig. 1 shows the clinical time line graph.

By the end of 2 weeks of ventilation, despite steroids, there was difficulty in weaning from ventilatory support and she continued to require invasive ventilation however trend of oxygenation index improved (fiO_2 -40%, MAP -8,0I-8). There were no associated systemic setbacks or cutaneous manifestations during the two weeks and neonate was on full enteral nutrition In view of persisting pneumonia $>$ 2 weeks (day 21 of illness), inability to wean from invasive ventilation, septic screen, ECHO and inflammatory markers were repeated. There was significant thrombocytosis and lymphocytic predominance leucocytosis. Blood culture was sterile. Repeat nasopharyngeal COVID RT PCR remained positive (at day 21 of illness) and Covid Ig G And Ig M Antibodies were positive. CT scan of the lungs could not be performed due to logistic constraints. In view of persistence ground glass opacities and thrombocytosis possibility of persisting inflammation and micro thrombosis were considered. Repeat ECHO revealed normal coronaries, moderate pulmonary

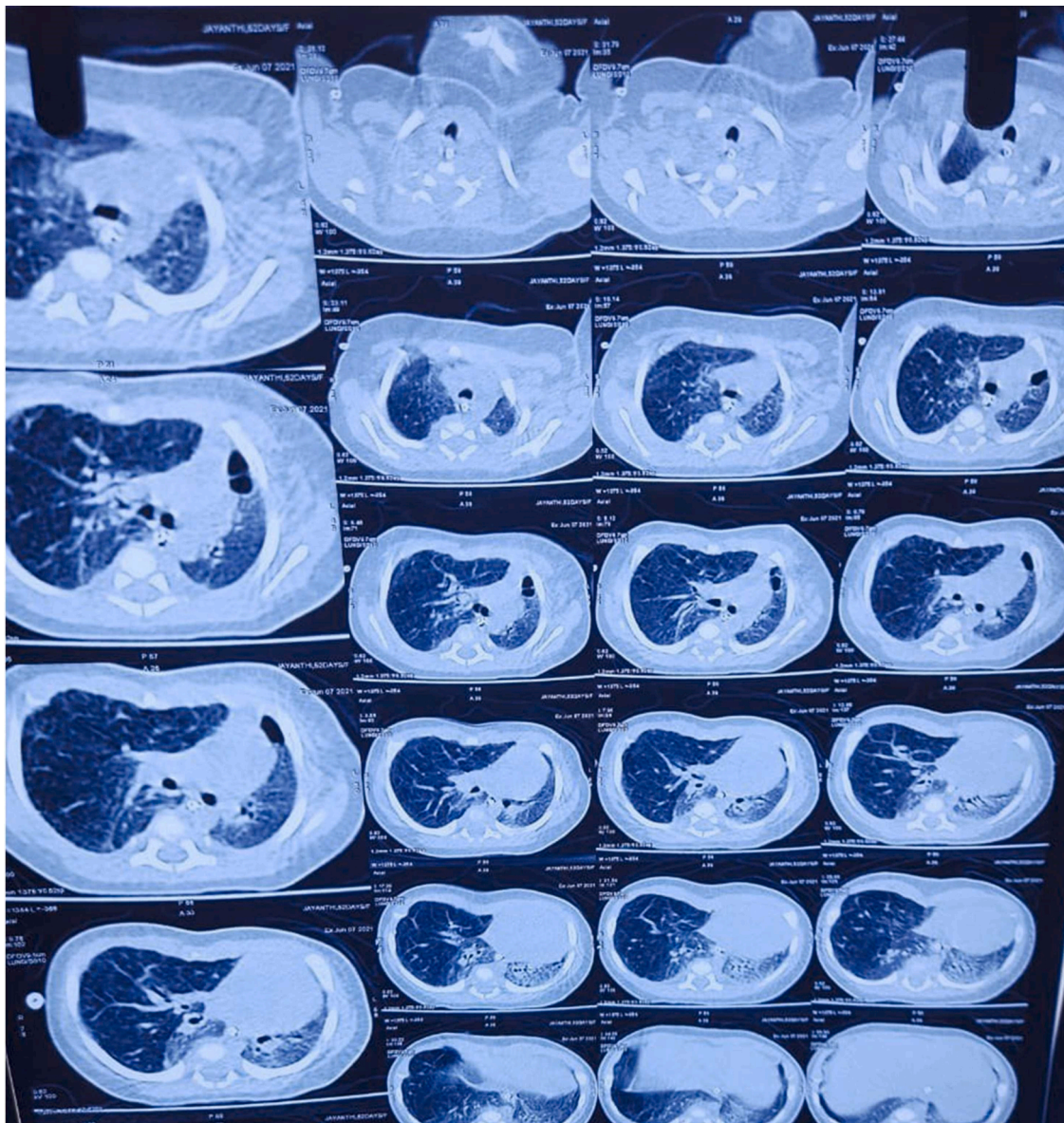


Fig. 2. HRCT lung showing faint ground glass opacities with volume reduction, noted in both lower lung lobes and cystic changes in the left upper lobe, consistent with resolving COVID 19 pneumonia with fibrosis. Compensatory emphysematous changes in the right lung upper lobe with transmediastinal herniation.

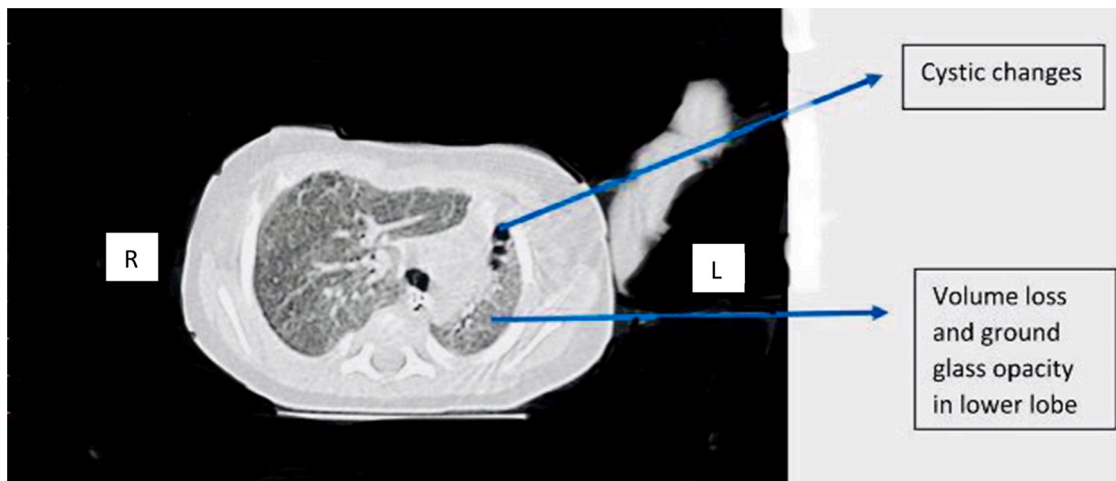


Fig. 2. (continued)

hypertension and good LV function. ECG was normal. Repeat d dimer was normal and pro BNP was elevated. In view clinical timeline of the illness (3rd week post covid) with positive antibody titers, un-resolving ground glass opacities, pulmonary hypertension, thrombocytosis and elevated pro BNP, she was treated with IVIG (1 gm/kg) over a period of 12 h by day 21 of illness. Thereafter in the next 48 hours, oxygenation improved ($O_1 < 5$) she was weaned to pressure support ventilation and was extubated to NIPPV by day 27 of illness. However she developed stridor and was reintubated in the next 24 h. She underwent airway evaluation which revealed mild laryngomalacia and BAL culture was sterile. After 72 h, (day 35 of illness) she was successfully extubated to NIPPV and there after to CPAP after 7 days (day 42 of illness). HRCT chest done (day 48 of illness) (Fig. 2) revealed faint ground glass opacities with volume reduction noted in both lung lower lobe and cystic changes in the left upper lobe consistent with resolving COVID 19 pneumonia with fibrosis. Compensatory emphysematous changes in the right lung upper lobe with trans mediastinal herniation was also noted. She was finally weaned off CPAP by 7 weeks of hospital stay (day 50 of illness) to room air.

After obtaining a pulmonologist opinion, inhaled budesonide, immunomodulators (Azithromycin), ecosporin and anti reflux medications were initiated. She was found to have bilateral Zone 2 stage III plus retinopathy of prematurity with plus disease on eye screening at 42 weeks of post menstrual age (day 42 of illness). Urgent laser photocoagulation was done followed by intravitreal ranibizumab injection in both the eyes. Further screening (after one week) showed regression of ROP and need for close follow up was advised. Post extubation she was noted to have encephalopathy with mild stupor and had one episode of generalized seizures which settled with anti epileptic therapy (levetiracetam). There was generalized hypotonia with differential lower limb tone lesser than upper limb. Reflexes were just elicitable. Head circumference was on the 50th centile as per Fenton's growth chart. CSF analysis done was normal. CPK was done and was normal. Expert neurologist opinion was obtained and the possibility of post covid related encephalitis was considered. MRI brain done (42 days of illness, PMA 42 weeks) (Fig. 3) was suggestive of subcortical volume loss (right occipital and left parieto occipital) with cystic changes, tiny hemorrhages at the caudothalamic groove with loss of myelination at the posterior limb of internal capsule. The changes possibly related to post infectious, encephalitis sequelae. Video EEG done was normal.

Gradually encephalopathy and tone improved and there were no further seizures by 8 weeks of illness. In view of hypotonia, seizures and MRI findings, she was discharged on Levetiracetam. She was also started on gentle physiotherapy and early stimulation. At discharge, she had effortless tachypnoea without hypoxia with features of flattening of left chest wall. She was active with appropriate response to sound and light. There were no abnormal movements. There was hypotonia of lower limbs (adductor angle 160 deg at 44 weeks PMA) in comparison to upper limbs (scarf sign bilateral at ipsilateral nipple line at 44 weeks PMA). Axial tone was normal. The neonate was discharged on nasogastric tube feeds to avoid feeding difficulties. Parents were counseled advised about long term multidisciplinary follow up plan.

Discussion

Perinatal and transplacental covid 19 infection in neonate is a known entity [9]. Most Covid 19 infection and exposure in neonates range from asymptomatic infection to mild respiratory distress. Transplacental infection is characterized by more severe disease in neonates [10]. The pathognomonic inflammatory cascade mediated disease spectrum ranging from severe pneumonia to multisystem inflammatory syndrome though reported is rare in neonates [11]. There is very little literature on post covid lung fibrosis, thromboembolism and encephalitis in neonates and children [12].

We report this rare case presentation in the neonate with possible perinatal transmission of covid 19 infection in the late third trimester with severe pneumonia leading to sequel of pulmonary fibrosis [13], demyelination and hypotonia at 6 weeks following acquisition of infection [14,15]. The neonate responded to immunomodulatory medications intravenous dexamethasone and immunoglobulin therapy in the acute phase of the illness between 1 to 3 weeks. In the recovery phase the post infectious inflammation leading to reactive airway disease was treated with nebulized steroids, ecosporin, azithromycin and anti reflux medications. Although the neonate had no neurological manifestations through the first three weeks of illness and post extubation at 35 days of illness, she was noted to have generalized hypotonia with predominant lower limb hypotonia and MRI brain was consistent with findings encephalitis. Through the recovery phase by 7 weeks hypotonia improved. Post covid demyelination has been reported in pediatric and adult population, however is rare in neonates.

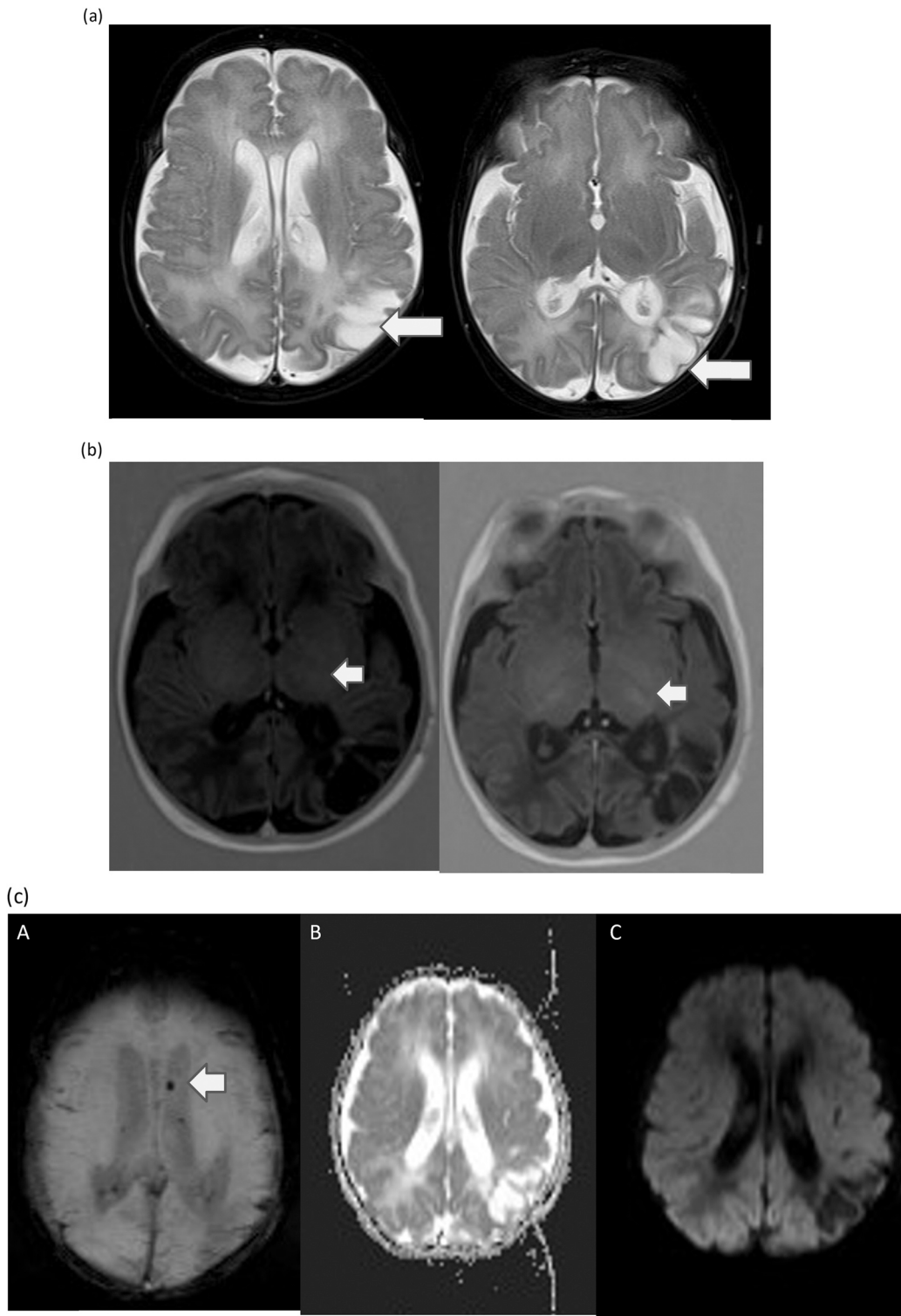


Fig. 3. (a) T2 WI showing cystic changes in the left parietal region (white arrow) (b) T1 WI showing lack of myelination in the posterior limb of internal capsule (white arrow) (c) (A)SWI:showing subependymal microbleeds (arrows) (B) DWI and ADC images showing no restricted diffusion.

There is no standard pharmacotherapy recommendations for neurological manifestations and has been reported as self limiting with good prognosis in pediatric population. However some literature do report the use of steroids and IVIG for the same [16,17]. These neonates would require long term neurodevelopmental followup till 2 years of age for improvised quality of life [18]. Retinopathy of prematurity was the major dreaded morbidity in this neonate as

diagnosed at 25 days of post natal life at post menstrual age of 40 weeks. This was a classical retinopathy probably due severe illness in the neonate and stormy course in the first three weeks. The neonate had bilatereal stage 3 ROP and was treated with And laser photocoagulation [19].The neonate never had cutaneous manifestations, myocardial involvement or MISC. The inflammatory mediators were marginally elevated and CRP remained negative even in the acute

phase of illness. We understand that fetal exposure and perinatal transmission of covid 19 infection has a more stormy inflammatory cascade leading to multi system morbidities in neonates [20]. A better understanding of transplacental transmission with its varied spectrum of illness in neonate will help in better preparedness to focused care in this high risk population [21]. This also high lights the significance of maternal vaccination for prevention of these complications and long term sequelae [22].

Consent

Written informed consent was obtained from the patient for publication of this case report and accompanying images.

Ethical approval

A single patient report. Patient has given verbal and written consents for publication of this case.Consent.

Funding

None.

Authors contribution

Vaanathi H.K. drafted the first manuscript; Chandrakumar N. helped in finalizing the manuscript; Madabhushi assisted in collection of data and contributed to the manuscript; Shivabalan S. , Gopinath C. , Dhanalakshmi D., Shyam, Ahalya, Maria, Jean, contributed to collection of data and critically reviewed the manuscript. All authors approved the final manuscript as submitted.

Conflict of interest

None.

References

- [1] Liguoro I, Pilotto C, Bonanni M, Ferrari ME, Pusiol A, Nocerino A, et al. SARS-CoV-2 infection in children and newborns: a systematic review. *Eur J Pediatr* 2020;179(7):1029–46.
- [2] NATIONAL NEONATOLOGY FORUM (NNF) COVID REGISTRY GROUP. Outcomes of neonates born to mothers with Coronavirus disease 2019 (COVID-19)- NNF COVID19 Registry.
- [3] Ramcharan T, Nolan O, Lai CY, Prabhu N, Krishnamurthy R, Richter AG, et al. Paediatric inflammatory multisystem syndrome: temporally associated with SARS-CoV-2 (PIMS-TS): cardiac features, management and short-term outcomes at a UK tertiary paediatric hospital. *Pediatr Cardiol* 2020;41(7):1391–401.
- [4] Kappanayil M, Balan S, Alawani S, Mohanty S, Leeladharan SP, Gangadharan S, et al. Multisystem inflammatory syndrome in a neonate, temporally associated with prenatal exposure to SARS-CoV-2: a case report. *Lancet Child Adolesc Health* 2021;5(4):304–8.
- [5] Zhou S, Wang Y, Zhu T, Xia L. CT features of coronavirus disease 2019 (COVID-19) pneumonia in 62 patients in Wuhan, China. *Am J Roentgenol* 2020;214(6):1287–94.
- [6] Laura Fabbri SM, Khan F, Chi W. Post-viral parenchymal lung disease of COVID-19 and viral pneumonitis: a systematic review and meta-analysis. *medRxiv* 2021. <https://doi.org/10.1101/2021.03.15.21253593>
- [7] Gray DM, Davies M-A, Githinji L, Levin M, Mapani M, Nowalaza Z, et al. COVID-19 and pediatric lung disease: a South African tertiary center experience. *Front. Pediatr.* 2021;8:614076.
- [8] Zhang C, Huang L, Tang X, Zhang Y, Zhou X. Pulmonary sequelae of pediatric patients after discharge for COVID-19: an observational study. *Pediatr Pulmonol* 2021;56(5):1266–9.
- [9] Yee J, Kim W, Han JM, Yoon HY, Lee N, Lee KE, et al. Clinical manifestations and perinatal outcomes of pregnant women with COVID-19: a systematic review and meta-analysis. *Sci Rep* 2020;10(1):18126. Published 2020 Oct 22.
- [10] Vivanti AJ, Vauloup-Fellous C, Prevot S, Zupan V, Suffee C, Do Cao J, et al. Transplacental transmission of SARS-CoV-2 infection. *Nat Commun* 2020;11:3572.
- [11] Sankaran D, Nakra N, Cheema R, Blumberg D, Lakshminrusimha S. Perinatal SARS-CoV-2 infection and neonatal COVID-19: a 2021 update. *Neoreviews* 2021;22(5):e284–95.
- [12] Stafstrom CE, Jantzie LL. COVID-19: neurological considerations in neonates and children. *Children* 2020;7:133.
- [13] Zhang C, Huang L, Tang X, Zhang Y, Zhou X. Pulmonary sequelae of pediatric patients after discharge for COVID-19: an observational study. *Pediatric Pulmonology* 2021;56:1266–9.
- [14] LaRovere KL, Riggs BJ, Poussaint TY, Young CC, Newhams MM, Maamari M, et al. Neurologic involvement in children and adolescents hospitalized in the United States for COVID-19 or multisystem inflammatory syndrome. *JAMA Neurol* 2021;78(5):536–47.
- [15] Gray DM, Davies MA, Githinji L, Levin M, Mapani M, Nowalaza Z, et al. COVID-19 and pediatric lung disease: a South African tertiary center experience. *Front Pediatr* 2021;8:614076.
- [16] Gharebaghi N, Nejadrahim R, Mousavi SJ, Sadat-Ebrahimi SR, Hajizadeh R. The use of intravenous immunoglobulin gamma for the treatment of severe coronavirus disease 2019: a randomized placebo-controlled double-blind clinical trial [published correction appears in *BMC Infect Dis.* 2020 Nov 26;20(1):895]. *BMC Infect Dis.* 2020;20(1):786. Published 2020 Oct 21.
- [17] Tzilas V, Manali E, Papiris S, Bouros D. Intravenous immunoglobulin for the treatment of COVID-19: a promising tool. *Respiration.* 2020;99(12):1087–9.
- [18] Wigén J, Löfdahl A, Bjermer L, Elowsson-Rendin L, Westergren-Thorsson G. Converging pathways in pulmonary fibrosis and Covid-19 – the fibrotic link to disease severity. *Respir Med X.* 2020;2:100023.
- [19] More K, Chawla D, Murki S, Tandur B, Deorari AK, Kumar P. National neonatology forum (NNF) COVID-19 registry group. outcomes of neonates born to mothers with coronavirus disease 2019 (COVID-19) – national neonatology forum (NNF) India COVID-19 registry. *Indian Pediatr* 2021;58(6):525–31.
- [20] Chen Y, Peng H, Wang L, Zhao Y, Zeng L, Gao H, et al. Infants born to mothers with a new coronavirus (COVID-19). *Front Pediatr.* 2020;8:104.
- [21] Saadaoui M, Kumar M, Al Khodor S. COVID-19 infection during pregnancy: risk of vertical transmission, fetal, and neonatal outcomes. *J Pers Med* 2021;11(6):483.
- [22] Guidelines on Operationalization of COVID Care Services for Children & Adolescents. Government of India Ministry of Health and Family Welfare June, 2021. Available from URL: <https://www.mohfw.gov.in/pdf/GuidelinesonOperationalizationofCoVIDCareServicesforChildrenandAdolescents14062021.pdf> Accessed July 18th, 2021.