



2021

An unusual intracoronary honeycomb pattern in a patient with coronary artery disease with dextrocardia

Follow this and additional works at: <https://www.j-saudi-heart.com/jsha>



Part of the [Cardiology Commons](#)



This work is licensed under a [Creative Commons Attribution-Noncommercial-No Derivative Works 4.0 License](#).

Recommended Citation

Singh, Ajay Pratap Dr; Raj, Ajay; Chaudhary, Kaushal; and Nath, Ranjit K. (2021) "An unusual intracoronary honeycomb pattern in a patient with coronary artery disease with dextrocardia," *Journal of the Saudi Heart Association*: Vol. 33 : Iss. 2 , Article 12.

Available at: <https://doi.org/10.37616/2212-5043.1254>

This Case Report is brought to you for free and open access by Journal of the Saudi Heart Association. It has been accepted for inclusion in Journal of the Saudi Heart Association by an authorized editor of Journal of the Saudi Heart Association.

An Unusual Intracoronary Honeycomb Pattern in a Patient with Coronary Artery Disease with Dextrocardia

Ajay P. Singh*, Ajay Raj, Kaushal Chaudhary, Ranjit K. Nath

Department of Cardiology, Atal Bihari Vajpayee Institute of Medical Sciences and Dr. Ram Manohar Lohia Hospital, New Delhi, India

Abstract

This case highlights the diagnostic dilemma and emphasizes the role of Optical Coherence Tomography (OCT) to differentiate between spontaneous coronary artery dissection and recanalized thrombus with multiple channels in a patient with dextrocardia.

Keywords: Dextrocardia, OCT, Honeycomb, Thrombus

1. History of presentation

A 48-year-old male presented to the emergency department with a history of exertional chest pain and dyspnea (NYHA class II) since last 02 months. His blood pressure was 124/70 mm Hg and his heart rate of 82 beats/min/regular. His other physical examination findings were unremarkable.

2. Past medical history

He was a current smoker and there was no history of other stimulant abuse. There was no history of febrile illness. There was no significant history of any medical condition or heart disease.

Differential diagnosis: coronary artery disease with left ventricular dysfunction, dilated cardiomyopathy, hypertrophic cardiomyopathy.

3. Investigations

Urgent laboratory examinations revealed a Troponin I level of 118.6 pg/ml (normal range: ≤ 15.6 pg/ml) and a brain natriuretic peptide level

of 106 pg/ml (normal range: ≤ 18.4 pg/ml). ECG revealed a right axis deviation, with a positive QRS complex in lead aVR suggestive of dextrocardia (Fig. 1A). Chest X-ray subsequently confirmed dextrocardia with situs inversus (Fig. 1B). Echocardiography revealed situs inversus (Fig. 1C), dextrocardia with hypokinesia of the apical, anterior, and anterolateral segments. The left ventricular ejection fraction was 52% using the Simpson method [1]. There was no pericardial effusion, intracardiac thrombi, or thrombi in main or branch pulmonary arteries. Coronary angiography revealed a linear radiolucent defect in the proximal to mid-segment of the left anterior descending artery (LAD) (Fig. 2. A & B). Based on the angiographic profile, differential diagnosis of spontaneous coronary artery dissection or recanalized thrombus was considered, and for further evaluation, OCT was performed using Dragonfly OPTIS catheter (Abbot-USA) which confirmed significant stenotic lesion with plaque rupture and extensive left anterior descending artery thrombosis with multiple channels showing the characteristic and very unusual honeycomb-like structure (Fig. 3).

Received 23 May 2021; revised 25 May 2021; accepted 26 May 2021.
Available online 7 July 2021.

* Corresponding author at.
E-mail address: ajayaps04@gmail.com (A.P. Singh).



4. Management

Based on findings of OCT imaging, it was decided to perform PCI and as the patient was having dextrocardia, horizontal axis mirror-image inversion angiographic mode was used to facilitate PCI (Fig. 2C). Using a coronary microcatheter and a hydrophilic guidewire [Fielder XT (Asahi Intec Co)], the diseased LAD was crossed across the true lumen of the vessel. OCT was done for confirmation of the true lumen and the lesion was pre-dilated and subsequently stented using a Sirolimus-eluting stent (3.5 × 48 mm) and was post-dilated to achieve a satisfactory OCT parameter and with no stent edge dissection (Fig. 4). The patient was discharged on day 2 of revascularization on optimum guideline-directed medical therapy.

5. Discussion

Patients with dextrocardia have the same incidence of coronary artery disease as the general population [2]. PCI in dextrocardia is challenging due to the unfamiliarity of angiographic views and intrinsic risk of associated cardiac anomalies. Using the horizontal axis mirror-image inversion angiographic technique, one can easily reproduce standard angiographic views with inversion of right anterior oblique and left anterior oblique angulation (RAO/LAO) keeping the cranial/caudal tilts the same [2]. OCT revealed the presence of plaque rupture along with multiple channels with thrombus giving an unusual impression of a

Abbreviations

OCT	Optical coherence tomography
PCI	percutaneous coronary intervention
CAD	coronary artery disease

“honeycomb pattern” [3,4], which was missed and interpreted as spontaneous coronary artery dissection on conventional coronary angiography. In our case, OCT proved to be an essential tool for evaluating the nature of the lesion and deciding the further line of management. Despite Thrombolysis In Myocardial Infarction (TIMI) III flow, honeycomb lesions should be treated with PCI as it has already been shown that such lesion has significant stenosis, identified by coronary flow velocity reserve indexes and myocardial fractional flow reserve [5,6]. It was treated successfully with a sirolimus-eluting stent with satisfactory OCT results.

6. Follow up

The patient was free from any new symptoms at 3 months of follow-up and his current functional status of dyspnea improved to NYHA I (previously NYHA II-III).

7. Conclusion

We report a case of dextrocardia with an intracoronary honeycomb appearance in the LAD due to plaque rupture and recanalization of the thrombus.

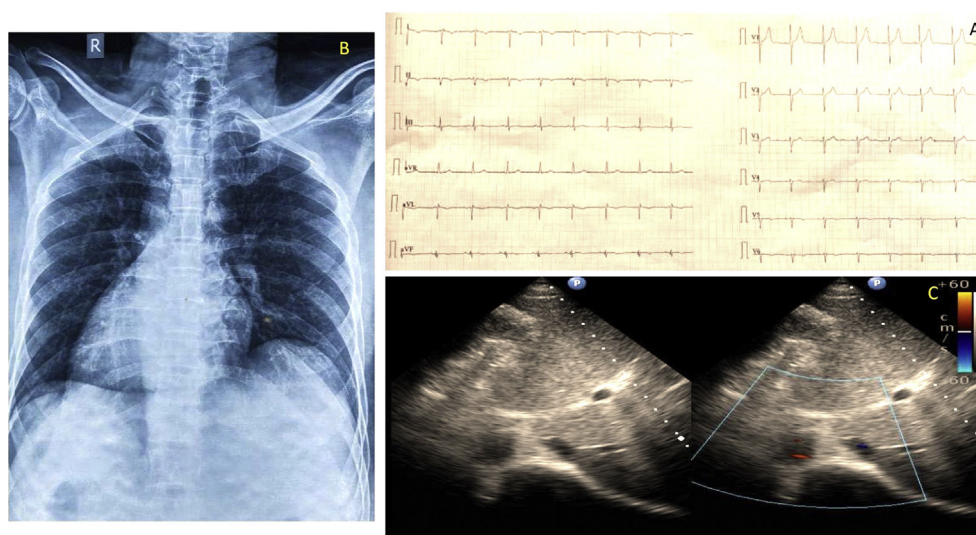


Fig. 1. Electrocardiogram, Chest X-Ray, and Echocardiography. A. Standard 12-lead electrocardiogram showing right axis deviation and positive QRS complexes in lead aVR, inversion of lead I, and absent R-wave progression in the chest leads, suggestive of dextrocardia. B. Chest X-ray (PA view) showing cardiac apex and fundal gas shadow on the right suggestive of dextrocardia with situs inversus. C. 2D-echocardiography subcostal view confirming situs inversus (IVC to the right (blue) and aorta on left (red)).

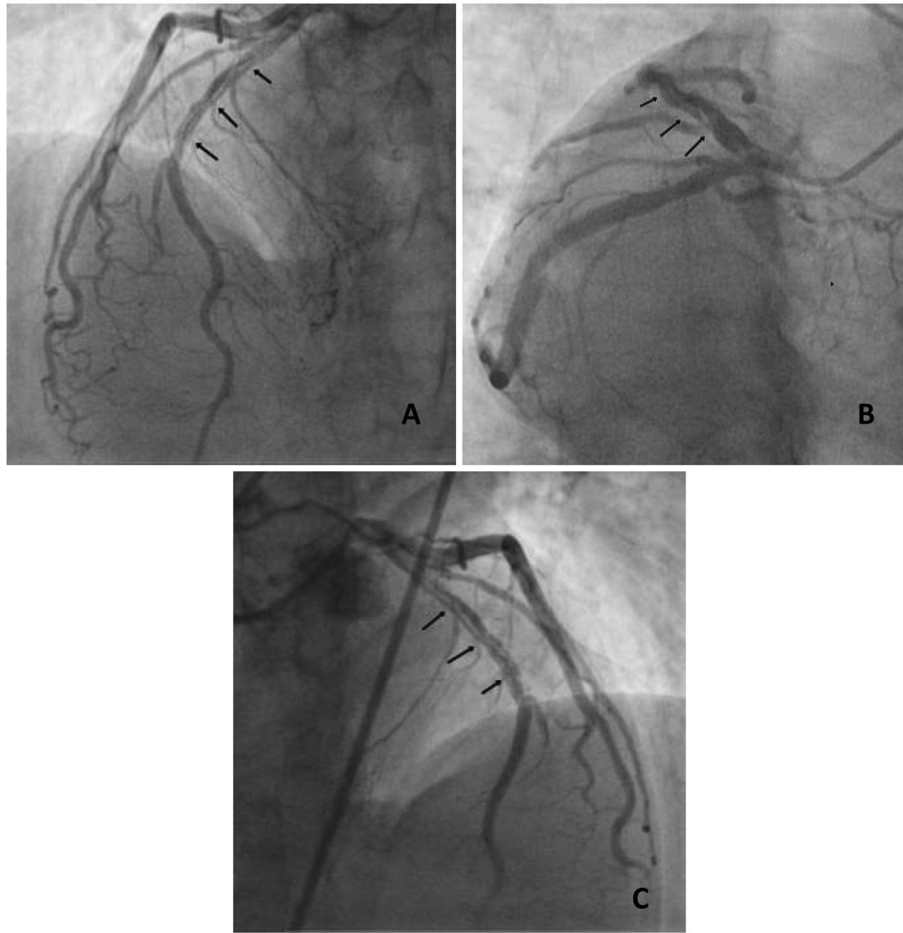


Fig. 2. Coronary angiography, A. P-A cranial angulation & B. RAO caudal angulation showing a linear radiolucent defect in LAD extending from proximal to mid-segment (black arrows). C. RAO cranial angulation after using the horizontal axis inversion angiographic mode.

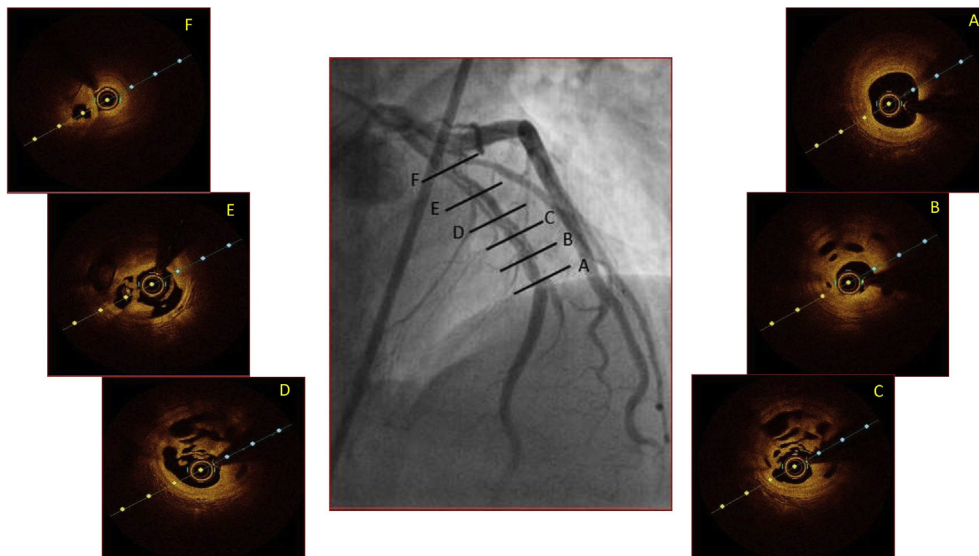


Fig. 3. Optical coherence tomography findings (Short axis). A. Usual atherosclerotic change with a fibrous plaque and significant diametric stenosis (MLA 2.4 mm²), B. Intracoronary "Honeycomb appearance", C & D. Multiple tram track channels with the presence of plaque rupture at 2 'o'clock, E. Extension of the channels with intraluminal thrombus within at 7 and 9 'o'clock, F. Usual atherosclerotic narrowing of the true lumen with false lumen seen at 7 'o'clock.

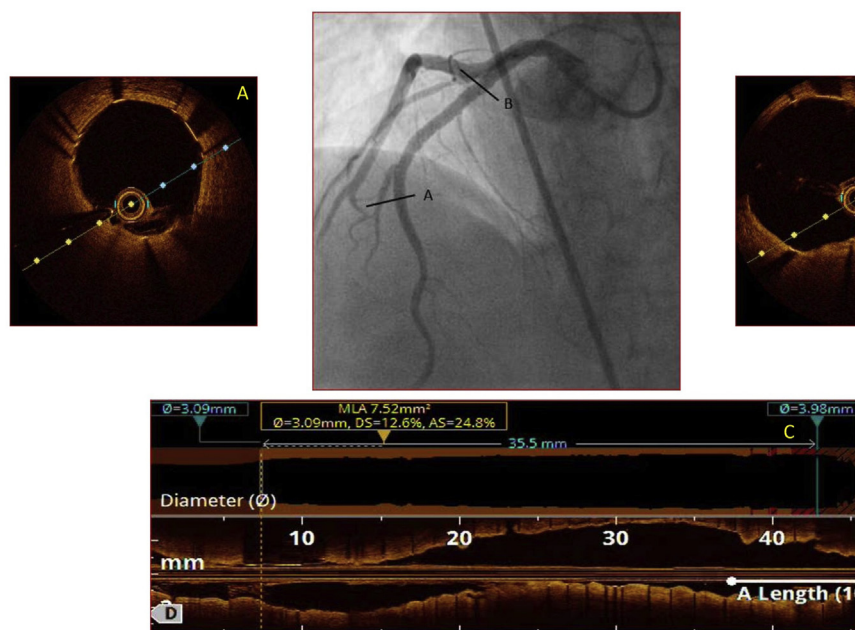


Fig. 4. Optical coherence tomography. Post stenting OCT findings A. Distal edge, B proximal edge, C. Longitudinal section showing satisfactory stent expansion.

Such lesions are significantly stenotic despite the TIMI flow grade in the vessel.

Funding

None.

Author contribution

Conception and design of Study: Ajay P. Singh, Ajay Raj. Literature review: Ajay P. Singh, Ajay Raj. Acquisition of data: Ajay P. Singh, Kaushal Chaudhary. Analysis and interpretation of data: Ajay P. Singh. Research investigation and analysis: Ajay P. Singh, Ajay Raj, Kaushal Chaudhary. Data collection: Ajay P. Singh, Kaushal Chaudhary. Drafting of manuscript: Ajay P. Singh. Revising and editing the manuscript critically for important intellectual contents: Ajay P. Singh, Ranjit K. Nath. Data preparation and presentation: Ranjit K. Nath. Supervision of the research: Ajay Raj, Ranjit K. Nath. Research coordination and management: Ranjit K. Nath. Funding for the research: Ajay P. Singh, Ajay Raj. Conflict of interest

No relationships with industry.

References

[1] Lang RM, Badano LP, Mor-Avi V, Afilalo J, Armstrong A, Ernande L, et al. Recommendations for cardiac chamber quantification by echocardiography in adults: an update from

Learning objective

- Percutaneous coronary intervention in dextrocardia can be done easily with horizontal axis mirror-image inversion angiographic mode, which converts it into conventional levocardia views.
- Intracoronary imaging with OCT helps in differentiating spontaneous dissection with recanalized thrombus, and underlying etiology.
- The presence of intracoronary honeycomb appearance portends significant stenotic lesions despite TIMI flow grade.

the American Society of Echocardiography and the European Association of Cardiovascular Imaging. *J Am Soc Echocardiogr* 2015 Jan;28(1):1–39.e14. <https://doi.org/10.1016/j.echo.2014.10.003>. PMID: 25559473.

- [2] Goel PK, Moorthy N. Trans-radial primary percutaneous coronary intervention in dextrocardia using double inversion technique. *J Cardiol Cases* 2013 Apr 24;8(1):e31–3. <https://doi.org/10.1016/j.jccase.2013.03.010>. PMID: 30546734; PMCID: PMC6281499.
- [3] Musashi M, Tada N, Uemura N, Kawashima O, Ootomo T, Inoue N, et al. Multivessel honeycomb-like structure finding in optical coherence tomography. *JACC Cardiovasc Interv* 2014 Feb;7(2):e7–8. <https://doi.org/10.1016/j.jcin.2013.04.028>. PMID: 24556108.
- [4] Valencia J, Martín-Torres JM, Ruiz-Nodar JM, Lozano T. An intracoronary honeycomb: a case report. *Eur Heart J Case Rep* 2020 Dec 5;4(6):1–2. <https://doi.org/10.1093/ehjcr/ytaa395>. PMID: 33447713; PMCID: PMC7793216.

- [5] Suzuki M, Seki A, Nishikawa K, Takamisawa I, Tobaru T, Sumiyoshi T. Novel physiological insight into a lotus root appearance in stable coronary artery diseases; Report of two cases. *Cardiovasc Interv Ther* 2016 Apr;31(2):128–30. <https://doi.org/10.1007/s12928-015-0325-5>. Epub 2015 Mar 7. PMID: 25749916.
- [6] Xu T, Shrestha R, Pan T, Huang X, Xu H, Zhang JJ, et al. Anatomical features and clinical outcome of a honeycomb-like structure in the coronary artery: reports from 16 consecutive patients. *Coron Artery Dis* 2020 May;31(3):222–9. <https://doi.org/10.1097/MCA.0000000000000822>. PMID: 31658133.