

# Hybrid Percutaneous-Endoscopic Treatment for Acute Calculous Cholecystitis in a High-Risk Surgical Patient

Khalil Aloreidi, MD<sup>1</sup>, Jeremy Berg, MD<sup>2</sup>, Terry Yeager, MD<sup>3</sup>, Muslim Atiq, MD<sup>4</sup>, and Bhavesh Patel, MD<sup>4</sup>

<sup>1</sup>Department of Internal Medicine, Sanford School of Medicine, University of South Dakota, Sioux Falls, SD

<sup>2</sup>Department of Pathology, Sanford School of Medicine, University of South Dakota, Sioux Falls, SD

<sup>3</sup>Department of Radiology, Sanford School of Medicine, University of South Dakota, Sioux Falls, SD

<sup>4</sup>Department of Gastroenterology, Sanford School of Medicine, University of South Dakota, Sioux Falls, SD

## ABSTRACT

Acute cholecystitis (AC) has long been treated with percutaneous cholecystostomy (PC) in patients who are poor surgical candidates, but it is associated with high recurrence rate. We report our experience with a hybrid percutaneous-endoscopic technique in an elderly patient with AC who had received a PC. In this technique, a pediatric endoscope was introduced through the PC opening to the gallbladder, and the stones were visualized, fragmented, and extracted using a retrieval basket. The patient's AC resolved, and within 2 weeks the PC tube was removed. The patient remained asymptomatic at the 6-month and 1-year follow-up visits. We believe that if this method is replicated in large scale, it could be an effective alternative to cholecystectomy in nonsurgical candidates.

## INTRODUCTION

Percutaneous cholecystostomy (PC) has long been used to provide external decompression in patients with acute cholecystitis (AC) in the critical care setting. This approach effectively resolves AC in approximately 90% of patients.<sup>1</sup> However, this approach is rarely a definitive treatment, as there is a high recurrence of calculus cholecystitis and subsequent symptomatic choledocholithiasis.<sup>2</sup> We describe the usage of a hybrid percutaneous-endoscopic technique to manipulate and extract gallstones under direct visualization. We believe that utilization of this technique will increase the likelihood of AC resolution and minimize repeated interventions and complications.

## CASE REPORT

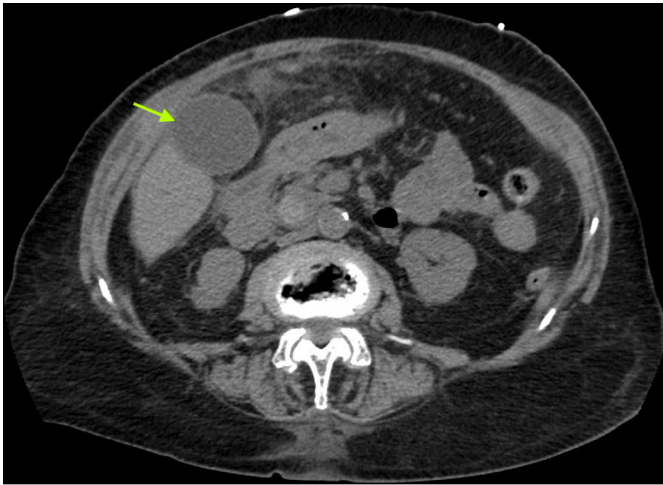
An 86-year-old woman presented to the emergency department with nausea, vomiting, and right upper quadrant abdominal pain without associated fevers or chills. Her past medical history was significant for coronary artery disease, pulmonary hypertension, mitral regurgitation, atrial fibrillation, and chronic kidney disease. Upon examination, she was found to be tachycardic and hypotensive, with right upper quadrant tenderness and a positive Murphy's sign. Laboratory studies showed elevated liver enzymes with alkaline phosphatase 387 U/L, alanine aminotransferase 89 U/L, aspartate aminotransferase 78 U/L, and total bilirubin 5.9 mg/dL, with a direct fraction of 5.2 mg/dL. Creatinine and white blood cell count were elevated, whereas lipase was normal. A right upper quadrant ultrasound showed a distended gallbladder with cholelithiasis, a wall thickness of 3 mm, and a 14-mm dilated common bile duct (CBD). An abdominal computed tomography scan also showed a distended gallbladder with thickened walls and inflammatory changes within the adjacent fat, along with cholelithiasis and a dilated CBD (Figure 1). She was admitted to the intensive care unit with a diagnosis of sepsis secondary to acute cholecystitis, choledocholithiasis, and acute kidney injury.

ACG Case Rep J 2017;4:e89. doi:10.14309/crj.2017.89. Published online: July 19, 2017.

Correspondence: Khalil Aloreidi, Sanford School of Medicine, University of South Dakota, 1400 W 22nd St, Sioux Falls, SD 57105 (khalil.aloreidi@usd.edu).

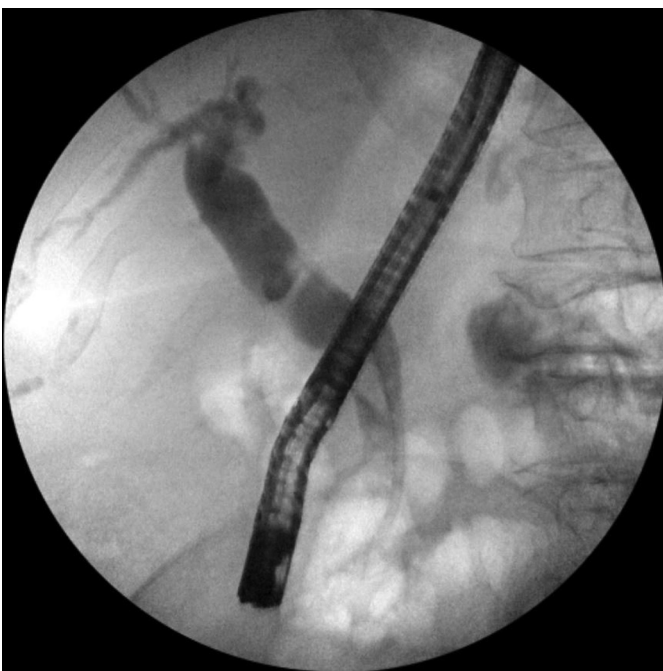


Copyright: © 2017 Aloreidi et al. This work is licensed under a Creative Commons Attribution-NonCommercial-NoDerivatives 4.0 International License. To view a copy of this license, visit <http://creativecommons.org/licenses/by-nc-nd/4.0>.

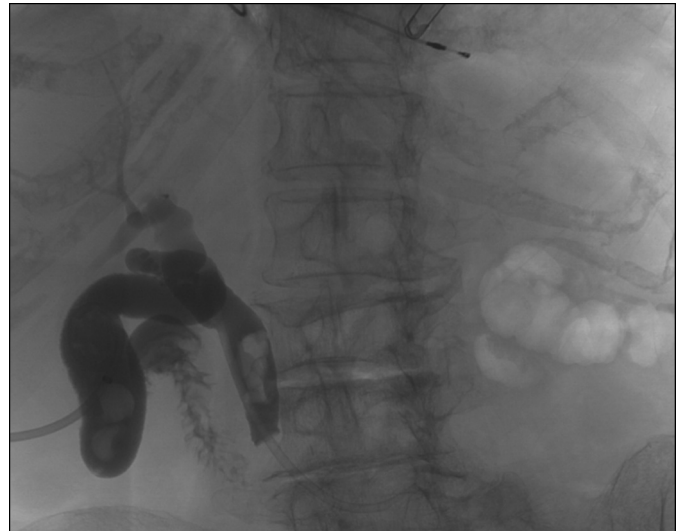


**Figure 1.** CT scan showing distended gallbladder (arrow) and inflammatory changes within the adjacent fat, suggestive of acute cholecystitis.

The patient was started on intravenous hydration and empiric antibiotics, and soon after underwent endoscopic retrograde cholangiopancreatography (ERCP), which showed an obstructed cystic duct and multiple CBD stones (Figure 2). The stones were removed after sphincterotomy and a 10F x 9 cm plastic stent was placed in the CBD due to residual stones. The patient was not considered a surgical candidate for laparoscopic cholecystectomy due to her multiple comorbidities. Four days after ERCP, she underwent ultrasound-guided PC tube placement. The patient's clinical condition improved, and she was discharged home with the PC tube in place. She underwent multiple evaluations and exchanges of the PC



**Figure 2.** ERCP image showing obstructed cystic duct with multiple filling defects in the CBD.

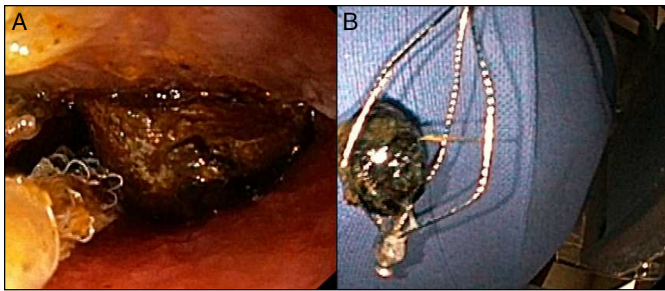


**Figure 3.** Percutaneous cholangiogram showing gallbladder and CBD stones.

tube by interventional radiology, and percutaneous cholangiograms showed a patent cystic duct and occluded biliary stent with some contrast reaching the duodenum (Figure 3). Three months after the initial PC, the patient underwent another ERCP to remove the biliary stent and extract all CBD stones using a cholangioscope (SpyGlass™ DS system, Boston Scientific, Marlborough, MA) and electrohydraulic lithotripsy. The CBD was completely cleared and another 10F X 7 cm plastic stent was placed as the patient was at risk for recurrent choledocholithiasis.

Given the patient's status as a non-surgical candidate, it was decided to remove the residual gallstones by a hybrid percutaneous-endoscopic technique, with the ultimate goal of removing the PC tube and minimizing future interventions. Under sedation and local anesthesia, the cholecystostomy drain opening was dilated, a 28F sheath was placed, and a pediatric gastroscope (Olympus GIF-N180) was advanced through it. The gallbladder was visualized and multiple stones were identified, the largest being 14 mm in diameter. Lithotripsy was successful, and the gallstones were removed using a variety of techniques, including a Roth net and a retrieval basket (Figure 4). After completion of the procedure, the sheath was removed and a 20F drainage catheter was placed.

Two months later, another ERCP was performed. The biliary stent was found to be occluded and was removed. A stone found in the middle third of the CBD was swept out with a 12-mm balloon, and no other stones remained. A week later, a percutaneous cholangiogram showed contrast flow into the duodenum with no significant obstruction (Figure 5). The PC tube was then removed, and the dilated PC site healed with no complications. The patient remained asymptomatic at her 6-month and 1-year follow-up appointments.

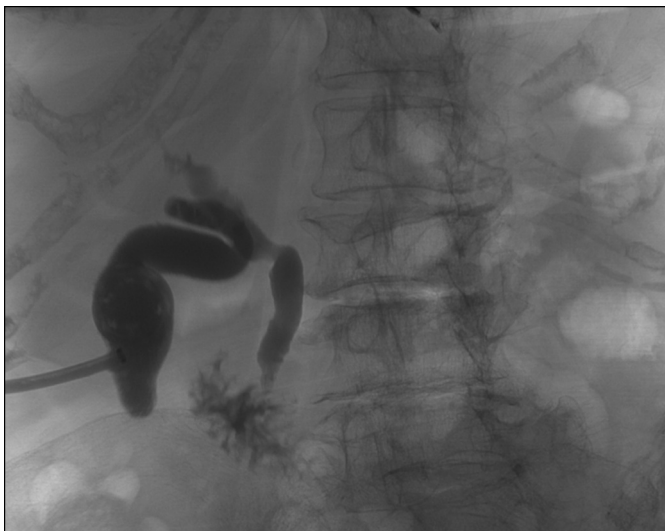


**Figure 4.** (A) Gallstone retrieval under direct visualization using Roth net retriever. (B) One of the extracted gallstones in a retrieval basket.

## DISCUSSION

More than 90% of AC cases are associated with cholelithiasis leading to obstruction of the cystic duct, which in turn leads to gallbladder distention, compromised blood flow and lymphatic drainage, and mucosal ischemia and necrosis.<sup>3</sup> In critically ill patients, AC carries a high mortality rate.<sup>4</sup> Although decompression and drainage of the gallbladder through a PC may be used as a temporary treatment of AC in this population, there is still some debate about the management of the PC tube and the subsequent need for cholecystectomy. PC is usually kept in place for variable length of time, with a median duration of 12 days. However, it is associated with multiple complications. The most frequent is catheter displacement, which occurs in about 30% of the cases. Other complications include bile leak (4%), skin fistula (1.5%), and infection or abscess formation (1%).<sup>5</sup>

With the use of the described hybrid percutaneous-endoscopic approach, gallstones can be fragmented by various devices, such as electrohydraulic lithotripsy and laser, and then removed under direct visualization, which can potentially



**Figure 5.** Percutaneous cholangiogram following the procedure showing contrast flow into the duodenum with no significant obstruction.

lead to the resolution of AC and allow for the eventual removal of the PC tube.<sup>6,7</sup> The major advantage of this technique is that it can be performed under local anesthesia, which is a valuable alternative when considering high surgical risk and critically ill patients. It would also decrease the need for repeated cholecystostomy drain changes, which are needed in 19% of cases treated with other techniques.<sup>5</sup>

Compared to fluoroscopy-guided percutaneous gallstone removal, which can be done through a smaller diameter PC, the percutaneous-endoscopic approach has certain limitations. It takes a relatively long time for a tract to mature enough for gallstone removal, and it requires substantial tract dilatation to allow the introduction of the endoscopic instrument, which is usually painful.<sup>8,9</sup> The use of the newer Spyglass™ DS system (3.3 mm outer diameter), however, allows good visualization and treatment of gallstones with minimal dilation of the cholecystostomy opening compared to a pediatric gastroscope (5.9 mm outer diameter). Other complications include bleeding as a result of damaged intrahepatic arterial branches during tract dilation and stone extraction, intraperitoneal bile leakage, PC tube displacement, wound infection, and cholangitis.<sup>10</sup> In addition, as the gallbladder is still present, gallstone recurrence is a possibility, with a cumulative recurrence rate up to 44% after 4 years.<sup>11</sup> However, as the target population has multiple significant medical comorbidities, the long-term risk of recurrent gallstones may not be a major clinical concern.

We believe that if this hybrid percutaneous-endoscopic technique were replicated on a larger scale, it could prove to be a less invasive, safe, and effective alternative to cholecystectomy for patients with symptomatic cholelithiasis who are poor surgical candidates. With the use of a small flexible endoscope and advances in lithotripsy equipment, complete gallstone clearance could be achieved. This could, in turn, lead to AC resolution, PC tube removal, and an improved quality of life.

## DISCLOSURES

Author contributions: K. Aloreidi wrote the manuscript. J. Berg, T. Yeager, M. Atiq, B. Patel wrote and revised the manuscript. B. Patel is the article guarantor.

Financial disclosure: None to report.

Informed consent was obtained for this manuscript.

Received January 31, 2017; Accepted June 12, 2017

## REFERENCES

1. Simorov A, Ranade A, Parcels J, et al. Emergent cholecystostomy is superior to open cholecystectomy in extremely ill patients with acalculous cholecystitis: A large multicenter outcome study. *Am J Surg.* 2013;206(6):935-40.

2. Morse BC, Smith JB, Lawdahl RB, Roettger RH. Management of acute cholecystitis in critically ill patients: Contemporary role for cholecystostomy and subsequent cholecystectomy. *Am Surg*. 2010;76(7):708-12.
3. Strasberg SM. Clinical practice. Acute calculous cholecystitis. *N Engl J Med*. 2008;358(26):2804-11.
4. Papadakis M, Ambe PC, Zirngibl H. Critically ill patients with acute cholecystitis are at increased risk for extensive gallbladder inflammation. *World J Emerg Surg*. 2015;10:59.
5. Horn T, Christensen SD, Kirkegård J, Larsen LP, Knudsen AR, Mortensen FV. Percutaneous cholecystostomy is an effective treatment option for acute calculous cholecystitis: A 10-year experience. *HPB (Oxford)*. 2015;17(4):326-31.
6. Hwang MH, Mo LR, Chen GD, Yang JC, Lin CS, Yueh SK. Percutaneous transhepatic cholecystic ultrasonic lithotripsy. *Gastrointest Endosc*. 1987;33(4):301-3.
7. El Ghany ABA, Holley MP, Cuschieri A. Percutaneous stone clearance of the gallbladder through an access cholecystostomy. *Surg Endosc*. 1989;3(3):126-30.
8. Kim YH, Kim YJ, Shin TB. Fluoroscopy-guided percutaneous gallstone removal using a 12-Fr sheath in high-risk surgical patients with acute cholecystitis. *Korean J Radiol*. 2011;12(2):210-5.
9. Al Nammi A, Cheema A, Al Nammi M, Chaudhry I. Percutaneous removal of gallstones under fluoroscopy guidance in high-risk patients with acute cholecystitis. *Arab J Intervent Radiol*. 2017;1(1):30-2.
10. Wong SK, Yu SC, Lam YH, Chung SS. Percutaneous cholecystostomy and endoscopic cholecystolithotripsy in the management of acute cholecystitis. *Surg Endosc*. 1999;13(1):48-52.
11. Donald JJ, Cheslyn-Curtis S, Gillams AR, Russell RC, Lees WR. Percutaneous cholecystolithotomy: Is gall stone recurrence inevitable? *Gut*. 1994;35(5):692-5.