

# Gallstone Ileus, Bouveret's Syndrome and Choledocholithiasis in a Patient with Billroth II Gastrectomy – A Case Report of Combined Endoscopic and Surgical Therapy

R. Fejes G. Kurucsai A. Székely F. Luka Á. Altorjay  
L. Madácsy

1st Department of Gastroenterology, Szent György Hospital, Székesfehérvár,  
Hungary

## Key Words

Gallstone disease · Gallstone ileus · Bouveret's syndrome · ERCP · Billroth II gastrectomy · Mechanical lithotripsy

## Abstract

Intestinal obstruction due to gallstone is a rare, but quite severe gastrointestinal disorder, which always requires a rapid and correct diagnosis to achieve optimal therapy. Digestive endoscopy is an important method to determine the level of the bowel obstruction and to plan an optimal therapeutic strategy. Our present case demonstrates that in a high-risk patient, a combined endoscopic and surgical therapy is the best choice to solve the obstruction of the colon, of the stomach and of the common bile duct caused by multiple gallstones.

## Introduction

Gallstone ileus is an important, though infrequent cause of mechanical bowel obstruction, which is caused by an impacted large gallstone, predominantly in the terminal ileum [1]. The gallstone must be at least 2.5 cm in diameter to cause obstruction. The source can be the gallbladder or the common bile duct after being passed through a biliary-enteric fistula. Approximately 1–4% of all mechanical intestinal obstructions are

caused by gallstones. Elderly patients over the age of 65 years who often have other significant comorbidities are mainly predisposed to this condition [2]. While mortality has declined over recent years, it remains as high as 15–18%, probably due to the late and difficult diagnosis [3, 4]. Digestive endoscopy is an important method to localize the level of obstruction and is helpful to plan an optimal therapeutic strategy. The classic X-ray signs are intestinal obstruction, pneumobilia and aberrantly located gallstones. In general, emergency surgery is the treatment of choice, although effective endoscopic therapeutic approaches are also possible, such as retrieving the gallstone by foreign body forceps to eliminate the bowel obstruction [5].

### Case Report

A 76-year-old man was admitted to our hospital with symptoms of diffuse abdominal pain, vomiting, and progressive abdominal distension started one day earlier. In his past medical history several comorbidities were mentioned, such as hypertension, chronic obstructive pulmonary disease, percutaneous transluminal coronary angioplasty for coronary artery stenosis and medical treatment for internal and external carotid artery and iliofemoro-popliteal arterial stenosis. He had undergone a Billroth type II gastrectomy due to a peptic ulcer of the stomach 52 years ago. At the time of admittance, the patient presented with symptoms and signs of mechanical large bowel obstruction. On physical examination we found a distended, painful abdomen, and metallic and rare bowel sounds. Laboratory examination depicted elevated inflammatory parameters (WBC  $11.57 \times 10^9/l$ , CRP 69.8 mg/l) and a moderately increased gamma-GT level (105 U/l). Plain abdominal X-ray demonstrated dilated small and large bowel loops with characteristic air-fluid levels, but the left-sided colon was preserved. Abdominal ultrasound revealed a gallbladder with known stones without air and dilatation of the intrahepatic bile ducts. In consideration of the high surgical risk of our patient, the surgeon consultant suggested to perform further preoperative diagnostic tests such as colonoscopy to clarify the level and cause of obstruction. After adequate volume and electrolyte supplementation and preparation, we performed an emergency colonoscopy on the next day. During the colonoscopy, in the ascending colon an impacted hard gallstone with a dimension of  $2 \times 3$  cm was detected as a cause of the large bowel obstruction (fig. 1). After unsuccessful attempts with a polypectomy snare, the stone was finally captured with a Dormia basket and then successfully extracted from the colon through the anus. After our endoscopic intervention the symptoms of mechanical large bowel obstruction (ileus) were resolved, but the patient remained symptomatic with recurrent vomiting and upper abdominal pain. To reveal the origin of these symptoms, an upper endoscopy was performed that located another large gallstone with a 3-cm diameter in the resected stomach. This stone was too large to be retrieved through the cardia, therefore an ERCP mechanical lithotripter was applied for fragmentation, and only after lithotripsy did it become possible to completely remove it with a Dormia basket (fig. 2).

On the following day an ERCP was scheduled, but we again found a new gallstone in the stomach, which was again extracted after fragmentation with the same endoscopic method (lithotripsy, then Dormia basket) with a jumbo duodenoscope (fig. 3). Then we proceeded to perform the ERCP after localization of the Vater papilla in the afferent loop. After cannulation with a papillotome, the dilated common bile duct was filled with contrast, and a 10-mm diameter common bile duct stone was diagnosed. The gallbladder which was full of large stones was also filled, together with a cholecystoduodenal fistulous tract at the end of the afferent loop. After precut papillotomy with a needle knife, a guidewire and a 7F small stent were inserted, and a complete biliary sphincterotomy was achieved with the needle knife. Then the common bile duct stone was also successfully removed with a Dormia basket and the stone-free bile ducts were verified with balloon maneuver (fig. 4). Finally, with a gastroscope, we were able to observe a widely opened cholecystoduodenal fistula, close to the blind end of the afferent loop, and even the remaining stones in the fistulous tract were visualized, but they were too large to be extracted endoscopically (fig. 5). Although we solved the mechanical bowel obstruction and achieved a stone-free bile duct and gastrointestinal status, due to the potentially high risk of further stone passage through the widely opened cholecystoduodenal fistula, a surgery was performed in the next week. The surgical solution was made with a cholecystectomy and the reconstruction of the duodenal wall in the afferent loop. No postoperative complication occurred, and the patient was sent home 10 days after the successful operation.

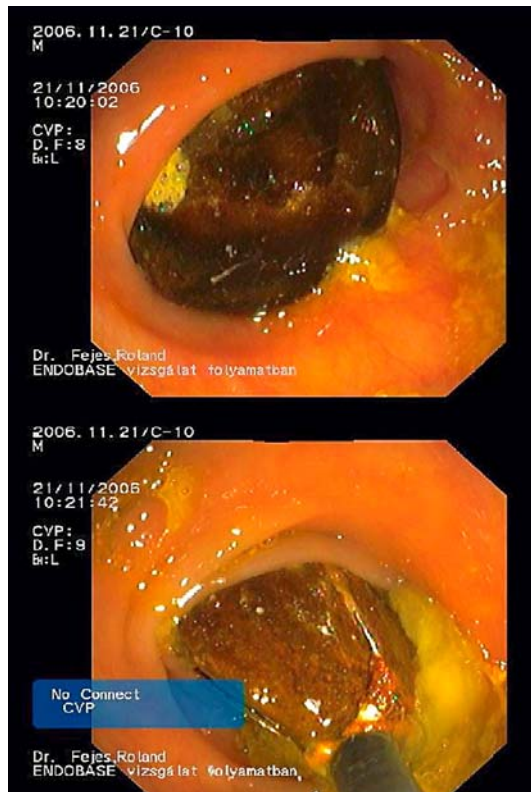
## Discussion

Gallstone ileus is an unusual cause of gastrointestinal tract obstruction, affecting mainly elderly patients with significant comorbidity. The site of stone impaction is predominantly the small bowel, or at the ileocecal valve, and only in 4% of cases the stone was impacted in the colon [6]. In our case, the impacted stone was found at the ascending colon, as it passed through the ileocecal valve and then stopped at the hepatic flexure of the colon. Passage of the ileocecal valve may permit a spontaneous ‘per vias naturales’-emptying a few days later, but in the presented patient the resolution of the gallstone ileus occurred after colonoscopic removal. Gastric outlet obstruction caused by a gallstone in the duodenum or pylorus (i.e. Bouveret’s syndrome) occurs only in 0.5% of cases with gallstone ileus [7]. But we are not aware of any case in the literature where gallstone ileus, Bouveret’s syndrome and choledocholithiasis were described concomitantly.

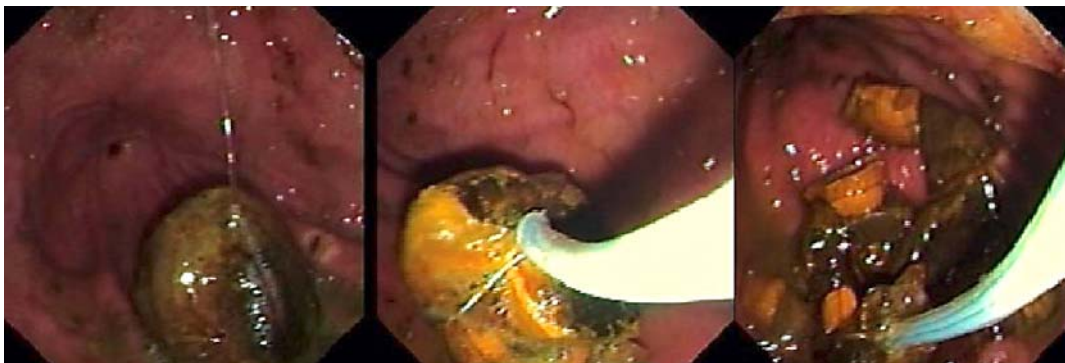
The symptoms of the gallstone ileus may be intermittent and the characteristic roentgenographic signs are often absent [8]. Therefore, the diagnosis of gallstone ileus is often delayed and the diagnostic procedures generally fail to identify the exact cause of the bowel obstruction. The correct diagnosis can be made preoperatively only in about half of all cases with plain X-ray, abdominal US, and CT scan [8]. Upper and lower gastrointestinal endoscopy can be more useful to identify the cause and the level of obstruction, and may allow immediate therapy. Although in obstructive ileus a surgical therapy should be considered as an emergency treatment of choice, endoscopic removal of the impacted stone may be attempted, especially in elderly patients with high operative risk and significant comorbidity [9].

Our present case represented a high-risk patient, where maximal endoscopic therapy could be achieved with the resolution of the obstruction of the colon, stone extraction from the stomach and from the common bile duct. With our therapeutic approach this patient escaped from an urgent and extended operation, which obviously would have carried a high risk of postoperative morbidity and mortality.

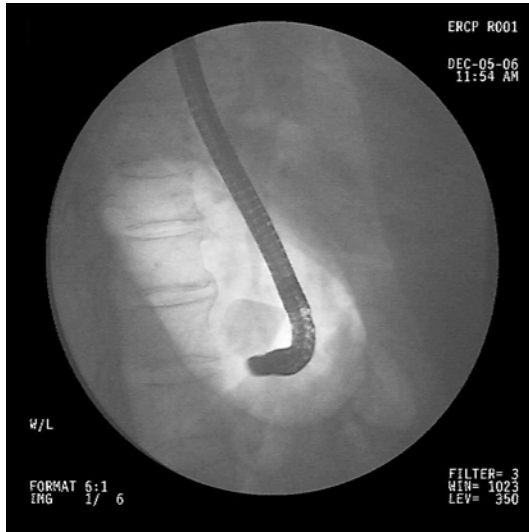**Fig. 1.** Endoscopic pictures of impacted gallstone in the right-sided colon (top) and the stone captured by a mechanical lithotripter.



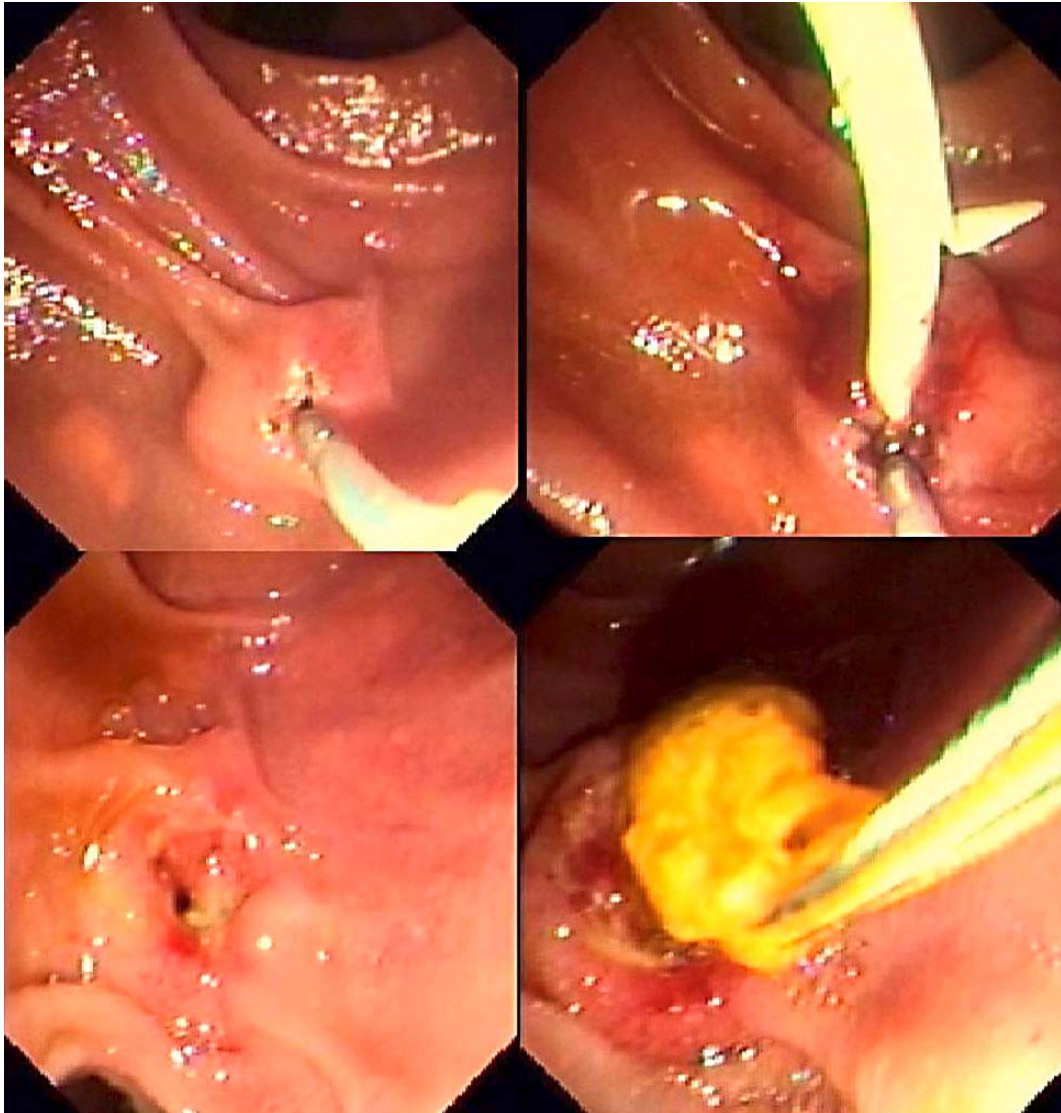
**Fig. 2.** Big gallstone in the stomach before and after its fragmentation with a mechanical lithotripter.



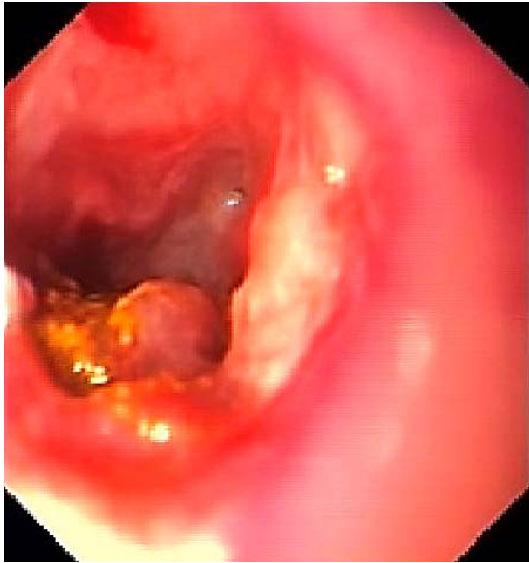**Fig. 3.** X-ray picture of the gallstone in the stomach.



**Fig. 4.** Stages of the process of complete biliary sphincterotomy over a stent and the extraction of the stone from the common bile duct.



**Fig. 5.** Gallstones in the fistulous tract observed through a widely opened cholecystoduodenal fistula with a gastroscope.



## References

- 1 Reisner RM, Cohen JR: Gallstone ileus: a review of 1,001 reported cases. *Am Surg* 1994;60:441–446.
- 2 Clavien PA, Richon J, Burgan S, Rohner A: Gallstone ileus. *Br J Surg* 1990;77:737–742.
- 3 Deitz GM, Standage DA, Pinson CW, et al: Improving the outcome in gallstone ileus. *Am J Surg* 1986;151:572–576.
- 4 Illuminati G, Bartolucci T, Leo G, et al: Gallstone ileus: report of 23 cases with emphasis on factors affecting survival. *Ital J Surg Sci* 1987;17:319–325.
- 5 Murray EL, Collie M, et al: Colonoscopic treatment of gallstone ileus. *Endoscopy* 2006;38:197.
- 6 Anagnostopoulos GK, Sakorafas G, Kolettis T, Kotsifopoulos N, Kassaras G: A case of gallstone ileus with an unusual impaction site and spontaneous evacuation. *J Postgrad Med* 2004;50:55–56.
- 7 Khan AZ, Escofet X, Miles WF, Singh KK: The Bouveret syndrome: an unusual complication of gallstone disease. *J R Soc Health* 2002;122:125–126.
- 8 Swinnen L, Sainte T: Colonic gallstone ileus. *J Belge Radiol* 1994;77:272–274.
- 9 Bornet G, Chiavassa H, Galy-Fourcade D, Jarlaud T, Sans N, Labbé F, Gouzy JL, Railhac JJ: Biliary colonic ileus: an unusual cause of colonic obstruction. *J Radiol* 1998;79:1499–1502.