

Review Article

The Surgical Treatment of Pelvic Bone Metastases

Daniel A. Müller¹ and Rodolfo Capanna²

¹*Department of Orthopedic Surgery, Balgrist University Hospital, 8008 Zurich, Switzerland*

²*Department of Orthopedic Oncology, Careggi University Hospital, 50139 Florence, Italy*

Correspondence should be addressed to Daniel A. Müller; daniel.mueller@balgrist.ch

Received 23 September 2014; Revised 1 February 2015; Accepted 4 February 2015

Academic Editor: Boris Zelle

Copyright © 2015 D. A. Müller and R. Capanna. This is an open access article distributed under the Creative Commons Attribution License, which permits unrestricted use, distribution, and reproduction in any medium, provided the original work is properly cited.

Pelvic bone metastases are a growing concern in the field of orthopedic surgery. Patients with pelvic metastasis are individually different with different needs of treatment in order to attain the best possible quality of life despite the advanced stage of disease. A holistic collaboration among the oncologist, radiation therapist, and orthopedic surgeon is mandatory. Special attention has to be directed to osteolytic lesions in the periacetabular region as they can provoke pathological fractures and subsequent functional impairment. Different reconstruction techniques for the pelvis are available; the choice depends on the patient's prognosis, size of the bone defect, and response of the tumor to adjuvant treatment. If all the conservative treatments are exhausted and the patient is not eligible for surgery, one of the various percutaneous ablation procedures can be considered. We propose a pelvic analogue to the treatment algorithm in long bone metastasis and a scoring system in pelvic metastasis. This algorithm aims to simplify the teamwork and to avoid under- or overtreatment of pelvic bone metastases.

1. Introduction

Primary cancer can spread via the blood or lymphatic circulation to distant organs and form a metastasis. In theory, any organ of the body can be affected, but after lung and liver, bone is the third most common site for metastases. Prostate (32%), breast (22%), kidney (16%), lung and thyroid cancer have a high risk for metastatic bone disease. In fact, these primary carcinomas account for 80% of all the metastases to the bone [1].

Metastatic lesions are found most frequently in the spine, followed by the pelvis. Indeed 833 (18.8%) of all 4431 metastatic lesions registered in the archive of the Rizzoli institute [2] were found to occur in the pelvic region: 559 (12.6%) are located in the ilium, 80 (1.8%) in the ischium, and 53 (1.2%) in the pubis.

In most of the cases complete cure of the disease is not possible and treatment is aimed at palliation. Nevertheless, metastatic carcinoma to the pelvis and the acetabulum decreases seriously the quality of life of the patient and necessitates further treatment. Surgical intervention helps to achieve adequate pain control and to prevent or stabilize pathological fractures. However, in selected cases, complete resection may improve the survival rate of the patient.

The overall prognosis of patients with bone metastasis is extremely variable depending on the site of the lesion, type of primary carcinoma, and existence of further metastasis.

In the past decades, the life expectancy of patients with metastatic carcinoma has improved considerably because of advances in chemotherapy, immunotherapy, hormonal treatment, and radiotherapy [3]. However, this has resulted in an increase in number of patients at risk of developing bone metastases or experiencing a pathological fracture [4]. These patients demand a more reliable and stable reconstructive technique.

Myeloma and lymphoma bone lesions have been shown to have a similar biological behavior as metastatic bone disease and the mechanical implications are comparable. However, chemotherapy and radiotherapy are still the cornerstones of treatment for all lymphomas. In lymphoma patients, bone lesions at risk for a fracture are often successfully treated with chemotherapy and radiotherapy in combination with rest and non-weight-bearing. Surgery is only indicated in pathological fractures with major functional impairments, whereas the timing remains a controversial issue [5]. If fracture location and patient condition allow, the surgical treatment can even be delayed until chemotherapy and radiation therapy are finished [5]. In summary, surgical treatment

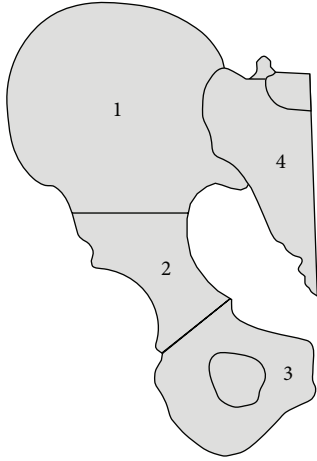


FIGURE 1: Anatomic regions of the pelvis according to the Enneking classification.

of primary bone lymphoma should aim to restore function and pain while minimizing potential delay in chemotherapy initiation.

To date, there is no officially accepted treatment algorithm for pelvic bone metastasis. Orthopedic surgeons, oncologists, or radiotherapists have been treating pelvic metastasis without any guidelines to consider the indications for surgical treatment. The following overview discusses the different possible surgical techniques and their indications and limitations in dealing with pelvic bone metastasis. The chosen procedure should offer an adequate treatment to the patient to achieve the best possible quality of life while avoiding under- or overtreatment.

2. Anatomic Regions of the Pelvis

Metastatic lesions affect the strength of bone reducing stress transmission and the ability to absorb energy. The evaluation of the risk of fracture in a metastasis of the pelvis is guided by its appearance and its location.

Osteolytic lesions are more at risk of fracture than osteoblastic or mixed lesions. Those with a permeative pattern of osteolysis have the same risk of fracture as the more classic types, which show a discrete area of lysis. Permeative osteolysis may be underestimated on plain radiographs, but MRI usually reveals the real extent of the disease.

Highly stressed anatomical sites are particularly predisposed for pathological fractures. According to the Enneking classification [6] the pelvic girdle is divided into 4 different regions as shown in Figure 1.

Zones 1 and 3 are comparable to non-weight-bearing and expendable bones of the extremity and trunk (clavicle, sternum, and fibula). Zone 2 equates to the articular part of major long bones (humerus, femur, and tibia).

The periacetabular (zone 2) lesions are at greater risk for mechanical failure with progressive destruction of the hip joint. Metastatic lesions in zones 1 and 3, even if they are osteolytic, do not compromise the mechanical stability of the pelvic ring.

3. Patient Classification

The multidisciplinary approach to bone metastasis needs a good functioning interaction between orthopedic surgeon, oncologist, and radiotherapist, especially when surgery is needed. Capanna and Campanacci [7] introduced in 2001 an algorithm in long bone metastases providing an easy tool for all involved specialists to find an adequate treatment. The patients are divided into 4 classes: (1) solitary lesion with good prognosis; (2) pathologic fracture; (3) impending fracture; (4) other lesions (see Table 1). In selecting the adequate treatment in long bones and pelvis, important parameters as expected survival, the type and stage of the tumor, visceral spread, the time interval from the primary lesion, the risk of pathological fracture, and the sensitivity to chemotherapy, hormone therapy, and irradiation are considered.

4. Guidelines for Multidisciplinary Treatment

The treatment depends on the patient's prognosis (Capanna Classes 1–4), the exact site of the metastasis in the pelvis (Enneking zones 1–3), and the amount of bone loss of the periacetabular region. A schematic overview of a proposed treatment algorithm is given in Figure 2.

All patients in Classes 1, 2, and 3 should have priority referral to an orthopedic oncologist for surgical treatment. After the operation they will be sent back to an oncologist and a radiotherapist for the evaluation of adjuvant treatment. Patients in Class 4 are treated first conservatively by chemotherapy, hormone therapy, and/or radiation therapy.

5. Patient Class 1

Class 1 includes those patients with a single metastatic lesion of a primary tumor with a good prognosis and an interval of more than three years from detection of the primary lesion to the development of bone metastasis. Primary tumors with a favorable prognosis include well-differentiated thyroid, prostate, breast, when sensitive to hormonal treatment or chemotherapy, clear-cell renal, and colorectal carcinoma. The metastasis is treated as a primary tumor and the operation aims to achieve a long-term cure, both oncological and mechanical. Previous studies have reported that curettage of single metastatic lesions in the pelvis is associated with high mortality and decreased survival compared with wide resection and have justified consideration of a radical surgical approach to achieve tumor control [8–14]. Surgery is probably one of the most important aspects of multimodal strategy in patients with few metastases when a curative attempt is made possible. Despite the emergence of molecular targeted systemic therapy (angiogenesis inhibitors for metastatic renal cell carcinoma) cure is uncommonly achieved in the absence of surgical resection [15].

The Enneking zones 1 and 3 do not require any reconstruction following the tumor resection because the ambulation capability is still preserved. A reinforcement by synthetic mesh helps to avoid visceral herniation. Relatively thin skin, diminished subcutaneous tissue, and lack of muscle mass

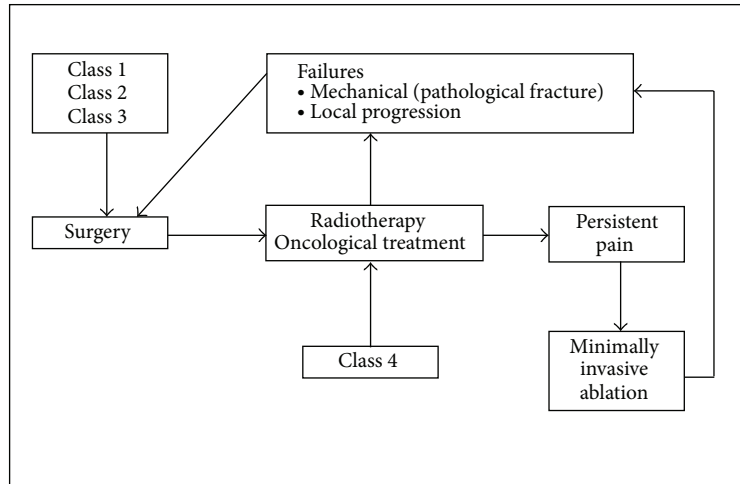


FIGURE 2: Indications for surgical and conservative treatment according to the patient classes.

TABLE 1: Characteristics of the different patient classes comparing metastatic lesions in long bones and pelvis.

Class	Long bones	Pelvis
	Solitary metastatic lesion	
	Primary with good prognosis	
1	(well-differentiated thyroid, prostate, breast sensitive to adjuvants, rectum, clear-cell renal, lymphoma, and myeloma)	
	Interval over three years since detection of the primary	
2	Pathological fracture at any site	Pathological fracture in periacetabular region
3	Impending fracture in a major weight bearing bone	Supra-acetabular osteolytic lesion
	Multiple osteoblastic lesions at all sites	
4	Osteolytic or mixed lesions in nonstructural bone	Osteolytic or mixed lesions in iliac wing and anterior pelvis
	Osteolytic lesion with no impending fracture in major weight bearing bone	Small periacetabular osteolytic lesions

overlying the anterior part of the pelvis increase the risk for skin necrosis and wound complications [1].

Resections in zone 2 alone or in combination with the adjacent regions necessitate further reconstruction to prevent disability and gait disturbances. The periacetabular region can be replaced by custom-made or modular megaprosthesis, saddle prosthesis, or massive allograft in combination with a total hip replacement (Figure 3).

The saddle prosthesis (Link, Hamburg, Germany) was designed by Nieder et al. [16] for large acetabular defects in revision hip arthroplasty. Since the 1908s the saddle prosthesis was also used for reconstruction after periacetabular tumor resection. A notch has to be created in the iliac remnant, in some cases with an allograft augmentation providing more stability. The saddle articulates with the iliac notch and does not require an exact anatomic fit. A high risk of complications (ranging from 33 to 65%) are reported [12, 17, 18]. The major complications consist of wound problems (18–37%), transient peroneal nerve paresis, and neuropraxia of the sciatic and femoral nerves because of the manipulation of the femur and fractures of the remaining iliac wing (0–7%), which generate leg length discrepancies and dislocations

(0–18%). The long-term functional outcome was poor with limited hip flexion [18].

Therefore the saddle prosthesis cannot be recommended for reconstruction after periacetabular tumor resections and remains a salvage procedure for extreme cases.

Custom-made and modular megaprotheses are useful in cases in which standard components are not sufficient. Intraoperative still modifiable modular components (especially the anteversion of the femoral neck) help to achieve better stability of the hip joint. The few available data in the literature indicates a satisfying functional outcome: most of the reported patients can ambulate without pain [19].

Wide tumor resections in the pelvis are reported to have a high rate of complications. But skeletal metastases decrease the quality of life, especially the loss of mobility, independence, and social functioning of a patient [20]. In spite of the mentioned complications, the surgical treatment of pelvic metastasis improves significantly the quality of life and morbidity of the patients [21, 22]. The decision to expose the patient to the burden of major surgery should be well considered and restricted to patients with a good prognosis and major functional impairments.

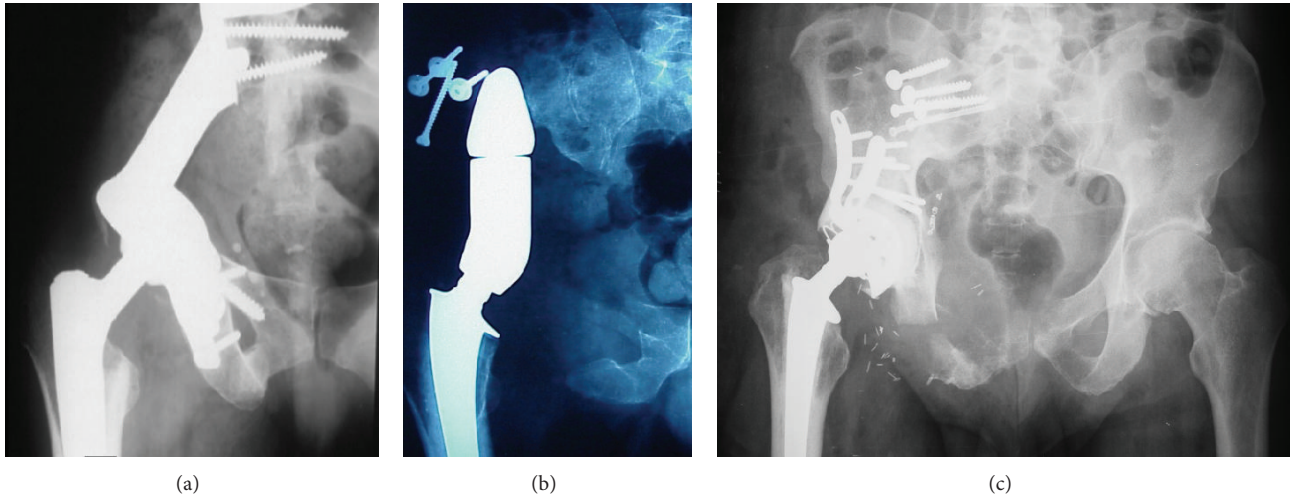


FIGURE 3: Different reconstruction techniques after wide resection of a periacetabular lesion. (a) Megaprosthesis; (b) saddle prosthesis; (c) massive allograft with total hip replacement.

6. Patient Classes 2 and 3

Impending and pathological fractures necessitating a surgical intervention are all located in the periacetabular region (Enneking zone 2). The principle goal of the surgical treatment is to prevent a pathological fracture (Class 3) or to restore the mechanical integrity and function (in particular ambulation) if the fracture already occurred (Class 2). Preoperative angiography and selective embolization are recommended in highly vascular lesions such as clear-cell renal or thyroid carcinoma. If wide oncological margins are achieved at resection, postoperative radiotherapy can be avoided, but it is still recommended after marginal or intralesional procedures or in patients presenting with a pathological fracture. It should be delivered with full doses (3000 to 5000 cGy) and not with levels used for palliative control of pain.

The amount of the periacetabular bone loss dictates the type of surgery. A good tool to indicate the acetabular destruction is the Harrington Classification, ranging from Groups I to IV (Figure 4).

Harrington Group I. If the subchondral bone of the acetabulum is still intact, a simple curettage of the lesion may be performed with cement filling, thus preserving the hip. This procedure may be even carried out percutaneously. Metal pins or bars inserted into intact bone may be used as augmentation to reinforce the acetabular dome. Often the normal congruity of the acetabular surface shows already a disruption. But the unaffected periacetabular bone is still sufficient for a cemented conventional hip prosthesis. The incidence of loosening and migration will not exceed the amount seen in routine total hip replacement. Porous-coated implants have the disadvantage of requiring bone ingrowth for stability. These implants should not be used as the ingrowth is impaired by the cancer and chemo- or radiation therapy applied postoperatively.

Harrington Group II. The medial wall of the acetabulum is destroyed but the superior part (roof) and the lateral wall is still preserved. The use of a conventional prosthesis would lead to a medial migration and consequent loosening. Therefore the cup has to be fixed with the help of a reinforcement ring; otherwise the reconstruction will fail (Figure 5).

Harrington Group III. Extensive osteolysis affects not only the medial wall but also the roof and the lateral rim of the acetabulum. In most patients also the inferior part is functionally nonexistent. So there is no possibility to adequately fixate a conventional cup or a reinforcement ring. Reconstruction typically involves using an implant and cement with internal fixation that extends into uninvolved portions of the pelvis. The large defect has to be replaced first by cement or an allograft to allow an implantation of a cup component afterwards. The use of cement is preferable as the addition of antibiotic drugs lowers the infection risk and an immediate weight-bearing of the affected limb is possible. The disease of the host bone and the irradiation therapy impair the union and ingrowth of an allograft postoperatively. Pseudarthrosis, allograft fractures, prolonged functional impairments, and a higher infection rates are resulting.

Harrington described a technique [23] using large threaded pins placed within the surrounding hemipelvis to support the cemented acetabular component. These pins are used to transform the weight-bearing stresses from the component placed in the deficient acetabular bone to the unaffected bone of the remaining pelvis (Figure 6). This technique is challenging and requires an understanding of the pelvic anatomy and spatial orientation. Placing a finger in the sciatic notch while drilling helps to orientate the anteroposterior pins and protects the sciatic nerve.

Every effort must be made to improve stability of the hip and to avoid subsequent dislocation. Intrinsically stable joints should be implanted if possible. The use of either a snap-fit

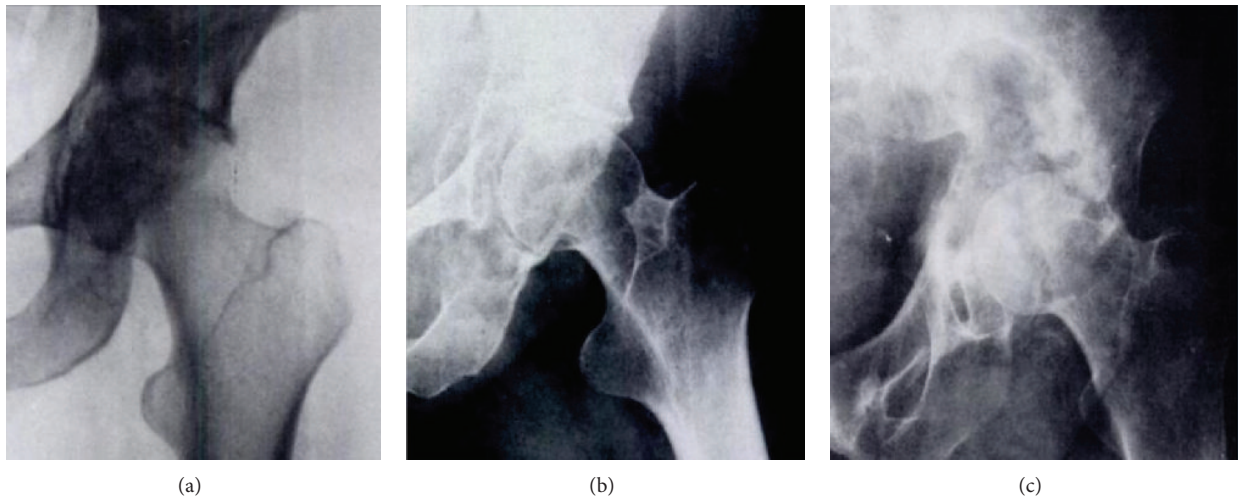


FIGURE 4: Classification of acetabular defects according to Harrington. (a) Integrity of medial and superior periacetabular bone (Group I). (b) Medial wall insufficiency (Group II). (c) Medial wall and supra-acetabular destruction (Group III). Group IV (no image): total collapse of acetabulum.

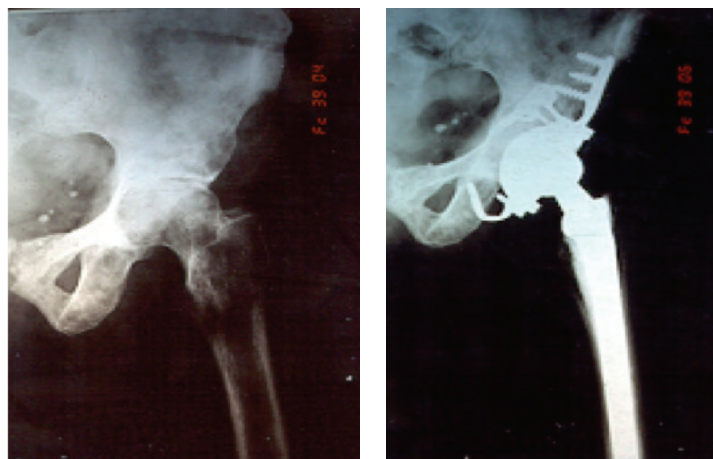


FIGURE 5: Pre- and postoperative radiographies for Harrington Class 2 bone defect.

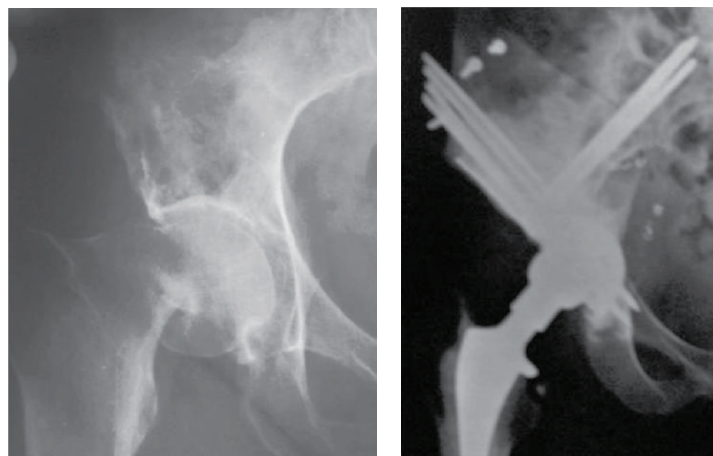

FIGURE 6: Pre- and postoperative radiographies of Class 3 acetabular defect using the Harrington technique for reconstruction.

TABLE 2: Summary of surgical techniques for pelvic metastasis.

Patient	Site of lesion	Resection	Reconstruction
Class 1	Zones 1, 3	Wide margins	None
	Zone 2	Wide margins	Harrington procedure Megaprosthesis Saddle prosthesis Massive allograft with THR
Classes 2, 3	Zone 2	Marginal, intralesional	Harrington I defect Curettage, cement Conventional THR
			Harrington II defect THR with reinforcement ring Harrington III defect Harrington procedure Defect filling with cement or allograft and THR Harrington IV defect Megaprosthesis Saddle prosthesis Massive allograft with THR

THR: total hip replacement.

socket or a large prosthetic femoral head (size 28 to 32 mm) is strongly recommended.

Harrington Group IV. The acetabulum is collapsed completely and can be restored only through a resection. The used reconstructions techniques are the same as in Class 1 patients except that aiming for wide margins is not necessary.

A summary of the different reconstruction techniques and their indications is shown in Table 2.

7. Suggestion for Surgical Treatment in Classes 2 and 3

Concordant to metastatic lesions in long bones [7] an adapted scoring system is introduced for assessment of periacetabular metastases in patients belonging to Class 2 or 3 (Table 3). Additionally to the size of defect, the expected survival (Table 4) and the response of the tumor to adjuvant treatment (Table 5) were taken into account. The aim of the scoring system is selecting the most appropriate surgery to avoid over- or undertreatment of the metastatic lesions. The surgical treatment should be more aggressive in an expected long survival of the patient and big lesions, which do not improve during adjuvant therapies.

8. Patients Class 4

This class includes patients with multiple osteoblastic lesions at any site and osteolytic or mixed lesions in non-weight-bearing bones (Enneking zones 1 and 3) who do not match

the criteria for Class 1. Patients in Class 4 should be treated conservatively by chemotherapy, hormonal therapy, and/or irradiation according to the diagnosis. Periacetabular lesions (Enneking zone 2) can be treated in the same way if they are osteoblastic or osteolytic with a small size and a positive reaction to irradiation is expected (breast, thyroid, prostate, myeloma, and lymphoma). Weight-bearing is strictly forbidden during the radiation therapy to reduce the risk for an iatrogenic fracture [24]. The response to treatment and the control of pain should be carefully evaluated at follow-up. In the case of pathological fracture, persistence of pain for two months after completion of treatment [25], or radiological signs of local progression, the patients should be referred to an orthopedic surgeon for surgical treatment since they are now in either Class 2 or Class 3.

9. Minimally Invasive Treatment

Patients evaluated as Class 4 do not benefit from a surgical resection of the metastatic lesion. They are treated conservatively trying to improve quality of life. Radiation therapy is quite effective in providing relief from painful bone metastasis: 50–80% of patients experience improvement in their pain and 20–50% of the treated patients have even complete pain relief [26, 27]. So the external irradiation is the standard care for patients with localized bone pain and results in the palliation of the majority of these patients. However, some patients do not experience any pain relief. Furthermore, patients who have recurrent pain at a site previously irradiated may not be eligible for further radiation therapy secondary to limitations in normal tissue tolerance. Image-guided percutaneous methods of tumor destruction have rapidly evolved for benign skeletal lesions and more recently for palliation of painful bone metastasis. Because of shortcomings of the currently available therapies for painful metastatic disease, there is a need for alternative treatment strategies. All these new techniques are based on the use of percutaneous image-guided methods to deliver tissue ablative materials or devices inside the metastatic lesion. In the literature described procedures are the local application of ethanol, laser-induced interstitial thermotherapy, cryoablation, and radiofrequency ablation. Additionally a new and promising technology is the electrochemotherapy, but it is still under investigation for the efficacy in bone metastasis and the clinical application [28, 29]. These percutaneous treatments should be considered if the patient has pain not controllable by narcotic analgesics or not responding to earlier applied therapies and is not eligible for a surgical resection. The device based ablation methods may also be combined with the use of methyl methacrylate for further stabilization.

9.1. Ethanol and Thermotherapy. The easiest and presumably the most cost-effective treatment is the injection of ethanol (95%) under CT guidance [30]. The rare existing reported results in the literature indicate a complete pain relief in 16% and no effect in 28% of the patients [30]. For the laser-induced

TABLE 3: Scoring system and recommended treatment for pelvic metastasis in patients of classes 2 and 3.

Survival	Site of defect	Size of defect	Response to adjuvant therapy
<1 year = 1		Small supra-acetabular or medial wall = 2	Yes = 0
1-2 years = 2	Periacetabular = 1	Medial and lateral wall = 4	No = 3
>2 years = 3		Protrusio acetabuli = 6	
Up to 5 points:	curettage or conventional total hip replacement		
5 to 10 points:	complex total hip replacement (reinforcement ring, Harrington procedure)		
10 to 13 points:	megaprosthesis, saddle prosthesis, and massive allograft		

TABLE 4: Predictive survival and scoring for the protocol.

Survival	Source of metastasis
<1 year (1 point)	Unknown
	Melanoma
	Lung
	Pancreas
	Thyroid (undifferentiated)
1 to 2 years (2 points)	Stomach
	Colon
	Breast (not responding to adjuvants)
	Liver
	Uterus (responding to adjuvants)
Over 2 years (3 points)	Thyroid (differentiated)
	Myeloma
	Lymphoma
	Breast (responding to adjuvants)
	Rectum
	Prostate
	Kidney

TABLE 5: Predictive response to adjuvant treatment and scoring for the protocol.

Responsive to adjuvant therapy (0 points)	Breast
	Thyroid
	Myeloma
	Lymphoma
	Prostate
Nonresponsive to adjuvant therapy (3 points)	Kidney
	Gastrointestinal tumor
	Lung
	Uterus
	Pancreas

thermotherapy only 3 cases are reported with a pain relief of maximal 45% [31].

9.2. *Cryoablation.* Cryoablation has a long history of successful treatment of neoplasms in several organs, especially in the prostate. The rapid freezing adjacent to the probe results in intracellular ice formation and with more distance to the probe the cooling causes osmotic differences. Both of these

cellular changes induce cell death. Available preliminary data suggest that cryoablation is effective in treating painful secondary bone neoplasms [32, 33].

9.3. *Radiofrequency Ablation.* Radiofrequency ablation utilizes a high-frequency alternating current that is passed from the needle electrode into the surrounding tissue, resulting in frictional heating and necrosis. Dupuy [34] first reported that radiofrequency ablation of metastases involving the bone may provide pain relief. The first results were engaging and a multicenter study was performed [35] to obtain reliable data: 95% of the included patients experienced a clinical significant pain reduction during the observed time.

9.4. *Promising New Technique: Electrochemotherapy.* Electrochemotherapy (ECT) is the combined effect of electric fields and chemotherapeutics to treat tumor [29]. Using electric pulses bleomycin can enter the tumor cells and accumulates intracellularly. A local effect is created without any unspecific toxicity to normal tissue. Clinical application of ECT mainly focuses on cutaneous and subcutaneous metastatic tumor nodules. Laboratory findings in rats suggest good clinical and histological results using electrochemotherapy in bone metastasis [28]. No important side effects were observed and it seems that in contrary to the other ablation techniques the mechanical bone strength is preserved. Further clinical investigations have to be performed to evaluate this promising procedure.

9.5. *Acetabuloplasty.* Cotten et al. [36] adapted the vertebroplasty technique and applied the same principles for the management of secondary osteolytic lesions around the acetabulum. Acetabuloplasty consists of a percutaneous injection of low viscosity acrylic cement into the osteolytic cavity (Figure 7).

The principal goal is an immediate improvement of the mechanical properties of the affected bone, especially a higher resistance to compressive stresses lowering the fracture risk [37]. Additionally the exothermic reaction during the polymerization of the cements exerts a local cytotoxic reaction against the tumor. Complete pain relief is achieved in 59% of patients [38]. The combination between an ablation therapy and cementoplasty seems to boost the overall effect. A 100% success rate concerning pain control was reported for radiofrequency ablation together with cementoplasty at the level of the spine [39].

TABLE 6: Overview for reported results in minimally invasive techniques.

Technique	Author	Year	Patients	Follow-up	Complications	Effect
Ethanol therapy	Gangi et al. [30]	1994	25	2 weeks	none	Complete pain relief in 16% Partial pain relief in 75%
Laser-induced thermotherapy	Groenemeyer et al. [31]	2002	3	3 months	none	45% pain reduction
Cryoablation	Callstrom et al. [33]	2006	14	6 months	none	Pain relief in 100%
Radiofrequency ablation	Goetz et al. [35]	2004	43	16 weeks	1 skin burn 1 transient bowel and bladder incontinence (metastasis of sacrum) 1 fracture of acetabulum	Pain relief in 95%
	Cotten et al. [36]	1995	18	7 months	Recurrent pain fever/inflammatory processes	Pain relief in 81%
Acetabuloplasty	Marcy et al. [40]	2000	18	4.6 months	1 acetabular fracture	Pain relief in 81%
	Hierholzer et al. [41]	2003	5	—	None	Pain relief in 100%
	Kelekis et al. [42]	2005	14	—	1 intraarticular leakage 1 leakage near pudendal nerve	Pain relief in 92%
	Maccauro et al. [38]	2008	25	6 months	2 venous injection of cement	Complete pain relief in 59% Partial pain relief in 49%

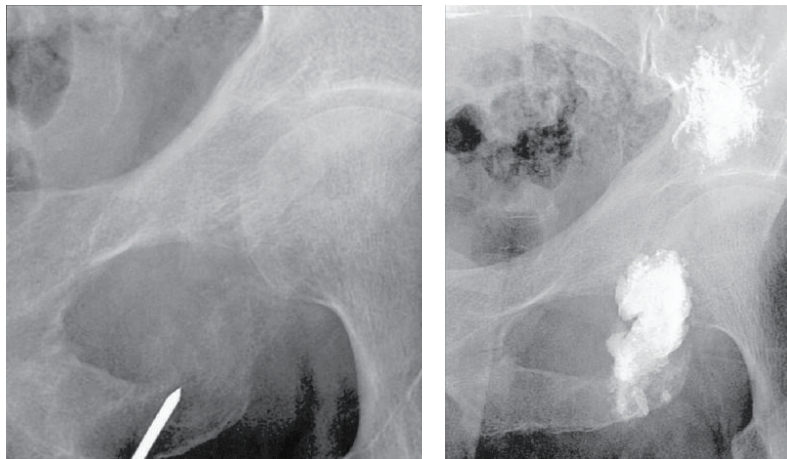


FIGURE 7: Intra- and postoperative radiographies of an acetabuloplasty.

Generally very low complication rates are observed using the percutaneous procedures. Due to the minimal skin incision infection risk is very low. Rare cases of cement protrusion in the hip joint are described with no significant functional loss [40, 42]. Ablation methods as radiofrequency or cryotherapy are contraindicated if the tumor is closer than 1 cm to important structures, for example, spinal cord, major nerves, vessels, or intestine. A short overview for the reported results of minimally invasive techniques is shown in Table 6.

10. Conclusion

Pelvic bone metastases are a growing concern in the field of orthopedic surgery. Every patient needs careful evaluation

and staging. Wide resection results in an improved survival only in solitary metastasis with favorable prognosis. Osteolytic lesions in the periacetabular regions can lead to pathological fractures and important functional impairment. Different reconstruction techniques for the acetabulum are available; the choice depends on the patient's prognosis, size of the bone defect, and response of the tumor to adjuvant treatment. Osteosclerotic acetabular lesions and lesions in the iliac wing and the anterior pelvis are commonly treated conservatively with external irradiation to reduce pain and as local control. If all the conservative treatments are exhausted and the patient is not eligible for surgery, a percutaneous ablation therapy with radiofrequency or cryoablation can be considered. Cementoplasty is another minimal invasive

solution to reduce pain and additionally to reinforce the residual bone.

Every patient needs his individual treatment of the metastasis to provide the best possible life quality despite the advanced stage of disease. A good organized collaboration between the different specialists as oncologists, radiation therapist, and orthopedic surgeon is mandatory. The use of the presented classifications and algorithms simplifies the teamwork and helps to avoid under- or overtreatment of pelvic bone metastasis.

Conflict of Interests

Daniel A. Müller and Rodolfo Capanna declare that there is no conflict of interests regarding the publication of this paper.

Acknowledgment

Daniel A. Müller was supported by a scholarship from the Swiss Society of Orthopaedics and Traumatology (Swiss Orthopaedics).

References

- [1] A. J. Aboulaia, A. M. Levine, D. Schmidt, and D. Aboulaia, "Surgical therapy of bone metastases," *Seminars in Oncology*, vol. 34, no. 3, pp. 206–214, 2007.
- [2] P. Picci, M. Manfrini, N. Fabbri, M. Gambarotti, and D. Vanel, *Atlas of Musculoskeletal Tumors and Tumorlike Lesions*, Springer, Berlin, Germany, 2014.
- [3] W. D. Hage, A. J. Aboulaia, and D. M. Aboulaia, "Incidence, location, and diagnostic evaluation of metastatic bone disease," *Orthopedic Clinics of North America*, vol. 31, no. 4, pp. 515–528, 2000.
- [4] S. Li, Y. Peng, E. D. Weinhandl et al., "Estimated number of prevalent cases of metastatic bone disease in the US adult population," *Clinical Epidemiology*, vol. 4, no. 1, pp. 87–93, 2012.
- [5] G. Scoccianti, L. Rigacci, B. Puccini et al., "Primary lymphoma of bone: outcome and role of surgery," *International Orthopaedics*, vol. 37, no. 12, pp. 2437–2442, 2013.
- [6] W. Enneking, W. Dunham, M. Gebhardt, M. Malawar, and D. Pritchard, "A system for the classification of skeletal resections," *La Chirurgia degli Organi di Movimento*, vol. 75, no. 1, pp. 217–240, 1990.
- [7] R. Capanna and D. A. Campanacci, "The treatment of metastases in the appendicular skeleton," *The Journal of Bone and Joint Surgery—British Volume*, vol. 83, no. 4, pp. 471–481, 2001.
- [8] R. A. W. Marco, D. S. Sheth, P. J. Boland, J. S. Wunder, J. A. Siegel, and J. H. Healey, "Functional and oncological outcome of acetabular reconstruction for the treatment of metastatic disease," *The Journal of Bone and Joint Surgery—American Volume*, vol. 82, no. 5, pp. 642–651, 2000.
- [9] F. R. Patterson and T. D. Peabody, "Operative management of metastases to the pelvis and acetabulum," *Orthopedic Clinics of North America*, vol. 31, no. 4, pp. 623–631, 2000.
- [10] A. W. Yasko, J. Rutledge, V. O. Lewis, and P. P. Lin, "Disease- and recurrence-free survival after surgical resection of solitary bone metastases of the pelvis," *Clinical Orthopaedics and Related Research*, no. 459, pp. 128–132, 2007.
- [11] T. Kunisada and P. F. M. Choong, "Major reconstruction for periacetabular metastasis: early complications and outcome following surgical treatment in 40 hips," *Acta Orthopaedica Scandinavica*, vol. 71, no. 6, pp. 585–590, 2000.
- [12] Y. Kitagawa, E. T. Ek, and P. F. Choong, "Pelvic reconstruction using saddle prosthesis following limb salvage operation for periacetabular tumour," *Journal of Orthopaedic Surgery*, vol. 14, no. 2, pp. 155–162, 2006.
- [13] K. D. Harrington, "The management of acetabular insufficiency secondary to metastatic malignant disease," *The Journal of Bone and Joint Surgery—American Volume*, vol. 63, no. 4, pp. 653–664, 1981.
- [14] J. Nilsson, P. Gustafson, P. Fornander, and E. Ornstein, "The Harrington reconstruction for advanced periacetabular metastatic destruction: good outcome in 32 patients," *Acta Orthopaedica Scandinavica*, vol. 71, no. 6, pp. 591–596, 2000.
- [15] R. H. Breau and M. L. Blute, "Surgery for renal cell carcinoma metastases," *Current Opinion in Urology*, vol. 20, no. 5, pp. 375–381, 2010.
- [16] E. Nieder, R. A. Elson, E. Engelbrecht, M. R. Kasselt, A. Keller, and K. Steinbrink, "The saddle prosthesis for salvage of the destroyed acetabulum," *The Journal of Bone and Joint Surgery—British Volume*, vol. 72, no. 6, pp. 1014–1022, 1990.
- [17] A. J. Aboulaia, R. Buch, J. Mathews, W. Li, and M. M. Malawar, "Reconstruction using the saddle prosthesis following excision of primary and metastatic periacetabular tumors," *Clinical Orthopaedics and Related Research*, no. 314, pp. 203–213, 1995.
- [18] J. A. Jansen, M. A. J. van de Sande, and P. D. S. Dijkstra, "Poor long-term clinical results of saddle prosthesis after resection of periacetabular tumors tumor," *Clinical Orthopaedics and Related Research*, vol. 471, no. 1, pp. 324–331, 2013.
- [19] X. Tang, W. Guo, and T. Ji, "Reconstruction with modular hemipelvic prosthesis for the resection of solitary periacetabular metastasis," *Archives of Orthopaedic and Trauma Surgery*, vol. 131, no. 12, pp. 1609–1615, 2011.
- [20] K. O. Rove and E. D. Crawford, "Metastatic cancer in solid tumors and clinical outcome: skeletal-related events," *Oncology*, vol. 23, no. 14, pp. 21–27, 2009.
- [21] A. Giurea, P. Ritschl, R. Windhager, A. Kaider, U. Helwig, and R. Kotz, "The benefits of surgery in the treatment of pelvic metastases," *International Orthopaedics*, vol. 21, no. 5, pp. 343–348, 1997.
- [22] R. Nagarajan, D. R. Clohisey, J. P. Neglia et al., "Function and quality-of-life of survivors of pelvic and lower extremity osteosarcoma and Ewing's sarcoma: the childhood cancer survivor study," *The British Journal of Cancer*, vol. 91, no. 11, pp. 1858–1865, 2004.
- [23] K. D. Harrington, "Orthopaedic management of extremity and pelvic lesions," *Clinical Orthopaedics and Related Research*, no. 312, pp. 136–147, 1995.
- [24] D. Oh and S. J. Huh, "Insufficiency fracture after radiation therapy," *Radiation Oncology Journal*, vol. 32, no. 4, pp. 213–220, 2014.
- [25] K. D. Harrington, "Impending pathologic fractures from metastatic malignancy: evaluation and management," *Instructional Course Lectures*, vol. 35, pp. 357–381, 1986.
- [26] T. Bates, "A review of local radiotherapy in the treatment of bone metastases and cord compression," *International Journal of Radiation Oncology Biology Physics*, vol. 23, no. 1, pp. 217–221, 1992.

- [27] E. J. Maher, "The use of palliative radiotherapy in the management of breast cancer," *European Journal of Cancer*, vol. 28, no. 2-3, pp. 706-710, 1992.
- [28] M. Fini, F. Salamanna, A. Parrilli et al., "Electrochemotherapy is effective in the treatment of rat bone metastases," *Clinical and Experimental Metastasis*, vol. 30, no. 8, pp. 1033-1045, 2013.
- [29] R. Cadossi, M. Ronchetti, and M. Cadossi, "Locally enhanced chemotherapy by electroporation: clinical experiences and perspective of use of electrochemotherapy," *Future Oncology*, vol. 10, no. 5, pp. 877-890, 2014.
- [30] A. Gangi, B. Kastler, A. Klinkert, and J. L. Dietemann, "Injection of alcohol into bone metastases under CT guidance," *Journal of Computer Assisted Tomography*, vol. 18, no. 6, pp. 932-935, 1994.
- [31] D. H. W. Groenemeyer, S. Schirp, and A. Gevargez, "Image-guided percutaneous thermal ablation of bone tumors," *Academic Radiology*, vol. 9, no. 4, pp. 467-477, 2002.
- [32] P. E. Sewell, J. C. Howard, W. B. Shingleton, and R. B. Harrison, "Interventional magnetic resonance image-guided percutaneous cryoablation of renal tumors," *Southern Medical Journal*, vol. 96, no. 7, pp. 708-710, 2003.
- [33] M. R. Callstrom, J. W. Charboneau, M. P. Goetz et al., "Image-guided ablation of painful metastatic bone tumors: a new and effective approach to a difficult problem," *Skeletal Radiology*, vol. 35, no. 1, pp. 1-15, 2006.
- [34] D. E. Dupuy, "Minimally invasive therapies in the treatment of bone malignancies," *Critical Review*, vol. 75, pp. 161-171, 1998.
- [35] M. P. Goetz, M. R. Callstrom, J. W. Charboneau et al., "Percutaneous image-guided radiofrequency ablation of painful metastases involving bone: a multicenter study," *Journal of Clinical Oncology*, vol. 22, no. 2, pp. 300-306, 2004.
- [36] A. Cotten, X. Deprez, H. Migaud, B. Chabanne, B. Duquesnoy, and P. Chastanet, "Malignant acetabular osteolyses: percutaneous injection of acrylic bone cement," *Radiology*, vol. 197, no. 1, pp. 307-310, 1995.
- [37] Z. Li, N. B. Butala, B. S. Etheridge, H. J. Siegel, J. E. Lemons, and A. W. Eberhardt, "A biomechanical study of periacetabular defects and cement filling," *Journal of Biomechanical Engineering*, vol. 129, no. 2, pp. 129-136, 2007.
- [38] G. Maccauro, F. Liuzza, L. Scaramuzza et al., "Percutaneous acetabuloplasty for metastatic acetabular lesions," *BMC Musculoskeletal Disorders*, vol. 9, article 66, 2008.
- [39] M. D. Lane, H. B. Q. Le, S. Lee et al., "Combination radiofrequency ablation and cementoplasty for palliative treatment of painful neoplastic bone metastasis: experience with 53 treated lesions in 36 patients," *Skeletal Radiology*, vol. 40, no. 1, pp. 25-32, 2011.
- [40] P.-Y. Marcy, J. Palussière, N. Magné, P.-Y. Bondiau, C. Ciais, and J.-N. Bruneton, "Percutaneous cementoplasty for pelvic bone metastasis," *Supportive Care in Cancer*, vol. 8, no. 6, pp. 500-503, 2000.
- [41] J. Hierholzer, G. Anselmetti, H. Fuchs, C. Depriester, K. Koch, and D. Pappert, "Percutaneous osteoplasty as a treatment for painful malignant bone lesions of the pelvis and femur," *Journal of Vascular and Interventional Radiology*, vol. 14, no. 6, pp. 773-777, 2003.
- [42] A. Kelekis, K. O. Lovblad, A. Mehdizade et al., "Pelvic osteoplasty in osteolytic metastases: technical approach under fluoroscopic guidance and early clinical results," *Journal of Vascular and Interventional Radiology*, vol. 16, no. 1, pp. 81-88, 2005.