

# Purpuric and cream-colored plaques in an immunocompromised person: A case of disseminated trichosporonosis



Joy Wan, MD, Evan W. Piette, MD, and Misha Rosenbach, MD  
Philadelphia, Pennsylvania

**Key words:** disseminated trichosporonosis; fungal infection; opportunistic infection; purpura; white piedra.

## INTRODUCTION

*Trichosporon* species have become increasingly recognized as opportunistic pathogens capable of causing disseminated infections. Cutaneous lesions are fairly common and may serve as a diagnostic clue to invasive *Trichosporon* infection. We report a case of disseminated trichosporonosis in an immunocompromised patient who presented with purpuric and cream-colored plaques.

## CASE REPORT

A 67-year-old man with insulin-dependent diabetes mellitus and chronic kidney disease was admitted to the hospital for perforated ischemic colitis requiring exploratory laparotomy and partial colectomy. He was taking tacrolimus and methylprednisolone for immunosuppression for a cardiac transplantation 8 years ago. His hospital course was complicated by ventilator-dependent respiratory failure, and he was given broad-spectrum antimicrobials, including meropenem, vancomycin, and caspofungin, for culture-negative fevers. Approximately 4 weeks into his hospitalization, he had cream-colored plaques with surrounding stellate purpura and necrosis on the right medial thigh and scrotum and multiple blue-black bullous plaques on the right foot (Fig 1). Laboratory testing found a white blood cell count of 18,600/ $\mu$ L (reference range 4,000–11,000/ $\mu$ L), hemoglobin of 8.3 g/dL (reference range, 13.5–17.5 g/dL), and serum creatinine of 2.38 mg/dL (reference range, 0.64–1.27 mg/dL).

A bedside potassium hydroxide preparation performed from the right thigh lesion found fungal elements (Fig 2, A), and immediate frozen section,

standard skin biopsy, and tissue cultures were also performed. The skin biopsy found acute necrotizing inflammation, hemorrhage, and deep fungal infection in the skin and subcutis, with pleomorphic yeast and hyphae forms highlighted on Periodic Acid–Schiff and Grocott stains (Fig 2, B). *Trichosporon asabii* was isolated from skin tissue culture and subsequently from respiratory and blood cultures. Fungal culture plates found characteristic morphology of the yeast (Fig 2, C), which resembled the cream-colored plaques on the patient's skin.

The patient's antifungal therapy was switched to voriconazole and amphotericin, and his immunosuppressive medications were stopped. Despite these measures, his condition continued to deteriorate, and he died a few days after diagnosis of the disseminated infection.

## DISCUSSION

*Trichosporon* species are basidiomycetous yeasts that are ubiquitous in the environment but can colonize the gastrointestinal and urinary tracts, respiratory airways, and skin.<sup>1</sup> Although *Trichosporon* is most commonly associated with white piedra, a benign superficial infection of the hair, it has become increasingly recognized as an opportunistic pathogen capable of causing invasive and fatal infection.<sup>2</sup> *Trichosporon* is the second most common cause, after *Candida*, of disseminated yeast infection in patients with hematologic malignancies.<sup>1</sup> Of the 50 *Trichosporon* species classified to date, *T asabii* is the most common cause of invasive infection, followed by *Trichosporon mucoides* and *Trichosporon asteroides*.<sup>1</sup>

From the Department of Dermatology, University of Pennsylvania.  
Funding sources: None.

Conflicts of interest: None declared.

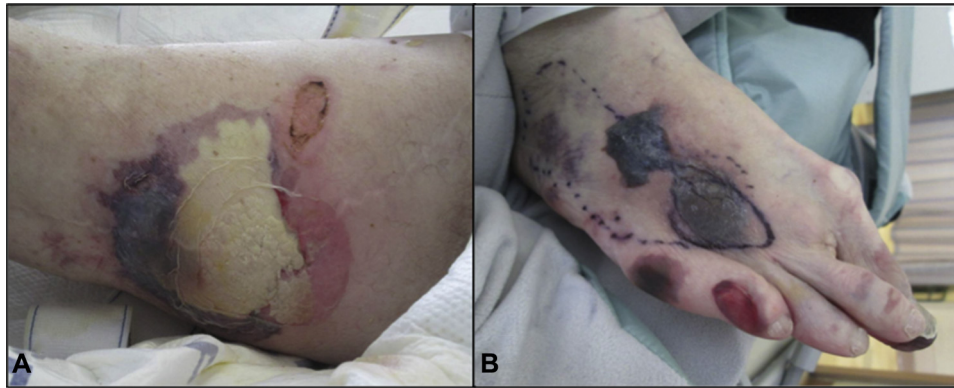
Correspondence to: Misha Rosenbach, MD, 3600 Spruce Street, 2 Maloney Building, 2M47, Philadelphia, PA 19104. E-mail: [Misha.Rosenbach@uphs.upenn.edu](mailto:Misha.Rosenbach@uphs.upenn.edu).

JAAD Case Reports 2016;2:275-7.

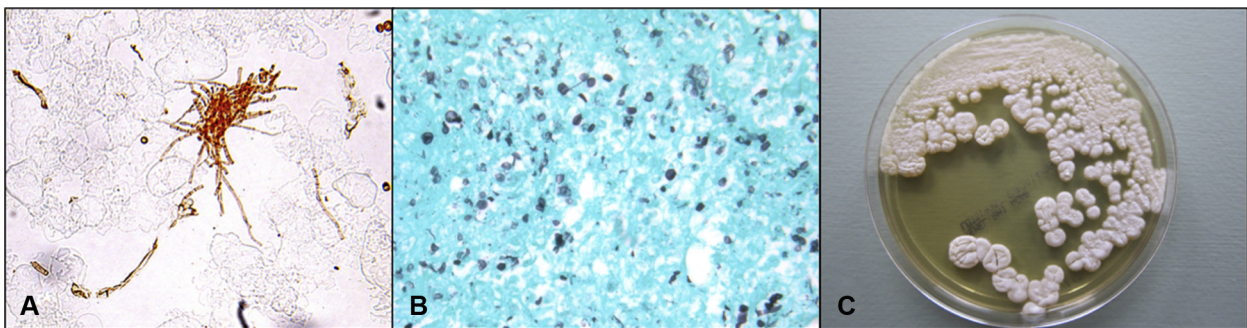
2352-5126

© 2016 by the American Academy of Dermatology, Inc. Published by Elsevier, Inc. This is an open access article under the CC BY-NC-ND license (<http://creativecommons.org/licenses/by-nc-nd/4.0/>).

<http://dx.doi.org/10.1016/j.jidcr.2016.05.014>



**Fig 1.** Disseminated trichosporonosis. **A**, Cream-colored and purpuric plaque on the right medial thigh. **B**, Necrotic bullae on the right foot.



**Fig 2.** **A**, Potassium hydroxide preparation. **B**, Punch biopsy with visible organisms (Grocott stain; original magnification:  $\times 40$ ). **C**, Fungal culture plate with *Trichosporon*. (Courtesy of Laurel Glaser, MD, PhD.)

Invasive trichosporonosis generally affects immunocompromised persons, particularly those with hematologic malignancies or history of organ transplantation.<sup>1-4</sup> It has also been reported in persons with AIDS and critically ill patients without other underlying immunosuppression.<sup>1,5,6</sup> While exogenous inoculation may cause infection, such as in catheter-associated cases, it has been theorized that mucosal, including gut, colonization with *Trichosporon* and subsequent translocation may lead to deep-seated infection.<sup>1</sup> Fungemia and fever are the most common findings in disseminated trichosporonosis. Approximately 30% of patients subsequently have cutaneous lesions, which present as red or purpuric papules, vesicles, and nodules, often with necrosis or ulceration.<sup>6</sup> Organs such as the lung, liver, heart, brain, and urinary tract may also be infected.

Early diagnosis of invasive trichosporonosis is critical and can be made using tissue histology and culture. Although limited data exist on the antifungal susceptibilities of *Trichosporon* species, triazoles, including voriconazole, appear to have the greatest

activity and are recommended as first-line therapy.<sup>3,4,7</sup> However, breakthrough *Trichosporon* infections have been noted in patients even after the administration of triazoles,<sup>1,7-9</sup> and multiple *Trichosporon* species can produce triazole-resistant biofilms.<sup>10</sup> In addition, increasing evidence suggests that amphotericin and echinocandins have little to no efficacy against *Trichosporon*.<sup>1,8</sup> Despite antifungal therapy, invasive trichosporonosis carries a mortality rate of 50% to 80%.<sup>1</sup>

The authors thank Laurel Glaser, MD, PhD, for her review of the pathology and microbiology.

#### REFERENCES

- Colombo AL, Padovan AC, Chaves GM. Current knowledge of trichosporon spp. and trichosporonosis. *Clin Microbiol Rev*. 2011;24(4):682-700.
- Liao Y, Lu X, Yang S, Luo Y, Chen Q, Yang R. Epidemiology and outcome of trichosporon fungemia: A review of 185 reported cases from 1975 to 2014. *Open Forum Infect Dis*. 2015;2(4):ofv141.
- Almeida Junior JN, Song AT, Campos SV, et al. Invasive trichosporon infection in solid organ transplant patients: A report of two cases identified using IGS1 ribosomal DNA

- sequencing and a review of the literature. *Transpl Infect Dis.* 2014;16(1):135-140.
4. Mays SR, Bogle MA, Bodey GP. Cutaneous fungal infections in the oncology patient: Recognition and management. *Am J Clin Dermatol.* 2006;7(1):31-43.
  5. Chagas-Neto TC, Chaves GM, Melo AS, Colombo AL. Bloodstream infections due to trichosporon spp.: Species distribution, trichosporon asahii genotypes determined on the basis of ribosomal DNA intergenic spacer 1 sequencing, and antifungal susceptibility testing. *J Clin Microbiol.* 2009;47(4):1074-1081.
  6. Nahass GT, Rosenberg SP, Leonardi CL, Penneys NS. Disseminated infection with trichosporon beigelii. report of a case and review of the cutaneous and histologic manifestations. *Arch Dermatol.* 1993;129(8):1020-1023.
  7. Suzuki K, Nakase K, Kyo T, et al. Fatal trichosporon fungemia in patients with hematologic malignancies. *Eur J Haematol.* 2010;84(5):441-447.
  8. Walsh TJ, Groll A, Hiemenz J, Fleming R, Roilides E, Anaissie E. Infections due to emerging and uncommon medically important fungal pathogens. *Clin Microbiol Infect.* 2004;10(Suppl 1):48-66.
  9. Kontoyiannis DP, Torres HA, Chagua M, et al. Trichosporonosis in a tertiary care cancer center: Risk factors, changing spectrum and determinants of outcome. *Scand J Infect Dis.* 2004;36(8):564-569.
  10. Iturrieta-Gonzalez IA, Padovan AC, Bizerra FC, Hahn RC, Colombo AL. Multiple species of trichosporon produce biofilms highly resistant to triazoles and amphotericin B. *PLoS One.* 2014;9(10):e109553.