

Age-stratified analysis of temporomandibular joint osteoarthritis using cone-beam computed tomography

Hee-Jeong Song¹, Hang-Moon Choi², Bo-Mi Shin³, Young-Jun Kim¹, Moon-Soo Park¹,
Cheul Kim^{1,*}

¹Department of Oral Medicine and Diagnosis, Research Institute of Oral Science, College of Dentistry, Gangneung-Wonju National University, Gangneung, Korea

²Department of Oral and Maxillofacial Radiology, Research Institute of Oral Science, College of Dentistry, Gangneung-Wonju National University, Gangneung, Korea

³Department of Dental Hygiene, Research Institute of Oral Science, College of Dentistry, Gangneung-Wonju National University, Gangneung, Korea

ABSTRACT

Purpose: This study aimed to evaluate age-stratified radiographic features in temporomandibular joint osteoarthritis using cone-beam computed tomography.

Materials and Methods: In total, 210 joints from 183 patients (144 females, 39 males, ranging from 12 to 88 years old with a mean age of 44.75 ± 19.97 years) diagnosed with temporomandibular joint osteoarthritis were stratified by age. Mandibular condyle position and bony changes (flattening, erosion, osteophytes, subchondral sclerosis, and subchondral pseudocysts in both the condyle and articular eminence, thickening of the glenoid fossa, joint space narrowing, and joint loose bodies) were evaluated through cone-beam computed tomography. After adjusting for sex, the association between age groups and radiographic findings was analyzed using both a multiple regression model and a multinomial logistic regression model ($\alpha = 0.05$).

Results: The prevalence of joint space narrowing and protruded condyle position in the glenoid fossa significantly increased with age ($P < 0.05$). The risks of bony changes, including osteophytes and subchondral pseudocysts in the condyle; flattening, erosion, osteophyte, and subchondral sclerosis in the articular eminence; joint loose bodies; and thickening of the glenoid fossa, also significantly rose with increasing age ($P < 0.05$). The number of radiographic findings increased with age; in particular, the increase was more pronounced in the temporal bone than in the mandibular condyle ($P < 0.05$).

Conclusion: Increasing age was associated with a higher frequency and greater diversity of bony changes in the temporal bone, as well as a protruded condyle position in the glenoid fossa, resulting in noticeable joint space narrowing in temporomandibular joint osteoarthritis. (*Imaging Sci Dent* 2024; 54: 71-80)

KEY WORDS: Age Groups; Cone-Beam Computed Tomography; Osteoarthritis; Temporomandibular Joint

Introduction

Osteoarthritis is a degenerative condition that occurs

when the stress on a joint surpasses the physiological tolerance of the cartilage. This non-inflammatory disorder is marked by the progressive breakdown of soft tissues within the joint, which is followed by bone resorption and proliferation. Osteoarthritis can affect any synovial joint that is subjected to prolonged and repetitive strain. Despite extensive research, the exact cause of osteoarthritis remains uncertain.¹ Various factors, such as occupational overuse, repetitive injuries, obesity, sex, genetic predisposition, and age, have been implicated in its development.

This study was supported by the 2021 Scientific Research Program (SR2102) of Gangneung-Wonju National University Dental Hospital.

Received October 17, 2023; Revised December 26, 2023; Accepted January 8, 2024

Published online February 22, 2024

*Correspondence to : Prof. Cheul Kim

Department of Oral Medicine and Diagnosis, Research Institute of Oral Science, College of Dentistry, Gangneung-Wonju National University, 7 Jukheon-gil, Gangneung 25457, Korea

Tel) 82-33-640-2459, E-mail) chkim@gwnu.ac.kr

Copyright © 2024 by Korean Academy of Oral and Maxillofacial Radiology

This is an Open Access article distributed under the terms of the Creative Commons Attribution Non-Commercial License (<http://creativecommons.org/licenses/by-nc/3.0>) which permits unrestricted non-commercial use, distribution, and reproduction in any medium, provided the original work is properly cited.

Imaging Science in Dentistry · pISSN 2233-7822 eISSN 2233-7830

The temporomandibular joint (TMJ) is unique in that it allows both rotational and gliding movements during mandibular motion. TMJ osteoarthritis is characterized by degenerative bony changes, such as flattening, erosion, osteophytes, subchondral sclerosis, pseudocysts, and alterations in the mandibular condyle and articular eminence dimensions, as well as loose bodies within the joint space.^{2,3}

While the general radiographic findings of degenerative bony changes in TMJ osteoarthritis are well-established, evaluating the TMJ with conventional radiography can be challenging due to the potential for overlapping anatomical structures. Cone-beam computed tomography (CBCT) has effectively addressed this limitation, offering high-resolution, distortion-free, 3-dimensional images of the TMJ. Furthermore, CBCT provides multi-planar images with significantly lower radiation exposure than conventional computed tomography (CT) scans, making it an essential tool for diagnosing TMJ osteoarthritis.^{4,6}

Age is a well-established and significant risk factor for the development of osteoarthritis. As individuals age, the cumulative effects of biomechanical loads applied to the joint may exceed its physiological tolerance, increasing the likelihood of developing osteoarthritis. Consequently, the prevalence of osteoarthritis escalates notably after the age of 45.⁷⁻¹⁰

Numerous studies have investigated the relationship between age and osteoarthritis, not only in the TMJ but also in other joints such as the knee, ankle, and wrist.¹¹⁻¹⁴ The knee joint, in particular, has been the subject of extensive research. Jordan et al.¹³ found that the prevalence of knee osteoarthritis was 26.2% in individuals aged 55-64, but this figure rose to 50% in those aged 75 and older. Ding et al.¹⁴ highlighted that the most pronounced structural changes in knee osteoarthritis associated with aging include the extent of cartilage defects, cartilage thinning, and an increase in bone size.

While age is a well-established risk factor for osteoarthritis, it is noteworthy that adolescents often exhibit severe degenerative changes in the bony structures of the TMJ, setting it apart from other joints. Surprisingly, research on the radiographic features of TMJ osteoarthritis in relation to increasing age is lacking. Previous studies have primarily concentrated on evaluating the articular surface of the mandibular condyle or the overall bony changes in the TMJ.^{6,7} However, there is a scarcity of research clarifying which radiographic findings are more closely associated with specific age groups among patients with TMJ osteoarthritis.

The objective of the present study was to investigate age-stratified radiographic features in CBCT images of TMJ

osteoarthritis and identify which radiographic findings are more strongly associated with age progression.

Materials and Methods

Subjects

This study was approved by the Institutional Review Board of Gangneung-Wonju National University Dental Hospital (IRB no. GWNUDH-IRB2021-A006). Data were retrospectively collected from patients diagnosed with TMJ osteoarthritis, based on clinical and TMJ CBCT examinations, who presented with TMJ pain, dysfunction, or joint noise and visited the Department of Oral Medicine at Gangneung-Wonju National University Dental Hospital between March 2017 and August 2021. All subjects were consistently evaluated and documented by 3 board-certified orofacial pain specialists according to the Research Diagnostic Criteria for Temporomandibular Disorders (RDC/TMD).¹⁵

Patients were categorized into age groups spanning their 10s, 20s, 30s, 40s, 50s, 60s, and 70s and beyond. Thirty joints were randomly selected from each age group for radiographic analysis. A total of 183 patients (144 females and 39 males, with an age range of 12-88 years and a mean age of 44.75 ± 19.97 years) were included in this study, accounting for 210 joints. This total included 27 patients in whom the TMJs on both sides were affected.

Patients with congenital anomalies, a history of surgery and acute trauma involving the TMJ, or any systemic disease known to affect joint morphology, such as rheumatoid arthritis, were excluded. Additionally, patients with TMJ osteoarthrosis who presented with no clinical signs or symptoms other than degenerative radiographic findings or TMJ crepitus at their initial visit were also excluded.

Methods

All subjects were instructed to bite in maximum intercuspation. The CBCT images were scanned using the Alphard-3030[®] (Asahi Roentgen Co, Kyoto, Japan) in P-mode, operating at 80 kV and 8 mA, with images acquired at a voxel size of 0.30 mm. For imaging analysis, the Xelis Dental program[®] (INFINITT Healthcare Co, Seoul, Korea) was employed. The coronal plane, aligned with the long axis connecting the medial and lateral poles of the mandibular condyle in the TMJ, and the sagittal plane perpendicular to this long axis were established as the standard reference planes. The image slices were configured with a thickness and interval of 1 mm for both the corrected coronal and sagittal reconstructions. Osteoarthritic bony changes were assessed in both the mandibular condyle and temporal

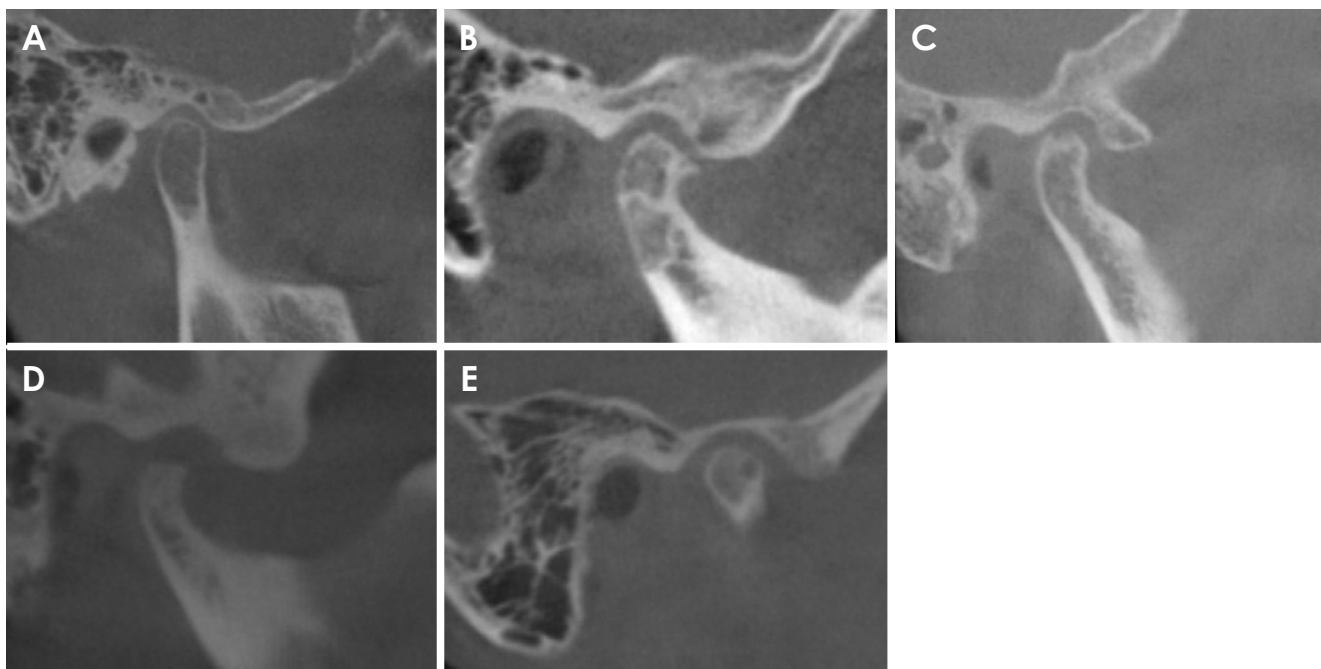


Fig. 1. Sample cone-beam computed tomography images represent bony changes in the mandibular condyle, selected from subjects in this study. A. Normal state. B. Flattening and osteophyte. C. Erosion. D. Subchondral sclerosis. E. Subchondral pseudocyst.

bone of the TMJ. All CBCT images were reconstructed and evaluated according to the interpretation criteria of Ahmad et al.¹⁶ by a board-certified oral and maxillofacial radiologist at Gangneung-Wonju National University Dental Hospital.

The criteria for identifying osteoarthritic bony changes were as follows: Flattening (F-C) referred to the loss of the convex shape of the articular surface of the mandibular condyle. Erosion (E-C) indicated a loss of continuity in the cortical bone boundaries of the mandibular condyle. An osteophyte (O-C) was defined as a pathological growth of bone or an outwardly grown bone tissue on the mandibular condyle. Subchondral sclerosis (SS-C) denoted a condition of osteosclerosis beneath the articular cartilage of the mandibular condyle. A subchondral pseudocyst (SC-C) referred to a subchondral cavity that deviates from the normal bone marrow morphology of the mandibular condyle. Flattening (F-E) involved the loss of the convex shape of the articular surface of the articular eminence. Erosion (E-E) referred to a loss of continuity in the cortical bone boundaries of the articular eminence. An osteophyte (O-E) was defined as a pathological growth of bone or an outwardly grown bone tissue on the articular eminence. Subchondral sclerosis (SS-E) was defined as a condition of osteosclerosis beneath the articular cartilage of the articular eminence. A subchondral pseudocyst (SC-E) referred to a subchondral cavity deviating from the normal bone marrow morphology of the artic-

ular eminence. Thickening of the glenoid fossa (T-F) was characterized by the roof of the glenoid fossa being thicker than 1.5 mm.^{17,18} Joint space narrowing was defined as an abnormally reduced joint space (less than 1.5 mm) in 2 or more of the anterior, superior, and posterior regions.¹⁹ Joint loose bodies (LB) referred to calcified structures that were not continuous with the articular disc or bone structure of the joint.

The mandibular condyle position in the closed state was assessed as follows: A concentric position was defined as equal distances from the mandibular condyle to the anterior and posterior slopes of the articular surface of the temporal bone in a midsagittal image. A protruded position occurred when the mandibular condyle in the joint space was anterior to the concentric position. A retruded position referred to a configuration where the mandibular condyle in the joint space was posterior to the concentric position. Figures 1-4 show sample CBCT images of the mandibular condyle, temporal bone, joint space, and mandibular condyle position, respectively.

Intra-rater reliability

To assess the intra-rater reliability of the radiographic readings, a total of 14 joints were randomly selected (2 joints chosen from each age group), and the radiographic readings were repeated by the same examiner. The results

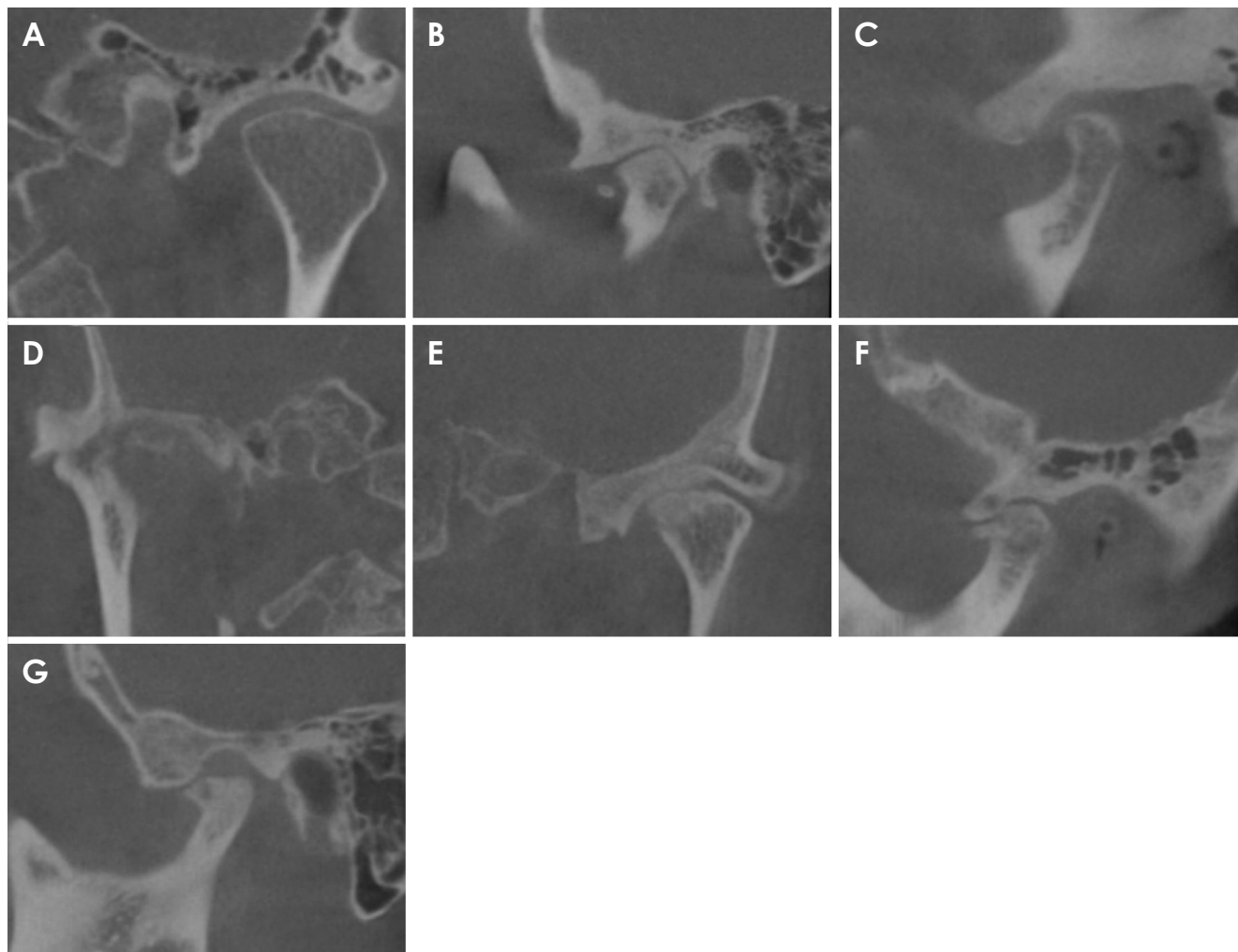


Fig. 2. Sample cone-beam computed tomography images show bony changes in the temporal bone, selected from subjects in this study. A. Normal state (coronal view). B. Flattening (sagittal view). C. Erosion (sagittal view). D. Osteophyte (coronal view). E. Subchondral sclerosis (coronal view). F. Subchondral pseudocyst (sagittal view). G. Thickening of glenoid fossa.

indicated excellent intra-rater reliability, with a Cohen’s kappa coefficient of 0.950 ($P < 0.05$).

Statistical analysis

Age was categorized into 7 groups to examine the correlations between radiographic findings and age: 10-19 years old, 20-29 years old, 30-39 years old, 40-49 years old, 50-59 years old, 60-69 years old, and over 70 years old. The associations between age group and radiographic findings were evaluated using the chi-square test. If a variable had more than 20% of cells with an expected frequency of less than 5, the Fisher exact test was performed. The risk of degenerative bony changes in the TMJ by age group was then evaluated using logistic regression analysis, and the results were expressed as odds ratios (ORs) and 95% confidence intervals (CI).

The mandibular condyle position variables were classified as concentric = 0, protruded = 1, and retruded = 2, and multinomial logistic regression analysis was performed with the concentric position as the standard category.

In this study, 3 variables were created by combining a total of 12 components: the radiographic findings score of the mandibular condyle (composed of F-C, E-C, O-C, SS-C, and SC-C; ranging from 0 to 5 points), the radiographic findings score of the temporal bone (consisting of F-E, E-E, O-E, SS-E, SC-E, and TF; ranging from 0 to 6 points), and the total radiographic findings score (incorporating all 11 components with LB; ranging from 0 to 12 points).

To assess the normality of radiographic findings scores in the mandibular condyle, temporal bone, and overall scores for each age group, the Kolmogorov-Smirnov test was utilized. Based on the normality test outcomes, differences in

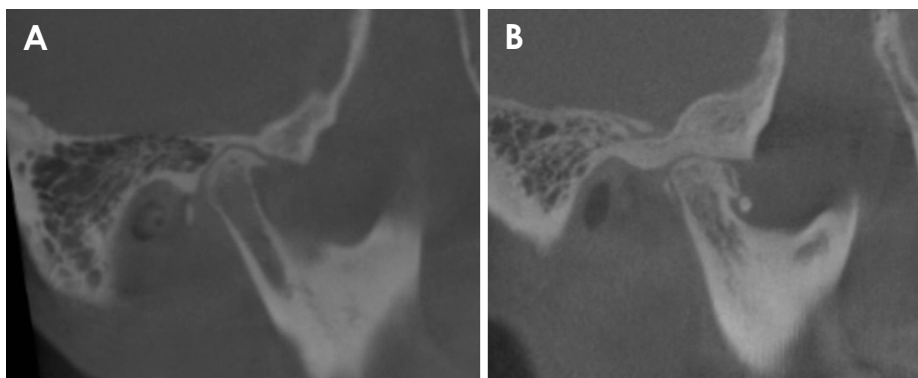


Fig. 3. Sample cone-beam computed tomography images depict joint space narrowing and joint loose bodies, selected from subjects in this study. A. Joint space narrowing. B. Joint loose bodies.

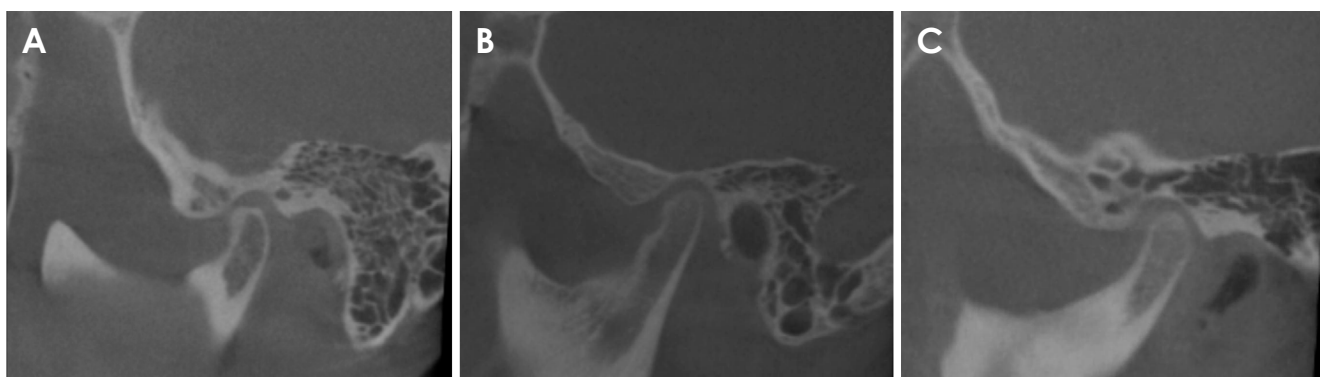


Fig. 4. Sample cone-beam computed tomography images illustrate mandibular condyle position in the closed state, selected from subjects in this study. A. Protruded position. B. Concentric position. C. Retruded position.

radiographic findings scores across age groups were analyzed using either the Kruskal-Wallis test or 1-way analysis of variance (ANOVA). Multiple regression analysis was then conducted to determine the influence of age on radiographic findings scores, with all models adjusted for sex. Statistical analyses were performed using SPSS version 25.0 (IBM Corp., Armonk, NY, USA), with the significance level set at $\alpha=0.05$.

Results

Mandibular condyle position and degenerative bony changes

The chi-square test was used to examine differences in affected side of bony changes, mandibular condyle position, and joint space narrowing based on age group and sex (Table 1). Out of 210 joints, 42.9% had bony changes on the right side, and 57.1% on the left, with no significant sex or age group differences. The mandibular condyle position showed a statistically significant association with age group

($P<0.05$), but not with sex. Joint space narrowing increased with age, showing a statistically significant difference ($P<0.05$), but no significant difference by sex was observed.

In the investigation of the frequency of various radiographic findings observed in CBCT images, it was found that E-C had the highest frequency (88.1%), while SC-E had the lowest frequency (8.0%). There were no statistically significant differences in the presence or absence of all radiographic findings according to sex. However, the analysis revealed statistically significant differences in all radiographic findings, except F-C and E-C, according to age group ($P<0.05$) (Table 2).

Analyzing the risk of changes in mandibular condyle position while adjusting for sex revealed a significant 1.67-fold increase in the risk of a protruded mandibular condyle position with each 10-year increase in age. No significant difference was found in the risk of a retruded mandibular condyle position compared to the concentric position (Fig. 5A). The analysis also demonstrated that the risks of T-F, SS-E, and LB increased by 2.03, 2.02, and 1.99 times, respectively, as

Table 1. Cone-beam computed tomography assessment of temporomandibular joint osteoarthritis by age and sex (number and percentage, chi-square test)

Subject population	N	Affected side of bony changes			Mandibular condyle position in closed state				Joint space narrowing		
		Right	Left	P-value	Retruded	Concentric	Protruded	P-value	No	Yes	P-value
Sex											
Female	167	73 (43.7)	94 (56.3)	0.730	62 (37.1)	51 (30.5)	54 (32.3)	0.313	107 (64.1)	60 (35.9)	0.371
Male	43	17 (39.5)	26 (60.5)		18 (41.9)	8 (18.6)	17 (39.5)		31 (72.1)	12 (27.9)	
Age group											
10-19	30	12 (40.0)	18 (60.0)	0.961	20 (66.7)	9 (30.0)	1 (3.3)	<0.05	130 (100.0)	0 (0.0)	<0.05
20-29	30	11 (36.7)	19 (63.3)		19 (63.3)	9 (30.0)	2 (6.7)		28 (93.3)	2 (6.7)	
30-39	30	14 (46.7)	16 (53.3)		8 (26.7)	13 (43.3)	9 (30.0)		21 (70.0)	9 (30.0)	
40-49	30	12 (40.0)	18 (60.0)		9 (30.0)	10 (33.3)	11 (36.7)		18 (60.0)	12 (40.0)	
50-59	30	13 (43.3)	17 (56.7)		11 (36.7)	6 (20.0)	13 (43.3)		16 (53.3)	14 (46.7)	
60-69	30	13 (43.3)	17 (56.7)		6 (20.0)	10 (33.3)	14 (46.7)		16 (53.3)	14 (46.7)	
70~	30	15 (50.0)	15 (50.0)		7 (23.3)	2 (6.7)	21 (70.0)		9 (30.0)	21 (70.0)	
Total	210	90 (42.9)	120 (57.1)		80 (38.1)	59 (28.1)	71 (33.8)		138 (65.7)	72 (34.3)	

Table 2. Cone-beam computed tomography evaluation of temporomandibular joint osteoarthritis-related bone changes by age and sex (number and percentage)

Subject population	Mandibular condyle						Temporal bone					
	F-C*	E-C†	O-C*	SS-C*	SC-C*	LB†	F-E*	E-E*	O-E†	SS-E*	SC-E†	T-F†
Sex												
Female	119 (71.3)	151 (90.4)	110 (65.9)	93 (55.7)	42 (25.1)	18 (10.8)	37 (22.2)	70 (41.9)	21 (21.6)	37 (22.2)	6 (3.6)	19 (11.4)
Male	32 (74.4)	34 (79.1)	30 (69.8)	25 (58.1)	9 (20.9)	5 (11.6)	11 (25.6)	21 (48.8)	5 (11.6)	8 (18.6)	2 (4.7)	6 (14.0)
P-value	>0.05	>0.05	>0.05	>0.05	>0.05	>0.05	>0.05	>0.05	>0.05	>0.05	>0.05	>0.05
Age group												
10-19	18 (60.0)	28 (93.3)	10 (33.3)	10 (33.3)	3 (10.0)	0 (0.0)	1 (3.3)	2 (6.7)	0 (0.0)	0 (0.0)	0 (0.0)	0 (0.0)
20-29	18 (60.0)	24 (80.0)	17 (56.7)	10 (33.3)	1 (3.3)	0 (0.0)	1 (3.3)	7 (23.3)	0 (0.0)	0 (0.0)	0 (0.0)	0 (0.0)
30-39	21 (70.0)	25 (83.3)	22 (73.3)	17 (56.7)	5 (16.7)	0 (0.0)	5 (16.7)	7 (23.3)	1 (3.3)	3 (10.0)	1 (3.3)	0 (0.0)
40-49	23 (76.7)	26 (86.7)	21 (70.0)	21 (70.0)	7 (23.3)	3 (10.0)	8 (26.7)	13 (43.3)	4 (13.3)	5 (16.7)	0 (0.0)	2 (6.7)
50-59	21 (70.0)	28 (93.3)	21 (70.0)	22 (73.3)	11 (36.7)	5 (16.7)	4 (13.3)	18 (60.0)	7 (23.3)	7 (23.3)	0 (0.0)	4 (13.3)
60-69	28 (93.3)	27 (90.0)	27 (90.0)	20 (66.7)	15 (50.0)	7 (23.3)	15 (50.0)	25 (83.3)	7 (23.3)	17 (56.7)	4 (13.3)	14 (46.7)
70~	22 (73.3)	27 (90.0)	22 (73.3)	18 (60.0)	9 (30.0)	8 (26.7)	14 (46.7)	19 (63.3)	7 (23.3)	13 (43.3)	3 (10.0)	5 (16.7)
P-value	0.078	0.688	<0.05	<0.05	<0.05	<0.05	<0.05	<0.05	<0.05	<0.05	<0.05	<0.05
Total	151 (71.9)	185 (88.1)	140 (66.7)	118 (56.2)	51 (24.3)	23 (11.0)	48 (22.9)	91 (43.3)	26 (12.4)	45 (21.4)	3.8 (8.0)	25 (11.9)

F-C: flattening of condyle, E-C: erosion of condyle, O-C: osteophyte of condyle, SS-C: subchondral sclerosis of condyle, SC-C: subchondral pseudocyst of condyle, LB: joint loose bodies, F-E: flattening of articular eminence, E-E: erosion of articular eminence, O-E: osteophyte of articular eminence, SS-E: subchondral sclerosis of articular eminence, SC-E: subchondral pseudocyst of articular eminence, T-F: thickening of the glenoid fossa, *: Chi-square test, †: Fisher exact test

the age group increased by each 10-year interval ($P < 0.05$) (Fig. 5B).

Quantitative analysis of bony changes according to the radiographic findings score

The Kruskal-Wallis test was used to compare radiographic findings scores in both the mandibular condyle and tem-

poral bone by age group, and statistically significant differences were observed ($P < 0.05$) (Tables 3 and 4). Furthermore, 1-way ANOVA was employed to analyze the difference in total radiographic findings scores by age group, and a statistically significant difference was also confirmed (Table 5). The *post hoc* analysis using Dunnett’s T3 revealed that the scores for individuals in their 10s and 20s

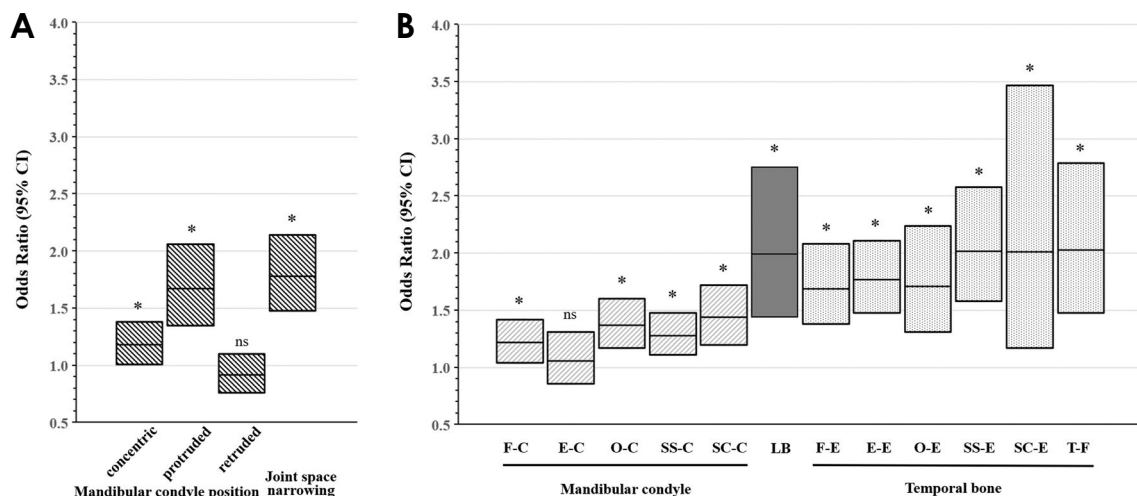


Fig. 5. Odds ratios for cone-beam computed tomography findings in temporomandibular joint osteoarthritis by age group. A. Mandibular condyle position and joint space narrowing (reference: concentric). B. Degenerative bony changes. *: $P < 0.05$; F-C: Flattening of condyle; E-C: Erosion of condyle; O-C: osteophyte of condyle; SS-C: subchondral sclerosis of condyle; SC-C: subchondral pseudocyst of condyle; LB: joint loose bodies; F-E: flattening of articular eminence; E-E: erosion of articular eminence; O-E: osteophyte of articular eminence; SS-E: subchondral sclerosis of articular eminence; SC-E: subchondral pseudocyst of articular eminence; T-F: thickening of the glenoid fossa.

Table 3. Age-related differences in the radiographic findings score of the mandibular condyle in temporomandibular joint osteoarthritis (Kruskal-Wallis test)

Age group	Radiographic findings score of the mandibular condyle	
	Mean \pm standard deviation	<i>P</i> -value
10-19	2.30 \pm 1.09	< 0.05
20-29	2.33 \pm 0.99	
30-39	3.00 \pm 1.17	
40-49	3.27 \pm 1.39	
50-59	3.43 \pm 1.36	
60-69	3.90 \pm 1.30	
70~	3.27 \pm 1.39	
Total	3.07 \pm 1.34	

Table 4. Age-related differences in the radiographic findings score of the temporal bone in temporomandibular joint osteoarthritis (Kruskal-Wallis test)

Age group	Radiographic findings score of temporal bone	
	Mean \pm standard deviation	<i>P</i> -value
10-19	0.10 \pm 0.31	< 0.05
20-29	0.27 \pm 0.52	
30-39	0.57 \pm 0.97	
40-49	1.07 \pm 1.36	
50-59	1.33 \pm 1.42	
60-69	2.73 \pm 1.53	
70~	2.03 \pm 1.85	
Total	1.16 \pm 1.52	

were significantly lower than those in their 40s, 50s, 60s, and 70s and beyond. Additionally, those in their 30s and 40s also had significantly lower scores than those in their 60s.

The average total radiographic findings score increased from the 10s to the 60s and then slightly decreased in the age group of 70 and older. Regression analysis, using the radiographic findings score as the dependent variable, revealed significant increases in mean values of 0.231, 0.411, and 0.693 in the mandibular condyle, temporal bone, and total radiographic findings scores, respectively, with each 10-year increment in age group ($P < 0.05$). Each regression

equation was formulated as follows: radiographic findings score of mandibular condyle = $2.148 + 0.231 * \text{Age group}$, $R^2 = 0.119$; radiographic findings score of temporal bone = $-0.486 + 0.411 * \text{Age group}$, $R^2 = 0.293$; total radiographic findings score = $1.567 + 0.693 * \text{Age group}$, $R^2 = 0.264$ (Tables 3-5).

Discussion

The diagnostic criterion used in this study was that of the RDC/TMD, established in 1992 to set a global standard for TMD examinations. According to the RDC/TMD, a diagnosis of TMJ osteoarthritis is made when arthralgia (pain upon

Table 5. Age-related differences of the total radiographic findings score in temporomandibular joint osteoarthritis (1-way ANOVA)

Age group	Total radiographic findings score		
	Mean \pm standard deviation	P-value	Dunnett T3 test
10-19 (a)	2.40 \pm 1.07	<0.05	a, b < d, e, f, g c, d < f
20-29 (b)	2.60 \pm 1.30		
30-39 (c)	3.57 \pm 1.79		
40-49 (d)	4.43 \pm 2.36		
50-59 (e)	4.93 \pm 2.61		
60-69 (f)	6.87 \pm 2.89		
70~ (g)	5.57 \pm 3.11		
Total	4.34 \pm 2.70		

palpation in 1 or more joints or joint pain during maximal opening or lateral movement) is accompanied by coarse crepitus or imaging evidence of arthrosis. Conversely, the presence of either arthrosis imaging or crepitus without arthralgia is termed osteoarthrosis of the TMJ.¹⁵

In contrast, the Diagnostic Criteria for Temporomandibular Disorders (DC/TMD), published in 2014, take a different approach. They define degenerative joint disease as having a history of TMJ noise within 30 days or the patient reporting joint noise during the examination, corroborated by the examiner through crepitus, and this can be confirmed through computed tomography.²⁰ The crucial difference between these 2 diagnostic criteria is the inclusion of arthralgia as a component of the diagnosis. As the treatment plan for patients with TMJ osteoarthritis depends on the current progression of degenerative bony changes and the presence of pain as a symptom in the clinical setting, this study exclusively focused on patients with TMJ osteoarthritis adhering to the RDC/TMD diagnostic criteria.

The subject pool, selected through a random choice of 30 joints for each age group, comprised 144 women and 39 men. It is noteworthy that women were more prevalent than men in all age groups, which aligns with prior studies that have confirmed a link between sex and degenerative bony changes.^{8,21} However, in this study, there was no statistically significant correlation between age group and sex, nor were there any notable differences in findings based on sex. To present the data in a sex-neutral manner, all data were adjusted for sex.

Truelove et al.²² conducted an evaluation of the diagnostic validity of the RDC/TMD criteria and found a sensitivity of 0.10 and specificity of 0.99 for osteoarthritis. In contrast, the DC/TMD criteria, which do not differentiate

between osteoarthritis and osteoarthrosis, exhibited a sensitivity of 0.55 and specificity of 0.61, without the use of a radiographic examination during the diagnosis of degenerative joint disease.²⁰ These values are lower than those found for other diagnostic criteria of temporomandibular disorders, highlighting the essential role of imaging examinations in diagnosing TMJ osteoarthritis. This suggests that relying solely on clinical examination may be insufficient for detecting degenerative bony changes. Therefore, this study prioritized the inclusion of patients with bony changes evident on TMJ CBCT images. Clinical symptoms were then confirmed through a review of medical records, which streamlined the process of recruiting subjects.

Several studies have focused on image analysis criteria based on the RDC/TMD standards. Ahmad et al.¹⁶ confirmed their validity, including criteria for detecting degenerative bony changes in the TMJ using computed tomography. Flattening and/or subchondral sclerosis are considered less definitive indicators for osteoarthritis diagnosis, as they often reflect natural aging or progressive remodeling processes. Contemporary standards highlight erosion as a key sign of osteoarthritis, with the progression of erosion potentially leading to the formation of subchondral pseudocysts. Osteophytes signal cartilage degeneration and are associated with joint pain, suggesting osteoarthritis progression even when they are small. The identification of loose bodies in the joint space must be carefully differentiated from conditions such as synovial chondromatosis. Loose bodies should be considered indicative of osteoarthritis only when they occur alongside other significant bony changes characteristic of the disease.²

While joint space narrowing can result from osteophytes or joint disc displacement, it is considered a significant radiographic finding in knee joint osteoarthritis and can also serve as an indicator of TMJ osteoarthritis, even without the influence of gravity. The findings of the current study revealed a significant increase in joint space narrowing with age, with erosion being the most prevalent occurrence in both the mandibular condyle and articular eminence. These results are consistent with previous research outcomes.^{2,16,23}

The protruded mandibular condyle position in the glenoid fossa was predominant among individuals aged 60 and older, while the retruded mandibular condyle position was prevalent among those in their 10s and 20s. Therefore, it seems that the affected condyle in TMJ osteoarthritis tends to move from a posterior to an anterior position with advancing age.

The mandibular condyle position in the glenoid fossa among patients with TMJ osteoarthritis has sparked con-

siderable debate. In a study by Wiese et al.,²⁴ where the patients' age was not considered, the concentric position of the condyle was dominant regardless of the presence of TMJ osteoarthritis. In contrast, Gynther et al.²³ reported that the anterior position was observed in 45%, the concentric position in 40%, and the posterior position in 15% of cases (mean age: 52 years, age range: 30-76 years). Cho et al.²⁵ noted that the concentric position was most common in asymptomatic TMJ osteoarthritis cases, while the posterior position was more prevalent in symptomatic cases among children and adolescents (mean age: 15.5 years, age range: 10-18 years). These findings are partially in line with the results of this study. To date, no research has specifically examined the relationship between age and the position of the condyle in the glenoid fossa in patients with TMJ osteoarthritis, highlighting the need for further study. The findings of this study indicate that a protruded position of the mandibular condyle, along with a reduction in joint space, contributes to arthralgia and limited physiological movement on the antero-superior surface of the mandibular condyle in older individuals with TMJ osteoarthritis.

Radiographic findings scores were calculated by summing the number of radiographic finding variables within each substructure and in the overall TMJ, aiming to quantify the extent of degenerative bony changes. The results indicated a significant increase in the diversity of findings with advancing age. These findings align with those of a previous study by Alexiou et al.,²⁶ which observed a higher frequency and severity of osseous changes in older patients with TMJ osteoarthritis. The severity of degenerative bony changes across the entire TMJ became more pronounced with age, more so than in individual components. Notably, the extent of degenerative bony changes in the temporal bone, as opposed to the mandibular condyle, was more pronounced with age. Consequently, clinicians should be vigilant in examining both the mandibular condyle and the temporal bone in TMJ radiographs of elderly patients.

In this study, patient cases exhibiting only bony flattening or localized sclerosis were excluded from the analysis of radiographic findings. This exclusion was due to the common occurrence of these features in both progressive remodeling and TMJ osteoarthritis. As a result, the findings in this study may differ from those of other studies^{21,26} that included cases exclusively showing these bony changes. This difference could potentially explain the higher frequency of erosion findings observed in the present study, as compared to flattening findings.

Moreover, recent efforts have been made to quantitatively evaluate radiographic images through three-dimensional re-

construction.^{27,28} In light of these advancements, the radiographic findings score derived from CBCT images, as used in this study, could potentially be adopted in clinical settings. This would provide a straightforward and convenient method for analyzing and assessing the severity of bony deformities in TMJ osteoarthritis.

In conclusion, this study's analysis of the relationship between age and degenerative bony changes in CBCT images of the TMJ confirmed that erosions were more frequent regardless of age, and a greater variety of bony changes occurred with age. While the overall degree of degenerative bony changes was higher in the mandibular condyle than in the temporal bone, the correlation with age was more pronounced in the temporal bone. Additionally, the extent of degenerative bony changes in the entire TMJ was more noticeable than in each substructure when considered individually in relation to age.

The study's findings highlight that as individuals with TMJ osteoarthritis age, specific changes occur in the position of the mandibular condyle within the glenoid fossa. Specifically, as individuals grow older, the affected mandibular condyle tends to shift from a posterior to an anterior position within the glenoid fossa. This positional change results in the narrowing of the joint space, particularly on the antero-superior articular surface of the mandibular condyle. These alterations in condylar position and joint space can have implications for mandibular movement dysfunction, potentially contributing to the symptoms associated with TMJ osteoarthritis in elderly individuals.

Conflicts of Interest: None

References

1. Perschbacher SE. Temporomandibular joint abnormalities. In: Mallya SM, Lam E WN. White and Pharoah's oral radiology: principles and interpretation. 8th ed. St. Louis: Elsevier; 2019. p. 576-606.
2. Koç N. Evaluation of osteoarthritic changes in the temporomandibular joint and their correlations with age: a retrospective CBCT study. *Dent Med Probl* 2020; 57: 67-72.
3. de Leeuw R, Boering G, Stegenga B, de Bont LG. Radiographic signs of temporomandibular joint osteoarthrosis and internal derangement 30 years after nonsurgical treatment. *Oral Surg Oral Med Oral Pathol Oral Radiol Endod* 1995; 79: 382-92.
4. Barghan S, Tetradis S, Mallya S. Application of cone beam computed tomography for assessment of the temporomandibular joints. *Aust Dent J* 2012; 57 Suppl 1: 109-18.
5. Alkhader M, Ohbayashi N, Tetsumura A, Nakamura S, Okochi K, Momin MA, et al. Diagnostic performance of magnetic resonance imaging for detecting osseous abnormalities of the temporomandibular joint and its correlation with cone beam

- computed tomography. *Dentomaxillofac Radiol* 2010; 39: 270-6.
6. Honey OB, Scarfe WC, Hilgers MJ, Klueber K, Silveira AM, Haskell BS, et al. Accuracy of cone-beam computed tomography imaging of the temporomandibular joint: comparisons with panoramic radiology and linear tomography. *Am J Orthod Dentofacial Orthop* 2007; 132: 429-38.
 7. Jo JH, Park MW, Kim YK, Lee JY. The occurrence of degenerative change in the mandibular condyles of Korean patients with temporomandibular disorders. *J Oral Med Pain* 2011; 36: 53-63.
 8. Alzahrani A, Yadav S, Gandhi V, Lurie AG, Tadinada A. Incidental findings of temporomandibular joint osteoarthritis and its variability based on age and sex. *Imaging Sci Dent* 2020; 50: 245-53.
 9. Zhang Y, Jordan JM. Epidemiology of osteoarthritis. *Clin Geriatr Med* 2010; 26: 355-69.
 10. van Saase JL, van Romunde LK, Cats A, Vandenbroucke JP, Valkenburg HA. Epidemiology of osteoarthritis: Zoetermeer survey. Comparison of radiological osteoarthritis in a Dutch population with that in 10 other populations. *Ann Rheum Dis* 1989; 48: 271-80.
 11. Sacitharan PK. Ageing and osteoarthritis. *Subcell Biochem* 2019; 91: 123-59.
 12. Shane Anderson A, Loeser RF. Why is osteoarthritis an age-related disease? *Best Pract Res Clin Rheumatol* 2010; 24: 15-26.
 13. Jordan JM, Helmick CG, Renner JB, Luta G, Dragomir AD, Woodard J, et al. Prevalence of knee symptoms and radiographic and symptomatic knee osteoarthritis in African Americans and Caucasians: the Johnston County Osteoarthritis Project. *J Rheumatol* 2007; 34: 172-80.
 14. Ding C, Cicuttini F, Scott F, Cooley H, Jones G. Association between age and knee structural change: a cross sectional MRI based study. *Ann Rheum Dis* 2005; 64: 549-55.
 15. Dworkin SF, LeResche L. Research diagnostic criteria for temporomandibular disorders: review, criteria, examinations and specifications, critique. *J Craniomandib Disord* 1992; 6: 301-55.
 16. Ahmad M, Hollender L, Anderson Q, Kartha K, Ohrbach R, Truelove EL, et al. Research diagnostic criteria for temporomandibular disorders (RDC/TMD): development of image analysis criteria and examiner reliability for image analysis. *Oral Surg Oral Med Oral Pathol Oral Radiol Endod* 2009; 107: 844-60.
 17. Greene MW, Hackney FL, Van Sickels JE. Arthroscopy of the temporomandibular joint: an anatomic perspective. *J Oral Maxillofac Surg* 1989; 47: 386-9.
 18. Honda K, Larheim TA, Sano T, Hashimoto K, Shinoda K, Westesson PL. Thickening of the glenoid fossa in osteoarthritis of the temporomandibular joint. An autopsy study. *Dentomaxillofac Radiol* 2001; 30: 10-3.
 19. Hansson T, Oberg T, Carlsson GE, Kopp S. Thickness of the soft tissue layers and the articular disk in the temporomandibular joint. *Acta Odontol Scand* 1977; 35: 77-83.
 20. Schiffman E, Ohrbach R, Truelove E, Look J, Anderson G, Goulet JP, et al. Diagnostic Criteria for Temporomandibular Disorders (DC/TMD) for clinical and research applications: recommendations of the International RDC/TMD Consortium Network* and Orofacial Pain Special Interest Group. *J Oral Facial Pain Headache* 2014; 28: 6-27.
 21. Bae S, Park MS, Han JW, Kim YJ. Correlation between pain and degenerative bony changes on cone-beam computed tomography images of temporomandibular joints. *Maxillofac Plast Reconstr Surg* 2017; 39: 19.
 22. Truelove E, Pan W, Look JO, Mancl LA, Ohrbach RK, Velly AM, et al. The research diagnostic criteria for temporomandibular disorders. III: validity of Axis I diagnoses. *J Orofac Pain* 2010; 24: 35-47.
 23. Gynther GW, Tronje G, Holmlund AB. Radiographic changes in the temporomandibular joint in patients with generalized osteoarthritis and rheumatoid arthritis. *Oral Surg Oral Med Oral Pathol Oral Radiol Endod* 1996; 81: 613-8.
 24. Wiese M, Svensson P, Bakke M, List T, Hintze H, Petersson A, et al. Association between temporomandibular joint symptoms, signs, and clinical diagnosis using the RDC/TMD and radiographic findings in temporomandibular joint tomograms. *J Orofac Pain* 2008; 22: 239-51.
 25. Cho BH, Jung YH. Osteoarthritic changes and condylar positioning of the temporomandibular joint in Korean children and adolescents. *Imaging Sci Dent* 2012; 42: 169-74.
 26. Alexiou K, Stamatakis H, Tsiklakis K. Evaluation of the severity of temporomandibular joint osteoarthritic changes related to age using cone beam computed tomography. *Dentomaxillofac Radiol* 2009; 38: 141-7.
 27. Bianchi J, Gonçalves JR, de Oliveira Ruellas AC, Ashman LM, Vimort JB, Yatabe M, et al. Quantitative bone imaging biomarkers to diagnose temporomandibular joint osteoarthritis. *Int J Oral Maxillofac Surg* 2021; 50: 227-35.
 28. Cevidanes LH, Hajati AK, Paniagua B, Lim PF, Walker DG, Palconet G, et al. Quantification of condylar resorption in temporomandibular joint osteoarthritis. *Oral Surg Oral Med Oral Pathol Oral Radiol Endod* 2010; 110: 110-7.