

A surgeon with symptomatic ventricular tachycardia while operating and exacerbated by left lateral decubitus position: Too much of a stretch?



Faris Khan, MD, MS,* Gregory K. Feld, MD, FHRS,* Amir Schricker, MD, FHRS,*
Frederick T. Han, MD, FHRS,† Kurt S. Hoffmayer, MD, FHRS,* Jonathan C. Hsu, MD, MAS, FHRS*

From the *Section of Cardiac Electrophysiology, Division of Cardiology, University of California San Diego, La Jolla, California, and †Section of Cardiac Electrophysiology, Division of Cardiology, University of Utah, Salt Lake City, Utah.

Introduction

Idiopathic ventricular arrhythmias are seen in patients with otherwise structurally normal hearts. Common areas of origin include the ventricular outflow tracts, the left ventricular (LV) base including the intracavitary structures, and the right ventricular (RV) inflow region. The moderator band (MB) of the RV is an intracavitary structure that has been implicated in idiopathic ventricular arrhythmias.^{1,2} The authors report a case of an otherwise healthy surgeon with palpitations and light-headedness associated with premature ventricular contractions (PVCs) and ventricular tachycardia (VT), exacerbated by the left lateral decubitus position and a potential stretch mechanism, and found to be arising from the RV MB.

Case report

A 62-year-old neurosurgeon with no significant medical history was in his usual state of health until a week prior when he began having intermittent palpitations. Subsequently, while standing and performing a surgical procedure in the operating room, he felt the sensation of palpitations and profound light-headedness. He was unable to complete the surgical procedure, and staff in the operating room were able to perform a 12-lead electrocardiogram (ECG; in the supine position), which showed frequent PVCs and 2-lead telemetry showed salvos of nonsustained ventricular tachycardia (NSVT) of the same morphology (Figures 1A and 1B). The patient denied any other symptoms of angina or acute coronary syndrome, including chest pain, shortness of breath, paroxysmal nocturnal dyspnea, or orthopnea. He

denied drug use and had no family history of cardiac disease or sudden cardiac death. Physical examination was normal. Laboratory examination was notable for normal potassium and creatinine levels.

After admission during hospitalization, he continued to have palpitations and profound light-headedness associated with PVCs and NSVT of up to 30 beats in length (Figure 1B), despite treatment with intravenous lidocaine. He underwent coronary angiography, which showed severe disease involving the first diagonal branch of the left anterior descending artery, but the remaining arteries did not have significant obstructive coronary artery disease (CAD) (Online Supplemental Video 1). Because of the sudden onset of PVCs and VT and no overt clinical symptoms of angina or acute coronary syndrome, percutaneous coronary intervention of the diagonal branch was deferred and medical management was advised by the interventional cardiology team for newly diagnosed CAD. His transthoracic echocardiogram showed normal LV and RV function with preserved ejection fraction and no LV wall motion abnormalities. Upon further questioning, he reported noticing distinct and reproducible worsening of ventricular ectopy including ventricular bigeminy and NSVT while on cardiac telemetry monitoring when he was placed in the left lateral decubitus position. Upon lying in the right lateral recumbent or supine position, he had minimal ventricular ectopy. Because of the recurrent nature of his ventricular arrhythmias, an electrophysiology study and possible ablation was recommended after a cardiac magnetic resonance imaging was performed. Cardiac magnetic resonance imaging showed focal hypokinesis and delayed enhancement in the mid- and apical anterior LV myocardium (diagonal artery territory) compatible with a prior ischemic event and no other abnormality (Supplemental Video 1). LV and RV function was overall preserved.

KEYWORDS Moderator band; Ventricular tachycardia; Ablation; Right ventricle; Stretch; Premature ventricular contractions (Heart Rhythm Case Reports 2017;3:210–214)

Address reprint requests and correspondence: Dr Jonathan C. Hsu, Section of Cardiac Electrophysiology, Division of Cardiology, University of California San Diego, 9454 Medical Center Dr 3rd Fl, Rm 3E-417 La Jolla, CA 92037. E-mail address: Jonathan.Hsu@ucsd.edu.

Analysis of the ECG

The patient's baseline ECG showed sinus rhythm with PVCs in a bigeminal pattern (Figures 2A and 2B). A review of the

KEY TEACHING POINTS

- Stretch mechanism can be involved in ventricular tachycardia induction from the moderator band.
- Use of intracardiac echocardiography can be useful to confirm ablation catheter position around the moderator band insertion site.
- Idiopathic ventricular tachycardia originating from the moderator band may have excellent outcomes after radiofrequency ablation.

telemetry showed that all ventricular ectopy was monomorphic with a left bundle branch block morphology with superior axis, and the 12-lead ECG showed an R-wave transition from negative to positive at precordial lead V₅, left bundle branch block pattern, and left superior axis. Vectorcardiography indicated an inferolateral RV free wall exit site.

Electrophysiology study

In the electrophysiology laboratory, the patient was prepped and draped in a standard fashion, and 3-dimensional electroanatomic mapping patches and 12-lead ECG patches were placed. While the patient was in the supine position, there was no evidence of ventricular arrhythmias, even without sedative medication. Subsequently, provocative testing was performed by placing the patient in the left lateral decubitus position, which immediately reproduced the clinically relevant ventricular ectopy in a bigeminal pattern (Figures 2A–2D). The ventricular ectopy was recorded, and a 12-lead ECG morphology template was created for possible pace-map matching with the recording system (Bard Electrophysiology, Lowell, MA). The CARTO 3-dimensional electroanatomic mapping system (Biosense Webster Inc., Diamond Bar, CA) was used with the CARTO-Sound module along with an 8-F phased array CARTO-Sound intracardiac echocardiography (ICE) catheter. CARTO-Sound and ICE were used to precisely delineate the anatomy of the RV endocardium, papillary muscles, and MB. A 3.5-mm D/F curve Smart TouchThermocool (Biosense Webster) mapping/ablation catheter was used. After creating geometry using the mapping catheter in addition to CARTO-Sound, we attempted to induce VT using burst pacing from the RV apex down to 300 ms and programmed electrical stimulation at 500 ms with single extrastimuli down to 300 ms. No ventricular ectopy or VT could be induced with RV pacing at baseline or during infusion of isoproterenol up to 5 µg/min. Atrial burst pacing was also performed from the proximal coronary sinus catheter down to a cycle length of 400 ms; however, this was also not able to induce ventricular arrhythmia. Owing to a lack of ventricular ectopy in the supine position despite ventricular pacing and programmed electrical stimulation, we used the previously templated PVCs obtained when the patient was in the left lateral decubitus position to perform pace mapping in an attempt to localize the exit site

of a presumed ectopic ventricular arrhythmia source. Under guidance of a 3-dimensional geometry created by CARTO-Sound, an RV MB was identified that extended from the inferior-lateral and mid free wall of the RV to the basal septum of the RV. Pace mapping was performed from the distal bipole of the ablation catheter at 5 mA and 2.0-ms pulse width duration, with ICE guidance, throughout the RV ventricular endocardium, along the papillary muscles, and along the MB. A pace-map match as high as 98% on both the Bard system and the CARTO-Paso system (Figures 3A–3C) was observed at the inferior-lateral free wall RV insertion site of the MB (Figure 3C), which was presumed to be the exit site of ventricular arrhythmia. Radiofrequency catheter ablation was performed at the best pace-match site, at the inferior-lateral free wall RV insertion site of the MB (Figures 3D and 3E and Online Supplemental Video 2). Radiofrequency energy up to 50 W was delivered at this site during sinus rhythm for up to 60–90 seconds during each ablation. To avoid complication while using 50 W power during ablation, we used a contact force sensing catheter to avoid any persistently high force application to avoid any potential risk of perforation. The impedance graph was also monitored throughout each ablation to evaluate for any rise that would be a precursor to a steam pop, and ablation was terminated if any sudden impedance rise was seen. In addition, the ablation catheter at the MB insertion site was constantly visualized using ICE during radiofrequency ablation. During initial ablation, salvos of PVCs and VT were observed that matched the morphology (>95% match) of the preablation PVC template. These salvos of PVCs resolved after further ablation of the RV MB lateral free wall insertion site. A total of 27 ablations were performed in the area surrounding the best pace-map match site near the RV MB insertion site. Postablation, reinduction of PVCs and VT was attempted with RV burst pacing and programmed electrical stimulation, both off and on isoproterenol infusion up to 5 µg/min. No ventricular ectopy was seen. We then reversed sedation completely and placed the patient in the left lateral decubitus position with all sheaths still in place, because of concern that the only preprocedural evidence of ventricular arrhythmia was in this position. In this left lateral decubitus position, no ventricular ectopy was seen. After a 30-minute waiting period without PVCs or VT, the procedure was terminated. Postablation, antiarrhythmic drugs were discontinued. Telemetry overnight did not show any clinical PVCs or NSVT, despite the patient lying in the left lateral decubitus position. Aspirin, atorvastatin, and an angiotensin-converting enzyme inhibitor were initiated and continued as an outpatient treatment because of newly diagnosed CAD. The patient was discharged home the next day in stable condition.

Follow-up

The patient resumed normal activity the day after the procedure and resumed work including performing surgery within 5 days after being discharged. He was evaluated in the outpatient arrhythmia clinic 1 month postablation and was noted to have no

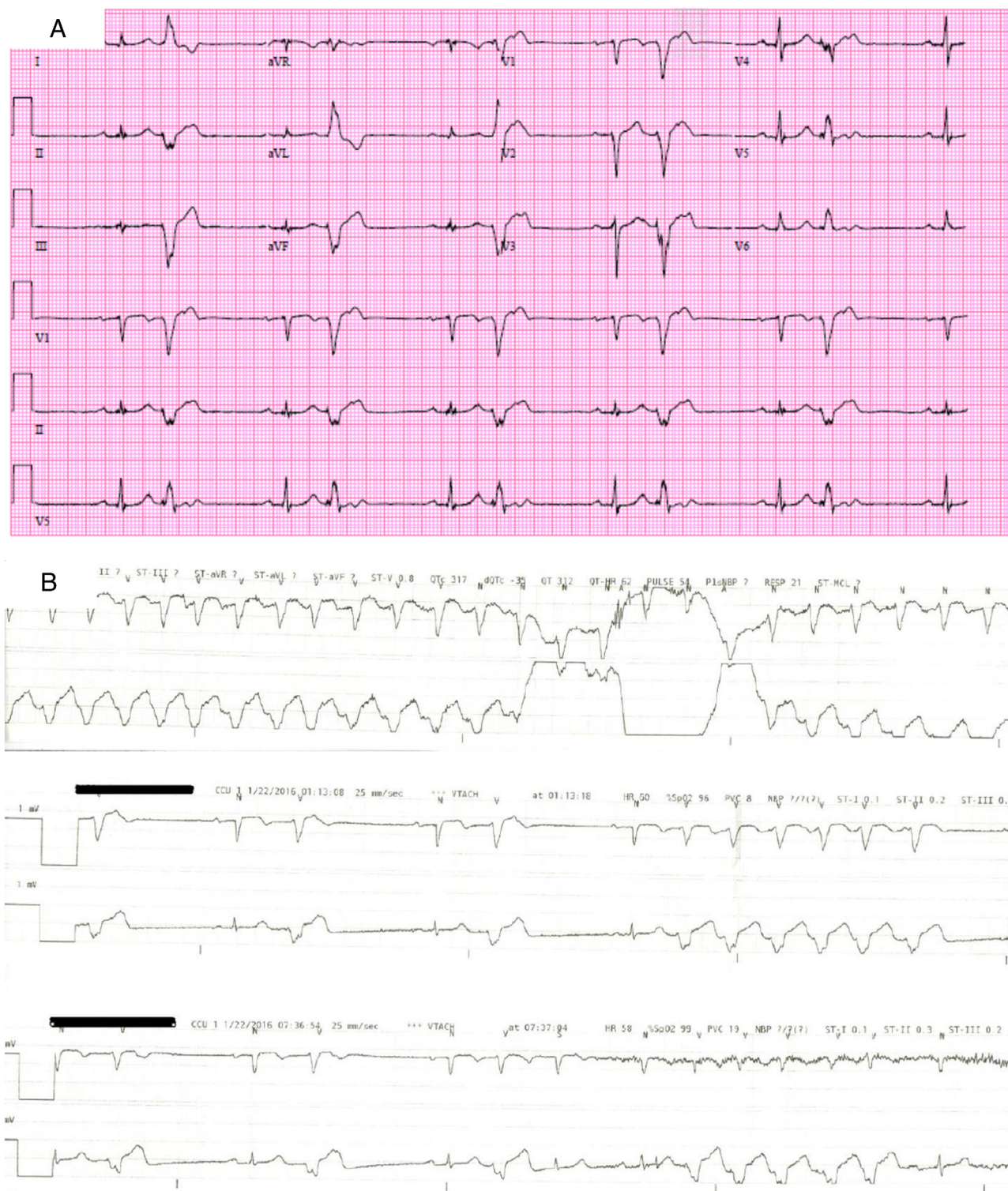


Figure 1 A: Twelve-lead electrocardiogram showing a ventricular bigeminy pattern on lateral decubitus positioning. B: Telemetry strips showing runs of nonsustained ventricular tachycardia.

symptoms indicative of recurrent ventricular arrhythmias. A repeat ECG showed normal sinus rhythm without PVCs.

Discussion

The MB is a muscular structure that spans from the RV septal wall to the free wall. It contains Purkinje fibers (PFs) and is

innervated by autonomic nerves.³ Idiopathic ventricular arrhythmias originating from the MB are often monomorphic with distinct ECG characteristics.¹ In addition, arrhythmias originating from myocardial tissue containing PFs have excellent outcomes after treatment with radiofrequency ablation.^{1,4,5} The exact mechanism of PVC/VT origination

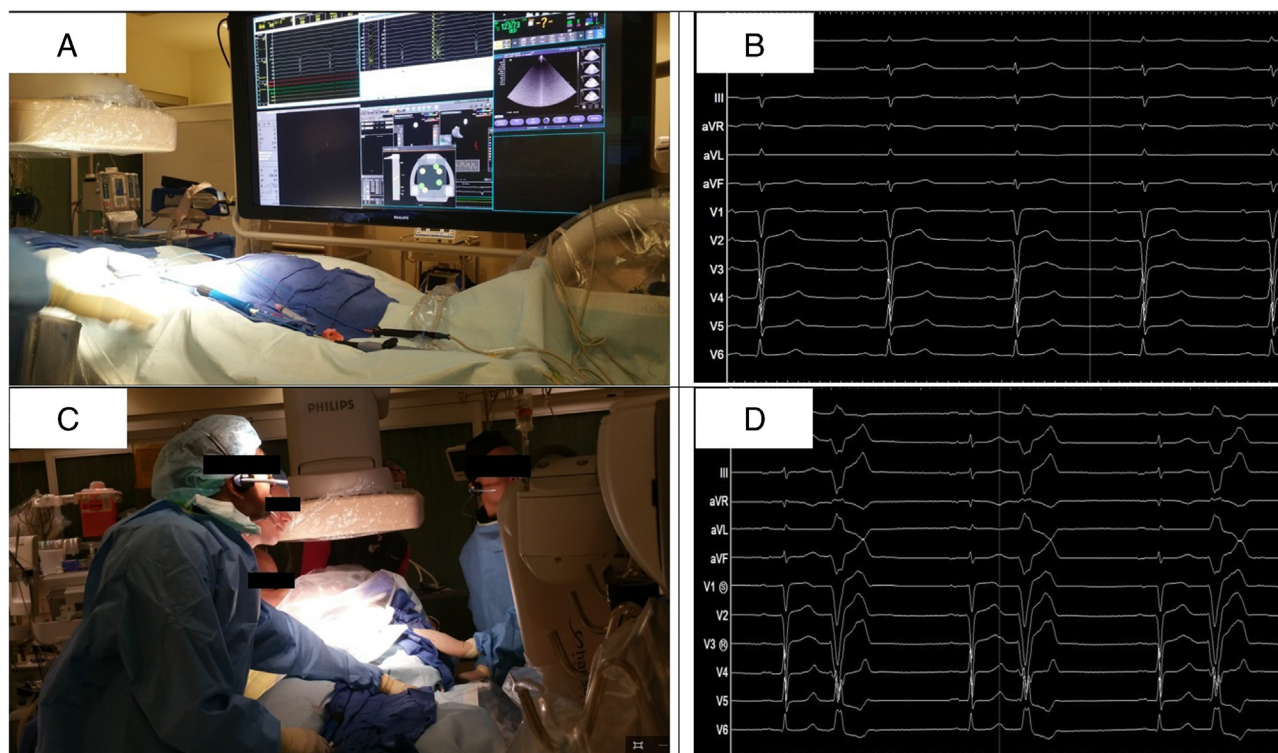


Figure 2 A and B: Patient in the supine position (panel A), with the 12-lead electrocardiogram showing normal sinus rhythm (panel B) with no ectopy. C and D: Patient now in the left lateral recumbent position (panel C), with the 12-lead electrocardiogram showing ventricular bigeminy (panel D).

from the MB remains unclear; however, several mechanisms have been proposed including early depolarization with inward calcium currents in the Purkinje system leading to ventricular ectopy or arrhythmia, abnormal refractory period of PFs at the MB leading to reentrant ventricular arrhythmias, and autonomic innervation of MB potentially affecting refractory periods and predisposing to VT initiation from PVCs.¹

To our knowledge, this is the first report of an idiopathic ventricular arrhythmia arising from the RV MB clearly exacerbated by patient body position. It is possible that the left lateral decubitus position may have caused the heart to shift within the thoracic cavity, with an increase in the rate of RV filling and/or increased RV filling pressure, which would be concentrated at the RV apex and the MB. The dynamics of the LV diastolic filling may have also contributed to the arrhythmogenesis, with the possibility of increased LV filling pressures affecting the interventricular septum and subsequently the MB. With the increased RV filling pressure and/or myocardial stretch upon the MB, the subsequent increase in intracellular calcium levels and associated early afterdepolarizations could elicit the PVCs noted in this case. An additional related possible mechanism could be increased venous blood flow to the right atrium and RV in the left lateral decubitus position, with dilatation of these chambers resulting in ventricular arrhythmias due to mechanical stretch.

The positional nature of PVC/VT has been postulated previously. In a case report by Betsuyaku et al,⁶ the stretch

mechanism was postulated as a possible hypothesis for an LV false tendon; however, ablation was not performed. In our case, we not only postulated but also proved that the ventricular ectopy due to positional changes could not be reinduced after ablation of the MB, an RV structure. Gautam et al⁷ also observed positional nature of the VT; however, they did not postulate the probable mechanism. Mechanical stretch has also been proposed as a mechanism initiating PF early depolarization leading to VT initiation.^{1,8} Other examples of arrhythmogenesis in which mechanical stretch has been implicated include atrial tachycardia and atrial fibrillation (AF).^{1,9} Solti et al¹⁰ observed that dilatation of the left atrium by inflation of a balloon catheter in dog hearts led to decreased atrial effective refractory period, increasing atrial tachyarrhythmia vulnerability. Ravelli and Allesie¹¹ used Langendorff-perfused rabbit hearts to show shortening of atrial effective refractory period and monophasic action potential after increased myocardial stretch by elevated atrial pressure predisposing to increased AF vulnerability. Ueda et al¹² observed that an increased intra-atrial pressure and decreased conduction across gap junctions facilitate AF occurrence. Other studies have shown that both selective and nonselective stretch activated ion channels as well as increased calcium inward current may lead to arrhythmogenic electrical changes in the myocardium.^{8,12} In addition, mechanical stretch may stimulate collagen deposition that then provides a substrate for AF.¹³ Similar mechanisms may be involved in ventricular arrhythmias, but we are unaware of previous descriptions involving this phenomenon.

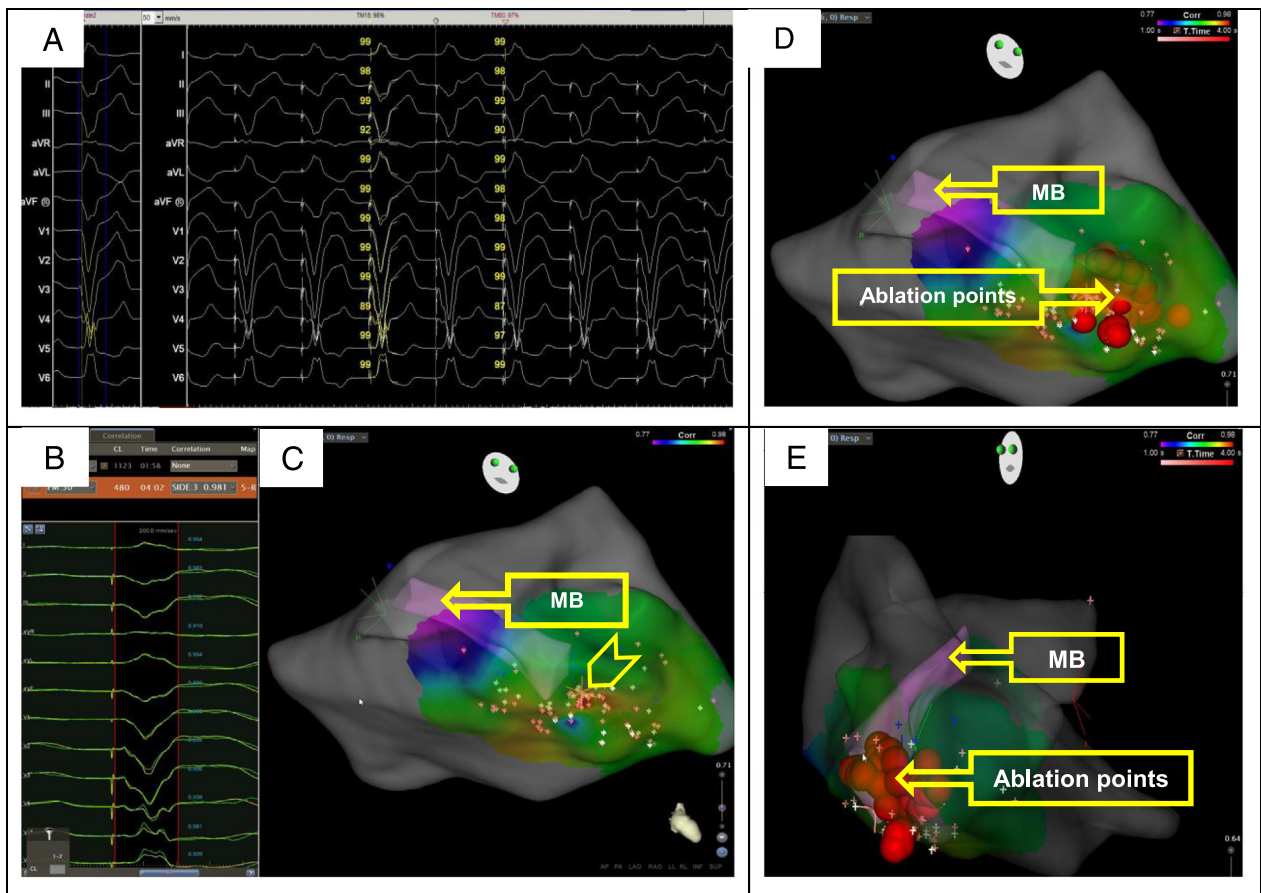


Figure 3 **A:** Twelve-lead electrocardiogram template showing 98% pace-map match. **B:** CARTO-Paso template showing 98% match. **C:** Color map showing Paso correlation points (red color with highest correlation). Star (pointed by a chevron) on the fast anatomic map in a right anterior oblique–caudal view shows the best match on the Paso and Bard mapping systems. **D and E:** CARTO 3-dimensional map with the moderator band (MB; in pink color) and ablation lesions in a right anterior oblique–caudal view (panel D) and in a left anterior oblique view (panel E). The fill threshold was set to 10.

Conclusion

Idiopathic PVCs and VT originating from MB are not uncommon. We report a case of a patient with PVCs and VT refractory to medical therapy and induced with left lateral decubitus positioning, alleviated by radiofrequency catheter ablation of the inferior-lateral and free RV wall insertion site of the MB. We propose a stretch mechanism involved in triggering ventricular arrhythmia from the MB. Further research is needed to determine the role of mechanical stretch on arrhythmogenesis in humans, as well as the exact mechanisms.

Appendix

Supplementary data

Supplementary data associated with this article can be found in the online version at <http://dx.doi.org/10.1016/j.hrcr.2017.01.001>.

References

- Sadek MM, Benhayon D, Sureddi R, et al. Idiopathic ventricular arrhythmias originating from the moderator band: electrocardiographic characteristics and treatment by catheter ablation. *Heart Rhythm* 2015;12:67–75.
- Anter E, Buxton AE, Silverstein JR, Josephson ME. Idiopathic ventricular fibrillation originating from the moderator band. *J Cardiovasc Electrophysiol* 2013;24:97–100.
- Bojsen-Moller F, Tranum-Jensen J. On nerves and nerve endings in the conducting system of the moderator band (septomarginal trabecula). *J Anat* 1971;108:387–395.
- Haissaguerre M, Shoda M, Jais P, et al. Mapping and ablation of idiopathic ventricular fibrillation. *Circulation* 2002;106:962–967.
- Knecht S, Sacher F, Wright M, et al. Long-term follow-up of idiopathic ventricular fibrillation ablation: a multicenter study. *J Am Coll Cardiol* 2009;54:522–528.
- Betsuyaku T, Yonezawa K, Sakurai M, Kitabatake A. Positional ventricular tachycardia. *Pacing Clin Electrophysiol* 2004;27:1437–1439.
- Gautam PL, Kathuria S, Sood D, Kaul TJ. Recurrent positional ventricular tachycardia in a patient with carcinoma of the oesophagus. *Anaesthesia* 2003;58:98.
- Bode F, Katchman A, Woosley RL, Franz MR. Gadolinium decreases stretch-induced vulnerability to atrial fibrillation. *Circulation* 2000;101:2200–2205.
- Anter E, Jessup M, Callans DJ. Atrial fibrillation and heart failure: treatment considerations for a dual epidemic. *Circulation* 2009;119:2516–2525.
- Solti F, Vecsey T, Kekesi V, Juhasz-Nagy A. The effect of atrial dilatation on the genesis of atrial arrhythmias. *Cardiovasc Res* 1989;23:882–886.
- Ravelli F, Alessie M. Effects of atrial dilatation on refractory period and vulnerability to atrial fibrillation in the isolated Langendorff-perfused rabbit heart. *Circulation* 1997;96:1686–1695.
- Ueda N, Yamamoto M, Honjo H, Kodama I, Kamiya K. The role of gap junctions in stretch-induced atrial fibrillation. *Cardiovasc Res* 2014;104:364–370.
- Lubitz SA, Benjamin EJ, Ellinor PT. Atrial fibrillation in congestive heart failure. *Heart Fail Clin* 2010;6:187–200.