




Contents lists available at ScienceDirect

## Epilepsy &amp; Behavior Reports

journal homepage: [www.elsevier.com/locate/ebcr](http://www.elsevier.com/locate/ebcr)

## Case report

## Focal bilateral motor seizures precipitated by abrupt cessation of chronic lormetazepam abuse and amitriptyline overdose

Rosario Rossi <sup>\*</sup>, Francesca Di Stefano, Sara Lizzos, Gianluca Deiana

Neurology and Stroke Unit, San Francesco Hospital, Nuoro, Italy

## ARTICLE INFO

## Article history:

Received 29 April 2020

Received in revised form 10 July 2020

Accepted 15 July 2020

Available online 31 July 2020

## Keywords:

Benzodiazepine withdrawal

Lormetazepam

Focal seizures

## ABSTRACT

We report the case of an adult psychiatric patient who developed new-onset focal bilateral motor seizures (FBMS) in the context of a severe benzodiazepine withdrawal syndrome. The patient was forced to interrupt chronic lormetazepam abuse and overdosed on amitriptyline (800 mg in an oral solution) before the onset of seizures. Typical signs of amitriptyline intoxication such as sedation and anticholinergic effects were not observed. Video-EEG recordings revealed a stereotypical ictal motor pattern with asymmetric tonic posturing and bilateral clonic movements of the upper limbs, but there were no abnormalities identified by EEG. Seizures recurred multiple times per day but resolved simultaneously when withdrawal symptomatology subsided eight days after onset. Nonepileptic seizures (NES) were considered in the differential diagnosis because of the patient's psychiatric history including preserved awareness during the bilateral convulsions, the absence of postictal confusion, and normal EEG. The present case indicates that FBMS may occur during benzodiazepine withdrawal in patients who overdosed on amitriptyline. The diagnosis may be challenging as FBMS may mimic NES in the absence of abnormal neurophysiologic findings. This may be especially challenging in patients with an underlying psychiatric disease.

© 2020 The Author(s). Published by Elsevier Inc. This is an open access article under the CC BY-NC-ND license (<http://creativecommons.org/licenses/by-nc-nd/4.0/>).

## 1. Introduction

Epileptic seizures (ES) have been frequently reported as clinical manifestations of benzodiazepine withdrawal, an acute disorder precipitated by an abrupt discontinuation of chronic therapies including benzodiazepines. The withdrawal symptomatology may also include insomnia, irritability, muscular pain and stiffness, hand tremor, anxiety, and psychotic episodes [1]. An acute reduction in brain gamma-aminobutyric acid function has been indicated as a pathogenic mechanism of the syndrome [2]. While generalized tonic-clonic seizures are the most common, focal seizures are rarely reported in this condition. Particularly, focal nonconvulsive seizures have been described in patients treated with flumazenil during detoxification from lormetazepam abuse [3].

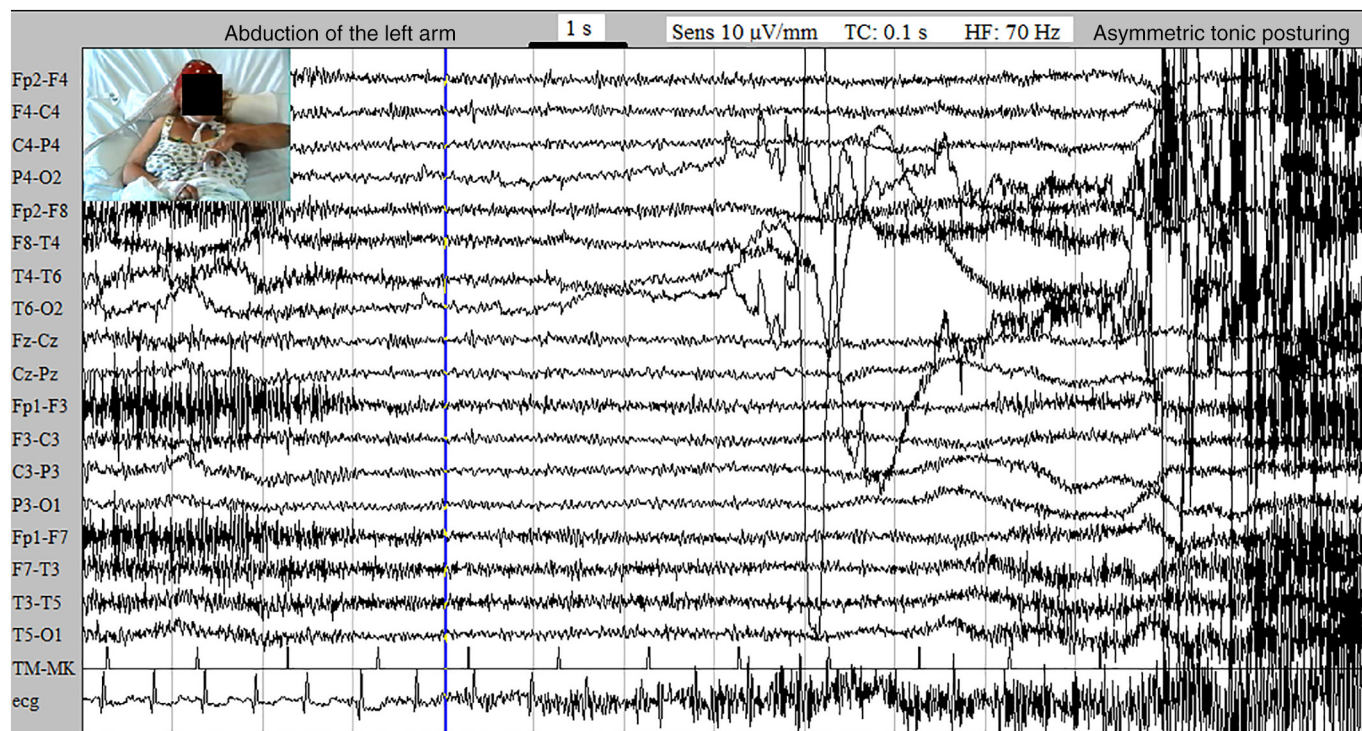
## 2. Case report

A 46-year-old woman with a clinical history of schizoaffective and personality disorders presented to our hospital with new-onset convulsive seizures. It was reported that the patient was forced to interrupt chronic lormetazepam abuse (a daily drug consumption of

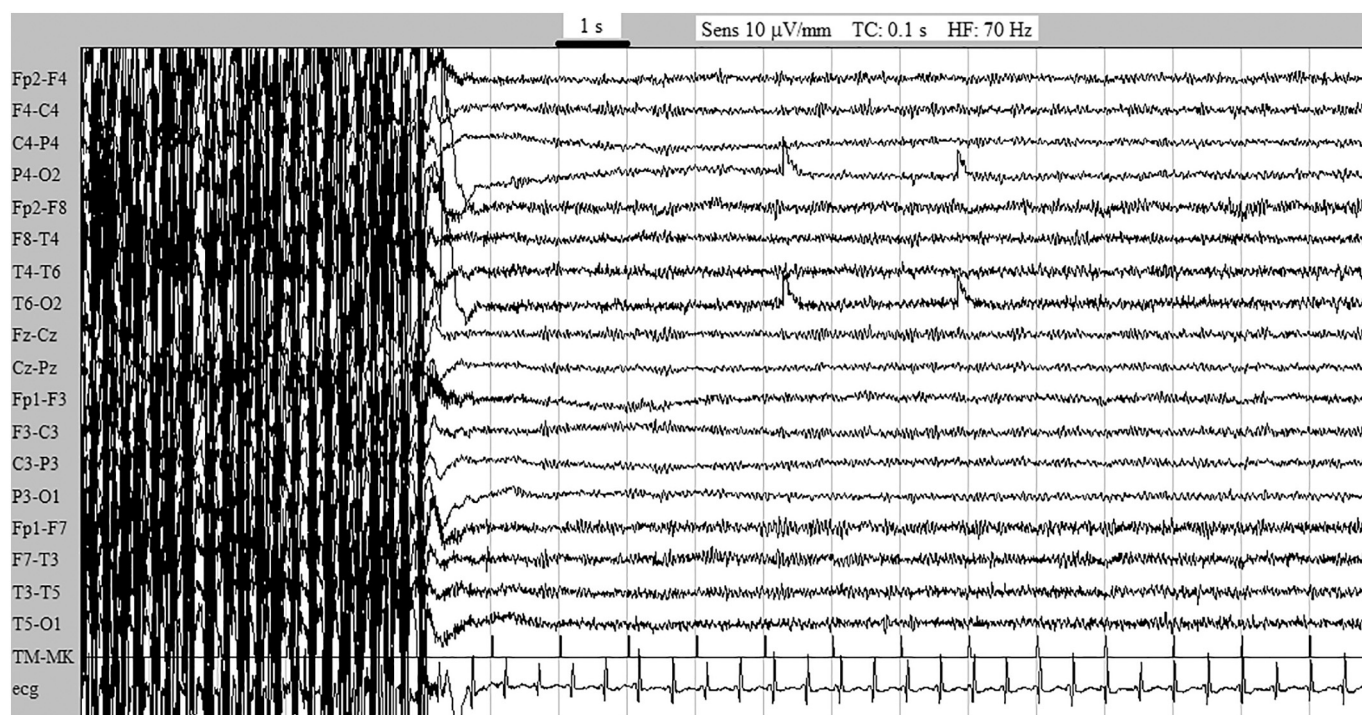
150–250 mg of an oral solution) the day before the onset of seizures. When she ran out of the medication, she ingested an oral solution containing 800 mg of amitriptyline as a supposed sedative substitute for lormetazepam. Convulsive seizures recurred multiple times per day in the hospital during daytime and night-time hours in a clinical context of insomnia, restlessness, muscular rigidity, and painful spasms affecting the back muscles that implicated a benzodiazepine withdrawal syndrome. There was no evidence of amitriptyline toxicity, as the patient did not show sedation, anticholinergic effects, arterial hypotension, or cardiac arrhythmias. The amitriptyline blood level was not obtained. Seizures presented with a duration of approximately 53 s and a paroxysmal, stereotyped sequence of movements that was documented with video-EEG. The recordings of seizures, using the usual 10–20 system of electrode placement, did not show EEG abnormalities or postictal slowing of the background activity, but the tracings were disturbed by myogenic artifacts throughout the course of the events (Figs. 1–2). Awareness was preserved during the episodes. The patient occasionally called for help at seizure onset but remained unresponsive until the cessation of movements. Rapid recovery of speech and an absence of postictal confusion were reported on different occasions. Magnetic resonance imaging of the brain was normal. Three days after the patient's admission, a cluster of convulsive episodes prompted a short intensive treatment with propofol and mechanical ventilation. Seizures were increasingly observed again after extubation, despite oral treatment with clonazepam, levetiracetam, and repeated

<sup>\*</sup> Corresponding author at: Neurology and Stroke Unit, San Francesco Hospital, via Mannironi, 08100 Nuoro, Italy.

E-mail address: [rosariovirgilio.rossi@atssardegna.it](mailto:rosariovirgilio.rossi@atssardegna.it) (R. Rossi).



**Fig. 1.** EEG recording of the initial phase of a focal bilateral motor seizure with a still-frame from the video. The EEG does not reveal evident abnormalities at seizure onset. The tracing is progressively disturbed by myogenic artifacts during the evolution of the seizure motor pattern.



**Fig. 2.** EEG recording of the final phase of a focal bilateral motor seizure. Phasic myogenic artifacts mark the tracing during the ending clonic phase of the seizure. The EEG shows the persistence of the background activity in the immediate postictal period.

intravenous administrations of diazepam. Regardless of the inefficacy of the treatment during an eight-day period of intense seizure activity, the patient eventually became seizure-free. The remission of seizures occurred simultaneously with the cessation of insomnia and muscular symptoms related to lormetazepam withdrawal. Clonazepam and

levetiracetam were subsequently reduced and discontinued as the patient remained asymptomatic. Despite the absence of ictal EEG abnormalities, a retrospective analysis of the seizure semiology based on video recordings and additional recorded observations of the episodes at bedside suggested the clinical diagnosis of FBMS,

presumably arising from the supplementary sensorimotor area (SSMA). This diagnostic conclusion was supported by the evidence of a paroxysmal, stereotyped ictal motor pattern with early abduction of the arm flexed at the elbow and subsequent asymmetric tonic posturing of the upper limb that reproduced the figure four sign [4] at seizure onset. The left arm was extended, and the right arm was flexed (at the elbow), while the head was briefly turned to the left at this point of the seizure. Consequent bilateral clonic movements of the upper limbs showed a typical epileptic pattern with a gradual frequency decline and a progressive amplitude increase of movements [5]. A stereotyped left hemifacial spasm was also noted during the tonic contraction of the upper limbs. The short duration of the episodes, occasional evidence of cyanosis and lack of pupillary reactivity served as additional clues to the ES diagnosis. Although the clinical picture was initially confounded by the patient's preserved awareness during the bilateral convulsions, the absence of postictal confusion, and the normal EEG findings, these features finally appeared consistent with FBMS arising in the SSMA, as previously reported in the literature [6–8]. The patient was discharged with a normal neurologic status nine days after the last convulsive episode. Seizures did not recur even without antiseizure medication during the following month, after which the patient was lost to follow-up.

### 3. Discussion

The manifestation of convulsive seizures without EEG abnormalities in the context of benzodiazepine withdrawal syndrome and psychiatric disease requires a differential diagnosis of ES and nonepileptic seizures (NES). In fact, the abrupt interruption of high dosage, chronic benzodiazepine treatment represents a potential precipitating factor for ES, while NES are occasionally observed as imitators of epilepsy in patients with mental health problems [9,10]. In addition to the psychiatric disorders and the normal neurophysiologic findings, the patient's preserved awareness during the bilateral convulsions and the absence of postictal confusion confounded the clinical picture with the potential to misdiagnose FBMS as NES. FBMS are described as motor onset seizures arising in one cerebral hemisphere and rapidly involving bilateral motor networks, often with asymmetric tonic posturing [11]. The SSMA is classically recognized as the anatomical origin of FBMS [11]. Clinical characteristics of focal onset seizures arising in the SSMA include short duration (typically not exceeding 40 s) [6,12]; predominant onset during sleep [6,8]; somatosensory aura [8,13]; preserved awareness [6,8,13]; absence of postictal confusion [8]; vocalization or speech arrest [6,8,13]; unilateral tonic posturing [8,13] or bilateral, asymmetric tonic posturing [4,13,14]; bilateral abduction of the upper extremities [6]; and bilateral thrashing movements [6,8] that usually constitute a paroxysmal, stereotyped motor pattern in the same individual [6]. Particularly, asymmetric tonic posturing has been related to the asynchronous activation of the SSMA [4,14], thus representing a key semiologic feature of seizures involving this cortical area [8,12]. Authors have also referred to asymmetric tonic posturing as the figure four sign that marks focal to bilateral tonic-clonic seizures [4]. The lateralizing value of this sign has been repeatedly reported with the epileptogenic focus usually contralateral to the arm that is extended at the elbow [4,14]. In contrast, NES with convulsive-like manifestations are characterized by long duration (frequently exceeding 2 min); fluctuating course; and asynchronous movements (typically side-to-side head movements and out of phase limb movements) that show unchanged frequency and variable amplitude throughout the event [10].

In our patient, the convulsive disorders shared most of the mentioned clinical characteristics of focal onset seizures arising in the SSMA. In particular, the origin of ictal symptoms in the SSMA was suggested by the early stereotyped contraction of the left arm and consequent asymmetric tonic posturing of limbs, while a left hemifacial spasm appeared consistent with the presumed epileptic focus in the

right cerebral hemisphere. The progression of these phenomena to bilateral, tonic extension and clonic movements of the upper extremities characterized the final phase of the motor pattern mimicking focal to bilateral tonic-clonic seizures. However, the absence of awareness impairments, postictal confusion and EEG slowing in the immediate postictal phase discredited the apparent bilateral tonic-clonic evolution of focal seizures, suggesting limited epileptic involvement of the SSMA during the entire course of the events. While the seizure semiology could be referred to FBMS arising from the SSMA, the absence of ictal EEG abnormalities to confirm epileptic seizures is a limiting factor for the diagnosis of frontal lobe seizures. This suggests the potential utility of EEG recordings with additional midline electrodes (placed according to the 10–10 system) and/or ictal SPECT, as a supplementary method to confirm the epileptic nature and the anatomical origin of the seizures. However, it is not uncommon for seizures arising in the mesial and deep structures of the frontal lobe to have absent scalp ictal EEG changes utilizing the 10-20 international system of electrode placement.

Although structural brain abnormalities were not documented in our patient, neurochemical alterations induced by benzodiazepine withdrawal into specific networks may have resulted in a major seizure susceptibility of the SSMA. Interestingly, a major intrinsic epileptogenicity of specific cortical areas has been postulated by Albiero et al. to explain the occurrence of focal seizures in patients who underwent detoxification from chronic lorazepam abuse [3]. Additional information is needed to ascertain the major occurrence of focal seizures in patients who interrupted chronic lorazepam abuse. Although amitriptyline may have lowered the seizure threshold, the precise clinical impact of the substitution remains uncertain in our patient, as typical symptoms of amitriptyline intoxication such as sedation, arterial hypotension, cardiac arrhythmias or anticholinergic effects [15] were not observed during the period of recurrent seizures. In contrast, the strict concomitance of seizures with classic benzodiazepine abstinence symptoms such as insomnia, restlessness, rigidity, and muscular pain clearly indicated the primary precipitating role of lorazepam withdrawal. A previous report remarked that lorazepam is the benzodiazepine that is most frequently associated with abuse and dependence [16], particularly when it is used in the form of an oral solution [17]. The presence of ethanol in the oral solution of lorazepam has been specifically suspected to increase the risks for abuse and dependence. Although ethanol quantities may not be relevant in patients treated with accurate doses of lorazepam (1.5–2.5 mg daily for insomnia), the pathogenic effect of ethanol may be significant in lorazepam addicted patients. The present case provides additional information about the risks of lorazepam addiction as a component of psychiatric care. We suggest strict monitoring of patients treated with an oral solution of this medication.

### 4. Conclusion

FBMS may be observed during the clinical manifestation of lorazepam withdrawal in patients who overdosed on amitriptyline. FBMS may produce a confusing clinical picture, with the potential to misdiagnose NES, especially when no abnormal neurophysiologic findings are clearly identified and when patients have a known underlying psychiatric disease.

Supplementary data to this article can be found online at <https://doi.org/10.1016/j.ebr.2020.100385>.

### Ethical statement

The authors state that the study described in the paper complies with the publishing ethics of the journal.

The patient's face has been partially obscured in the attached video, as requested by the patient herself at the time of the given consent.

**Declaration of competing interest**

The authors state that there is no conflict of interest.

**References**

- [1] Petursson H. The benzodiazepine withdrawal syndrome. *Addiction*. 1994;89:1455–9.
- [2] Cowen PJ, Nutt DJ. Abstinence symptoms after withdrawal of tranquillising drugs: is there a common neurochemical mechanism? *Lancet*. 1982;2:360–2.
- [3] Albiero A, Brigo F, Faccini M, Casari R, Quaglio G, Storti M, et al. Focal non convulsive seizures during detoxification for benzodiazepine abuse. *Epilepsy Behav*. 2012;23:168–70.
- [4] Kotagal P, Bleasel A, Geller E, Kankirawatana P, Moorjani BI, Rybicki L. Lateralizing value of asymmetric tonic posturing observed in secondarily generalized tonic-clonic seizures. *Epilepsia*. 2000;41:457–62.
- [5] Tufenkjian K, Lüders HO. Seizure semiology: its value and limitations in localizing the epileptogenic zone. *J Clin Neurol*. 2012;8:243–50.
- [6] Kanner AM, Morris HH, Lüders H, Dinner DS, Wyllie E, Medendorp SV, et al. Supplementary motor seizures mimicking pseudo-seizures: some clinical differences. *Neurology*. 1990;40:1404–7.
- [7] Adamolekun B, Foreman A. Post-ictal alpha activity in supplementary motor seizures mimics non-epileptic seizures. *Epilepsy Behav*. 2010;18:317–21.
- [8] Morris HH, Dinner D, Lüders H, Wyllie E, Kramer R. Supplementary motor area seizures: clinical and electrographic findings. *Neurology*. 1988;38:1075–88.
- [9] International League Against Epilepsy. EpilepsyDiagnosis.org diagnostic manual. <https://www.epilepsydiagnosis.org/epilepsy-imitators.html#psychogenic>. [Accessed 30 June 2020].
- [10] Curt LaFrance Jr W, Baker GA, Duncan R, Goldstein LH, Reuber M. Minimum requirements for the diagnosis of psychogenic nonepileptic seizures: a staged approach. A report from the International League Against Epilepsy Nonepileptic Seizures Task Force. *Epilepsia*. 2013;54:2005–18.
- [11] International League Against Epilepsy. EpilepsyDiagnosis.org diagnostic manual. <https://www.epilepsydiagnosis.org/seizure/motor-overview.html>. [Accessed 22 March 2020].
- [12] International League Against Epilepsy. EpilepsyDiagnosis.org diagnostic manual. <https://www.epilepsydiagnosis.org/seizure/frontal-lobe-overview.html>. [Accessed 22 March 2020].
- [13] Sitthinamsuwan B, Usui N, Tottori T, Terada K, Kondo A, Matsuda K, et al. Seizures with tonic posturing: semiologic difference between supplementary sensorimotor area (SSMA) origin and extra-SSMA origin. *Epilepsia*. 2016;57:39–44.
- [14] Loddenkemper T, Kotagal P. Lateralizing signs during seizures in focal epilepsy. *Epilepsy Behav*. 2005;7:1–17.
- [15] Güloğlu C, Orak M, Ustündag M, Altuncu YA. Analysis of amitriptyline overdose in emergency medicine. *Emerg Med J*. 2011;28:296–9.
- [16] Faccini M, Leone R, Pajusco B, Quaglio G, Casari R, Albiero A, et al. Lormetazepam addiction: data analysis from an Italian medical unit for addiction. *Risk Manag Healthc Policy*. 2012;5:43–8.
- [17] Faccini M, Tamburin S, Casari R, Morbioli L, Lugoboni F. High-dose lormetazepam dependence: strange case of Dr Jekyll and Mr Hyde. *Intern Emerg Med*. 2019;14:1271–8.