



Contents lists available at ScienceDirect

International Journal of Surgery Case Reports

journal homepage: www.casereports.com

A case of lung volume reduction surgery with decortication for a septic patient in respiratory failure

M. Tarazi*, N. Mayoaran, M. Anwer, M.N. Anjum, K. Doddakula

Department of Cardiothoracic Surgery, Cork University Hospital, Ireland

ARTICLE INFO

Article history:

Received 27 May 2015

Received in revised form 22 October 2015

Accepted 31 October 2015

Available online 4 November 2015

Keywords:

Bullae

Emphysema

Decortication

Lung-volume-reduction

Thoracic surgery

ABSTRACT

INTRODUCTION: Decortication and lung volume reduction surgery are both major operations and each has its independent risk of morbidity and mortality.

CASE REPORT: We present the case of a 41 year old gentleman with left sided empyema and giant bullae of the upper lobe with an active air leak that was transferred to our tertiary referral centre for further management. We performed emergency left thoracotomy, decorticated the left lower lobe with extensive lung volume reduction surgery of the upper lobe. Patient's respiratory status significantly improved along with excellent radiological results.

CONCLUSION: Our case demonstrates that a combination of complex procedures is feasible with excellent outcomes.

© 2015 The Authors. Published by Elsevier Ltd. on behalf of IJS Publishing Group Ltd. This is an open access article under the CC BY-NC-ND license (<http://creativecommons.org/licenses/by-nc-nd/4.0/>).

1. Background

Secondary spontaneous pneumothorax is a pneumothorax that occurs as a complication of underlying lung disease [1,2]. In the treatment of this condition, pleurodesis is commonly achieved by either pleurectomy or chemical pleurodesis. An endoscopic stapler can be used to resect bullae or blebs most of the time.

Thoracic empyema is defined as pus in the pleural space. Debridement and decortication is carried out in multiloculated empyemas that fail to resolve with antibiotics and chest tube drainage.

Bullae are defined as sharply demarcated, air-filled spaces within the parenchyma of the lung, measuring one centimetre or greater in distended diameter, which are formed as a result of the destructive process of emphysema or alpha-1 antitrypsin deficiency [3].

Giant Bullous disease was first described by Burke et al. in 1937 as a case of Vanishing Lung Syndrome [4] which was characterised by unilateral or bilateral asymmetric upper lobe involvement with the formation of multiple bullae [9]. It can be challenging to differentiate from a pneumothorax which has a similar picture on a plain chest radiograph [10] which may lead to misdiagnosis and mismanagement.

Decortication and lung volume reduction surgery are both major operations and each has its independent risk of morbidity and mortality.

2. Case presentation

A 41 year old gentleman presented to the Emergency Department of a General Hospital complaining of sudden onset left sided chest pain. He has no past medical or surgical history. He is a smoker with a 25 pack year history.

Chest radiograph was reported as a large left sided pneumothorax. This was treated with insertion of a 28 Fr chest drain. Due to the acute presentation with significant respiratory sepsis, it was not possible to perform valid pulmonary function tests on this patient. During his hospital stay, he continued to have a significant air leak and his lung failed to re-expand fully.

On day 7 of admission, he spiked a temperature of 38.2 °C and became septic. His chest radiograph showed a left sided pleural effusion raising the suspicion of an empyema. Sampling of his pleural fluid was turbid looking with a pH of 6.96. He was subsequently referred to our tertiary referral centre on day 10 for further management (Fig. 1).

On arrival, the patient was severely dyspnoeic and febrile but otherwise haemodynamically stable. His physical examination was unremarkable apart for decreased air entry to the left lower zone which was dull to percussion.

Hb 12.7 g/dL, WCC $13.9 \times 10^9/L$, alpha-1 antitrypsin was negative.

CT thorax was performed and reported as a large loculated left sided hydropneumothorax with fluid in the base and large

* Corresponding author.

E-mail addresses: munirtarazi@rcsi.ie

(M. Tarazi), nmayoaran@rcsi.ie (N. Mayoaran), anwer253@yahoo.com (M. Anwer), anjummn@hotmail.com (M.N. Anjum), corkkishore@gmail.com (K. Doddakula).

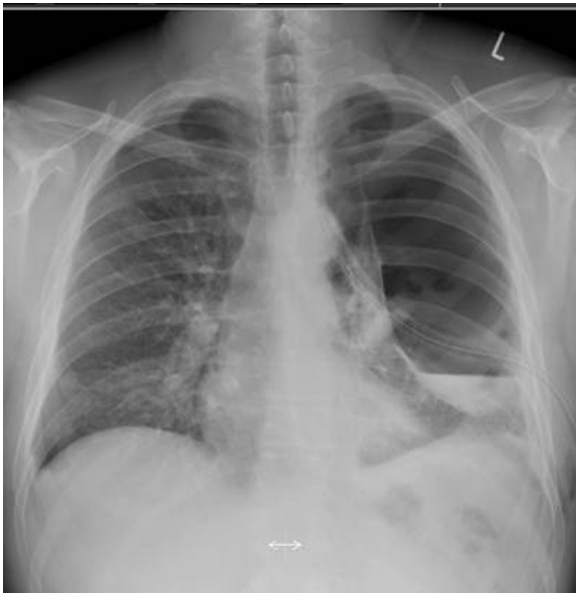

Fig. 1. PA chest radiograph showing a left sided pneumothorax and empyema with chest drain in situ.

pneumothorax locules/complex bullous lung disease compressing the upper lobe. The right lung was normal. He was commenced on broad spectrum antibiotics – Flucloxacillin, Vancomycin, and Piperacillin/Tazobactam – as per microbiology advice with minimal improvement (Fig. 2).

We proceeded to perform emergency left posterolateral thoracotomy and decortication with lung volume reduction surgery. Preoperative V/Q testing is not used as a routine preoperative investigation at our institution and thus was not performed. His operative findings showed multiple giant bullae in the upper lobe, and a lower lobe with thick pleura that was decorticated. Note that this patient's preoperative flexible bronchoscopy was normal. Due to significant bullous disease and adhesions due to the empyema, it was considered too risky to perform a thoracoscopic debridement on this patient.

Histopathology report of surgical samples contained a left apical bullae measuring $4.7 \times 2 \times 1.5$ cm and another left lung bullae measuring $11.8 \times 6.5 \times 3$ cm. Microscopic examination of these bullae confirmed large airspaces lined by variably thickened but uniformly fibrotic walls. Decorticated parietal pleura were also sent showing fibrotic and thickened pleura with surface fibrin, mesothelial cell

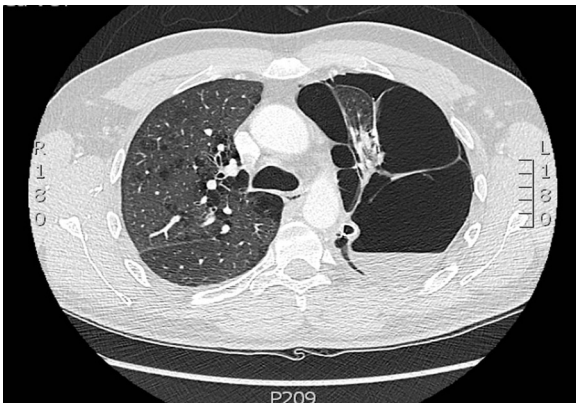


Fig. 2. CT thorax showing a large left sided hydropneumothorax and giant bullae. Right lung was normal.

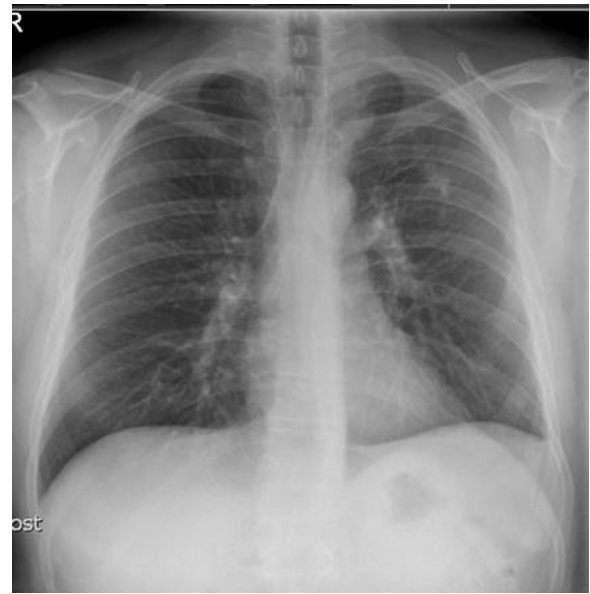


Fig. 3. Post-operative chest radiograph prior to discharge.

hyperplasia and eosinophils with scattered lymphoid aggregates. There was no evidence of malignancy.

Microbiological examination of the parietal pleura grew coagulase negative staphylococcus bacteria and was negative for acid-alcohol fast bacilli and for mycobacteria TB culture.

The patient's respiratory status significantly improved along with excellent radiological results. He was discharged on day 7 post operatively. Postoperative pulmonary function tests were not performed as the patient's respiratory status was not compromised (Fig. 3).

3. Methods

This case report has been reported in line with the CARE criteria [11].

4. Discussion

Given the presenting history, we feel this patient's left sided chest pain could have been secondary to pleurisy from a developing empyema rather than a pneumothorax. Initially, the operative plan was to treat this patient's empyema and perform a decortication. Peri-operatively, the patient was difficult to ventilate secondary to a massive air leak from the giant bullae; hence it was decided to perform a lung volume reduction surgery.

Bullous lung disease is an uncommon cause of respiratory distress. In patients with severe emphysema, discrete emphysematous bullae have been shown to functionally impair pulmonary mechanics and result in diminished exercise capacity and even acute respiratory distress [6]. Giant bullae refers to the enlargement of one or more bullae to such a degree that they fill more than one third of the hemithorax [3]. The disease usually afflicts young male smokers and is characterised by large bullae in the upper lobes of the lung [7].

A bulla results from destruction of the integrity of the alveolar tissue [8] and leakage of air into the interstitium [9]. Giant bullae are considered to be hard to rupture, because the rise in the internal pressure in a bulla spreads in a horizontal direction and the bigger the bulla, the less is the change of the pressure inside the bulla [8].

Bullae can produce signs and radiologic appearances of pneumothorax and it is important to differentiate them

before treatment. The differentiation between giant bulla and pneumothorax can be very difficult and often leads to inaccurate diagnosis and management [5].

The role of CT scan in the diagnosis of pneumothorax in the presence of bullous lung disease is vital as it can avoid unnecessary chest drain insertion. High resolution computed tomography (HRCT) plays an important role in characterising the degree and distribution of emphysema, providing information necessary for operative planning in symptomatic individuals. HRCT is often used to assist in the final diagnosis of Giant Bullous disease as it has been shown to have significant correlation ($r=0.94$) with pathologic grade on resected lung specimens [7].

The NETT trial showed that patients most likely to benefit from lung volume reduction surgery have heterogeneously distributed emphysema involving the upper lung zones predominantly. Lung volume reduction surgery increases the chance of improved exercise capacity but does not confer a survival advantage over medical therapy. Survival benefit was limited to patients with predominantly upper lobe emphysema and a low baseline exercise capacity. Functional benefits were noted in patients with predominantly upper lobe emphysema and a high baseline exercise capacity and in patients with non-upper lobe emphysema and a low baseline exercise capacity [10].

5. Conclusion

Our case demonstrates the feasibility of achieving an excellent overall outcome with a combination of complex procedures.

Conflicts of interest

No conflicts of interest.

Funding

No sources of funding.

Ethical approval

None.

Author contribution

All authors contributed in the study design, writing of the paper, and final approval of the case report.

Consent

Written informed consent was obtained from the patient for publication of this case report and any accompanying images. A copy of the written consent is available for review by the Editor-in-Chief of this journal.

Guarantor

Dr. Munir Tarazi.
Dr. Nithiananthan Mayooran.
Mr. Muhammad Anwer.
Mr. Muhammad Nadeem Anjum.
Mr. Kishore Doddakula.

References

- [1] S.A. Sahn, J.E. Hefner, Spontaneous pneumothorax, *N. Engl. J. Med.* 342 (12) (2000) 868–874.
- [2] M. Noppen, T. De Keukeleire, Pneumothorax, *Respiration* 76 (2) (2008) 121–127.
- [3] Mohsen Sokouti, Samad Golzari, A giant bulla of the lung mimicking tension pneumothorax, *J. Cardiovasc. Thorac. Res.* 2 (2) (2010) 41–44.
- [4] R. Burke, Vanishing lungs: a case report of bullous emphysema, *Radiology* 28 (3) (1937) 367–371.
- [5] Abhishek Jha, Ajay Gupta, Prakhar Gupta, Gagan Gupta, Ibne Ahmad, Mohd Saud, Vanishing lung disease in an adult misdiagnosed as pneumothorax, *Clin. Med.* 14 (2) (2014) 210–211.
- [6] Grayson Wheatley III, Aaron Estrera. Bullous Lung Disease. CTSNet (2010) Available at: <http://www.ctsnet.org/sections/clinicalresources/clinicalcases/article-1>.
- [7] Nidhi Sharma, Al Mamoon Justaniah, Jeffrey P. Kanne, Jud W. Gurney, Tan-Lucien H. Mohammed, Vanishing lung syndrome (giant bullous emphysema): CT findings in 7 patients and a literature review, *J. Thorac. Imaging* 24 (3) (2009) 227–230.
- [8] Muhammad Waseem, Jodi Jones, Sargine Brutus, John Munyak, Ramnath Kapoor, Joel Gernsheimer, Giant bulla mimicking pneumothorax, *J. Emerg. Med.* 29 (2) (2005) 155–158.
- [9] Naveed Nazir Shah, Rakesh Bhargava, Zuber Ahmed, Deepak Kumar Pandey, Mohd Shameem, Arshad Altaf Bachh, Khurshid Ahmad Dar, The vanishing lung, *Can. J. Emerg. Med.* 9 (3) (2007) 233–234.
- [10] National Emphysema Treatment Trial Research Group, A randomized trial comparing lung-volume-reduction surgery with medical therapy for severe emphysema, *N. Engl. J. Med.* 348 (21) (2003) 2059–2073.
- [11] J.J. Gagnier, G. Kienle, D.G. Altman, D. Moher, H. Sox, D.C.A.R.E. Riley Group, The CARE guidelines: consensus-based clinical case reporting guideline development, *BMJ Case Rep.* (2013), <http://dx.doi.org/10.1136/bcr-2013-201554>, pii: bcr2013201554.

Open Access

This article is published Open Access at sciedirect.com. It is distributed under the [IJSCR Supplemental terms and conditions](#), which permits unrestricted non commercial use, distribution, and reproduction in any medium, provided the original authors and source are credited.